



Case Report

Granulomatous rhinitis in a case of feline leishmaniasis

Alexandre Arenales¹, Camila Eckstein¹, Jaqueline Azevedo², Gisele M. S. Reginaldo², Valéria M. F. Lima², Daniela B. Rozza², Renato L. Santos¹

¹Escola de Veterinária, Universidade Federal de Minas Gerais, Belo Horizonte, MG, Brazil. Av. Antônio Carlos, 6627 - São Luiz, Belo Horizonte – MG, 31270-901.

²Faculdade de Medicina Veterinária de Araçatuba, Universidade Estadual Paulista, Araçatuba, SP, Brazil. Rua Clóvis Pestana, 793 – Dona Amélia, Araçatuba – SP, 16050-680.

*Corresponding author: Universidade Federal de Minas Gerais, Escola de Veterinária, Departamento de Clínica e Cirurgia Veterinárias. Av. Antônio Carlos, 6627, 31270-901 Belo Horizonte, MG, Brazil. Fone: (+55) 31-3409-2239. Fax: 31-3409-2230. E-mail: rsantos@vet.ufmg.br.

Submitted October, 10th 2017, Accepted January, 10th 2018

Abstract

This is a case report of leishmaniasis with granulomatous rhinitis in a 2-year-old domestic cat. Clinically, an obstruction in the right nostril was observed, with cytopathological examination positive for *Leishmania* sp. Euthanasia was performed, and multinodular, diffuse and smooth pinkish lesions were observed in the mucosa of the nasal cavity. Microscopically, nodular lesions corresponded to an intense granulomatous inflammation with macrophages containing large numbers of *Leishmania* sp. amastigotes. Macrophages containing amastigotes were also occasionally observed in the popliteal lymph node, skin, and spleen. Based on immunohistochemistry, amastigotes were confirmed as *Leishmania* sp. and *Leishmania* sp. DNA was also detected by qPCR in lymph nodes samples. Although it is an uncommon manifestation, leishmaniasis should be considered as a differential diagnosis in diseases affecting the nasal cavity in domestic felines.

Key words: immunohistochemistry, cat, nasal cavity, leishmaniasis.

Introduction

Leishmaniasis is a worldwide zoonotic disease, caused by the protozoan *Leishmania infantum* (synonym *Leishmania chagasi*). Visceral leishmaniasis is mainly studied in dogs and well described in this species, which is considered an important reservoir for human infections (2). Due to the high prevalence of canine leishmaniasis in certain parts of Brazil, it is likely that other species may be at high risk of infection, including domestic cats. However, there is little information available about epidemiology, susceptibility, and pathogenesis of leishmaniasis in cats (3).

Reports of feline leishmaniasis include one experimental study of cats inoculated with *L. braziliensis* (11), and a series of cases of cats naturally infected with *L. mexicana* in Texas (16), and natural infection with *L. infantum* in the Mediterranean basin (5). In Brazil, there are cases reported in the states of Mato Grosso do Sul (13,

14), Minas Gerais (6), São Paulo (1, 8, 17), and Rio de Janeiro (9, 10). Clinically, those cases were presented as skin and mucocutaneous junction ulcerative nodules, mainly on the face.

Considering the scarcity of reported cases of feline leishmaniasis, here we describe a case of leishmaniasis associated with granulomatous rhinitis in a domestic cat as the primary and atypical manifestation of the disease.

Case report

A 2-year-old female Brazilian short hair cat with breathing difficulty was admitted at the veterinary hospital of the Universidade Estadual Paulista (HV/UNESP; State of São Paulo, Brazil) in May 2014. Clinically, there were abnormal respiratory sounds originated from the superior respiratory tract, and there was an evident stenosis of the

right nostril (Fig. 1). Swabs were obtained for culture, and cytopathology was performed using a gynecological brush.

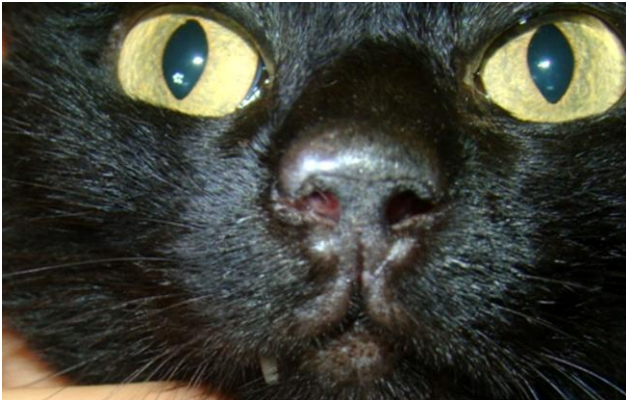

Figure 1. Brazilian short hair cat, female, 2-year-old. Right nostril with obstruction. Amastigotes of *Leishmania* sp. were observed by cytopathology.

Fungal culture was negative for *Sporothrix schenckii* and *Cryptococcus neoformans*, whereas cytopathological slides stained with Diff-Quick (LB; Laborclin; Paraná, Brazil) contained large amounts of amastigotes with morphology compatible with *Leishmania* sp., supporting the presumptive diagnosis of leishmaniasis.

Euthanasia was performed according to Brazilian sanitary regulation (4), and the cat was necropsied. Grossly, the animal was mildly emaciated with a focally extensive bilateral symmetrical alopecia and hypotrichosis in the extremity of the pinnae. After longitudinal sectioning of the partially obstructed right nostril, multinodular pinkish smooth proliferative areas were observed in the mucosa (Fig. 2). In the liver, there were multifocal red areas randomly distributed in the parenchyma, measuring approximate 0.5 cm in diameter, and gall bladder distention, containing numerous trematode parasites morphologically compatible with *Platynosomum* sp.

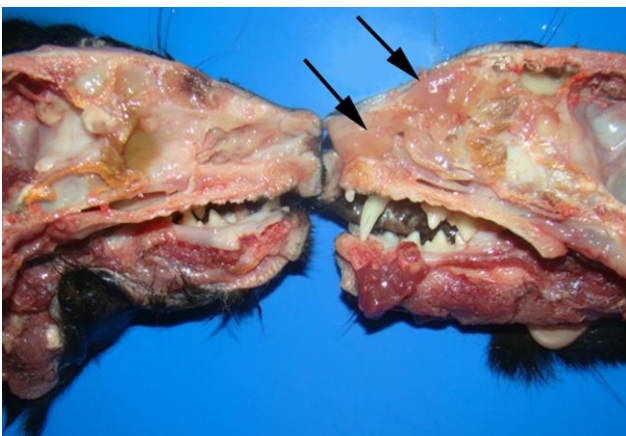


Figure 2. Cross section of nasal cavity. Nasal mucosa with multinodular and smooth proliferative lesion (arrows).

Microscopically, a diffuse expansion of the nasal turbinate, with accumulation of large numbers of macrophages and a mild amount of lymphocytes and plasma cells was observed, supporting the morphologic diagnosis of diffuse granulomatous rhinitis (Fig. 3). Several macrophages contained numerous intracytoplasmic round to oval amastigotes measuring approximately 2 to 4 μm in diameter with an oval nucleus measuring approximated 1 μm in diameter and a kinetoplast. The nasal cavity was variably filled with cellular debris and neutrophils. Moreover, at the periosteum of nasal conchae, intense and diffuse osteoblastic hyperplasia and hypertrophy were observed.

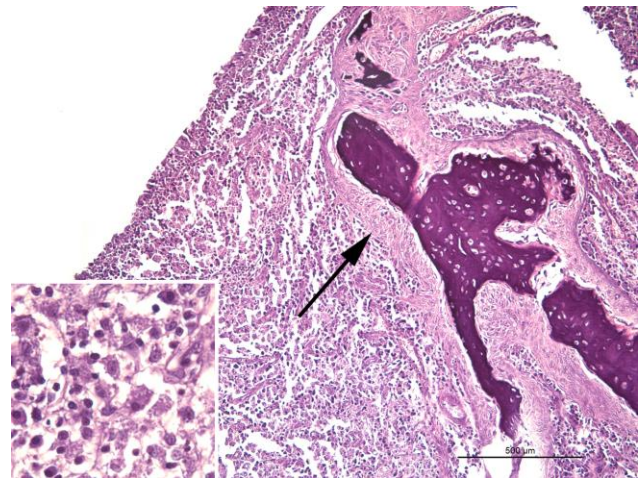


Figure 3. Histological section, nasal turbinate. Severe granulomatous infiltrate in the subepithelial connective tissue, notice the osteoblastic hyperplasia and hypertrophy (arrow). histiocytic infiltration, with intracellular round to oval amastigotes measuring approximately 2 to 4 μm . Hematoxylin and eosin. Bar = 500 μm .

The skin of the pinnae had a mild to moderate inflammatory infiltrate composed of macrophages containing amastigotes and moderate number of lymphocytes in the dermis, characterizing a mild and diffuse granulomatous dermatitis.

In the popliteal lymph node there were also macrophages containing amastigotes, with severe lymphoid hyperplasia and moderate plasma cell accumulation, characterizing a histiocytic lymphadenitis. In addition, there was a neutrophilic splenitis with moderate lymphoid hyperplasia and small amounts of amastigotes in a few macrophages. Marked alveolar edema associated with a mild and diffuse congestion was observed in the lung.

Immunohistochemistry was performed as previously described (15), using 3-Amino-9-ethylcarbazole (AEC) instead of diaminobenzidine (DAB) as chromogen, resulting in intense staining of amastigotes in macrophages in the nasal turbinate and nostrils (Fig. 4 and 5). Moreover, few to rare immunostained amastigotes were observed in the popliteal lymph node, spleen, and bone marrow.

Additionally, a small focal area of bone marrow, adjacent to the nostrils, filled with a large number of amastigotes that were evidenced by immunohistochemistry (Fig. 6). The *Leishmania* sp. DNA was detected in samples from lymph nodes by qPCR (data not shown) as previously described (18).

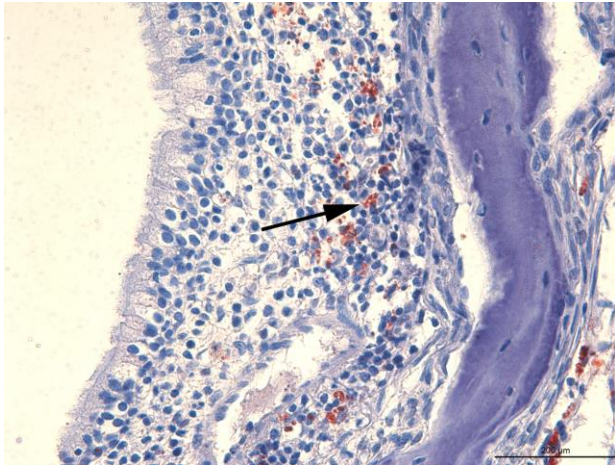


Figure 4. Immunohistochemistry for *Leishmania* sp. Nasal turbinate with granulomatous rhinitis, inside macrophages at laminae propriae, strongly positive structures compatible with *Leishmania* sp. (arrow). Streptavidin–peroxidase complex with AEC, and Mayer's hematoxylin counterstain. Bar = 200 μ m.

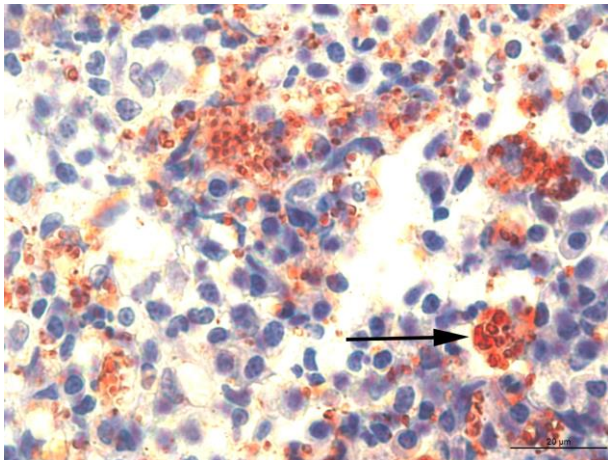


Figure 5. Immunohistochemistry for *Leishmania* sp. Nasal turbinate with macrophages containing strongly positive structures in cytoplasm (arrow). Streptavidin–peroxidase complex with AEC, and Mayer's hematoxylin counterstain. Bar = 20 μ m.

Discussion

This report describes a case of feline visceral leishmaniasis in a domestic cat with an atypical manifestation. To the best of our knowledge, this is the first reported case of diffuse granulomatous rhinitis associated with feline leishmaniasis. Although canine

visceral leishmaniasis has been extensively studied, *Leishmania* sp. infection in cats has been poorly studied, and the majority of studies concern parasitology, serology and epidemiology, barely describing pathological changes (1, 5, 6, 8-10, 14, 17).

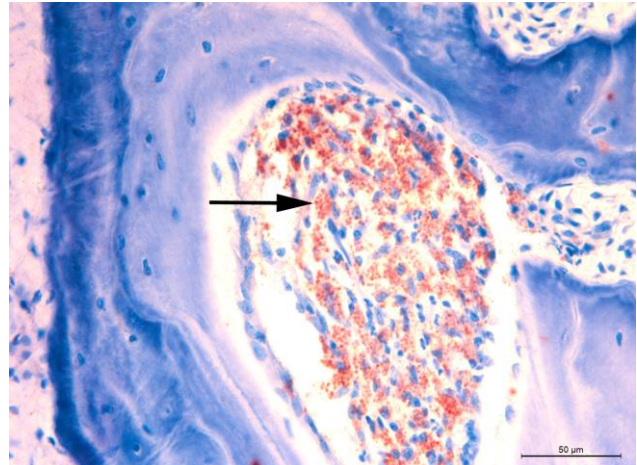


Figure 6. Immunohistochemistry for *Leishmania* sp. A small focal area of bone and bone marrow adjacent to the nostrils, which is filled with large amounts of macrophages containing numerous immunostained amastigotes (arrow). Streptavidin–peroxidase complex with AEC, and Mayer's hematoxylin counterstain. Bar = 50 μ m.

This case occurred in a region that is endemic to canine visceral leishmaniasis (7). Interestingly, cats in endemic areas usually do not develop clinical signs, which when present, are mostly restricted to the skin (3).

Our findings were histologically similar to those previously reported by other authors (1, 5, 6, 8-10, 14, 17). However, in spite of previous reports of lesions in the muzzle and rhinitis, they did not describe the extension of the lesions inside the nasal cavity, neither involvement of bone tissue, although bone involvement is an atypical manifestation in canine visceral leishmaniasis (12). A previous study in the same region as this case found 27 positive cats for *L. infantum* based on different diagnosis methods, including direct parasitological exam, PCR, serology, and immunohistochemistry (17). Those cats had skin lesions in the head, mainly in pinnae, with ulcers and hemorrhagic crusts. However, histopathology was not performed. In a series of eight cases from integumentary biopsies, gross lesions by *Leishmania mexicana* were described as single to multiple ulcerated nodules at pinnae, muzzle and periorbital skin, which were microscopically characterized by granulomatous inflammation with amastigote-laden macrophages (16). Another series of fifteen cases (5) described macroscopic changes mainly as cutaneous nodules, pododermatitis, conjunctivitis, panofthalmitis, which were microscopically associated with granulomatous inflammation at skin and mucocutaneous junctions, lichenoid interface dermatitis, granulomatous dermatitis with eosinophilic granuloma, granulomatous

perifolliculitis, and granulomatous panophtalmitis, with amastigotes of *Leishmania* sp. with macrophages, but only one case in this series had nasal involvement, characterizing rhinitis.

The experimental infection of cats with *L. braziliensis* (11), with cutaneous inoculation in the pinnae or through the nasal route, resulted in papules in the skin that progressed with the formation of satellite papules that coalesce to form a large irregular nodule, often with ulcerations. Partial obstruction of the nostrils, with extensive areas of ulceration and regional lymphadenomegaly were also observed. Even though it was an experimental study, with intranasal inoculation, the authors did not report diffuse rhinitis, such as described in this case.

Strongly positive immunohistochemical staining for amastigotes of *Leishmania* sp. observed in this case was similar to previous reports (5, 17). However, although the description of amastigotes in the bone marrow is frequently seen by cytology (17), in this case, amastigotes were only identified in the bone marrow by immunohistochemistry. The qPCR detected *Leishmania* sp. DNA in lymph nodes samples and confirmed the diagnosis of visceral leishmaniasis in cats.

Clinically, cutaneous lesions associated with feline leishmaniasis may resemble other diseases, especially cryptococcosis, sporotrichosis, squamous cell carcinoma, and dermatophytosis. All these conditions may present as nodular areas in the face (5, 16). Therefore, cytological or histopathological examination is essential for a conclusive diagnosis, with the possibility of confirmation by immunohistochemistry, since leishmaniasis becomes a differential diagnosis for nodular lesions, especially in the muzzle.

Acknowledgements

Work in RLS lab is supported by CNPq (Conselho Nacional de Desenvolvimento Científico e Tecnológico, Brazil), FAPEMIG (Fundação de Amparo a Pesquisa do Estado de Minas Gerais, Brazil), and CAPES (Coordenação de Aperfeiçoamento de Pessoal de Nível Superior, Brazil). RLS has a fellowship from CNPq (Brazil).

References

1. Coelho WMD, Lima VM, Amarante AFT, Lagoni H, Pereira VBR, Abdelnour A, Bresciani KDS. Occurrence of *Leishmania (Leishmania) chagasi* in a domestic cat (*Felis catus*) in Andradina, São Paulo, Brazil: case report. *Rev Bras Parasitol Vet.* 2010;19(4):256-8.
2. Diniz SA, Silva FL, Carvalho Neta AV, Bueno R, Guerra RM, Abreu-silva AL, Santos RL. Animal reservoirs for visceral leishmaniasis in densely populated urban areas. *J Infect Dev Ctries.* 2008;2(1):24-33.
3. Maia C, Campino L. Can domestic cats be considered reservoir hosts of zoonotic leishmaniasis? *Trends Parasitol.* 2011;27:341-4.
4. Brasil. Ministério da Saúde. Secretaria de Vigilância em Saúde. Departamento de Vigilância Epidemiológica. Manual de vigilância e controle da leishmaniose visceral / Ministério da Saúde, Secretaria de Vigilância em Saúde, Departamento de Vigilância Epidemiológica. – Brasília: Editora do Ministério da Saúde, 2006. 120 p.: il. color – (Série A. Normas e Manuais Técnicos).
5. Navarro JA, Sanchez J, Peñafiel-Verdú C, Buendía J, Vilafranca M. Histopathological lesions in 15 cats with leishmaniasis. *J Comp Pathol.* 2010;143(4):279-302.
6. Passos VMA, Lasmar EB, Gontijo CMF, Fernandes O, Degraive W. Natural Infection of a Domestic Cat (*Felis domesticus*) with *Leishmania (Viannia)* in the Metropolitan Region of Belo Horizonte, State of Minas Gerais, Brazil. *Mem Inst Oswaldo Cruz.* 1996;91(1):19-20.
7. Queiroz NMGP, Assis J, Oliveira TMFS, Machado RZ, Nunes CM, Starke-buzetti WA. Diagnóstico da Leishmaniose Visceral Canina pelas técnicas de imunoistoquímica e PCR em tecidos cutâneos em associação com a RIFI e ELISA-teste. *Rev Bras Parasitol Vet.* 2010;19:32-8.
8. Savani ESMM, Camargo CGOC, Carvalho MR, Zampieri RA, Santos MG, D'auria N, Shaw JJ, Winter-Floeter LM. The first record in the Americas of an autochthonous case of *Leishmania (Leishmania) infantum chagasi* in a domestic cat (*Felis catus*) from Cotia County, São Paulo State, Brazil. *Vet Parasitol.* 2004;120:229-33.
9. Schubach TMP, Figueiredo FB, Pereira SA, Madeira MF, Santos IB, Andrade MV, Cuzzi T, Marzochi MCA, Schubach A. American cutaneous leishmaniasis in two cats from Rio de Janeiro, Brazil: first report of natural infection with *Leishmania (Viannia) braziliensis*. *Trans R Soc Trop Med Hyg.* 2010;98:165-7.
10. Silva AVM, Cândido CDS, Pereira DP, Peçanha R, Carreira JCA. The first record of American visceral leishmaniasis in domestic cats from Rio de Janeiro, Brazil. *Acta Trop.* 2008;105:92-4.
11. Simões-Mattos L, Mattos MRF, Teixeira MJ, Oliveira-lima JW, Bevilacqua CML, Prata-Junior RC, Holanda CM, Rondon FCM, Bastos KMS, Coelho ZCB, Coelho ICB, Barral A, Pompeu MML. The susceptibility of domestic cats (*Felis catus*) to experimental infection with *Leishmania braziliensis*. *Vet Parasitol.* 2005;127:199-208.
12. Souza AI, Juliano RS, Gomes TS, Diniz SA, Borges AM, Tarufi WL, Santos RL. Osteolytic osteomyelitis

- associated with visceral leishmaniasis in a dog. *Vet Parasitol.* 2005;129:51-4.
13. Souza AI, Barros EMS, Ishikawa E, Olha IMN, Marin GRB, Nunes VLB. Feline leishmaniasis due to *Leishmania (Leishmania) amazonensis* in Mato Grosso do Sul State, Brazil. *Vet Parasitol.* 2005;128:41-5.
 14. Souza AI, Nunes VLB, Borralho VM, Ishikawa EAY. Domestic feline cutaneous leishmaniasis in the municipality of Ribas do Rio Pardo, Mato Grosso do Sul State, Brazil: a case report. *J Venom Anim Toxins Incl Trop Dis.* 2008;15(2):359-65.
 15. Tarufi WL, Santos RL, Arantes RM, Gonçalves R, De Melo MN, Michalick MS, Tarufi WL. An alternative immunohistochemical method for detecting *Leishmania* amastigotes in paraffin-embedded canine tissues. *J Immunol Methods.* 2004;292:17-23.
 16. Trainor KE, Porter BF, Logan KS, Hoffman RJ, Snowden KF. Eight cases of feline cutaneous leishmaniasis in Texas. *Vet Pathol.* 2010;47(6):1076-81.
 17. Vides JP, Schwardt TF, Sobrinho LSV, Marinho M, Laurenti MD, Biondo AW, Leutenegger C, Marcondes M. *Leishmania chagasi* infection in cats with dermatologic lesions from an endemic area of visceral leishmaniasis in Brazil. *Vet Parasitol.* 2011;178:22-8.
 18. Perosso J, Silva KL, Ferreira SÍ, Avanço SV, dos Santos PS, Eugênio F de R, de Almeida BF, de Lima VM Alteration of sFAS and sFAS ligand expression during canine visceral leishmaniasis. *Vet Parasitol.* 2014; 205: 417-23