Braz J Vet Pathol, 2018, 11(1), 12 – 18
DOI: 10.24070/bjvp.1983-0246.v11i1p12-18

BJVP
Brazilian Journal of Veterinary Pathology
ISSN 1983-0246

Case Report

Hemosuccus pancreaticus in a dog: A rare case of gastrointestinal hemorrhage

Ana F. M. Botelho[1], Matheus V. L. Moreira[1], Camila Eckstein[1], Fabrício G. Melo[1], Letícia B. Oliveira[2], Cláudia E. V. Rocha[3], Cibele J. Santos[1], Anelise C. Nepomuceno[1], Natália M. Ocarino[1], Rogéria Serakides[1*]

[1]From the Department of Veterinary Clinic and Surgery, Veterinary Faculty, Universidade Federal de Minas Gerais, 31270-901, Belo Horizonte, Brazil.
*__Corresponding author__: Rogéria Serakides. E-mail: serakidesufmg@gmail.com

Submitted June, 5th 2017, Accepted November, 7th 2017

Abstract

A 9-year-old, 5.5-kg (12.12-lb) spayed female Poodle was evaluated due to recurrent seizures and possible diabetes. The dog also had a history of anorexia, polyuria and polydipsia. Serum biochemistry results revealed increases in pancreatic amylase and glucose associated with decreased protein levels. Abdominal ultrasound suggested acute pancreatitis and/or a pancreatic tumor with intense peripancreatic vascularization. The clinical condition of the dog worsened despite medical treatment, and death occurred shortly thereafter. At necropsy, blood clots were found in the stomach and in the intestinal lumen, which was filled with undigested blood. The pancreas was moderately increased in size with an irregular surface and multifocal yellow firm areas. In the cranial portion of the pancreas, a single nodule, approximately 2 cm in diameter, was found. Histologic evaluation of the pancreas revealed chronic and acute lesions characterized by lymphohistiocytic pancreatitis, periductal fibrosis, degeneration of pancreatic islets and necrotizing and fibrinopurulent pancreatitis. The nodule was diagnosed as pancreatic adenocarcinoma. These clinical, imaging, and histopathologic findings were compatible with *Hemosuccus pancreaticus*. To the authors' knowledge, this is the first report of *Hemosuccus pancreaticus* in a dog and it should be considered as a differential diagnosis for dogs with pancreatic disease and gastrointestinal bleeding.

Key words: dog, *Hemosuccus*, pancreas, pancreatitis.

Introduction

Hemosuccus pancreaticus (HP), also known as *Wirsungorrhaghia* and pseudo hemobilia, is a condition characterized by gastrointestinal hemorrhage from the pancreatic duct (22). It is a rare pathology in humans (7), and it has not been reported in veterinary medicine.

HP can be caused by acute and chronic pancreatitis of primary or secondary origin (2, 16, 22, 25), as well as primary or metastatic neoplasia (13,14,15,), pancreatic duct stones (10), vascular malformations, or splenic or celiac artery aneurysm (6, 33). It has also been described as a clinical complication after pancreatic stent implants (29), abdominal trauma (11), iatrogenic causes (27) and pancreatic panniculitis (9).

Canine pancreatitis is a common and clinical significant disease. The signs vary from gastrointestinal alterations, such as anorexia, vomiting and diarrhea to severe pain and pancreatic failure. The etiology is usually unknown, and diagnosis is challenging due to the low sensitivity of current noninvasive tests available. One of the most important differential diagnoses is pancreatic adenocarcinoma, which is usually malignant, so very rarely may reach a large size before the presentation of metastasizes (31).

Recent reports in humans presented new insights on the diagnosis of this disease and further characterized

Braz J Vet Pathol, 2018, 11(1), 12 – 18
DOI: 10.24070/bjvp.1983-0246.v11i1p12-18

its pathophysiology (4, 7, 9). This case report provides a detailed description of the clinical, imaging and histological characteristics of *Hemosuccus pancreaticus* in a dog.

Case description

A 9-year-old, 5.5-kg (12.12-lb) spayed female Poodle was initially evaluated by a veterinary clinic specialist for recurrent seizures, anorexia, polyuria, polydipsia and a suspicion of *Diabetes mellitus*. Phenobarbital was prescribed 4 months prior to the clinical appointment, and the dose was adjusted (6 mg/kg [2.47 mg/lb], PO, q 12 h) with significant improvement of the seizures. Physical examination revealed that the animal walked in circles, had decreased consciousness, increased vocalization, reduced proprioception and hemistand and hemiwalk reflex in all limbs, associated with a decrease in the left eyelid reflex and bilateral menace response test.

Serum phenobarbital was evaluated to ensure proper dosage using electrochemiluminescence (Immulite 2000, Siemens Healthcare Diagnostic), and the level found (24.85 mcg/mL) was within the reference values for dogs undergoing this type of treatment (15-40 mcg/mL). In an attempt to minimize the symptoms, prednisone was prescribed at 2 mg/kg, twice a day for 11 days, followed by a gradual reduction.

Sequential blood counts were conducted and revealed a normocytic normochromic progressive anemia with a leucocyte increase (Table 1). Serum biochemical examination indicated an increase in aspartate aminotransferase, alkaline phosphatase, gamma-glutamyl transferase, amylase and glucose; there were low amounts of total protein, albumin, and globulins (Table 2). Cerebrospinal fluid was collected for differential diagnosis and showed an increase in total protein (24.26 g/dL) when compared to normal range values 13.97-4.54 g/dL [1] and lower glucose levels (24.95 mg/dL) when compared to serum concentration.

At the abdominal ultrasound examination, the right pancreatic lobe showed a hypoechoic tortuous track with an irregular contour, and it extended beyond its normal topography. A hypoechoic round structure, which was approximately 0.83 cm in size, was observed adjacent to the pancreas. A peripancreatic area of tissue reactivity with increased echogenicity was also observed (Fig. 1A). Color Doppler indicated intense vascularization of the pancreas and peripancreatic region (Fig. 1B). Based on these findings, the probable diagnoses were pancreatitis and/or a pancreatic tumor associated with peripancreatic reactivity.

Shortly after the ultrasound exam, the dog developed ascites, and a cytological examination of the peritoneal liquid revealed a chronic inflammatory process with dysplastic cells. No definite diagnosis was obtained, but the presence of malignant neoplasia could not be discarded. On the following day, the animal died, and a necropsy exam was performed.

Table 1. Sequential hematological exams of a dog with *Hemosuccus pancreaticus*.

Blood counts	1st day	2nd day	3rd day	Reference values
RBC	5.01	3.49	1.43	5.5-8.5 millions/mm^3
HB	12.7	8.3	3.64	12-18 g%
HCT	33	25	10	37-55 %
MCV	65.87	71.63	69.93	60-77 fL
MCHC	38.48	33.2	36.4	31-36 %
MCH	25.35	23.78	25.45	19-24.5 pg
RDW	13.0	12.8	11.7	12-15 %
WBC	29500	23900	23500	6000-17000/mm^3
GRAN	25665	19956.5	21385	3000-11500/mm^3
LYMPH	885	956	940	1000-4800/mm^3
MONO	2.950	21.51	940	150-1250/mm^3
PLT	237000	248000	147000	175000-500000/mm³

RBC: red blood cells; Hb: hemoglobin; Hct: hematocrit; MCV: mean corpuscular volume; MCHC: mean corpuscular hemoglobin concentration; MCH: mean corpuscular hemoglobin; RDW: red cell distribution with; WBC: white blood cell count; GRAN: granulocyte count; LYMPH: lymphocyte count; MONO: mononuclear cell count; PLT: platelet count.

Braz J Vet Pathol, 2018, 11(1), 12 – 18
DOI: 10.24070/bjvp.1983-0246.v11i1p12-18

Macroscopic evaluation of the mucosa (oral, ocular and vulvar) showed an intense pale color and discrete bloody secretion in the perianal region. Translucent liquid was found in the thoracic cavity (10 mL) (hydrothorax) and abdominal cavity (60 mL) (hydroperitoneum), associated with a fibrillar material covering the greater omentum, pancreas and intestines.

Table 2. Sequential serum biochemistry examinations of a dog with *Hemosuccus pancreaticus*.

Serum biochemistry	1st day	2nd day	3rd day	Reference values
Creatinine	*	0.36	0.55	0.5-1.5 mg/dL
Urea	36.17	51.69	56.16	20-56 mg/dL
AST	67.28	133	721.20	0-100 U/L
AF	550.35	526.43	557.16	20-156 U/L
GGT	33.88	37.06	87.32	0-25 U/L
Amylase	-	2835	1707.75	500-1500 U/L
Glucose	241.7	252.25	229.45	76-119 mg/dL
Total protein	4.21	3.28	3.57	5.4-7.5 g/dL
Albumin	2.68	1.57	1.09	2.3-3.1 g/dL
Globulin	1.53	1.58	2.48	2.7-4.4 g/dL

*Insufficient sample to perform exam. (-) Exam not performed. AST- aspartate aminotransferase, FA- alkaline phosphatase, GGT- gamma-glutamyl transferase.

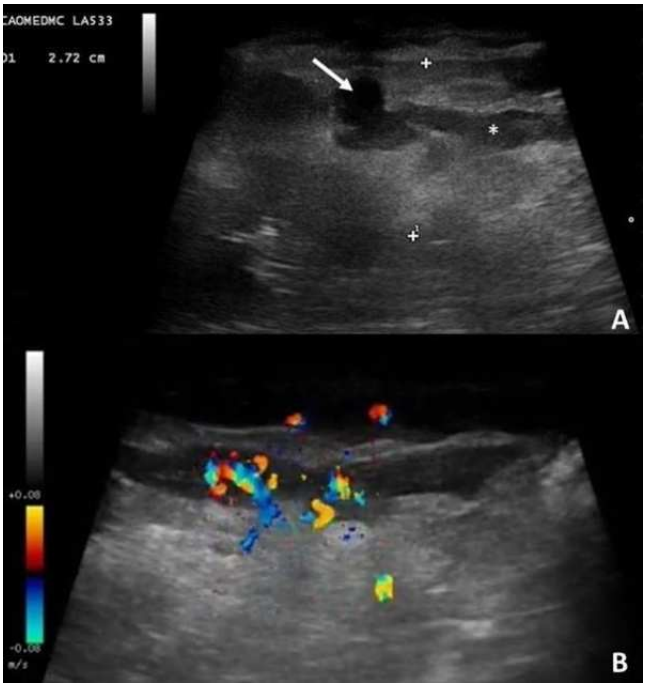

Figure 1. Abdominal ultrasound of a dog with *Hemosuccus pancreaticus*. **A.** Hypoechoic and irregular right pancreatic lobe (*); round hypoechoic structure (arrow) adjacent to the pancreas and peripancreatic tissue reaction (between the cursors). **B.** Color Doppler showing intense vascularization of the peripancreatic region (Ultrasound Esatoe MyLab 40).

The pancreas was moderately increased in volume with an irregular surface and multiple yellow and firm areas (Fig. 2A). In the cranial portion of the pancreas, a single nodule, approximately 2 cm in diameter, was found with a smooth surface and firm consistency. The cut surface was solid and comprised of white areas interspersed with red areas (Fig. 2B). Blood clots were observed in the stomach (Fig. 2C). The intestinal lumen was filled with undigested blood (hematochezia) (Fig. 2D). Complementary gross lesions were seen in the liver, which was a diffuse pale red color with a lobular pattern; similar lesions were observed in the kidneys, which were also a diffuse pale red.

Microscopic examination of the pancreas revealed two lesion patterns, chronic and acute. Chronic lesions were characterized by moderate multifocal lymphocytic and histiocytic pancreatitis, periductal fibrosis and degeneration of pancreatic islets. Acute lesions included multifocal to coalescent necrotizing areas with intense neutrophilic and fibrinous infiltration (fibrinopurulent pancreatitis) (Fig. 3A). The lumens of the pancreatic interlobular ducts were filled with erythrocytes (Fig. 3B). The pancreatic nodule showed a poorly defined neoplastic proliferation of epithelial cells, no encapsulation, and infiltration with a cords and acinar pattern, some of which were filled with erythrocytes that replaced the parenchyma (Fig. 3C). Cells ranged from cubic to pyramidal, juxtaposed, with imprecise cytoplasmic boundaries and an eosinophilic cytoplasm. Nuclei were oval and basal, with loose chromatin and 1-2 nucleoli. Anisocytosis and

Braz J Vet Pathol, 2018, 11(1), 12 – 18
DOI: 10.24070/bjvp.1983-0246.v11i1p12-18

anisokaryosis were moderate, and four mitotic figures were observed in 10 sequential high-power fields without overlapping (40x). In the intestine, erythrocytes filled the entire lumen (Fig. 3D).

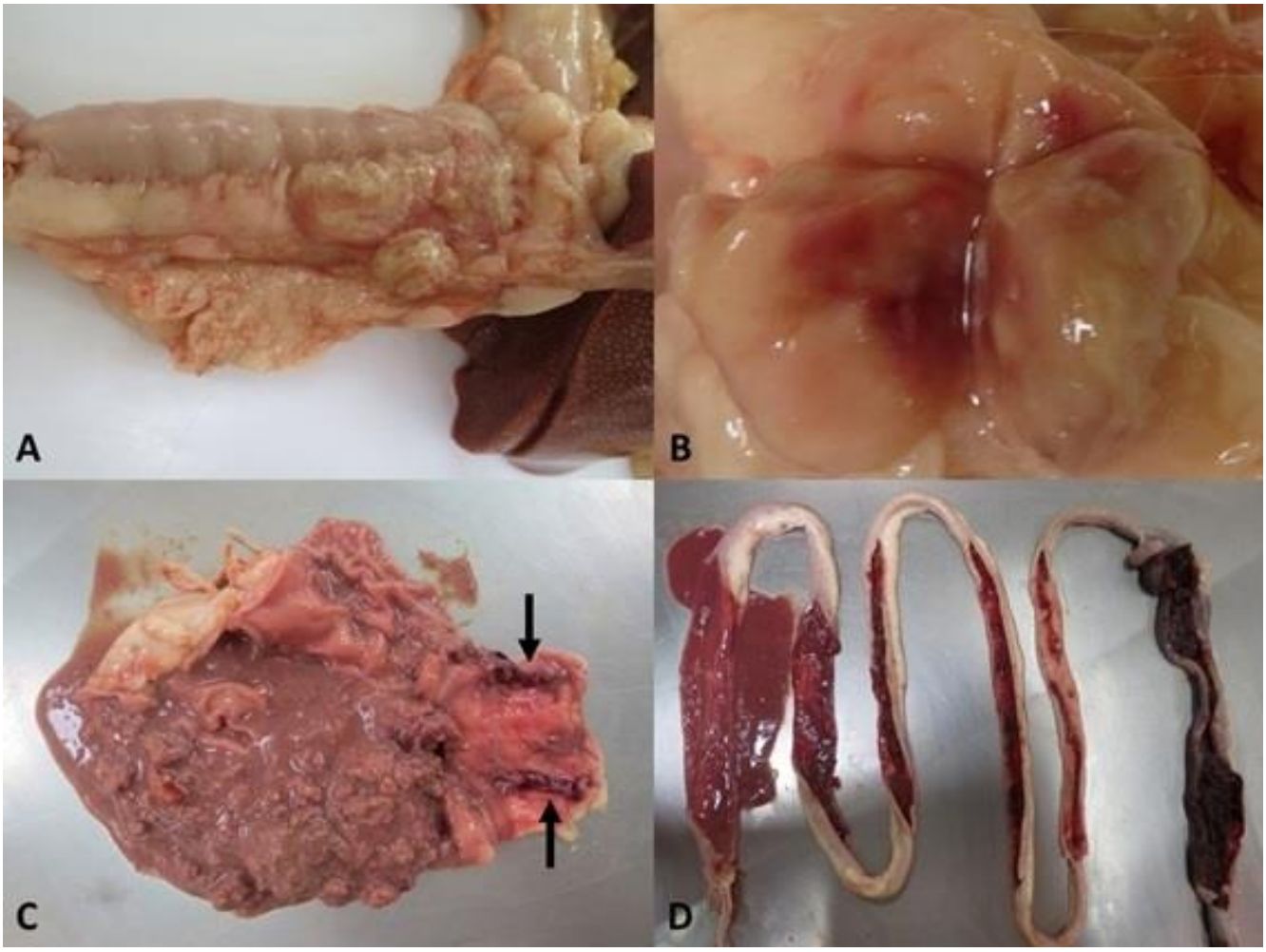

Figure 2. Gross lesions of a dog with *Hemosuccus pancreaticus*. **A.** The pancreas has a moderate increase in volume, with an irregular surface and multiple yellowed areas. **B.** Cut surface of a single pancreatic nodule, solid with white and red areas. **C.** Stomach lumen filled with red content and clots (arrows). **D.** Intestines with blood occupying the entire lumen.

Discussion

The clinical findings in the dog, characterized by anorexia, polyuria, polydipsia, a normocytic normochromic progressive anemia, hyperglycemia and hyperamylasemia are usually found in patients with pancreatic disorders. However, the association between these findings and hematochezia strongly suggests a diagnosis of *Hemosuccus pancreaticus* (HP). HP was confirmed in association with the pancreatitis and pancreatic adenocarcinoma. The absence of any lesions in the stomach and/or intestine and the observation of erythrocytes in the lumen of both the pancreatic ducts and neoplastic acini signaled the pancreatic origin of the hemorrhage found in the intestinal lumen.

Pancreatitis in dogs is usually idiopathic, but certain risk factors, such as a hypercaloric diet, hypothyroidism, Diabetes mellitus, pancreatic ischemia, prolonged corticosteroid therapy, hyperadrenocorticism, trauma, pancreatic tumors and obstruction of the pancreatic duct, need to be considered (31). Aside from pancreatic neoplasia, the dog in the present report had clinical symptoms of Diabetes mellitus, with persistent hyperglycemia, polyuria, polydipsia and a positive response to insulin therapy; these symptoms were associated with the degeneration of the pancreatic islets and periductal fibrosis. Due to the instability of the patient, a blood glucose curve test and evaluation of glucose levels in the urine were not performed. However, this was not necessary to confirm the diagnosis of Diabetes mellitus nor was it necessary for the treatment or prognosis of the animal (19).

Chronic pancreatitis could be associated with the diabetes. Pancreatic necrosis is a consequence of the release of pancreatic enzymes that promote parenchyma digestion with intense inflammation and erosion of

Braz J Vet Pathol, 2018, 11(1), 12 – 18
DOI: 10.24070/bjvp.1983-0246.v11i1p12-18

adjacent blood vessels. The outcome of pancreatic necrosis is the likely development of pseudoaneurysms and vessel rupture, causing hemorrhage through the pancreatic duct extending into the intestines through the sphincter of Oddi or the greater duodenal papilla sphincter (7, 22, 26). The blood found in the stomach is probably a consequence of a retrograde flux from the pancreatic duct and intestinal lumen. Gastrointestinal hemorrhage found in HP cases are generally intense, recurrent and intermittent (27), as was found in the present report. Blood flow through the pancreatic duct can clot and obstruct the ductal lumen, temporarily stopping the hemorrhage (7, 22). The dog in this case had an intense acute anemia that could have been associated with the blood loss from the pancreas, although hematochezia was only observed on the day of the animal's death.

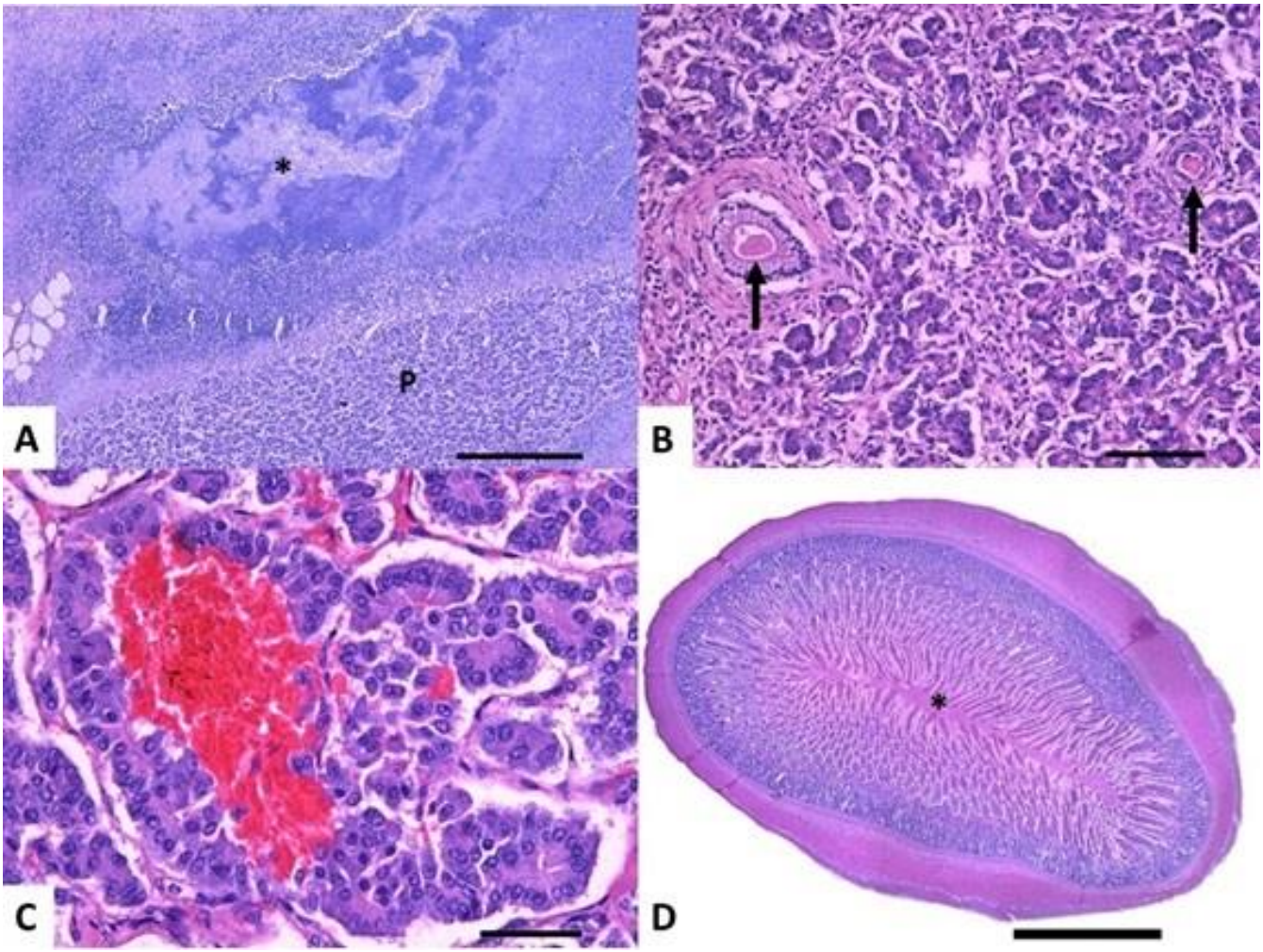

Figure 3. Microscopy of a dog with *Hemosuccus pancreaticus*. **A.** Pancreas with extensive focal acute necrosis (*) and a normal area of the exocrine organ (P) (H&E stain, bar = 500 µm). **B.** Lumen of the pancreatic ducts filled with erythrocytes (arrows) (H&E stain, bar = 100 µm). **C.** Pancreatic adenocarcinoma with erythrocytes in the lumen of neoformed acini (H&E stain, bar = 50 µm). **D.** Small intestine with the lumen filled with erythrocytes (*) (H&E stain, bar = 2 mm).

Other causes of gastrointestinal hemorrhage that were not observed in the present report include hemobilia (16), angiodysplasia (5), hypoadrenocisticism (18), hemostasis disorders (17, 21, 29), intestinal neoplasia (32), foreign bodies (8), gastrointestinal ulcers (28), and gastroenteritis caused by viruses (3) and bacteria (23). These etiologies should be considered as differential diagnoses for HP.

HP is a rare condition with a difficult diagnosis and intermittent clinical signs frequently associated with pancreatitis. Patients with a history of chronic pancreatitis, pancreatic tumors and vascular disorders usually present with hyperamylasemia and recurrent epigastric pain, followed by digestive bleeding such as hematemesis and/or hematochezia (6, 7, 13, 20, 22). Hematochezia, observed in this report, is one of the most common clinical alterations caused by pancreatic hemorrhage through the pancreatic duct, which is not associated with intestinal bleeding (7).

Currently there are a variety of diagnostic techniques that could be used to confirm HP, such as endoscopy, angiography (25), ultrasound (29), computerized tomography and magnetic resonance

imaging (12). In the present report, only ultrasound was performed; the histological findings and the images provided by the ultrasound revealed chronic and acute pancreatic lesions, neoplasia and intense peripancreatic vascularization, all of which were examined with the aid of the color Doppler, were related to HP.

Both the ultrasound images and histological findings revealed inflammatory and neoplasic pancreatic lesions that contributed to the development of HP. The observation of erythrocytes in the lumen of pancreatic ducts, the neoplastic acini, and the absence of lesions in the stomach and intestines confirmed the pancreatic origin of the bleeding.

The peripancreatic vascularization is physiological, formed by the ramifications of the celiac, splenic and pancreatic arteries. The increase in vascularization, as observed by the color Doppler on the ultrasound exam, suggested a tissue reaction. However, pancreatic enzymes could cause vascular necrosis and subsequent hemorrhage through the pancreas into the small intestine, causing HP (13).

Other alterations, such as hydrothorax and hydroperitoneum, could be related to the decrease in total protein levels, which is an ordinary finding in patients with chronic and debilitating diseases. The diabetes observed in the present case was confirmed by the recurrent hyperglycemia, clinical signs and histological findings, which included the lymphocytic and histiocytic pancreatitis, periductal fibrosis and degeneration of the pancreatic islets. No gross or histology lesions were found in the central nervous system, although the cerebrospinal fluid previously collected had lower levels of glucose, probably due to the diabetes and was likely the cause of the neurological symptoms.

HP treatment includes surgical and endovascular procedures (30) that could not be performed in this animal. In the present case, the absence of hematochezia in the days prior to the animal's death and the rarity of the disorder hindered the clinical diagnosis of HP. The definitive diagnosis was only established after the necropsy evaluation.

A number of factors allowed the diagnosis of *Hemosuccus pancreaticus*: the absence of stomach and intestinal lesions; the clinical findings associated with pancreatitis and pancreatic adenocarcinoma; and the observation of erythrocytes in the lumen of the pancreatic ducts, from normal and neoplasic areas. To the authors' knowledge, this is the first report of HP in veterinary medicine.

Acknowledgements

This work was supported by *Pro-Reitoria de Pesquisa of the Universidade Federal de Minas Gerais (PRPq-UFMG) - Brasil*.

References

1. Bailey CS, Higgins RJ. Comparison of total white blood cell count and total protein content of lumbar and cisternal cerebrospinal fluid of healthy dogs. Am J Vet Res. 1985;46:1162-5.
2. Belo AC, Grabowki EW. Zhang C, Longworth DL, Desilets DJ. Case of chronic pancreatic brucellosis presenting as *hemosuccus pancreaticus*. JOP. 2007;8:429-32.
3. Castro TX, Cubel Garcia RC, Gonçalves LP, Costa EM, Marecllo GC, Labarthe NV, Mendes-de-Almeida F. Clinical, hematological, and biochemical findings in puppies with coronavirus and parvovirus enteritis. Can Vet J. 2013;54:885-8.
4. Cerrato DR, Beteck B, Sardana N, Farooqui S, Allen D, Cunningham SC. *Hemosuccus pancreaticus* due to a noninflammatory pancreatic pseudotumor. JOP. 2014;15:501-3.
5. Fan TM, Simpson KW, Polack E, Dykes N, Harvey J. Intestinal haemorrhage associated with colonic vascular ectasia (angiodysplasia) in a dog. J Small Anim Pract. 1999;40:25-30.
6. Fazel I, Asle SoleimaniI H, Fallah S, Babaei M, Sedighi N, Marashi A, Beniaz F, Malekzadeh R. Hemosuccus pancreaticus in a patient with celiac trunk aneurysm. Arch Iran Med. 2008;11:658-61.
7. Han B, Song ZF, Sun B. *Hemosuccus pancreaticus*: a rare cause of gastrointestinal bleeding. Hepatobiliary. Pancreat Dis Int. 2012;11:479-88.
8. Hayes L. Gastrointestinal foreign bodies in dogs and cats: a retrospective study of 208 cases. J Small Anim Pract. 2009;50:576- 83.
9. Holt BA, Hawes R, Varadarajulu S. *Hemosuccus Pancreaticus* caused by superior mesenteric artery fistula presenting as pancreatic panniculitis and anemia. Clin Gastroenterol Hepatol. 2014;12:97-8.
10. Jakobs R, Riemann JF. *Hemosuccus pancreaticus* due to a pressure ulcer in pancreatolithiasis. Dtsch Med Wochenschr. 1992;117:1956-61.
11. Kim SS, Robert RR, Nagy KK, Joseph K, Bokhari F, An G, Barret J. *Hemosuccus pancreaticus* after penetrating trauma to the abdomen. J Trauma. 2000;49:948-50.
12. Koizumi J, Inoue S, Yonekawa H, Kunieda T. *Hemosuccus pancreaticus*: diagnosis with CT and MRI and treatment with transcatheter embolization. Abdom Imaging. 2002;27:77-81.
13. Kothari RA, Leelakrishnan V, Krishnan M. *Hemosuccus pancreaticus*: a rare case of gastrointestinal bleeding. Ann Gastroenterol. 2013;26:175-7.
14. Kurland J, Matthews T, Hoff E, Gentry A, Cash B. *Hemosuccus pancreaticus* caused by metastatic renal cell carcinoma. Gastrointest Endosc. 2007;66:1241-2.
15. Kuruma S, Kamisawa T, Tu Y, Egawa N, Tsuruta K, Toonoka A, Funata N. *Hemosuccus pancreaticus* due

to intraductal papillary-mucinous carcinoma of the pancreas. Clin J Gastroenterol. 2009;2:27-9.
16. Lippo NJ, Williams JE, Brawer RS, Sobel KE. Acute hemobilia and hemocholecyst in 2 dogs with gallbladder carcinoid. J Vet Intern Med. 2008;22:1249-52.
17. Londoño LA, Specht AJ, Vanderhart DJ, Bandt C. What Is Your Diagnosis? Gastric wall hemorrhage secondary to anticoagulant rodenticide intoxication. J Am Vet Med Assoc. 2015;247:243-5.
18. Medinger TL, Williams DA, Bruyette DS. Severe gastrointestinal tract hemorrhage in three dogs with hypoadrenocorticism. J Am Vet Med Assoc. 1993;202:1869-72.
19. Nichols R. Recognizing and treating canine and feline diabetes mellitus. Vet Med. 1992;87:211-22.
20. Okamoto H, Miura K, Fujii H. *Hemosuccus pancreaticus* following a puestow procedure in a patient with chronic pancreatitis. Case Rep Gastroenterol. 2011;5:452-6.
21. Otto CM, Dodds WJ, Greene CE. Factor XII and partial prekallikrein deficiencies in a dog with recurrent gastrointestinal hemorrhage. J Am Vet Med Assoc. 1991;198:129-31.
22. Sandblom P. Gastrointestinal hemorrhage through the pancreatic duct. Ann Surg. 1970;171:61-6.
23. Schlegel BJ, Van Dreumel T, Slavic D, Prescott JF. Clostridium perfringens type A fatal acute hemorrhagic gastroenteritis in a dog. Can Vet J. 2012;53:555-7.
24. Seicean A, Stan-Iuga R. Munteanu D. An unusual cause of *hemosuccus pancreaticus* diagnosed by endoscopic ultrasonography: splenic arterial fistula due to a pancreatic stent (with video). Endoscopy. 2010;42:239-40.
25. Setoyama T, Miyamoto S, Fukuda K. *Hemosuccus pancreaticus* diagnosed with concurrent endoscopy retrograde pancreatography and selective angiography. Clin Gastroenterol Hepatol. 2012;10:28.
26. Shah S, Barkin JS. *Hemosuccus pancreaticus*: a new mechanism. Pancreas. 2011;40:317-18.
27. Singh P, Gelrud A, Schmulewitz N. Chauhan S. *Hemosuccus pancreaticus* after EUS-FNA of pancreatic cyst (with video). Gastrointest Endos. 2008;67:543.
28. Stanton ME, Bright RM. Gastroduodenal ulceration in dogs. Retrospective study of 43 cases and literature review. J Vet Intern Med. 1989;3:238-44.
29. Stokol T, Parry BW, Mansell PD. Von Willebrand's disease in Dobermann dogs in Australia. Aust Vet J. 1995;72:257-62.
30. Suter M, Doens F, Chapuis G, Gillet M, Sandblom P. Haemorrhage into pancreatic duct (*Hemosuccus pancreaticus*): recognition and management. Eur J Surg. 1995;161:887-92.
31. Watson MA. Chronic pancreatitis in dogs. Top Companion Anim Med. 2012;27:133-9.
32. Willard MD. Alimentary neoplasia in geriatric dogs and cats. Vet Clin North Am Small Anim Pract. 2012;42:693-706.
33. Williams DM, Shetzline MA, Guarisco SA, Branch MS. Presumed arteriovenous malformation mimicking *hemosuccus pancreaticus* of Santorini's duct with normal pancreatic anatomy. Gastrointest Endosc. 1996;44:348-50.