Braz J Vet Pathol, 2018, 11(1), 24 – 27
DOI: 10.24070/bjvp.1983-0246.v11i1p24-27

BJVP
Brazilian Journal of Veterinary Pathology
ISSN 1983-0246

Case report

Melanoma of unknown primary origin metastasizing to visceral organs in a sheep

Ahmad Oryan[1], Mohsen Ghane[2*], Nasrollah Ahmadi[1], Yahya Daneshbod[3]

[1]Department of Pathology, School of Veterinary Medicine, Shiraz University, Shiraz, Iran.
[2]Department of Clinical Sciences, School of Veterinary Medicine, Shiraz University, Shiraz, Iran.
[3]Department of Pathology, Daneshbod Pathology Laboratory, Shiraz, Iran.
*__Corresponding author__: ghane@shirazu.ac.ir.

Submitted August, 13th 2017, Accepted February 27th 2018

Abstract

Malignant melanomas are quite uncommon in sheep and goats. A three-year-old native female sheep with a history of sudden death was referred for postmortem examination. Gross evaluations revealed multiple brown to black neoplastic masses with compact nodular appearance, involving lungs, mediastinal lymph nodes, liver and kidneys. Comprehensive physical examination of skin, all mucous membranes and mucocutaneous junctions revealed no evidence of concomitant pigmented lesions or dark discoloration. Microscopically, the masses were predominantly composed of round and polyhedral-shaped neoplastic cells of various sizes with abundant pale eosinophilic cytoplasm containing variable amounts of dark brown melanin pigment and peripherally located, oval to round, vesicular nuclei with prominent nucleoli. Immunohistochemically, the neoplastic cells displayed diffuse and positive expression for S100 protein, vimentin and melan-A. These histopathological and immunohistochemical findings were consistent with a final diagnosis of metastatic malignant melanoma, "epithelioid" type. To the author' knowledge, metastatic melanoma without an identified primary origin has not yet been reported in the domestic animals.

Key words: sheep, malignant melanoma, visceral organs, histopathology, immunohistochemistry, melan A.

Introduction

Melanomas are usually originated from neuroectodermal melanoblasts or epidermal melanocytes of domestic animals and many wildlife species (9). Melanocytic neoplasms have been commonly reported in most species especially dogs, horses and some breeds of swine (4). In sheep and goats, the pigmented melanocytic tumors are quite uncommon (10, 12). Although more than 90% of the melanocytic neoplasms usually originate from the skin, these tumors may occur metastatically in other sites without an identified primary lesion (7, 8). Such tumors are designated "melanomas of unknown primary origin" (MUP) (18). The present paper describes histopathological and immunohistochemical features of a malignant melanoma metastasized to the visceral organs of a 3-year-old sheep without an identifiable primary site.

Case report

A three-year-old Persian Karakul ewe with a history of sudden death was referred for postmortem examination. According to the owner, there was no known history of any cutaneous lesions from at least one year ago. Gross evaluations revealed multiple brown to black colored neoplastic masses with compact nodular appearance, 2×2×2 cm in diameter, involving lungs and mediastinal lymph nodes, liver and kidneys (Fig. 1A and B). The neoplastic masses were localized and showed firm attachments with regular borders in these organs or tissues. No marked macroscopic lesions in other organs or lymph nodes were observed. Comprehensive physical examination of skin, all mucous membranes and mucocutaneous junctions revealed no evidence of concomitant pigmented lesions or dark discoloration.

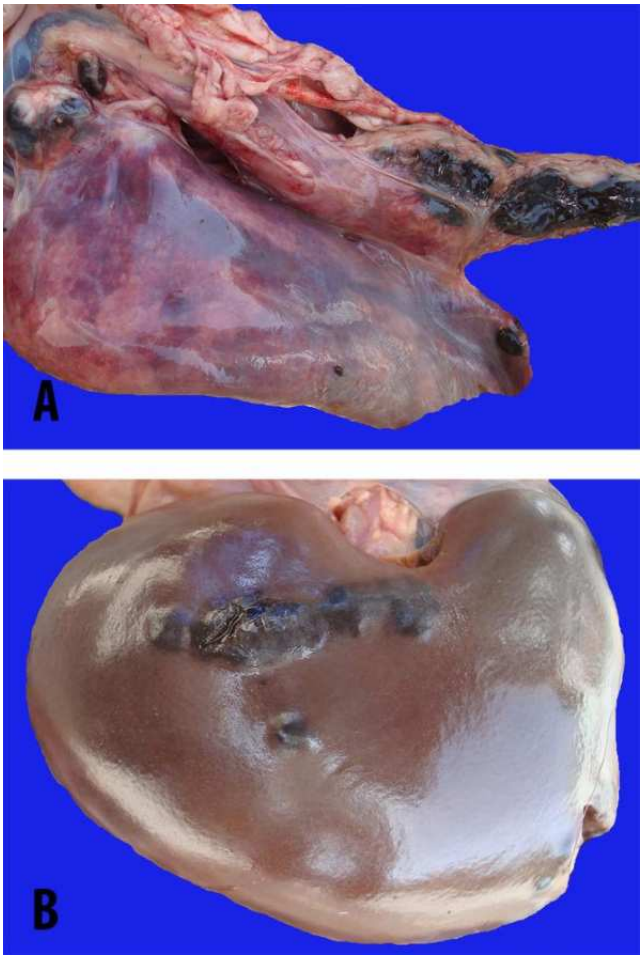

Figure 1. A. Lungs and mediastinal lymph nodes and **B.** Kidney showing multiple brown to black neoplastic masses of metastatic malignant melanoma in a 3-year-old sheep.

Representative specimens from the suspected neoplastic tissues including lungs, liver and kidneys were fixed in 10% neutral buffered formalin, routinely dehydrated, embedded in paraffin, sectioned in 5 µm thickness, stained with hematoxylin and eosin (H&E) and studied in a routine light microscope (Olympus, Japan) for histopathological assessments. In order to further characterize the neoplastic masses, immunohistochemistry (IHC) was performed on the paraffin embedded tissue sections (5 µm), using bond polymer refine detection system (Leica Biosystems, Newcastle, UK), by application of ready-to-use primary monoclonal antibodies specific for the melanocytic marker, melan A (clone no A103), S100 protein (clone no S1/61/69) and the mesoderm-derived tissue marker vimentin (clone no V9). All antibodies were provided from Novocastra Laboratories, Newcastle, UK. 3-3'diaminobenzidine (DAB) and Harris hematoxylin were used as the chromogen and the counterstaining materials, respectively. For negative controls, the primary antibodies were replaced by the non-immune serum. Appropriate internal and external positive control tissues such as blood vessels and normal skin (cutaneous Langerhans cells and melanocytes) were also used for expression of vimentin, S100 protein and melan A, respectively.

Microscopically, the masses were predominantly composed of round and polyhedral-shaped neoplastic cells of various sizes with abundant pale eosinophilic cytoplasm containing variable amounts of dark brown melanin pigment and peripherally located, oval to round, vesicular nuclei with prominent nucleoli. Cellular atypia and variation in nuclear size were mild to moderate with a mitotic index between 2-3 mitoses per 10 high power fields (hpf) (Fig. 2A and B). Focal necrosis, hemorrhage and to some extent inflammatory cells such as lymphocytes were also observed within or at periphery of the proliferative region of neoplastic cells. Immunohistochemically, the neoplastic cells displayed diffuse and positive expression for S100 protein, vimentin and melan A (Fig. 3A and B). These histopathological and immunohistochemical findings were consistent with a final diagnosis of metastatic malignant melanoma, “epithelioid” type.

Discussion

Although most melanocytic neoplasms are mainly originated from skin melanocytes, they also occur in the mucosal membrane of oral cavity and the ocular structures as primary tumor (2, 6). Melanocytes and/or epithelial pigmented cells have also been found in the inner ear, nervous system, heart and adipose tissues of human body (3). On the other hand, primary melanocytic tumors of the non-integumentary organs such as regional lymph nodes, lungs, liver and kidneys have not been previously described. For these reasons and also based on the histomorphological and immunohistochemical findings, the present case was finally diagnosed as metastatic malignant melanoma.

In the present work, we report an unusual case of metastatic malignant melanoma without identification of a primary tumor in a sheep. The entity of melanomas of unknown primary (MUP) origin and their criteria has been characterized and described in human beings (7, 8, 18). In man, different theories, such as the spontaneous regression of the pre-existing nevus as the primary site because of involvement of immunological mechanisms have been proposed to explain the phenomenon of MUP origin (7, 13, 20). Since domestic animals and men are exposed to the same environmental factors and also because of having similar immunopathophysiological mechanisms, we believe that the entity of MUP origin can be acceptable for the present ovine malignant melanoma (OMM).

DOI: 10.24070/bjvp.1983-0246.v11i1p24-27

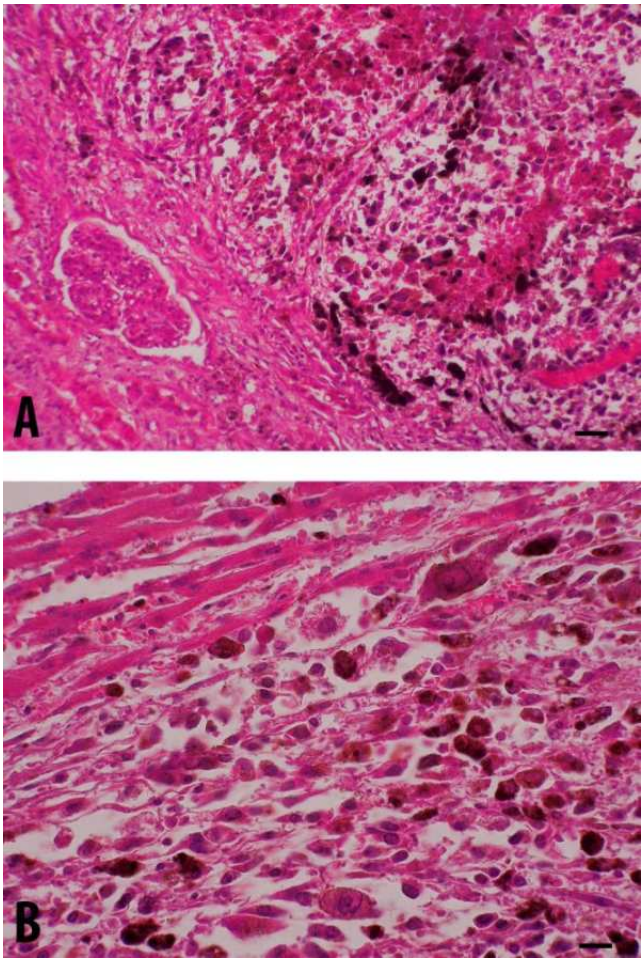

Figure 2. Malignant melanoma metastasized to **A.** kidney and **B.** liver; composed of markedly pleomorphic neoplastic cells with pale eosinophilic cytoplasm containing variable size of oval to round nuclei, prominent nucleoli and variable amounts of melanin pigment. HE. Bar: 55 µm (A) and 15 µm (B).

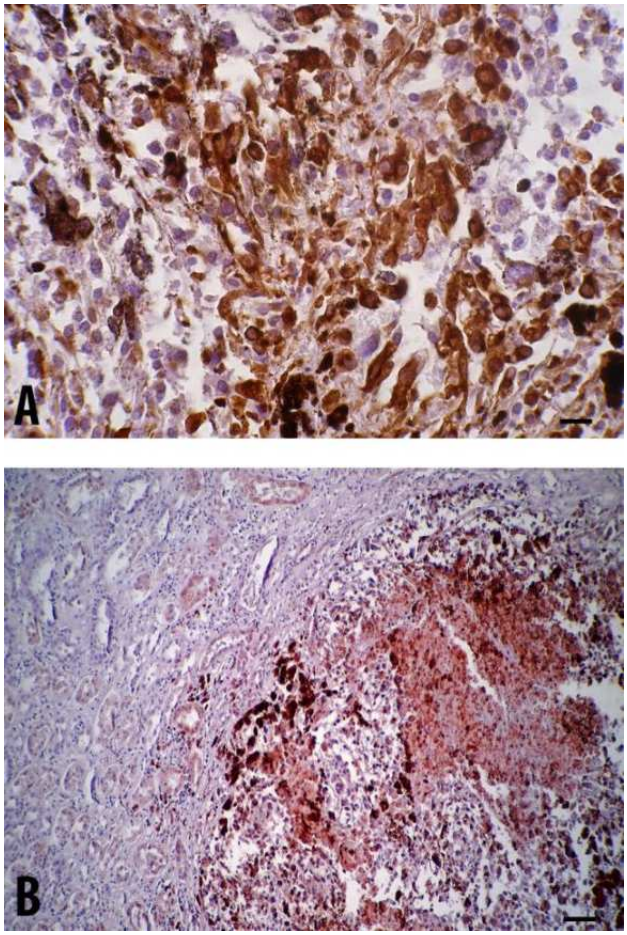

Figure 3. Metastatic malignant melanoma showing of diffuse immunopositivity of **A.** vimentin and **B.** melan A expression. IHC. Bar: 15 µm (A) and 55 µm (B).

In human and domestic animals, a combination of environmental and genetic factors may result in melanocytic neoplasms. The most important and the best-known etiology involved in development of cutaneous melanocytic tumors is prolonged and continuous exposure to ultraviolet radiation (UVR) and a relationship between the sunlight and skin cancer has been established in several domestic species (1, 16, 19). The UV-induced DNA damage of the epidermal melanocytes leads to inhibition of the tumor suppressor genes of the cell cycle and inactivation of apoptosis (5, 15). Because of economic significance and slaughtering of sheep and goats at early ages for meat production, the incidence of these tumors and molecular mechanisms of their initiation, progression and metastasis is inadequately documented.

Immunohistochemistry procedures with high sensitivity and specific immunomarkers has greatly aided in diagnosis of malignant melanoma especially amelanotic type and can lead to achieve a definitive prognosis, to predict the biological behavior and survival time and to differentiate benign from malignant melanocytic neoplasms (9, 15). Melan A is highly sensitive and 100% specific for the diagnosis of amelanotic melanocytic neoplasms in dogs (14). S100 protein and anti-vimentin antibodies are sensitive for tumors of melanocytic origin, but their specificity is low and may react with many other tumors (9, 11, 17).

In conclusion, to the best of our knowledge, this is the first report of a metastatic melanoma without an identified primary origin in domestic animals. There is paucity of published information or data about malignancy of melanocytic neoplasms, their site or breed predilection, biological behavior and clinical prognosis in small ruminant in comparison with other domestic animals such as dogs, cats and horses. The present report shows that OMM with developing metastasis can be a life-threatening disease and have a poor prognosis. Furthermore, no well-defined histopathological standards or systems have been

described to classify the melanocytic tumors and/or assess and describe their complete clinical outcomes in small ruminants and such shortages need to be further investigated.

Acknowledgements

The authors are grateful to Mrs. S. Jowkar and Mr. M. Zare from the Department of Pathology, School of Veterinary Medicine, Shiraz University, all personals from the Daneshbod Pathology Laboratory, Shiraz, Iran and Mr. M. Zendehboudi for their technical assistance.

References

1. Ahmed AF, Hassanein KMA. Ovine and caprine cutaneous and ocular neoplasms. Small Rumin Res. 2012;106:189-200.
2. Canpolat I, Yaman I, Gunay C. A case of primary intraocular malignant iris melanoma in an Akkaraman sheep. Rev Méd Vét. 2007;158:171-3.
3. Cichorek M, Wachulska M, Stasiewicz A, Tymińska A. Skin melanocytes: biology and development. Postepy Dermatol Alergol. 2013;30:30-41.
4. Goldschmidt MH, Goldschmidt KH. Epithelial and melanocytic tumors of the skin. In: Meuten DJ, editor. Tumors of Domestic Animals. 5th ed. New Jersey: John Wiley & Sons, Inc; 2017. p. 88-175.
5. Green A, Neale R, Kelly R, Smith I, Ablett E, Meyers B., Parsons P. An animal model for human melanoma. Photochem Photobiol. 1996;64:577-80.
6. Hamor RE, Severin GA, Roberts SM. Intraocular melanoma in an alpaca. Vet Ophthalmol. 1999;2:193-6.
7. Kamposioras K, Pentheroudakis G, Pectasides D, Pavlidis N. Malignant melanoma of unknown primary site. To make the long story short. A systematic review of the literature. Crit Rev Oncol Hematol. 2011;78:112-26.
8. Katz KA, Jonasch E, Hodi FS, Soiffer R, Kwitkiwski K, Sober AJ, Haluska FG. Melanoma of unknown primary: experience at Massachusetts General Hospital and Dana-Farber Cancer Institute. Melanoma Res. 2005;15:77-82.
9. Mauldin EA, Peters-Kennedy J. Integumentary system. In: Maxie MG, editor. Jubb, Kennedy, and Palmer's pathology of domestic animals. 6th ed. Saint Louis: Elsevier, Inc; 2016. 720 p.
10. Mignacca SA, Capucchio MT, Biasibetti E, Guarneri G, Milone S, Marchisotta A, Amato B, Di Marco Lo Presti V. Three cases of melanoma in small ruminants: clinical symptoms and pathological results. Small Rumin Res. 2015;126:25-7.
11. Ramos-Vara JA, Beissenherz ME, Miller MA, Johnson GC, Pace LW, Fard A, Kottler SJ. Retrospective study of 338 canine oral melanomas with clinical, histologic, and immunohistochemical review of 129 cases. Vet Pathol. 2000;37:597-608.
12. Roberson JR, Baird AN, Pugh DG. Diseases of the integumentary system. In: Pugh DG, Baird AN, editors. Sheep and goat medicine. 2nd ed. Saunders, an imprint of Elsevier Inc; 2012. 287 p.
13. Saleh FH, Crotty KA, Hersey P, Menzies SW. Primary melanoma tumor regression associated with an immune response to the tumor-associated antigen melan-A/MART-1. Int J Cancer. 2001;94:551-7.
14. Smedley RC, Lamoureux J, Sledge DG, Kiupel M. Immunohistochemical diagnosis of canine oral amelanotic melanocytic neoplasms. Vet Pathol. 2011;48:32-40.
15. Smith SH, Goldschmidt MH, McManus PM. A comparative review of melanocytic neoplasms. Vet Pathol. 2002;39:651-78.
16. Storm S, Yamamura Y. Epidemiology of non-melanoma skin cancer. Clin Plast Surg. 1997;24:627-36.
17. Sulaimon SS, Kitchell BE, Ehrhart EJ. Immunohistochemical detection of melanoma-specific antigens in spontaneous canine melanoma. J Comp Pathol. 2002;127:162-8.
18. Suzuki T, Kusumoto S, Iida S, Tada T, Mori F. Amelanotic malignant melanoma of unknown primary origin metastasizing to the bone marrow: A case report and review of the literature. Intern Med. 2014;53:325-8.
19. Valentine BA. Survey of equine cutaneous neoplasia in the Pacific Northwest. J Vet Diagn Invest. 2006;18:123-6.
20. Zorn E, Hercend T. A MAGE-6-encoded peptide is recognized by expanded lymphocytes infiltrating a spontaneously regressing human primary melanoma lesion. Eur J Immunol. 1999;29:602-7.