BJVP Brazilian Journal of Veterinary Pathology ISSN 1983-0246

Case Report

Thromboembolic encephalitis secondary to bacterial valvular endocarditis in a red-billed curassow (*Crax blumenbachii*)

Andréia Vielmo[1], Ronaldo M. Bianchi[1], Fernando F. Argenta[1], Veronica M. Rolim[1], Gustavo G. M. Snel[1,2], Bruna Zafalon-Silva[3], Marcelo M. Alievi[3], Claudio S. L. de Barros[4], David Driemeier[1]*

[1]Departamento de Patologia Clínica Veterinária, Setor de Patologia Veterinária, Faculdade de Veterinária, Universidade Federal do Rio Grande do Sul (UFRGS), Avenida Bento Gonçalves 9090, Agronomia 91540-000, Porto Alegre, Rio Grande do Sul, Brazil .
[2]Bolsista da CAPES–Brasil, Programa CsF.
[3]PRESERVAS-Núcleo de Conservação e Reabilitação de Animais Silvestres, Hospital de Clínicas Veterinárias, Universidade Federal do Rio Grande do Sul (UFRGS), Avenida Bento Gonçalves 9090, Agronomia 91540-000, Porto Alegre, Rio Grande do Sul, Brazil .
[4]Laboratório de Patologia Animal, Faculdade de Medicina Veterinária e Zootecnia, Universidade Federal do Mato Grosso do Sul (UFMS), Avenida Senador Filinto Müller 2443, 79074-460, Campo Grande, Mato Grosso do Sul, Brazil.
*Corresponding Author: Departamento de Patologia Clínica Veterinária, Setor de Patologia Veterinária, Faculdade de Veterinária, Universidade Federal do Rio Grande do Sul (UFRGS), Avenida Bento Gonçalves 9090, Agronomia 91540-000, Porto Alegre, Rio Grande do Sul, Brazil. E-mail: davetpat@ufrgs.br

Submitted September 11th 2017, Accepted January 16th 2018

Abstract

A case of bacterial (*Pseudomonas aeruginosa*) valvular endocarditis in a red-billed curassow is described. A traumatic fracture in one limb of the bird was considered the port of entry for the bacterium, followed by septicemia and seeding of the heart valve. Brain embolism resulting from detached thrombus fragments followed.

Key words: Cracidae, curassow, encephalitis, valvular endocarditis, *Pseudomonas aeruginosa*.

Introduction

Endocarditis is usually caused by bacteria that commonly affects the heart valves and occasionally extends to the adjacent mural endocardium (12). It is commonly described in cattle (11), pigs (6), horses (10), and dogs (13), but rarely reported in non-domesticated species (8). The aim of this report is to describe the pathological and microbiological aspects of a case of bacterial valvular endocarditis resulting in thromboembolic encephalitis in a red-billed curassow (*Crax blumenbachii*) from a wild fauna maintainer. To the authors' knowledge, this is the first report of this disease in this species.

Case report

The red-billed curassow, female, adult, was submitted for necropsy during which several tissues samples were processed for histopathology and stained with hematoxylin-eosin (HE).

The bird had one of its legs partially surgically amputated due to a traumatic fracture of the right tarsometatarsal joint. During the post-surgical period, it developed transient anorexia, weight loss, prostration and neurological signs such as ataxia and seizures, and died.

For bacterial isolation, fresh fragments of myocardium and valves were directly inoculated onto Sheep Blood Agar (5%) and McConkey Agar and incubated aerobically at 37°C for 24 hours. Bacteriologic examination revealed growth of mucoid, β-hemolytic colonies on Blood Agar and pale (non-lactose fermenting) colonies on MacConkey agar. The isolate was oxidase and catalase positive, produced a grape-like odor and a distinctive blue-green diffusible pigment on solid media. Gram staining showed medium-sized straight Gram-negative rods. Based on its characteristics, the isolate was identified as *Pseudomonas aeruginosa* (9).

 All rights reserved 2007.

At necropsy, regular body condition and absence of the distal part of the right pelvic limb from the tibiotarsal and tarsometatarsal joint were observed; the right pelvic limb had been bandaged. The heart had white, multifocal areas on the epicardium, and the aortic semilunar valve was thickened by a yellowish, friable mass (Fig. 1A). No other macroscopic alterations were found.

Histologically, thickening of the aortic semilunar valve due to edema, fibrin, proliferation of fibrovascular tissue, inflammatory infiltrate of heterophils, occasional lymphocytes and macrophages, and aggregates of bacilli were observed in the heart. Occasionally, the inflammatory infiltrate extended to the myocardium forming small aggregates between myofibers (Fig. 1B). In the brain, there were focally extensive areas of necrosis consisting of fragmented debris admixed with variable numbers of degenerated heterophils (Fig. 1C), occasional colonies of bacilli (Fig. 1D), and fibrin deposition. Multifocally, bounding the areas of liquefactive neuropil necrosis, there were moderate number of gitter cells. Furthermore, there was frequent vasculitis comprised of mural fibrinoid necrosis and associated thrombosis within affected areas. The spleen was observed to have deposition of fibrin within the red pulp and multifocal small areas of lymphoid necrosis of the white pulp. Discrete hyaline and necrosis of muscle fibers surrounded by inflammatory lymphohistiocytic infiltrate was observed in the skeletal muscles adjacent to the amputation site. The bacteriological cultured pure growth of numerous colony-forming units of *Pseudomonas aeruginosa*.

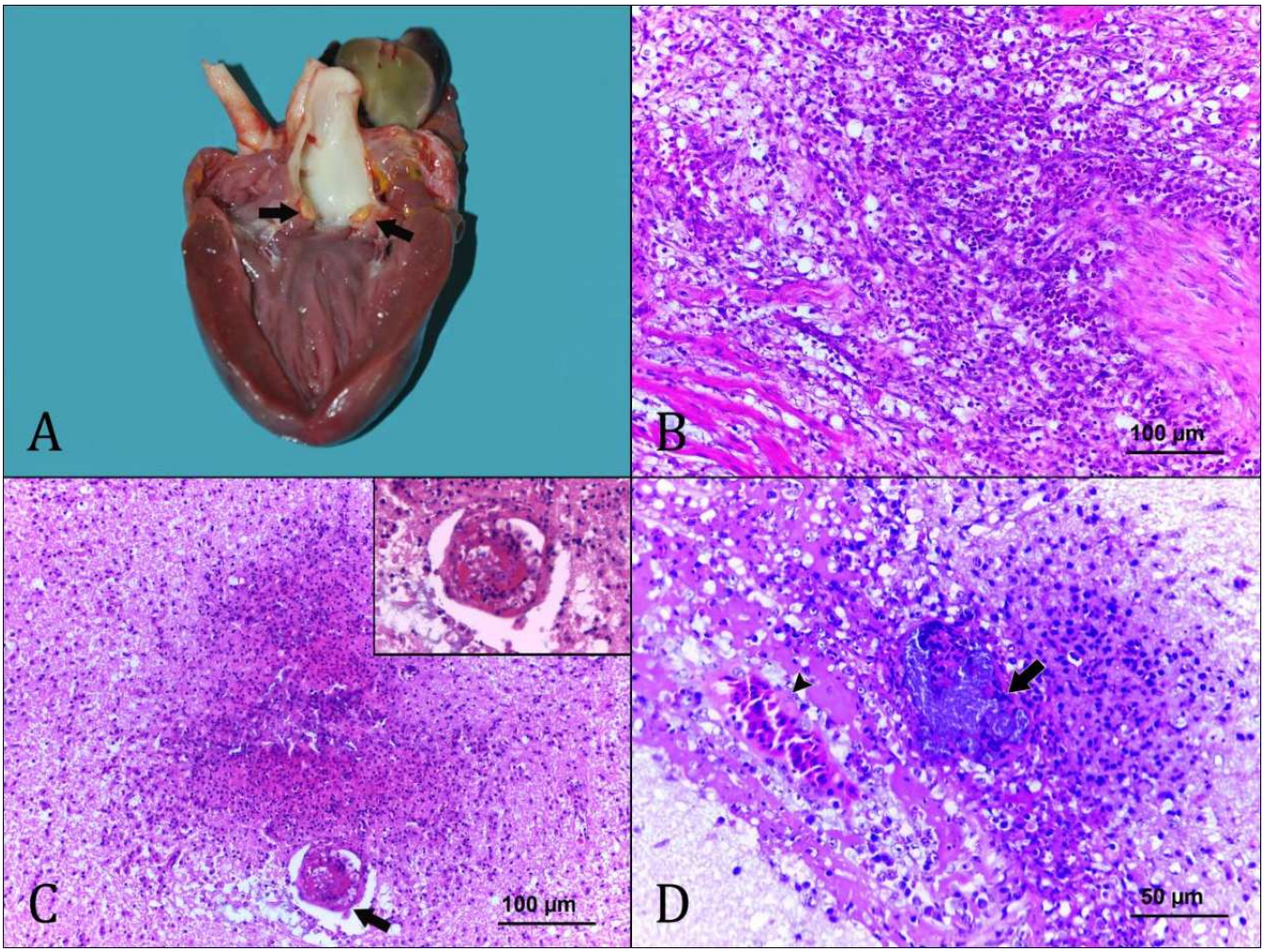

Figure 1. A. Heart. The aortic semilunar valve is thickened by a yellowish, friable mass (arrows). **B.** Heart. Inflammatory infiltrate of heterophils, occasional lymphocytes and macrophages in the endocardium, extending to the myocardium and forming small aggregates between myofibers. HE. 20X. **C.** Brain. Focally extensive area of liquefactive necrosis associate with inflammatory infiltrate consisting of degenerated heterophils, and thrombosis (arrow). HE. 20X. **D.** Brain. Inflammatory infiltrate of degenerated heterophils associate with bacterial aggregate (arrow) and fribinoid necrosis of the blood vessels (arrowheads). HE. 40X.

Discussion

Bacterial endocarditis frequently develops from a primary site of infection such as a penetrating wound, introduction of iatrogenic material, or bacterial sepsis, resulting in vascular migration to the heart and the colonizing of the cardiac valves (3). The left atrioventricular valve is the most commonly affected, followed by the aortic and the pulmonic valves; in the current report, the animal had a pelvic limb injury, which most likely was the port of entry for the bacterium. The lesions of endocarditis tend to occur at the lines of apposition on the surface of the valve exposed to forward blood flow in association with recurrent bacteremia (12).

Thrombosis and vasculitis in organs such as the brain, kidney, heart, and spleen, occurs due to bacteria proliferation within the mitral and aortic valves, overcomes the body's ability to sequester the infection. This results in the release of small fragments of the thrombus (emboli) in the bloodstream, that may or may not contain bacterial colonies, and cause obstruction of blood vessels. These organs have a unique vasculature with minimal vascular anastomoses; therefore, occlusion of blood vessels of various diameters typically results in infarction (8). This would justify the thromboembolic encephalitis reported in the present case.

Bacterial endocarditis is rarely reported in wild birds and to the best of our knowledge, had not been described in association with embolic brain lesions. There are some case reports including a bald eagle (7), mallards (14), a waldrapp ibis (2), a Salvin's Amazon parrot (1), a red-tailed hawk (8), hyacinth macaw (3), and a blue-and-gold macaw (5), among others. In these cases, bacterial endocarditis was caused by *Staphylococcus aureus* (3, 8, 14), *Streptococcus* sp. (2), *Enterobacter cloacae* (5), and *Lactobacillus jensenii* (1). However, the disease has not been described in red-billed curassows, which is a species at risk of extinction. Currrently, the known red-billed curassows are in public or private protected areas (4).

Pseudomonas aeruginosa is a strictly aerobic gram-negative nonspore-forming bacillus, oxidative, and catalase and oxidase positive. It is an opportunistic pathogen of animals, humans and, plants. Most isolates samples are resistant to many antimicrobials and may cause infections in animals undergoing antimicrobial or immunocompromised treatment. It may be found infrequently as part of the normal microbiota of healthy animals on the skin and mucous membranes but is rarely involved in primary diseases. Predisposing causes include tissue trauma (burns and wounds), immunodeficiency, and imbalance of the normal microbiota. In broiler chickens *Pseudomonas aeruginosa* can cause septicemia (9).

Valvular bacterial endocarditis is rarely described in wild birds; the diagnosis of the present report in a red-billed curassow was based on pathological and microbiological findings. The possibility of valvular lesions secondary to traumatic fractures due to a septicemia should be considered in wild birds, as seen is this case.

References

1. Foldenauer U, Rusch M, Simova-Curd S, Nitzl D, Hoop RK, Hatt JM. Endocarditis due to *Lactobacillus jensenii* in a Salvin's Amazon parrot (*Amazona autumnalis salvini*). Avian Pathol. 2009;38(1):55-8.
2. Greenwood AG, Marshall J, Tinsley EGF. Vegetative endocarditis in a Waldrapp ibis. Avian Pathol. 1996;25:387-91.
3. Huynh M, Carnaccini S, Driggers T, Shivaprasad HL. Ulcerative Dermatitis and Valvular Endocarditis Associated with *Staphylococcus aureus* in a Hyacinth Macaw (*Anadorhynchus hyacinthinus*). Avian Dis. 2014;58(2):223-7.
4. IBAMA 2004. Plano de ação para a conservação do mutum-do-sudeste *Crax blumenbachii* – uma espécie bandeira para a conservação da Mata Atlântica. Brasília: IBAMA/MMA.
5. Isaza R, Buergelt C, Kollias VG. Bacteremia and Vegetative Endocarditis Associated with a Heart Murmur in a Blue-and-Gold Macaw. Avian Dis. 199;36(4):1112-6.
6. Jarplid B, Brennius E, Nilsson Nils-Gunnar. Observations of apparent early valvular endocarditis in swine. J Vet Diagn Invest. 1997;9:449-51.
7. Jessup DA. Valvular endocarditis and bacteremia in a bald eagle. Mod Vet Pract. 1980;61:49-51.
8. Lemon MJ, Pack L, Forzán MJ. Valvular endocarditis and septic thrombosis associated with a radial fracture in a red-tailed hawk (*Buteo jamaicensis*). Can Vet J. 2012;53:79-82
9. Markey BK, Leonard FC, Archambault M, Cullinane A, Maguire D. 2013 *Pseudomonas*, *Burkholderia* and *Stenotrophomonas* species. In: Ibid. Clinical Veterinary Microbiology. 2nd ed., St. Louis (MO): Elsevier; 2013. p. 275-277.
10. Maxson AD, Reef VB. Bacterial endocarditis in horses: ten cases (1984-1995). Equine Vet J. 1997;29(5):394-9.
11. Power HT, Rebhun WC. Bacterial endocarditis in adult dairy cattle. J Am Vet Med Assoc. 1983;182(8):806-8.
12. Robinson FW, Robinson NA. Cardiovascular system. In: Maxie MG (ed). Jubb, Kennedy, and Palmer' pathology of domestic animals, 6th ed., vol. 3, St Louis (MO): Elsevier; 2016. p. 30-3.
13. Sykes JE, Kittleson MD, Pesavento PA, Byrne BA, MacDonald KA, Chomel BB. Evaluation of the relationship between cau,sative organisms and clinical characteristics of infective endocarditis in dogs: 71 cases (1992-2005). JAVMA. 2006;228(11):1723-34.
14. Wobeser G, Kost W. Starvation, Staphylococcosis, and vitamin A deficiency among Mallards

overwintering in Saskatchewan. J Wildl Dis. 1992;28(2):215-22.