



Original Full Paper

Identification of *Neospora caninum* in aborted bovine fetuses of Southern Chile

Manuel Moroni¹, Mauricio A. Navarro^{1,2}, Enrique Paredes¹, Alex Romero¹, Aintzane Alberdi¹, Tania Lischinsky³, Dadin P. Moore³, Carlos M. Campero³, Francisco A. Uzal^{2*}

¹Instituto de Patología Animal, Universidad Austral de Chile, Valdivia, Chile.

²California Animal Health and Food Safety Laboratory System, School of Veterinary Medicine, University of California, Davis, San Bernardino, CA, U.S.A.

³Instituto Nacional de Tecnología Agropecuaria (INTA), Balcarce, Argentina.

*Corresponding author: California Animal Health and Food Safety Laboratory System, San Bernardino Branch, University of California, Davis, 105 West Central Avenue, San Bernardino, CA 92408. E-mail: fauzal@ucdavis.edu

*Manuel Moroni and Mauricio A. Navarro contributed equally to this manuscript and are both joint first authors.

Submitted November, 6th, 2017, Accepted February, 05th 2018

Abstract

The aim of this study was to identify *Neospora caninum* in histologic sections of brain and optic nerve of aborted bovine fetuses. Sections of these tissues from 296 aborted bovine fetuses from Southern Chile, submitted between 2000 and 2010, to the Instituto de Patología Animal of the Universidad Austral de Chile were analyzed. Forty-four (14.9%) fetuses had microscopic lesions compatible with bovine neosporosis, including gliosis, necrosis, intralesional protozoan cysts and neuritis of optic nerves. *N. caninum* was identified by immunohistochemistry in brain sections of 27 cases (9.1%) with compatible lesions. Positive immunostaining was also found in the optic nerves of 13 cases (4.4%) with neuritis. *N. caninum* DNA was identified by PCR in brain sections in 31 cases (10.5%). In total, 36 cases (12.2%) were positive by either technique. Phylogenetic analysis of the ITS1 gene sequence of *N. caninum* revealed a high degree of conservation among different isolates. This is the first report of *N. caninum*-associated optic neuritis in cattle and also the first report of confirmed bovine abortion associated with this parasite in Chile.

Key words: bovine abortion, immunohistochemistry, *Neospora caninum*, PCR, phylogenetic analysis.

Introduction

The apicomplexan *Neospora caninum* is one of the most prevalent causes of abortion in cattle worldwide (8). Bovine neosporosis is manifested clinically mostly by fetal loss and neurologic signs in newborn calves. In the latter, the most significant gross changes include hydrocephalus, exophthalmos and narrowing of the spinal canal (9). Microscopic changes in bovine fetuses infected with *N. caninum* include multifocal, lymphoplasmacytic, necrotizing meningoencephalitis, myocarditis, hepatitis and myositis (2, 11). Similar lesions have been reported in aborted bovine fetuses in Chile (17, 18), but the cause was not determined. Inflammatory infiltrates in optic nerves

and retina have been reported in a foal (13) and a puppy (23) infected with *N. caninum*. However, no optic neuritis or retinitis has been described before in cattle with *N. caninum* infection.

Immunohistochemistry (IHC) and polymerase chain reaction (PCR) are frequently used to confirm the presence of *N. caninum* in association with lesions in the fetus (5, 9) for definitive diagnosis of bovine abortion due to *N. caninum* (4, 8). However, calves with brain lesions consistent with neosporosis and the presence of *N. caninum* have been described in term bovine fetuses which did not abort; this brings into question the use of these criteria to establish a definitive diagnosis of *N. caninum* abortion (26).

In Chile, serological evidence of exposure to *N. caninum* in dairy cattle by indirect fluorescent antibody test (IFAT) and enzyme-linked immunoassay (ELISA) has been previously documented (14, 20, 21). However, the parasite itself has never been reported in Chile before. In this study we report the detection of *N. caninum* in aborted bovine fetuses from Southern Chile. We also describe lesions in the optic nerve and retina, which have not been reported before in bovine fetuses with neosporosis.

Material and methods

Formalin-fixed, paraffin-embedded (FFPE) brain and optic nerves of 296, 3 to 9 months gestation aborted bovine fetuses that were submitted to the Instituto de Patología Animal, Universidad Austral de Chile for post-mortem examination, between 2000 and 2010, were used for this study. Bovine fetuses originated from dairy cattle herds from several regions of Southern Chile, from El Maule to Los Lagos region. FFPE tissues were processed routinely for the production of 4 µm-thick hematoxylin and eosin (H&E) sections. Microscopic changes in the brain considered compatible with *N. caninum* infection included focal or diffuse gliosis, diffuse glial infiltration, focal necrosis and the presence of protozoan cysts (22). Those cases showing microscopic lesions consistent with *N. caninum* infection were tested by IHC for *N. caninum* according to the protocol of the Laboratory of Veterinary Pathology at the Instituto Nacional de Tecnología Agropecuaria (INTA), Balcarce, Argentina (5, 6). Briefly, FFPE tissues were sectioned to produce 2-µm thick sections, and mounted on positively charged slides (ProbeOn™ Plus, microscope slides, Fisher Scientific, Pittsburgh, PA, USA) and processed in a manual immunostaining station (MicroProbe™, Fisher Scientific, Pittsburgh, PA, USA). Sections were treated with 0.4% pepsin (Sigma Chemical Co., St. Louis, MO) for antigen retrieval and incubated with 0.5% casein (Sigma Chemical Co., St. Louis, MO) to block nonspecific binding. A rabbit polyclonal anti-*N. caninum* antibody (donated by Dr. M. Anderson of the University of California, Davis, USA) was used at a dilution of 1:300. The reaction was amplified with Avidin Biotin Complex (Vectastain®, Elite ABC kit, PK-6101, Vector Laboratories, Burlingame, CA, USA), visualized with aminoethylcarbazole substrate (Dako Inc., Carpinteria, CA, USA) and the slides were counterstained with Mayer's hematoxylin. Liver samples from a mouse experimentally inoculated with *N. caninum* were used as a positive control. The negative control consisted of replacing the anti-*N. caninum* antibody with buffer. Additionally, four 5-mm-thick sections of FFPE tissues from cases with compatible lesions were placed into microcentrifuge tubes for dewaxing by adding 1 ml of xylene, followed by centrifugation for 2 minutes at 12,000 xg. Then, the xylene was removed, and the pellet was washed with 1 ml of 100% ethanol. After centrifugation at 12,000 xg for 2 minutes, the ethanol was discarded, and

the samples were dried at room temperature for 45 minutes. The dewaxed tissues were then subjected to DNA extraction by using a commercial kit (QIAamp DNA FFPE Tissue Kit; Qiagen, Hilden, Germany) following the instructions of the manufacturer. The extracted DNA was used as a template for conventional PCR detection of the *N. caninum* *Nc5* gene (GenBank AN: X84238) using the following primers: 5'-GGGTGAACCGAGGGAGTTG-3' (Np4) and 5'-CCTCCCAATGCGAACGAAA-3' (Np7), which amplify a ~275 bp DNA fragment of the target gene (Yamaga et al, 1996). PCR was performed in a total volume of 25 µl containing 5 µl of extracted DNA, 10.9 µl of sterile water, 0.2 µl of GoTaq® Flexi DNA polymerase (5U/µl), 5 µl of 5X Green Flexi Buffer for GoTaq®, 1 µl of purified BSA (10 mg/ml), 1 µl of MgCl₂ (25 mM), 0.5 µl dNTPs (10 mM) and 0.7 µl of each primer. The samples were amplified in a thermocycler (LabNet® Thermal Cycler, Labnet International Inc., Woodbridge, NJ, USA) using the following conditions: 95° C for 5 minutes, 35 cycles of 95° C for 30 seconds, 55° C for 1 minute, 72° C for 1 minute and a final extension of 72° C for 7 minutes. The PCR products were separated on 1.5 % agarose gels stained with GelRed and observed under ultraviolet light. DNA extracted from a *N. caninum* strain was used as positive control. DNA extracted from a normal fetus was used as a template in negative controls reactions. Seven randomly selected positive samples, plus the positive control, were also tested for another PCR targeting the internal transcribed spacer 1 (ITS1) region of the rDNA of *N. caninum* as previously described (dos Santos et al, 2011) (7). After electrophoresis, PCR products were extracted from agarose gels (QIAquick Gel Extraction Kit; Qiagen, Hilden, Germany) and sent to Macrogen for sequencing. The sequencing results were edited based on a previously described method (7), and they were deposited in GenBank. The MEGA4® software (<http://www.megasoftware.net>) (25) was used to determine the degree of similarity between sequences and their phylogenetic relationships with other protozoal sequences belonging to the same subfamily (Toxoplasmatinae) deposited in GenBank, using the Neighbor-Joining method adjusted by using the nucleotide replacement parameter Kimura 2 (24).

Results

A diagnosis of *N. caninum* infection was confirmed in 36 out of the 296 fetuses (12.2%) which were positive by IHC or PCR (Table 1). Forty-four fetuses tested (14.9%) had microscopic lesions consistent with *N. caninum* infection in the brain. The most common lesions were multi-focal gliosis (Fig. 1A) and multi-focal necrosis (Fig. 1B), both found most frequently in the brainstem. Diffuse gliosis was rarely observed. Protozoan cysts (Fig. 1C) were observed in 4 cases with compatible lesions; these cysts were seen in samples of cerebrum (2), brainstem (1) and cerebellum (1). In 13 optic nerves

(4.4%) there was diffuse lymphoplasmacytic infiltration (Fig. 1D).

Table 1. Microscopic lesions (ML) compatible with *N. caninum* infection, *N. caninum* immunohistochemistry (IHC) and polymerase chain reaction (PCR) results in the brain and optic nerves of bovine fetuses aborted between 2000 and 2010.

Year	Number of fetuses	Number of brains				Number of optic nerves	
		ML	IHC (+)	PCR (+)	IHC or PCR (+)	ML	IHC (+)
2000	19	1	0	0	0	0	0
2001	18	1	0	0	0	0	0
2002	21	0	0	0	0	0	0
2003	15	0	0	0	0	0	0
2004	20	4	2	4	4	1	0
2005	51	8	5	5	5	3	0
2006	46	4	3	4	4	0	0
2007	31	11	6	8	9	5	1
2008	31	4	4	1	4	1	0
2009	11	3	1	2	2	1	1
2010	33	8	6	7	8	2	0
Total	296	44 (14.9%)	27 (9.1%)	31 (10.5%)	36 (12.2%)	13 (4.4%)	2 (0.7%)

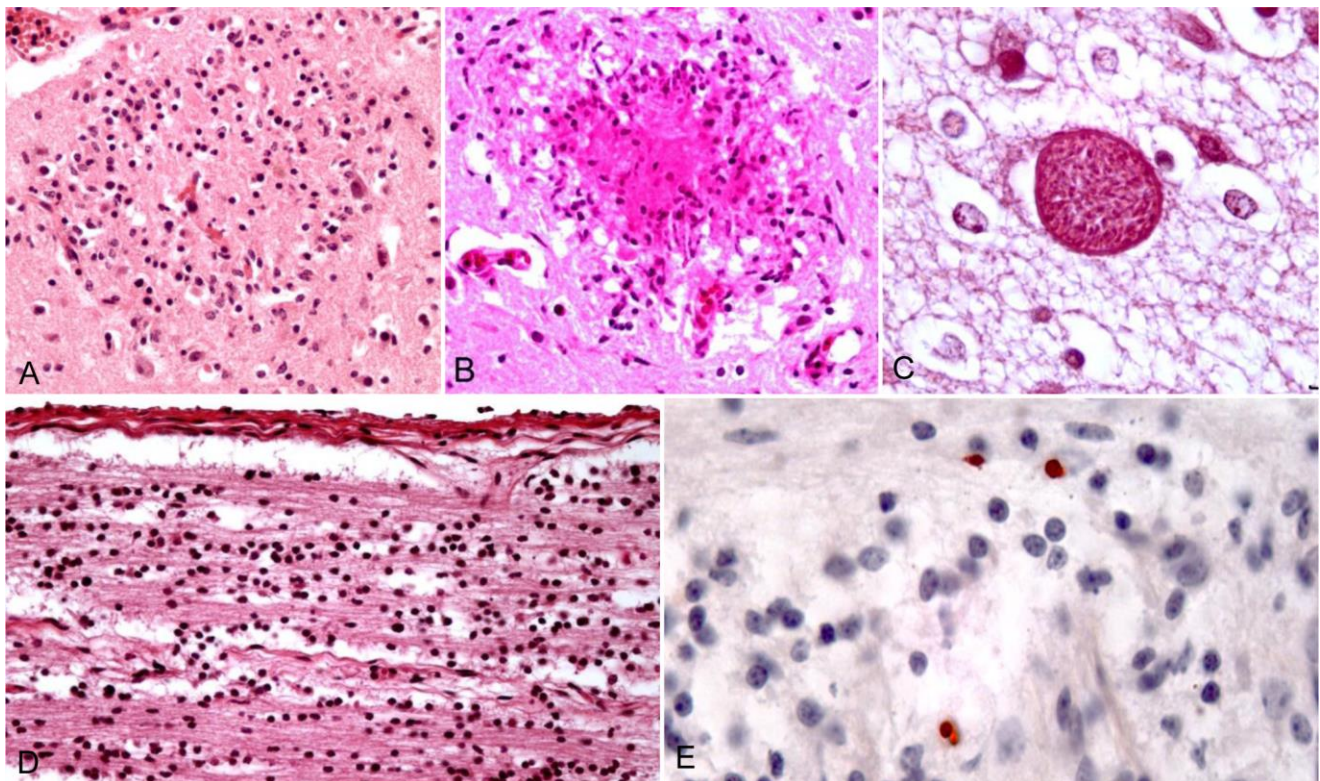


Figure 1. Microscopic findings in the CNS and optic nerve of aborted bovine fetuses. **A.** Focal gliosis in the brain (40X). **B.** Central focal necrosis surrounded by glial cells and vacuoles in the brainstem (40X). **C.** Protozoan cyst in the brain (100X). **D.** Diffuse neuritis of the optic nerve (40X). **E.** *N. caninum* immunopositive tachyzoites in the optic nerve (100X).

N. caninum was identified by IHC in 27 (9.1%) aborted bovine fetuses with microscopic lesions compatible with infection by this microorganism in the brain (Table 1). Tachyzoites were detected by IHC in 2 (0.7%) optic nerves with neuritis (Fig. 1E). In addition, 31 (10.5%) of the cases were positive for *N. caninum* PCR

when targeting the Nc5 gene. Amplified PCR products of the ITS1 region of *N. caninum* resulted in 98 to 100% similarity. A phylogenetic tree describing their phylogenetic relationship is presented in Fig. 2.

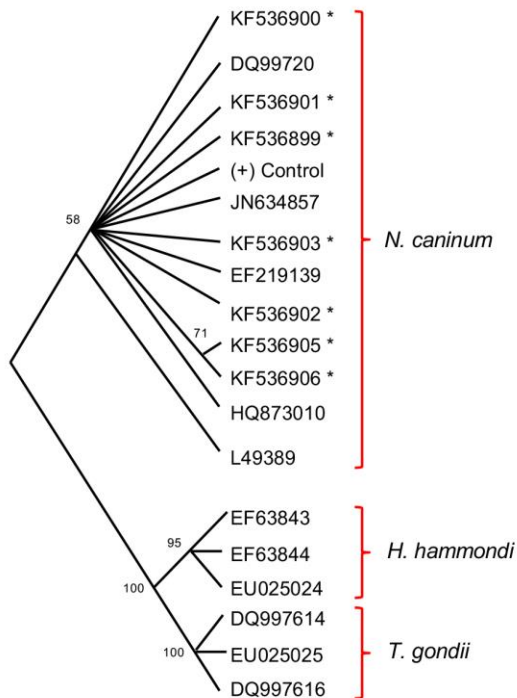


Figure 2. Phylogenetic relationships obtained among 19 sequences of the internal transcribed spacer 1 (ITS1) region of the rDNA of the Toxoplasmatinae subfamily represented by *Neospora caninum*, *Hammondia hammondi* and *Toxoplasma gondii*, based on a previously described method (dos Santos et al, 2011) (7). Terminal nodes indicate the GenBank accession numbers. Sequences highlighted with asterisks are those obtained in this study.

Discussion

In the south of Chile, the main infectious agents responsible for bovine abortion are *Leptospira interrogans*, bovine viral diarrhoea virus and bovine herpesvirus type 1 (19). Suspected infection by *N. caninum* has been reported based on serological tests (14, 20, 21). In addition, the presence of compatible microscopic changes in the brain and myocardium of aborted bovine fetuses has been reported (17, 18). However, definitive confirmation of a diagnosis of neosporosis has never been reported in Chile.

Although *N. caninum* may cause non-suppurative lesions in multiple tissues of the bovine fetus, examination of the brain is widely used to establish a presumptive diagnosis of *N. caninum* abortion (3, 4, 8). The most common microscopic lesions in the brain of fetuses in this study were focal gliosis and multi-focal necrosis. These findings are in agreement with several previous reports of *N. caninum* abortion in which brain lesions were mononuclear or necrotic multifocal encephalitis (12, 16).

In this study, a positive IHC result for *N. caninum* was obtained in 9.1% (27 cases) of the total number of fetuses analyzed, a slightly higher value than that of a previous study in Argentina, in which 7.4% of aborted

bovine fetuses were positive for *N. caninum* IHC (15). However, when only cases with microscopic compatible lesions were considered, *N. caninum* was detected by IHC in 61.4% (27/44) of the cases, while PCR detection reached 70.5% (31/44), suggesting a slightly higher sensitivity of this particular test, which may improve when fresh or frozen tissues are available. Nevertheless, it should be stressed that these sensitivities were calculated based on cases that had compatible microscopic lesions, a criterion that has not been validated to establish a definitive diagnosis of bovine neosporosis.

To the best of the authors' knowledge, no previous reports of *N. caninum*-associated optic neuritis have been published in cattle before. Optic neuritis was found in 13 (4.4%) of the specimens analyzed on this study, and IHC for *N. caninum* was positive in 2 of those cases, suggesting that this parasite was responsible for neuritis in at least some aborted fetuses.

The phylogenetic relationships seen in this study suggest a high degree of conservation among our sequences and those obtained from GenBank, while well-defined distances are observed when the sequences of *N. caninum* are compared with other species classified in the same Toxoplasmatinae subfamily. The results are consistent with previous reports (1, 7) that suggest little nucleotide variation in *N. caninum* isolates, and minor intra-strains differences seem to be a common finding, unlike the case of *T. gondii* (10). It has been suggested that the high homology between strains of *N. caninum* from different geographical areas would be influenced by the movement of animals between different regions, resulting in the distribution of a relatively homogeneous and dominant strain (7). The molecular characteristics of a strain may be useful for epidemiological studies and in the determination of the pathogenicity of a certain agent; in this regard, little is known about intra-strain variation and its relationship with the degree of virulence for *N. caninum*. Experimentally, some strains have shown to be more virulent than others when inoculated into mice and have shown differences in *in vitro* cultures (9). Significant genetic variations have not been demonstrated to this date, leading to the assumption that the level of pathogenicity depends on intrinsic elements of the affected animal, mainly the immune status at the time of infection, rather than attributes of the parasite.

In summary, the results obtained in this study show that *N. caninum* is recognized by IHC and PCR in bovine fetuses from 2004, being associated with histopathological lesions, and it is recognized as a causative agent of bovine abortions in Chile. Histopathological examination of the CNS of the fetuses is highly important since such lesions are indicative of vertical infection. Nevertheless, confirmation must be attempted by additional techniques such as IHC and PCR, as in the present study, in order to rule out the role of additional causes of bovine abortion. Neuritis of the optic

nerve should be considered suggestive of *N. caninum* infection in bovine fetuses.

References

1. Al-Qassab SE, Reichel MP, Ellis JT. On the biological and genetic diversity in *Neospora caninum*. *Diversity*. 2010;2:411-38.
2. Anderson M, Barr B, Rowe J, Conrad P. Neosporosis in dairy cattle. *Jpn J Vet*. 2012;60:51-4.
3. Antoniassi NAB, Juffo GD, Santos AS, Pescador CA, Corbellini LG, Driemeier D. Causas de aborto bovino diagnosticadas no setor de patologia veterinária da UFRGS de 2003 a 2011. *Pes Vet Bras*. 2013;33:155-60.
4. Cabral AD, Camargo CN, Cacciatori NT, Okuda LH, Pituco EM, Del Fava C. Diagnosis of *Neospora caninum* in bovine fetuses by histology, immunohistochemistry and nested-PCR. *Rev Bras Parasitol Vet*. 2009;18:14-9.
5. Campero CM, Anderson ML, Conosciuto G, Odriozola H, Bretschneider G, Poso MA, *Neospora caninum*-associated abortion in a dairy herd in Argentina. *Vet Rec*. 1998;143:228-9.
6. Campero CM, Moore DP, Odeon AC, Cipolla AL, Odriozola E. Aetiology of bovine abortion in Argentina. *Vet Res Commun*. 2003;27(5):359-69.
7. dos Santos DS, Andrade MP, Varaschin MS, Guimaraes AM, Hirsch C. *Neospora caninum* in bovine fetuses of Minas Gerais, Brazil: genetic characteristics of rDNA. *Rev Bras Parasitol Vet*. 2011;20:281-8.
8. Dubey JP, Schares G, Ortega-Mora LM. Epidemiology and control of neosporosis and *Neospora caninum*. *Clin Microbiol Rev*. 2007;20:323-67.
9. Dubey JP, Schares G. Neosporosis in animals—The last five years. *Vet Parasitol*. 2011;180:90-108.
10. Gondim LF, Laski P, Gao L, McAllister MM. Variation of the internal transcriber spacer 1 sequence within individual strains and among different strains of *Neospora caninum*. *J Parasitol*. 2004;90:119-22.
11. Holler LD, Ruminant abortion diagnostics. *Vet Clin Food Anim*. 2012;28:407-18.
12. Lértora WJ, Mohr-Betiana N, Mosqueda MG, Sánchez-Negrette M. Detección de *Neospora caninum* en fetos bovinos abortados espontáneamente en el nordeste argentino. *In Vet*. 2010;12:173-82.
13. Lindsay DS, Steinberg H, Dubielzig RR, Semrad SD, Konkle DM, Miller PE, Blagburn BL. Central nervous system neosporosis in a foal. *J Vet Diagn Invest*. 1996;8:507-10.
14. Meléndez P, Concha C, Donovan A, Bjorkman C. Evidencia serológica de *Neospora caninum* en un rebaño lechero de la zona central de Chile. *Av Cs Vet*. 1999;14:13-6.
15. Moore DP, Regidor-Cerrillo J, Morrell E, Poso MA, Cano DB, Leunda MR, Linschinky L, Odeón AC, Odriozola E, Ortega-Mora LM, Campero CM. The role of *Neospora caninum* and *Toxoplasma gondii* in spontaneous bovine abortion in Argentina. *Vet Parasitol*. 2008;156:163-7.
16. Nishimura M, Kohara J, Hiasa J, Muroi Y, Yokoyama N, Kida K, Xuan X, Furuoka H, Nishikawa Y. Tissue distribution of *Neospora caninum* in experimentally infected cattle. *Clin Vaccine Immunol*. 2013;20:309-12.
17. Paredes E, Moroni M. Causas de aborto bovino diagnosticadas en el Instituto de Patología Animal de la Universidad Austral de Chile; período 2005-2007. 2007 Resúmenes de VIII Jornadas Chilenas de Buiatría, Frutillar, Chile, p. 94-5.
18. Paredes E, Moroni M, Jara K. Causas de aborto bovino diagnosticadas en el Instituto de Patología Animal de la Universidad Austral de Chile; período 2007-2009. 2009 Resúmenes de IX Jornadas Chilenas de Buiatría, Osorno, Chile, p. 56-7.
19. Paredes E, Moroni M, Navarrete MJ, Meyer L. Causas de aborto bovino diagnosticadas en el Instituto de Patología Animal de la Universidad Austral de Chile; período 2009-2011. 2011 Resúmenes de X Congreso Chileno de Buiatría, Osorno, Chile, p. 141-2.
20. Patitucci AN, Pérez MJ, Luders CF, Ratto MH, Dumont AG. Evidencia serológica de infección por *Neospora caninum* en rebaños lecheros del sur de Chile. *Arch Med Vet*. 1999;31:215-8.
21. Patitucci AN, Pérez MJ, Israel KF, Rozas MA. Prevalencia de anticuerpos séricos contra *Neospora caninum* en dos rebaños lecheros de la IX Región de Chile. *Arch Med Vet*. 2000;32:209-14.
22. Pescador CA, Corbellini LG, Oliveira EC, Raymundo DL, Driemeier D. Histopathological and immunohistochemical aspects of *Neospora caninum* diagnosis in bovine aborted fetuses. *Vet Parasitol*. 2007;150:159-63.
23. Peters M, Wagner F, Schares G. Canine neosporosis: clinical and pathological findings and first isolation of *Neospora caninum* in Germany. *Parasitol Res*. 2000;86:1-7.
24. Saitou N, Nei M. The neighbor-joining method: a new method for reconstructing phylogenetic trees. *Mol Biol Evol*. 1987;4:406-25.
25. Tamura K, Dudley J, Nei M, Kumar S. MEGA4: Molecular Evolutionary Genetics Analysis (MEGA) software version 4.0. *Mol Biol Evol*. 2007;24:1596-9.
26. Thurmond MC, Hietala SK, Blanchard PC. Predictive values of fetal histopathology and immunoperoxidase staining in diagnosing bovine abortion caused by *Neospora caninum* in a dairy herd. *J Vet Diagn Invest*. 1999;11:90-4.
27. Yamage M, Flechtner O, Gottstein B. *Neospora caninum*: specific oligonucleotide primers for the detection of brain “cyst” DNA of experimentally

infected nude mice by the polymerase chain reaction (PCR). J Parasitol. 1996;82:272-9.