BJVP
Brazilian Journal of Veterinary Pathology
ISSN 1983-0246

**Original Full Paper**

# Ameliorative effect of curcumin and vitamin B6 against lithocholic acid-induced cholestasis and liver injury in mice

Mohamed A. Nassan[1,2*], Tamer A. Ismail[1,3], Mohamed M. Soliman[1,4], Adel Q. Alkhedaide[1]

[1]Medical Laboratory Department, Faculty of Applied Medical Sciences, Turabah, Taif University, Saudi Arabia.
[2]Department of Pathology, Faculty of Veterinary Medicine, Zagazig University, Egypt.
[3]Department of Physiology, Faculty of Veterinary Medicine, Zagazig University, Egypt.
[4]Department of Biochemistry, Faculty of Veterinary Medicine, Benha University, Egypt.
***Corresponding author:** Pathology Department, Faculty of Veterinary Medicine, Zagazig University, El-Tagneed street, Zagazig, Egypt Tel.: +20553989550 moh_nassan@yahoo.com.

Submitted October 12th 2017, Accepted January 18th 2018

## Abstract

To examine the therapeutic effect of curcumin and/or vitamin B6 in treatment of cholestasis, a model of cholestasis was induced in mice using lithocholic acid (LCA). Alterations in biochemical parameters and liver histopathological and histochemical changes were examined in cholestatic mice and after treatments with curcumin, vitamin B6 and combination of both. Moreover, hepatic expressions of bilirubin-metabolizing enzymes, their regulatory nuclear receptors, and bile acid lipid transporters were examined using RT-PCR. Cholestatic mice showed an increase in the blood levels of AST, ALT, ALP, direct and total bilirubin and a decrease in cholesterol levels that were ameliorated by treatments. Liver histopathology showed multiple necrotic foci of different sizes spread all over the liver with congestion of hepatic blood vessels in LCA group. These foci were regenerated in hepatic tissues after administration of curcumin and vitamin B6. Immunohistochemical examination of liver showed an increase in glutathione and *NF-kB* expressions in treated mice. Cholestatic mice showed down-regulation of mRNA expression of hepatic bile acid and bilirubin-metabolizing/detoxifying enzymes (*Cyp2b10*, *Ugt1a1*, *Sult2a1*), their regulatory nuclear receptors (*CAR*, *PXR*, *farnesoid X receptor*), and bile acid/organic anion and lipid transporters (*Oatp2*, *Bsep*, *Mrp2*, *Abcg8*, *Asbt*). These changes were ameliorated and restored by treatment with curcumin, vitamin B6 and both. Only of examined genes, *NTCP* was up-regulated in cholestatic mice. In conclusion, treatment with curcumin mainly, vitamin B6 or the combination of them has the potential to ameliorate changes observed in induced cholestasis.

**Key words:** cholestasis, liver, curcumin, vitamin B6.

## Introduction

Cholestasis results from obstruction of the biliary tracts or due to inhibition of the bile salt export pump (*BSEP*) at the canalicular surface of the hepatocyte. This blockage results in accumulation of bile acids or their metabolites in hepatocytes and serum (34). The excess accumulation of bile acids markedly alters the expression of various genes involved in cholesterol and phospholipid homeostasis, resulting in cell death and inflammation, leading to severe liver injury (27). Bile acids accumulate in hepatocytes during cholestasis and have the potential to cause cytotoxicity (25). Liver injury caused by obstructive cholestasis in rodent model is characterized by bile infarcts which appear as areas of focal necrosis (15). Exposure of hepatic cells to high levels of the bile acids does not cause cell death directly (36). Several studies showed that high concentrations of toxic bile acids in rat hepatocytes resulted in hepatocellular apoptosis, mediated by mitochondrial and lysosomal dysfunction (14). Various studies revealed that the nature of acute liver injury in obstructive cholestasis is mainly an inflammatory injury,

 All rights reserved 2007.

triggered by the biliary leakage of osteopontin and the generation of CXC chemokines by hepatocytes exposed to bile acids (22).

Among varieties of bile acids, lithocholic acid (LCA) is a toxic hydrophobic secondary bile acid formed in the large intestine by bacterial 7α-dehydroxylation of chenodeoxycholic acid. Feeding LCA for rodents was used as a model of liver injury and cholestasis (11, 26). The accumulation of high biliary concentrations of LCA and its metabolites results in precipitation of LCA in cholangioles, segmental bile duct obstruction and destructive cholangitis (11).

The metabolizing enzymes play an important role in bile acid and bilirubin detoxification fundamentally via phase I hydroxylation and phase II conjugation which produce less toxic metabolites that are more liable to be excreted by urine. Also, bile acids are eliminated by transporters either on the canalicular membrane into bile or on the sinusoidal membrane into blood (13). Homeostasis is tightly regulated through multiple nuclear receptors including *FXR*, *RXR*, and *CAR*. These transporters undergo post-transcriptional regulation including insertion of transporters into/from the plasma membrane. These mechanisms regulate bile acid synthesis and transport under normal physiological conditions. Also they regulate intracellular concentrations of bile acids through suppression of bile acid synthesis, induction of bile acid metabolism as well as inhibition of hepatic bile acid uptake, and stimulation of bile acid efflux (35).

Curcumin is a phenolic compound found in the known spice turmeric, derived from the rhizome of *Curcuma longa* (1). Curcumin possesses antioxidant, free radical scavenging, anti-inflammatory, chemotherapeutic, radio-protective, and carcinogen-induced tumorigenesis-inhibitory effects in humans and laboratory animal (29). Curcumin can play different roles as antioxidant, as elimination of hydrogen peroxide, hydroxyl radical and peroxynitrite (3). Curcumin can also enhance the body's antioxidant capacity; and can increase the glutathione content and remove the reactive oxygen species (ROS). Vitamin B6 is involved in the metabolism of amino acids, nucleic acids, glycogen, lipids, and porphyrin and may play a vital role in antioxidant mechanism (21).

Vitamin B6 may react directly with the peroxy radicals and thus scavenge radicals and inhibit lipid peroxidation (19). Also, vitamin B6 may play an antioxidant role indirectly by acting as coenzyme in the glutathione antioxidant defense system through trans-sulfuration pathway of homocysteine to cysteine which act as an important participant in synthesis of reduced glutathione (GSH). A Japanese study reported that consumption of vitamin B6 reduces fecal ratio of lithocholic acid to deoxycholic acid in rats fed a high-fat diet (24).

Therefore, the current study aimed to examine the effect of curcumin and/ or vitamin B6 on the LCA feeding model and study their effect on hepatic bile acid and bilirubin-metabolizing/detoxifying enzymes (*Cyp2b10*, *Cyp3a11*, *Ugt1a1*, *Sult2a1*), their regulatory nuclear receptors (*CAR*, *PXR*, *farnesoid X receptor*), and bile acid and lipid transporters (*Ntcp*, *Oatp2*, *Bsep*, *Mrp2*, *Abcg8*, *Asbt*) in the liver. Moreover, biochemical assessments, histopathologic and immunohistochemical examinations of glutathione and *NFkB* in the liver will be performed

## Material and methods

### *Materials*

Adult male specific pathogen-free (SPF) Balb/c mice, 8 weeks old, weighting (20–25 g) were purchased from King Fahd Institute for Scientific Research, King AbdelAziz University, Saudi Arabia. Lithocholic acid was from Santa Cruz Biotechnology, Heidelberg Germany. Curcumin was from Taif markets and was identified by botanist. Vitamin B6 was purchased from Julphar pharmaceutical Company, Saudi Arabia. Biochemical kits for liver and other profiles were from Clini Lab, Cairo, Egypt. Solvents and related materials were from ADWIA pharmaceutical company, Egypt.

### *Animals and experimental Procedure*

Eighty adult male mice were housed under conditions of controlled temperature (25 ± 2°C) with a 12 h/12 h day-night cycle in laboratory animal unit, College of Applied Medical Sciences, Turabah, Taif University. Animals gained free access to food and water ad libitum. All procedures were approved by the Animal Care Committee of Taif University for the project # 5169-437-1.

### *Experimental design*

Adult healthy male mice were allocated into 8 groups, (10 mice each). Group (1): Negative control group - didn't receive any medication and gained free access to food and water. Group (2): Curcumin group -received 150 mg/kg curcumin daily by oral gavage (33). Group (3): Vitamin B6 group received 24 mg/kg vitamin B6 daily in the diet (28). Group (4): Curcumin and vitamin B6 group received 150 mg/kg curcumin by oral gavage and 24 mg/kg vitamin B6 daily in the diet. Group (5): Cholestatic group fed on 1% LCA mixed in diet for 4 days (1gm LCA added to 100 gm diet) and allowed food and water *ad libitum*. (1). Group (6): Cholestatic group treated with curcumin; fed on 1% LCA mixed in diet for 4 days then received 150 mg/kg curcumin daily by oral gavage. Group (7): Cholestatic group treated with vitamin B6; fed on 1% LCA mixed in diet for 4 days then received 24 mg/kg vitamin B6 daily in the diet. Group (8): Cholestatic group treated with curcumin and vitamin B6; fed on 1% LCA mixed in diet for 4 days then curcumin in a dose of 150 mg/kg orally and vitamin B6 in a dose of 24 mg/kg daily in

diet. Animals received their treatments daily for one month. At the end of experiments animals were decapitated and blood was collected for biochemical examination. Liver specimens were collected for histopathology and gene expression.

*Assay of biochemical parameters*

Serum samples were analyzed by standard enzymatic assays using commercial available kits for alanine aminotransferase (ALT), aspartate aminotransferase (AST), direct and total bilirubin (DBIL and TBIL), cholesterol in accordance with the manufacturer's protocols (Jiang-Cheng Biological, Nanjin, China). Gamma-glutamyl transferase (GGT) was assayed by using commercial Kit #GT1065, Randox, U.K. according to manufacturer's instructions manual.

*Gene expression and reverse transcription polymerase chain reaction (RT-PCR)*

For preparation of total RNA, liver samples (50 mg each) were immediately frozen in liquid nitrogen and subsequently stored at -70°C in 1 ml Qiazol. Frozen samples were then homogenized using a Polytron 300 D homogenizer (Brinkman Instruments, Westbury, NY). Then 0.3 ml chloroform was added to the homogenate. These mixtures were shaken for 30 seconds followed by centrifugation at 4°C at 12000 rpm for 20 min. The supernatant was then transferred to a new set of tubes, and an equal volume of isopropanol was added to the tubes, shacked for 15 seconds and centrifuged at 4°C at 12000 rpm for 15 min. The RNA pellets obtained were washed with 70% ethanol, briefly dried up then dissolved in Diethylpyrocarbonate (DEPC) water. RNA integrity was checked by electrophoresis. RNA concentration and purity were detected spectrophotometrically at 260 nm (10).

For cDNA synthesis, mixture of 2 µg total RNA and 0.5 ng oligo dT primer in a total volume of 11 µl sterilized DEPC water was incubated in the PeX 0.5 thermal Cycler (PCR machine) at 65°C for 10 min for denaturation. Then, 4 µl of 5X RT-buffer, 2 µl of 10 mM dNTPs and 100 U Moloney Murine Leukemia Virus (M-MuLV) Reverse Transcriptase were added in a total volume of 20 µl by DEPC water. This mixture was re-incubated in the thermal Cycler at 37°C for 1h. To inactivate the enzyme, incubation at 90°C for 10 min was done.

Specific primers for genes were designed using Oligo-4 computer program and synthesized by Macrogen (Macrogen Company, GAsa-dong, and Geumcheon-gu. Korea) as shown in Table 1. PCR was conducted in a final volume of 25 µl consisting of 1 µl cDNA, 1 µl of 10 picomolar (pM) of each primer (forward and reverse), and 12.5 µl PCR master mix (Promega Corporation, Madison, WI) the volume was brought up to 25 µl using sterilized, deionized water. PCR reaction was carried out at 94 °C for 5 minutes one cycle, followed by 30-35 cycles each consisted of denaturation at 94 °C for one minute, annealing at the specific temperature corresponding to each primer (Table 1) and extension at 72 °C for one minute with additional final extension step at 72 °C for 5 minutes. As a reference, expression of glyceraldehyde-3-phosphate dehydrogenase (*G3PDH*) mRNA as house keeping gene was done. PCR products were electrophorized on 1% agarose gel stained with ethidium bromide in TBE (Tris-Borate-EDTA) buffer. PCR products were visualized under UV light and photographed using gel documentation system.

*Histopathological examination*

Liver specimens were fixed in 10% buffered neutral formalin solution for at least 24 hours and then routinely processed for paraffin embedded. Paraffin sections of 5 micron thickness were prepared, stained with Hematoxylin and Eosin stain (H&E) and then examined microscopically.

*Immunohistochemical examination of glutathione and* NF-kB

Hepatic tissues were fixed in 10% buffered neutral formalin, washed, dehydrated, cleared, embedded in paraffin, and sectioned. Tissue sections were deparaffinized and treated with 3% $H_2O_2$ for 10 min to inactivate the peroxidases. Subsequently, samples were heated in 10 mM citrate buffer at 121°C for 30 min for antigen retrieval and blocked in 5% normal serum for 20 min, and then were incubated with a rabbit polyclonal anti-glutathione primary antibody (1:100; sc-71155; Santa Cruz Biotechnology, Inc., Dallas, TX) or *NFκB* p50 antibody (1:100; sc-7178; Santa Cruz Biotechnology, Inc.) in phosphate-buffered saline (PBS) overnight at 4°C. After three extensive washes with PBS, the sections were incubated with a goat anti-rabbit IgG biotin-conjugated secondary antibody (1:2,000; sc 2040; Santa Cruz Biotechnology, Inc.) for 20 min at 32°C. After further incubation with horseradish peroxidase-labeled streptavidin, antibody binding was visualized using diaminobenzidine, and the sections were counterstained with hematoxylin (18).

*Statistical analysis*

Results are shown as means ± standard error of means (SEM). Data analysis were done using analysis of variance (ANOVA) and post hoc descriptive tests by SPSS software version 11.5 for Windows (SPSS, IBM, Chicago, IL, USA) with $p<0.05$ considered as statistically significant. Regression analysis was done using the same software.

**Table 1.** Polymerase chain reaction conditions for the genes analyzed.

| Gene | Product size | Annealing temperature (°C) | Sense | Antisense |
|---|---|---|---|---|
| *G3PDH* | 396 | 59 | tgttcctacccccaatgtgt | tgtgagggagatgctcagtg |
| *CYP2B10* | 340 | 59 | agtacccccatgttgcagag | ggaggatggacgtgaagaaa |
| *UGT1A1* | 344 | 60.5 | cctatgggtcacttgccact | cgatggtctagttccggtgt |
| *SULT2A1* | 342 | 59 | tcggctggaatcctaagaga | tgggaagatgggaggttatg |
| *CAR* | 476 | 60.5 | gggcttcttcagacgaacag | tctggtcctccatggttagg |
| *PXR* | 300 | 60.5 | gctgaaggctagcagcttgt | ctcagaccccacaccaagtt |
| *FXR* | 483 | 59 | agttgccgtgaggaagctaa | gtgagcgcgttgtagtggta |
| *ABCG8* | 446 | 59 | tctccaggtcctgattggtc | ggcaatcagagtcaacagca |
| *ASBT* | 443 | 58.5 | gactcgggaacgattgtgat | gcaaagacgagctggaaaac |
| *MRP2* | 499 | 59 | tcctagacagcggcaagatt | ctctggctgtccaacactca |
| *BSEP* | 335 | 60 | actggtaggggctttgtgtg | gggaagcatctgtagcaagc |
| *OATP2* | 358 | 58 | acccaagaggctgtctctca | gccaacagaaatgccttgat |
| *NTCP* | 387 | 60.5 | cctcagtgctttccttctgg | acagccacagagagggagaa |

Genes abbreviations are *CYP2B10*, cytochrome P450, family 2, subfamily b, polypeptide 10; *UGT1A1*, *UDP* glucuronosyltransferase family 1 member A1; *SULT2A1*, Sulfotransferase Family 2A; *CAR*, constitutive androstane receptor; *PXR*, pregnane X receptor; *FXR*, Farnesoid x receptor; *ABCG8*, ATP-binding cassette sub-family G member 8; *ASBT*, Apical Sodium Dependent Bile Acid Transporter; *MRP2*, Multidrug resistance-associated protein 2; *BSEP*, Bile Salt Export Pump; *OATP2*, organic anion-transporting polypeptide; *NTCP*, Sodium/Taurocholate Co-transporting Polypeptide.

## Results

*Therapeutic effect of curcumin, vitamin B6 and both on biochemical changes in lithocholic acid model of cholestasis*

As shown in Table 2, both curcumin and vitamin B6 groups showed slightly normal levels with no significant changes compared to control group. Feeding on lithocholic acid, increased AST, ALT, ALP, BIL-T, BIL-D and GGT compared to control group. All these increased parameters were significantly normalized after administration of curcumin, vitamin B6 or both of them in lithocholic acid model of cholestasis ($p<0.05$). However, cholesterol decreased significantly ($p<0.05$) in lithocholic acid fed mice (30±1.28) and restored after administration of curcumin (123±1.51), vitamin B6 (143±1.06) or both of them (104±2).

**Table 2.** Therapeutic effect of curcumin and vitamin B6 or both on biochemical changes in lithocholic acid model of cholestasis.

| Test \ Group | Control | Curcumin | Vit.B6 | Cur+Vit.B6 | Lithocholic A | Lith+Cur | Lith+Vit B6 | Lith+Cur+Vit B6 |
|---|---|---|---|---|---|---|---|---|
| AST (U/L) | 170 ±1.62 | 141 ±1.50 | 180 ±1.07 | 179 ±1.28 | 5718 ±3.31$^{\#}$ | 302 ±2.50$^{\#*}$ | 358 ±2.60$^{\#*}$ | 258 ±2.78$^{\#}$ |
| ALT (U/L) | 49 ±1.22 | 43 ±1.70 | 57 ±1.42 | 49 ±2.22 | 1695 ±3.11$^{\#}$ | 59 ±1.95$^{\#*}$ | 87 ±1.74$^{\#*}$ | 83 ±2.06$^{\#}$ |
| ALP (U/L) | 90 ±1.06 | 60 ±1.58$^{\#}$ | 50 ±1.36$^{\#}$ | 60 ±1.24$^{\#}$ | 140 ±2.13$^{\#}$ | 60 ±1.81$^{\#*}$ | 80 ±1.53$^{\#*}$ | 40 ±1.63$^{\#}$ |
| BIL-T (mg/dl) | 0.03 ±0.004 | 0.03 ±0.003$^{\#}$ | 0.05 ±0.003 | 0.02 ±0.002$^{\#}$ | 0.92 ±0.019$^{\#}$ | 0.42 ±0.016$^{\#*}$ | 0.12 ±0.010$^{\#*}$ | 0.09 ±0.005$^{\#}$ |
| BIL-D (mg/dl) | 0.05 ±0.005 | 0.04 ±0.005 | 0.05 ±0.003 | 0.06 ±0.005 | 0.53 ±0.083 | 0.03 ±0.005$^{\#*}$ | 0.12 ±0.005$^{\#*}$ | 0.22 ±0.010$^{\#}$ |
| Cholesterol (mg/dl) | 101 ±1.80 | 84 ±1.46$^{\#}$ | 132 ±1.65 $^{\#}$ | 98 ±1.51$^{\#}$ | 30 ±1.28 $^{\#}$ | 123 ±1.5$^{*}$ | 143 ±1.06$^{\#*}$ | 104 ±2 |
| GGT (U/L) | 8 ±0.24 | 10 ±0.50$^{\#}$ | 9 ±0.31$^{\#}$ | 10 ±0.37$^{\#}$ | 65 ±1.36$^{\#}$ | 18 ±0.86$^{\#*}$ | 26 ±1.30$^{\#*}$ | 15 ±0.37 |

Values are means ± standard error (SEM) for 3 independent experiments per each treatment. Values are statistically significant at #$p < 0.05$ Vs.control; *$p<0.05$ Vs. lithocholic acid.

 All rights reserved 2007.

*Histopathological findings*

Livers of control, curcumin, vitamin B6 or both treatment groups showed normal tissue architecture with normal hepatic lobules, central veins and hepatic sinusoids (Fig. 1A, 1B, 1C and 1D respectively). Liver of lithocholic acid group showed multiple necrotic foci of different sizes spread all over the liver with congestion of hepatic blood vessels (Fig. 1E). Liver of lithocholic acid group treated with curcumin showed regeneration of hepatic tissue with multifocal hydropic degeneration (Fig. 1F). Liver of lithocholic acid group treated with vitamin B6 showed normal hepatic tissue except for minute necrotic foci in some areas with congestion of portal vein (Fig. 1G). Liver of lithocholic acid group treated with curcumin and vitamin B6 showed mostly normal hepatic tissue (Fig. 1H). Number and size of the necrotic foci are shown in Table 3.

*Immunohistochemical expression of glutathione and* NF-kB

Livers of control, curcumin, vitamin B6 or both treatment groups showed mild expression of glutathione in hepatic tissue (Fig. 2A, 2B, 2C and 2D respectively). Liver of lithocholic acid group showed mild expression of glutathione in hepatic tissue surrounding necrotic foci (Fig. 2E). Liver of lithocholic acid group treated with curcumin showed strong expression of glutathione all over the hepatic tissue (Fig. 2F). Liver of lithocholic acid group treated with vitamin B6 showed strong expression of glutathione in some areas of hepatic tissue, still other areas had weak or negative expression (Fig. 2G). Liver of lithocholic acid group treated with curcumin and vitamin B6 showed strong expression of glutathione all over the hepatic tissue (Fig. 2H).

Livers of control, curcumin, vitamin B or both treatment groups showed mild or no expression of *NF-kB* in hepatic tissue (Fig. 3A, 3B, 3C and 3D respectively). Liver of lithocholic acid group showed moderate expression of *NF-kB* in hepatic tissue surrounding necrotic foci (Fig. 3E). Liver of lithocholic acid group treated with curcumin showed strong expression of *NF-kB* all over the hepatic tissue especially around central veins (Fig. 3F). Liver of lithocholic acid group treated with vitamin B6 showed strong expression of *NF-kB* in some areas of hepatic tissue, still other areas have weak or no expression (Fig. 3G). Liver of lithocholic acid group treated with curcumin and vitamin B6 showed strong expression of *NF-kB* all over the hepatic tissue (Fig. 3H).

*Therapeutic effects of curcumin, vitamin B6 or both of them on regulatory nuclear receptors of bile acid (*PXR, FX receptor *and* CAR*) in lithocholic acid model of cholestasis*

No significant change was detected in PXR and FXR expressions in groups 1, 2, 3 and 4, meanwhile expression of CAR was downregulated in group 2, 3 and 4 compared to control group. In cholestatic mice, there was a significant downregulation ($p<0.05$) in mRNA expressions of *PXR*, *FXR* and *CAR* (Fig. 4D 5A and 5B, respectively) as compared with control group. Cholestatic mice treated with curcumin, vitamin B6 or both treatment showed significant ($p<0.05$) upregulation in mRNA expressions of *PXR*, *FX receptor* and *CAR* toward the normal expressions levels.

*Therapeutic effects of curcumin, vitamin B6 or both of them on bile acid/organic anion and lipid transporters* (OATP2, BSEP, NTCP, ASBT, MRP2 *and* ABCG8) *in lithocholic acid model of cholestasis*

As presented in Figures 5C, 5D, 6B, 6C and 6D, only *OATP2* expression was upregulated in curcumin and vitamin B6 group when compared to control. Curcumin downregulated *BSEP* expression, meanwhile curcumin and vitamin B6 upregulated it. Vitamin B6 & curcumin and vitamin B6 groups showed significant increase in mRNA expression of *NTCP*. Curcumin & curcumin and vitamin B6 downregulated mRNA expression of *ASBT* when compared to control. Both curcumin group and vitamin B6 group downregulated mRNA of *MRP2* in comparison to control. Curcumin, vitamin B6 & curcumin and vitamin B6 downregulated mRNA expression of *ABCG8* when compared to control. Induction of cholestasis in mice with lithocholic acid induced a significant downregulation ($p<0.05$) in mRNA expressions of *OATP2*, *BSEP*, *ASBT*, *MRP2* and *ABCG8*, respectively compared to control group. However, *NTCP* mRNA expression was increased significantly ($p<0.05$) in cholestatic mice compared to control mice (Fig. 6A). Regarding the observed downregulation in mRNA expressions of *OATP2*, *BSEP*, *ASBT*, *MRP2* and *ABCG8*, administration of curcumin, vitamin B6 and both of them restore their expressions significantly compared to cholestatic mice.

**Table 3.** Number and diameter (µm) of the necrotic foci in different groups.

| Group / Necrotic foci | 1 | 2 | 3 | 4 | 5 | 6 | 7 | 8 |
|---|---|---|---|---|---|---|---|---|
| Number (per low power field) | 0 | 0 | 0 | 0 | 3-4 | 0-1 | 0-1 | 0-1 |
| Diameter (µm) | 0 | 0 | 0 | 0 | 150-300 | 50-100 | 50-100 | 10-50 |

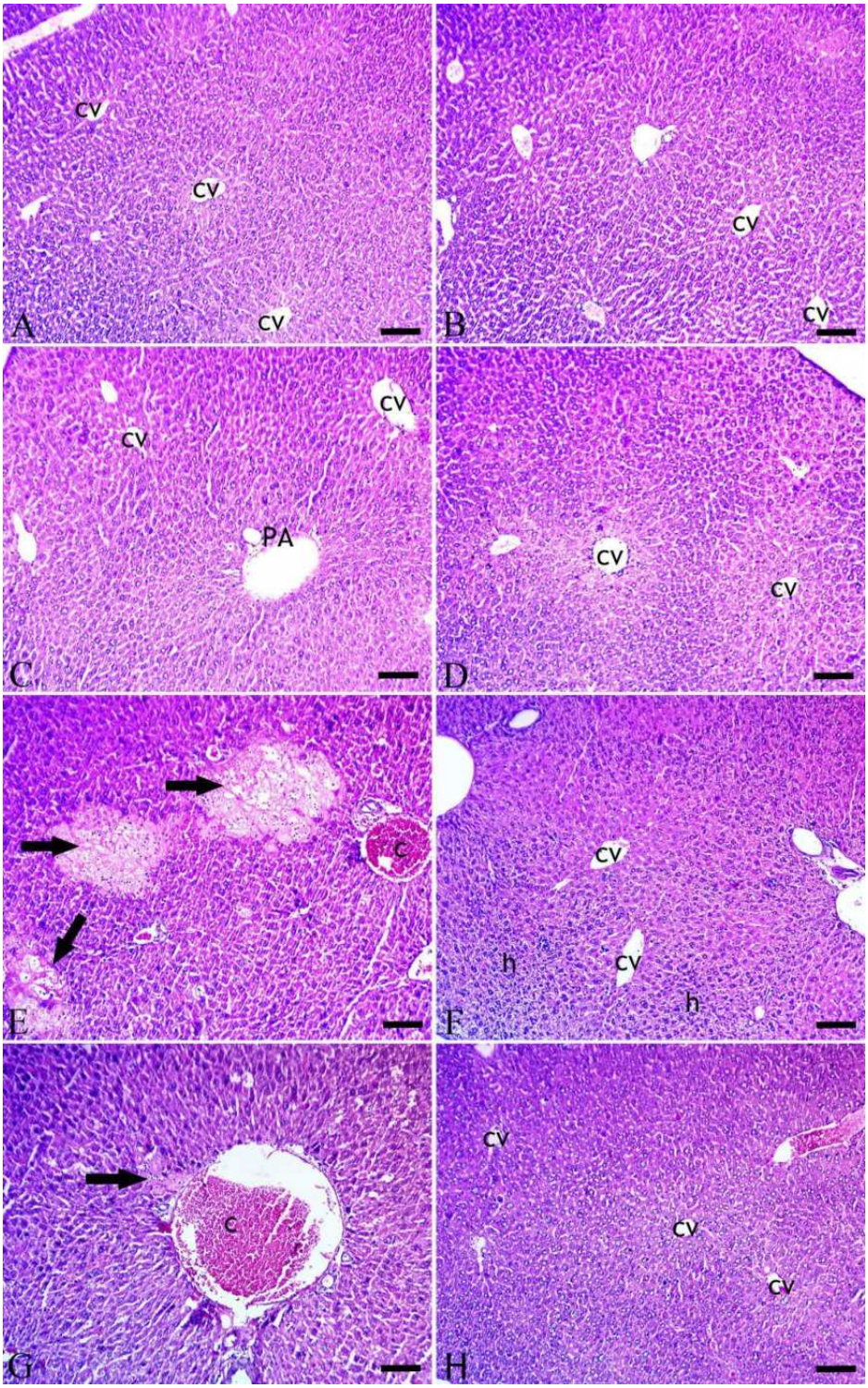


**Figure 1. A. B. C. D.** Livers of control, curcumin, vitamin B6 and curcumin & vitamin B groups respectively with normal tissue architecture with normal hepatic lobules, central6 veins (CV), hepatic sinusoids and portal areas (PA). **E.** Liver of lithocholic acid group with multiple necrotic foci (arrows) of different sizes spreaded all over the liver with congestion of hepatic blood vessels (**C**). **F.** Liver of lithocholic acid group treated with curcumin showed healing of hepatic tissue especially around central veins (CV) with hydropic degeneration of some areas (**H**). **G**. Liver of lithocholic acid group treated with vitamin B6 showed normal hepatic tissue except for minute necrotic foci (arrow) in some areas with congestion of portal vein. **H.** Liver of lithocholic acid group treated with curcumin and vitamin B6 showed mostly normal hepatic tissue. H&E, scale bar=100 µm.

## Discussion

The results of the present study clearly highlights the therapeutic effects of curcumin, vitamin B6 or both of them on LCA model of cholestasis and liver injury in mice. This was evidenced by liver morphology as well as the significant decrease in serum ALT, AST, ALP, GGT, total and direct bilirubin with restortion of cholesterol levels together with increased tissue expression of glutathione and *NF-kB*. Elevated serum GGT enzyme activity has been widely used as a marker of liver dysfunction (2). Other experimental findings have shown that GGT plays a crucial role in cellular antioxidant defense systems (20). Higher levels of ALT, AST and ALP may suggest inflammation of liver cells or the death of some cells due to liver damage as in lithocholic acid group. Cotreatment with curcumin and/or vitamin B6 ameliorates the changes caused by lithocholic acid. This could be due to the antioxidant activities of curcumin and relatively vitamin B6. Curcumin exhibit a differential antioxidant activity in several in vitro and in vivo models, for example, preventing lipid peroxidation in a variety of cells together with its ability to react directly with reactive species and to induce an upregulation of various cytoprotective and antioxidant proteins (32). Vitamin B6 may directly react with the peroxy radicals and thereby scavenge radicals and inhibit lipid peroxidation and may indirectly play an antioxidant role by serving as coenzyme in the glutathione antioxidant defense system (17). Higher tissue expression of glutathione was detected in treated groups when compared to control and lithocholic acid groups. Glutathione (GSH) is often referred to as the "master antioxidant," and has a major role in protection against oxidative stress and removal of xenobiotics (5). Histopathological results confirmed previous results, that feeding of high levels of LCA caused focal hepatic necrosis (11). This necrotic pattern is caused by the precipitation of hydrophobic LCA or its metabolites in cholangioles resulting in obstruction of biliary flow. Number and size of the necrotic foci were increased in LCA group with reduction in treated groups, especially curcumin and vitamin B6 group. The focal nature of the liver damage is attributed to the increased biliary pressure during obstructive cholestasis which results in rupture of cholangioles causing the leakage of bile back into the parenchyma (12). The nuclear factor kappa B (*NF-κB*) is a critical regulator of immune and inflammatory processes and is involved in cellular responses to stimuli (23). It can be activated by porinflammatory cytokines and endotoxins and then translocate to the nucleus to promote transcription of inflammatory mediators, regulates inducible gene expression under both physiological and pathological conditions. *NF-κB* plays a key regulatory role in controlling Th1 and Th2 immune responses (16). Mild or no expression of *NF-kB* was detected in hepatic tissue of control, curcumin, vitamin B6 or curcumin & vitamin B6 groups. Liver of lithocholic acid group showed moderate expression of *NF-kB* in hepatic tissue surrounding necrotic foci. Activation of *NF-κB* in treated groups (mainly curcumin and curcumin and vitamin B6 and to lesser degree the vitamin B6 group alone) could be attributed to its role in activating genes related to cell survival or cellular proliferation (16).

Administration of curcumin mainly, vitamin B6 and both of them result in stimulation of major hepatic bile acid/bilirubin metabolizing and detoxifying enzymes and hepatic major alternative excretory pumps, results that are adapted to counteract cholestasis. Our results showed that *CAR* expression was downregulated in group 2, 3 and 4 as compared to control group and was severely reduced in LCA group. Slight restoration of *CAR* expression was detected in curcumin /or vitamin B6 treated groups. Activation of the constitutive androstane receptor (*CAR*) can be a result of LCA administration to protect the liver against bile acid-induced toxicity (36). No significant change was detected in expressions of *PXR* and *FXR* in groups 2, 3 and 4 when compared to control. Severe reduction of *PXR* expression was detected in LCA group with elevation of gene expression in treated groups. Activation of *CAR* and the *pregnane X receptor* (*PXR*) can protect the liver against bile acid-induced cholestasis via up-regulation of bile acid metabolizing genes such as *Sult2A* (31). Also other studies showed significant degree of hepatocellular injury observed in the absence of *CAR* (*CAR*-null mice) (4). *FXR* expression showed significant reduction in LCA group in comparison to control group, this reduction was ameliorated in treated groups especially the combined group. Other studies showed that the expression of detoxification enzymes *SULT2A1* and canalicular membrane transporters *ABCG8* were significantly down-regulated in obstructive cholestatic patients, and were significantly and positively correlated with *FXR* reduction suggesting that targeted down-regulation of *FXR* may improve the hepatic detoxification ability in human obstructive cholestasis (4).

Administration of of vitamin B6 downregulated expression of *UGT1A1,* meanwhile curcumin and vitamin B6 upregulated it. Administration of curcumin and/or vitamin B6 downregulated *SULT2A1* expression. Both Vitamin B6 & curcumin and vitamin B6 significantly downregulated *CYP2B1,0* in comparison to control group. Expression of bile acid metabolizing enzymes and transporters (*UGT1A1*, *SULT2A*, *CYP2B10*) was also declined in LCA group with elevation of expression in treated groups especially curcumin group and both curcumin and vitamin B6 treated group.

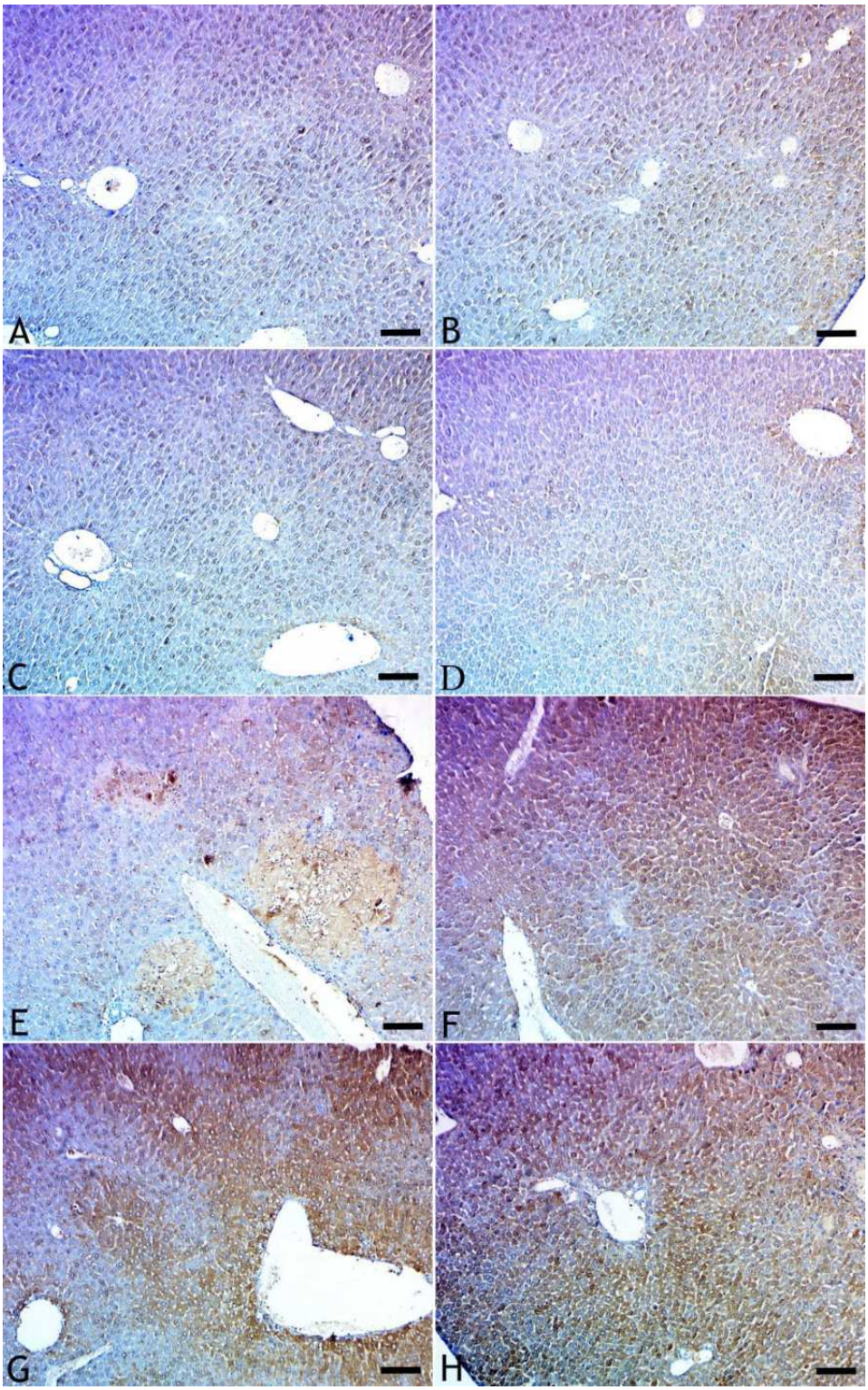


**Figure 2.** Immunohistochemical examination of glutathione expression. **A. B. C. D.** Livers of control, curcumin, vitamin B and curcumin & vitamin B groups respectively. Mild expression of glutathione in hepatic tisuue. **E.** Liver of lithocholic acid group showed mild expression of glutathione in the hepatic tissue surrounding necrotic foci. **F.** Liver of lithocholic acid group treated with curcumin showed strong diffuse expression of glutathione. **G.** Liver of lithocholic acid group treated with vitamin B6 showed strong expression of glutathione in some areas of hepatic tissue, still other areas had weak or negative expression. **H.** Liver of lithocholic acid group treated with curcumin and vitamin B6 showed strong diffuse expression of glutathione. Immunohistochemistry, DAB, Hematoxylin counter stain, scale bar=100 µm.

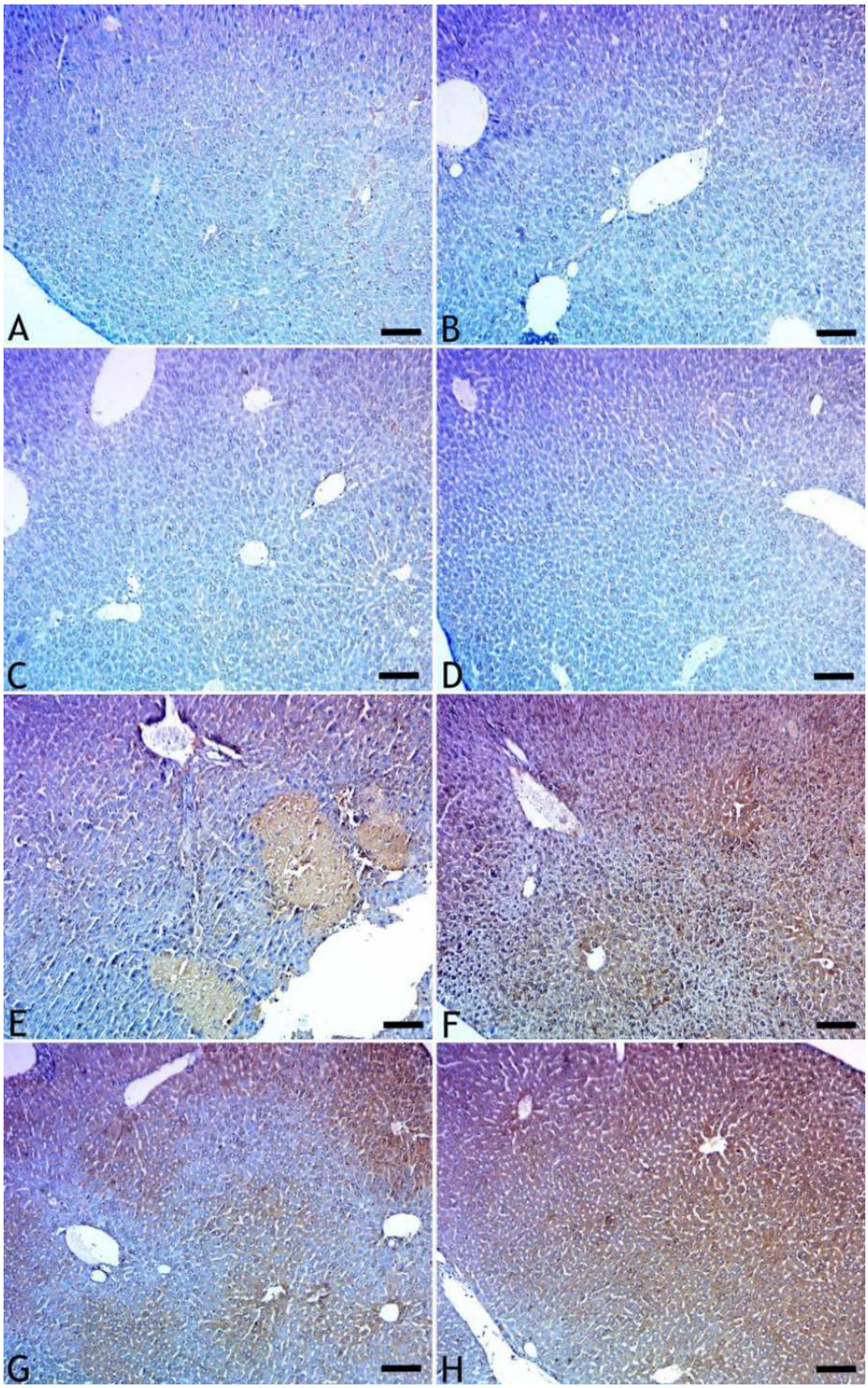


**Figure 3.** Immunohistochemical examination of *NF-kB* expression. **A. B. C. D.** Livers of control, curcumin, vitamin B6 and curcumin & vitamin B6 groups respectively.Mild or no expression of NF-kB in hepatic tisuue. **E.** Liver of lithocholic acid group showed moderate expression of *NF-kB* in hepatic tissue surrounding necrotic foci. **F.** Liver of lithocholic acid group treated with curcumin showed strong diffuse expression of NF-kB, especially around central veins. **G.** Liver of lithocholic acid group treated with vitamin B6 showed strong expression of *NF-kB* in some areas of hepatic tissue, still other areas have weak or negative expression. **H.** Liver of lithocholic acid group treated with curcumin and vitamin B6 showed strong diffuse expression of *NF-kB*. Immunohistochemistry, DAB, Hematoxylin counter stain, scale bar=100 µm.

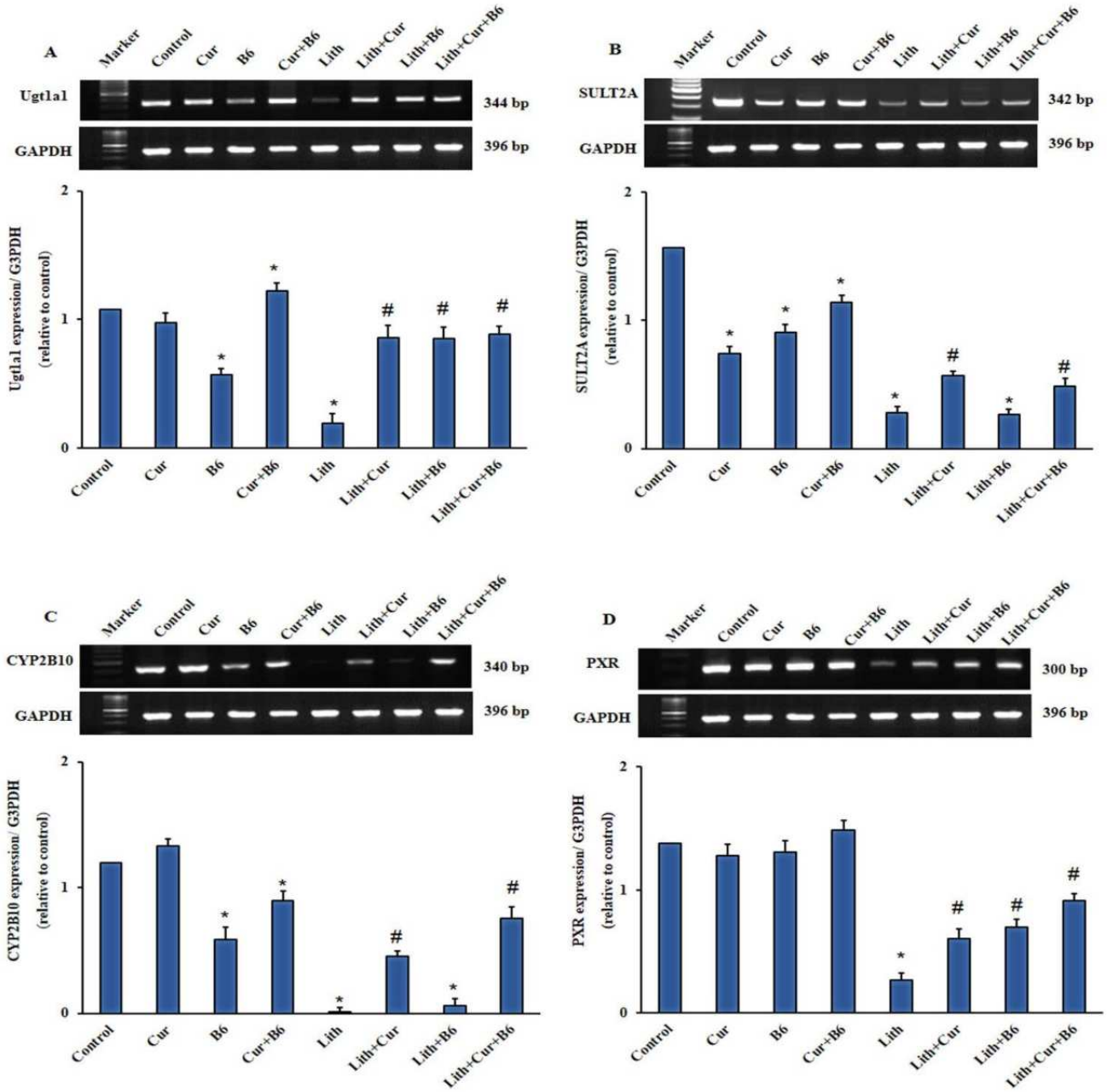


**Figure 4.** Semi-quantitative RT-PCR analysis of **A.** *UGT1A1*, **B.** *SULT2A1*, **C.** *CYP2B10* and **D.** *PXR* mRNA expressions and their corresponding *G3PDH* in liver. Experimental groups were left as a control (CTR), administered curcumin (CUR), vitamin B6 (B6), or curcumin plus vitamin B6 (CUR+B6), lithocholic acid (Lith), lithocholic acid treated with curcumin (Lith+Cur), lithocholic acid treated with vitamin B6 (Lith+B6), lithocholic acid treated with curcumin and vitamin B6 (Lith+Cur+B6) as described in materials and methods. Values are means ± SEM obtained from 3 independent experiments. P*< 0.05 vs. control group, and P#< 0.05 vs. lithocholic acid administered group.

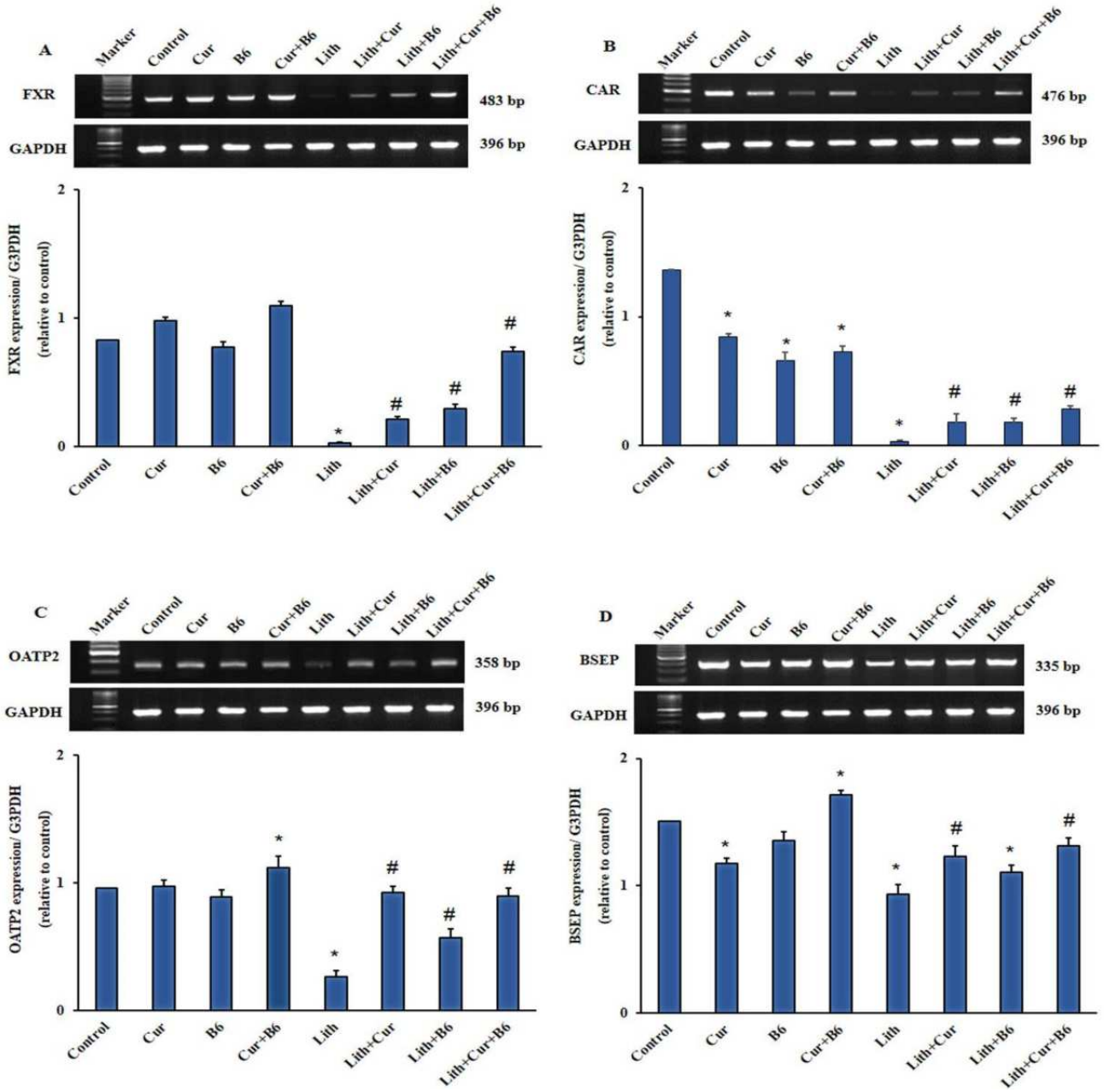


**Figure 5.** Semi-quantitative RT-PCR analysis of **A.** FXR, **B.** CAR, **C.** OATP2 and **D.** BSEP mRNA expressions and their corresponding G3PDH in liver. Experimental groups were left as a control (CTR), administered curcumin (CUR), vitamin B6 (B6), or curcumin plus vitamin B6 (CUR+B6), lithocholic acid (Lith), lithocholic acid treated with curcumin (Lith+Cur), lithocholic acid treated with vitamin B6 (Lith+B6), lithocholic acid treated with curcumin and vitamin B6 (Lith+Cur+B6) as described in materials and methods. Values are means ± SEM obtained from 3 independent experiments. P*<0.05 vs. control group, and P#< 0.05 vs. lithocholic acid administered group.

These metabolizing enzymes and transporters participate in bile acid elimination, including cytochrome (*CYP2B10*, *UGT1A1*, *SULT2A1*), bile salt export pump (*BSEP*), multidrug resistance-associated protein (*MRP 2*, *NTCP*, *Oatp2*), and organic solute transporter β (7). Nuclear receptors and transcription factors, such as pregnane X receptor (*PXR*), farnesoid X receptor, constitutive androstane receptor can regulate these genes and are considered potential therapeutic targets of cholestasis (30,38). *PXR* and its human homolog (steroid and xenobiotic receptor) are known to induce *UGT1A1* expression (8). So increased expression of the nuclear receptors and transcription factors in treated groups led subsequently to activation of bile acid metabolizing enzymes and transporters. *UGT1A1* when activated

mediates the glucuronidation of bilirubin, which makes it more hydrophilic and prone to excretion (6).

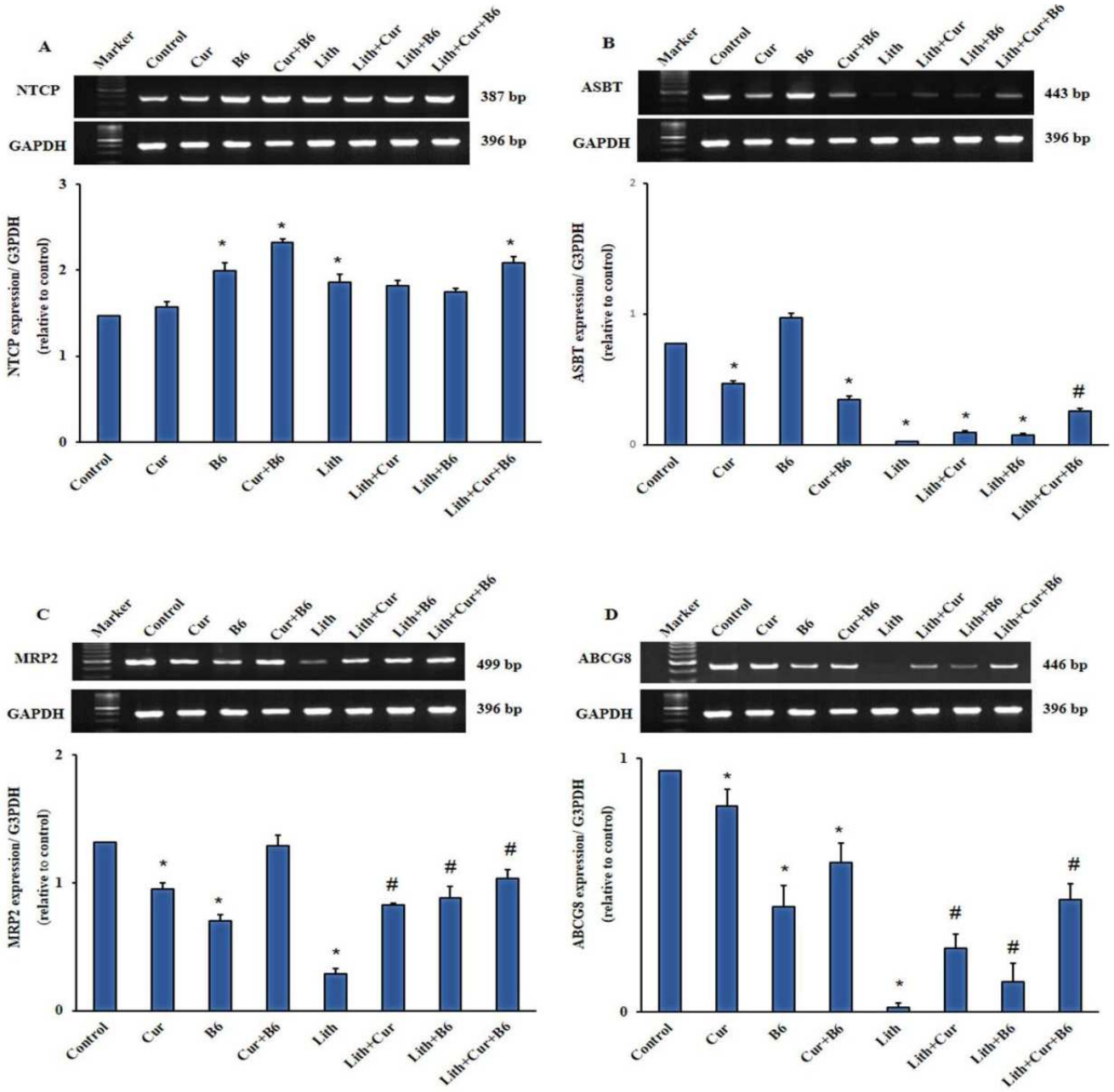


**Figure 6.** Semi-quantitative RT-PCR analysis of **A.** NTCP, **B.** ASBT, **C.** MRP2 and **D.** ABCG8 mRNA expressions and their corresponding G3PDH in liver. Experimental groups were left as a control (CTR), administered curcumin (CUR), vitamin B6 (B6), or curcumin plus vitamin B6 (CUR+B6), lithocholic acid (Lith), lithocholic acid treated with curcumin (Lith+Cur), lithocholic acid treated with vitamin B6 (Lith+B6), lithocholic acid treated with curcumin and vitamin B6 (Lith+Cur+B6) as described in materials and methods. Values are means ± SEM obtained from 3 independent experiments. P*< 0.05 vs. control group, and P#< 0.05 vs. lithocholic acid administered group.

Only expression of *OATP2* was upregulated in curcumin and vitamin B6 group when compared to control. Curcumin downregulated *BSEP* expression, meanwhile curcumin and vitamin B6 upregulated it. Vitamin B6 & curcumin and vitamin B6 groups showed significant increase in mRNA expression of *NTCP*. Curcumin and curcumin and vitamin B6 downregulated mRNA expression of *ASBT* when compared to control. Both curcumin group and vitamin B6 group downregulated mRNA of *MRP2* in comparison to control. All treatment groups showed downregulated *ABCG8* mRNA expression, when compared to control. Although variability in

expression of different genes in healthy state, there was an obvious normalization in treated groups, after significant downregulation in LCA group. Expression of bile acid and lipid transporters (*Oatp2, Bsep, Mrp2, Abcg8, Asbt*) was reduced in LCA group with partial restoration of genetic expression in treated groups. Expression of NTCP elevated in LCA group in comparison to control group. Bile acids are taken up from the sinusoidal blood into hepatocytes by the uptake transport proteins sodium taurocholate cotransporting polypeptide (*NTCP*) and organic anion transporting polypeptides (*OATP*s) (9). At the canalicular membrane, bile acids are excreted into bile predominantly via the bile salt export pump (*BSE*P) in an ATP-dependent manner. Multidrug resistance-associated protein 2 (*MRP2*), which is the main driving force for bile salt-independent bile flow through canalicular excretion of reduced glutathione, also transports glucuronide and sulfate conjugates of bile acids. Cholangiocytes (bile duct epithelial cells) also express ion and organic anion transporters on the apical (i.e. *ASBT*, *OATP1A2*) and basolateral membranes that modify the composition of bile before it passes into the larger bile ducts (9).

## Conclusion

In conclusion, induction of hepatic detoxification enzymes and alternative efflux systems after treatment with curcumin mainly, vitamin B6 and both of them in case of cholestasis may limit accumulation of toxic biliary compounds in hepatic cells.

## Acknowledgements

The authors would like to acknowledge and thank the Deans of Scientific Research Affairs in Taif University, Saudi Arabia for financial support of this study (project number 5169-437-1).

## References

1. Aggarwal BB, Sundaram C, Malani N, Ichikawa H. Curcumin: the Indian solid gold. Adv Exp Med Biol. 2007;595:1-75.
2. Arinc H, Sarli B, Baktir AO, Saglam H, Demirci E, Dogan Y, Kurtul S, Karaman H, Erden A, and Karaman A. Serum gamma glutamyl transferase and alanine transaminase concentrations predict endothelial dysfunction in patients with non-alcoholic steatohepatitis. Ups J Med Sci. 2013;118:228-34.
3. Barzegar A, Moosavi-Movahedi AA. Intracellular ROS protection efficiency and free radical-scavenging activity of curcumin. PLoS One. 2011;6:1-7.
4. Beilke LD, Aleksunes LM, Olson ER, Besselsen DG, Klaassen CD, Dvorak K, Cherrington NJ. Decreased apoptosis during car-mediated hepatoprotection against lithocholic acid-induced liver injury in mice. Toxicol Lett. 2009;188:38-44.
5. Bilinsky LM, Reed MC, Nijhout HF. The Role of Skeletal Muscle in Liver Glutathione Metabolism During Acetaminophen Overdose. J Theor Biol. 2015;376:118-33.
6. Bock KW. Human UDP-glucuronosyltransferases: feedback loops between substrates and ligands of their transcription factors. Biochem Pharmacol. 2012;84:1000-6.
7. Chai J, Feng X, Zhang L, Chen S, Cheng Y, He X, Wang H, Wang R, Chen W. Hepatic Expression of Detoxification enzymes is decreased in human obstructive cholestasis due to gallstone biliary obstruction. PLoS One. 2015;10:1-14.
8. Chen C, Staudinger JL, and Klaassen CD. Nuclear receptor, pregnane X receptor, is required for induction of UDP-glucuronosyltranferases in mouse liver by pregnenolone-16 alpha-carbonitrile. Drug Metab Dispos. 2003;31:908-15.
9. Dawson PA, Lan T, Rao A. Bile acid transporters. Journal of Lipid Research. 2009;50:2340-57.
10. El-kirdasy AF, Nassan MA, Baiomy AA, Ismail TA, Soliman MM, Attia HF. Potential ameliorative role of N-acetylcysteine against testicular dysfunction induced by titanium dioxide in male albino rats. Am J Pharmacol Toxicol. 2014;9:29-38.
11. Fickert P, Fuchsbichler A, Marschall HU, Wagner M, Zollner G, Krause R, Zatloukal K, Jaeschke H, Denk H, Trauner M. Lithocholic acid feeding induces segmental bile duct obstruction and destructive cholangitis in mice. Am J Pathol. 2006;168:410-22.
12. Fickert P, Zollner G, Fuchsbichler A, Stumptner C, Weiglein AH, Lammert F, Marschall HU, Tsybrovskyy O, Zatloukal K, Denk H, Trauner M. Ursodeoxycholic acid aggravates bile infarcts in bile duct-ligated and Mdr2 knockout mice via disruption of cholangioles. Gastroenterology. 2002;123:1238-51.
13. Ghonem NS, Assis DN, Boyer JL. Fibrates and cholestasis. Hepatology. 2015;62:635-43.
14. Graf D, Kurz AK, Reinehr R, Fischer R, Kircheis G, Häussinger D. Prevention of bile acid-induced apoptosis by betaine in rat liver. Hepatology. 2002;36:829-39.
15. Gujral JS, Farhood A, Bajt ML, Jaeschke H. Neutrophils aggravate acute liver injury during obstructive cholestasis in bile duct-ligated mice. Hepatology. 2003;38:355-63.
16. Hadfield KA, McCracken SA, Ashton AW, Nguyen TG, Morris JM. Regulated suppression of *NF-κB* throughout pregnancy maintains a favourable cytokine environment necessary for pregnancy success. J Reprod Immunol. 2011;89:1-9.
17. Hsu C, Cheng C, Hsu C, Lee W, Huang S, Huang Y. Role of vitamin B6 status on antioxidant defenses, glutathione, and related enzyme activities in mice with

homocysteine-induced oxidative stress. Food Nutr Res. 2015;59:1-7.
18. Ibrahim, ZS, Nassan MA, Soliman MM. Ameliorative effects of pomegranate on carbon tetrachloride hepatotoxicity in rats: A molecular and histopathological study. Mol Med Rep. 2016;13:3653-60.
19. Kannan K, Jain SK. Effect of vitamin B6 on oxygen radicals, mitochondrial membrane potential, and lipid peroxidation in H2O2-treated U937 monocytes. Free Radic Biol Med. 2004;36:423-8.
20. Karp DR, Shimooku K, Lipsky PE. Expression of gamma-glutamyl transpeptidase protects ramos B cells from oxidation-induced cell death. J Biol Chem. 2001;276:3798–804.
21. Keles M, Al B, Gumustekin K, Demircan B, Ozbey I, Akyuz M, Yilmaz A, Demir E, Uyanik A, Ziypak T, Taysi S. Antioxidant status and lipid peroxidation in kidney tissue of rats fed with vitamin B6-deficient diet. Ren Fail. 2010;32:618-22.
22. Licata LA, Nguyen CT, Burga RA, Falanga V, Espat NJ, Ayala A, Thorn M, Junghans RP, Katz SC. Biliary obstruction results in PD-1-dependent liver T cell dysfunction and acute inflammation mediated by Th17 cells and neutrophils. J Leukoc Biol. 2013;94:813-23.
23. McCracken SA, Gallery E, Morris JM. Pregnancy-specific down-regulation of *NF-kappa B* expression in T cells in humans is essential for the maintenance of the cytokine profile required for pregnancy success. J Immunol. 2004;172:4583-91.
24. Okazaki Y, Utama Z, Suidasari S, Zhang P, Yanaka N, Tomotake H, Sakaguchi E, Kato N. Consumption of vitamin B(6) reduces fecal ratio of lithocholic acid to deoxycholic acid, a risk factor for colon cancer, in rats fed a high-fat diet. J Nutr Sci Vitaminol (Tokyo). 2012;58:366-70.
25. Perez MJ, Briz O. Bile-acid-induced cell injury and protection. World J Gastroenterol. 2009;15:1677–89.
26. Ridlon JM, Kang DJ, and Hylemon PB. Bile salt biotransformations by human intestinal bacteria. J Lipid Res. 2006;47:241-59.
27. Rodrigues CM, Steer CJ. Mitochondrial membrane perturbations in cholestasis. J Hepatol. 2000;32:135-41.
28. Selhub J, Byun A, Liu Z, Mason JB, Bronson RT, Crott JW. Dietary vitamin B6 intake modulates colonic inflammation in the IL10-/- model of inflammatory bowel disease. J Nutr Biochem. 2013;24:2138-43.
29. Smith A, Oertle J, Prato D. Multiple Actions of Curcumin Including Anticancer, Anti-Inflammatory, Antimicrobial and Enhancement via Cyclodextrin. J Cancer Ther. 2015;6:257-72.
30. Tan KP, Wood GA, Yang M, and Ito S. Participation of nuclear factor (erythroid 2-related), factor 2 in ameliorating lithocholic acid-induced cholestatic liver injury in mice. Br J Pharmacol. 2010;161:1111-21.
31. Teng S, Piquette-Miller M. Hepatoprotective role of PXR activation and MRP3 in cholic acid-induced cholestasis. Br J Pharmacol. 2007;151:367-76.
32. Trujillo J, Chirino YI, Molina-Jijón E, Andérica-Romero AC, Tapia E, Pedraza-Chaverrí J. Renoprotective effect of the antioxidant curcumin: Recent findings. Redox Biology. 2013;1:448-56.
33. Wang BF, Cui ZW, Zhong ZH, Sun YH, Sun QF, Yang GY, Bian LG. Curcumin attenuates brain edema in mice with intracerebral hemorrhage through inhibition of AQP4 and AQP9 expression. Acta Pharmacol Sin. 2015;36:939-48.
34. Woolbright BL, Jaeschke H. Therapeutic Targets for Cholestatic Liver Injury. Expert Opin Ther Targets. 2016;20:463-75.
35. Yang K, Köck K, Sedykh A, Tropsha A, Brouwer KLR. An Updated Review on Drug-Induced Cholestasis: Mechanisms and Investigation of Physicochemical Properties and Pharmacokinetic Parameters. J Pharm Sci. 2013;102:3037-57.
36. Zhang J, Huang W, Qatanani M, Evans RM, and Moore DD. The constitutive androstane receptor and pregnane X receptor function coordinately to prevent bile acid-induced hepatotoxicity. J Biol Chem. 2004;279:49517-22.
37. Zhang Y, Hong JY, Rockwell CE, Copple BL, Jaeschke H, Klaassen CD. Effect of bile duct ligation on bile acid composition in mouse serum and liver. Liver Int. 2012;32:58-69.
38. Zollner G, Wagner M, and Trauner M. Nuclear receptors as drug targets in cholestasis and drug-induced hepatotoxicity. Pharmacol Ther. 2010;126:228-43.