Braz J Vet Pathol, 2018, 11(2), 64 – 67.
DOI: 10.24070/bjvp.1983-0246.v11i2p64-67

BJVP
Brazilian Journal of Veterinary Pathology
ISSN 1983-0246

Case Report

Metastatic oral squamous cell carcinoma in a captive common hippopotamus (*Hippopotamus amphibius*)

Ayisa R. de Oliveira[1], Alexandre Arenales[1], Thaynara P. de Carvalho[1], Angela T. Pessanha[2], Herlandes P. Tinoco[2], Maria Elvira L. T. da Costa[2], Tatiane A. da Paixão[3], Renato L. Santos[1*]

[1]Departamento de Clínica e Cirurgia Veterinárias, Escola de Veterinária, Universidade Federal de Minas Gerais, 31270-901, Belo Horizonte, Minas Gerais, Brazil.
[2]Departamento de Jardim Zoológico, Fundação de Parques Municipais e Zoobotânica de Belo Horizonte", 31365-450, Belo Horizonte, Minas Gerais, Brazil.
[3]Departamento de Patologia Geral, Instituto de Ciências Biológicas, Universidade Federal de Minas Gerais, 31279-901, Belo Horizonte, Minas Gerais, Brazil.
***Corresponding author:** Departamento de Clínica e Cirurgia Veterinária, Escola de Veterinária, Universidade Federal de Minas Gerais, Av. Presidente Antônio Carlos, 6627 – CEP 30161-970, Belo Horizonte, MG, Brazil. Fone: 55-31-3409-2239. Fax: 55-31-3409-2230. E-mail: rsantos@vet.ufmg.br

Submitted Feb, 5th 2018, Accepted March, 9th 2018

Abstract

Reported cases of neoplasia affecting hippopotamus are very scarce. This report describes a metastatic oral squamous cell carcinoma in a captive 44-year-old male common hippopotamus (*Hippopotamus amphibius*) that developed progressive loss of appetite, fibrinohemorrhagic oral discharge, and progressive weight loss. Gross, cytological, and histopathological findings were compatible with a conclusive diagnosis of an invasive oral squamous cell carcinoma with metastasis in the lung, adrenal, and spleen. To the best of our knowledge this is the first report of squamous cell carcinoma in a common hippopotamus.

Key words: neoplasia, wild animals, wild ungulates, zoo.

Introduction

Hippopotami are ungulate and pseudo-ruminant animals belonging to the family Hippopotamidae, which is composed of two species: the common hippopotamus (*Hippopotamus amphibius*) and the pygmy hippopotamus (*Choeropsis liberiensis*) (6, 9, 12). Common hippopotami are naturally found in rivers, lakes, and wetlands in sub-Saharan Africa and are considered to be vulnerable species according to the International Union for Conservation of Nature (IUCN) (6, 9). In the wild, these animals live from 35 to 50 years, with extended life expectancy for up to 61 years in captivity. They usually weight between 2,500 and 3,000 kg (9).

There are few reports of diseases affecting captive hippopotamus, which may be related to the challenging conditions for diagnosing diseases in these animals, requiring conditioning and adequate chemical restraint (9). Reports of neoplasms affecting the common hippopotamus are even more scarce, with a few cases described, including a systemic histiocytic sarcoma (1), a metastatic adenocarcinoma of unknown origin (13), a thyroid adenoma (14), and two cases of pheochromocytoma (2, 3). Our goal is to describe the first reported case of a metastatic oral squamous cell carcinoma in a common hippopotamus raised in captivity at the Zoo-Botanic Foundation in Belo Horizonte, Brazil.

Case report

A captive male 44-year-old, common hippopotamus (*Hippopotamus amphibius*), had a history of progressive loss of appetite, with fibrinous and bloody oral discharge, and progressive weight loss. Clinically, there

 All rights reserved 2007.

Braz J Vet Pathol, 2018, 11(2), 64 – 67.
DOI: 10.24070/bjvp.1983-0246.v11i2p64-67

was an ulcerative lesion adjacent to the mandibular molars on the left side. The animal was treated with anti-inflammatory and a topical antiseptic, but lost condition and died before a definitive diagnosis was established and a specific treatment could be initiated.

Necropsy was performed four hours after death. Grossly, in the oral cavity, there was a 15 x 10 cm soft ulcerative exophytic proliferation, with a putrid odor and irregular surface extending from the left jugal to gingival mandibular mucosa and adjacent to the second and the absent third molar (Fig. 1). In the lungs there were randomly and diffusely distributed multiple well-defined soft nodules, ranging from 1 to 4 cm in diameter, and a whitish and friable cutting surface (Fig. 2), with moderate amounts of blood clots within bronchia. The spleen had multiple 2-5 cm nodules, which were poorly delimited and more friable than those observed in the lungs. The left adrenal was enlarged and had a nodular growth at the cut surface, replacing the medullary region and part of the cortex, with 6 cm in diameter and the same gross appearance as the splenic nodules. Throughout the entire gastrointestinal tract there was moderate amount of digested blood. Additionally, there was a generalized and marked paleness of the subcutaneous tissue, mucosae and serosae of all abdominal organs.

During necropsy, samples were taken for cytological examination by performing imprints of the oral lesion and splenic nodules, which were stained with Diff-Quick. Cytological preparations from both oral cavity and spleen contained high numbers of epithelial squamous cells, arranged in large cellular aggregates. The cells had abundant cytoplasm, with large round to oval nuclei, and prominent central nucleolus (Fig. 3). There were moderate anisokaryosis, and rare mitotic figures.

Samples of the oral mucosa, spleen, liver, stomach, adrenal, thyroid, small and large intestines, urinary bladder, lungs, heart, and lymph nodes were fixed in 10% buffered formalin, submitted for routine histological processing, stained with hematoxylin and eosin (HE) and evaluated by light microscopy. Microscopically, the oral lesion was characterized by an infiltrative, non-encapsulated, epithelial neoplasm that extended from the oral mucosa and invaded into the adjacent connective and muscular tissues (Fig. 4). Neoplastic cells were predominantly organized in large nests with very evident intercellular junctions, morphology similar to stratum spinosum. In the center of these nests there was squamous differentiation with desquamation of a large amount of intensely eosinophilic material organized in concentric laminae ("keratin pearls"), admixed with a large amount of cellular debris and neutrophils (Fig. 5). Surrounding the nests of neoplastic cells there was a marked proliferation of fibrovascular connective tissue associated with an intense multifocal to coalescent lymphoplasmacytic infiltrate. In the mediastinal lymph nodes there were multiple foci of metastasis of the neoplasm within the subcapsular lymphatic sinuses and sometimes infiltrating the cortex. Multiples nodules located in the lungs, spleen, and adrenal gland had microscopic features similar to those observed in the primary oral neoplasia (Fig. 6). However, in all metastatic foci there was an extensive central area of necrosis associated with a large amount of keratin laminae, and, in the lungs, there was also extensive mineralization.

Gross and microscopic findings in this case were compatible with a conclusive diagnosis of metastatic oral squamous cell carcinoma (SCC). In addition to the metastatic carcinoma, pulmonary anthracosis and edema, thyroid gland hyperplasia, and chronic interstitial nephritis were also observed in this case.



Figure 1. Metastatic oral squamous cell carcinoma in a common hippopotamus (*Hippopotamus amphibius*). **A.** Oral cavity with an extensive dark red ulcerative area with irregular surface, between the second (arrow) and third molar (absent), involving the gingival mucosa (arrow heads). **B.** Fragment of the oral mucosa with an exophytic neoplasm.

Discussion

To the best of our knowledge, this is the first report of SCC in a common hippopotamus, and one of the few reported cases of neoplasia in this species (1-3, 13, 14). Among domestic animal species, oral neoplasms are commonly observed in cats and dogs, being less common

Braz J Vet Pathol, 2018, 11(2), 64 – 67.
DOI: 10.24070/bjvp.1983-0246.v11i2p64-67

in horses and rare in production animals (cattle, sheep, and pigs) (10). However, cattle raised in pastures with bracken fern (*Pteridium aquilinum*) have a high incidence of oral and esophageal SCC (7).



Figure 2. Metastatic oral squamous cell carcinoma in a common hippopotamus (*Hippopotamus amphibius*). One of multiple solid, well-delimitated, whitish, and friable neoplastic nodules located in the lungs.

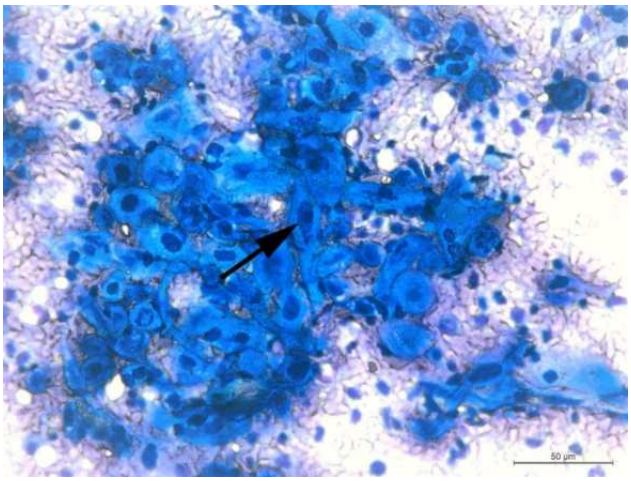

Figure 3. Metastatic oral squamous cell carcinoma in a common hippopotamus (*Hippopotamus amphibius*). Imprint of the oral neoplasm. Pleomorphic epithelial squamous cells forming large aggregates. Neoplastic cells often have large, central, prominent nucleoli (arrow), Diff Quick. Bar = 50 µm.

Among oral neoplasms, SCC is the most frequent neoplasm in cats, horses, and production animal species. In humans it represents 95% of oral neoplasms, and it is associated with alcohol and tobacco consumption, low hygiene, inadequate diets, and papillomavirus infection (10). Oral SCC has been described in other species of wild ungulates including white rhinoceros (*Ceratotherium simum*) (5) and Malayan tapir (*Tapirus indicus*) (8). In both cases, etiology was not established and the possibility of a viral infection predisposing to neoplastic development was not ruled out.

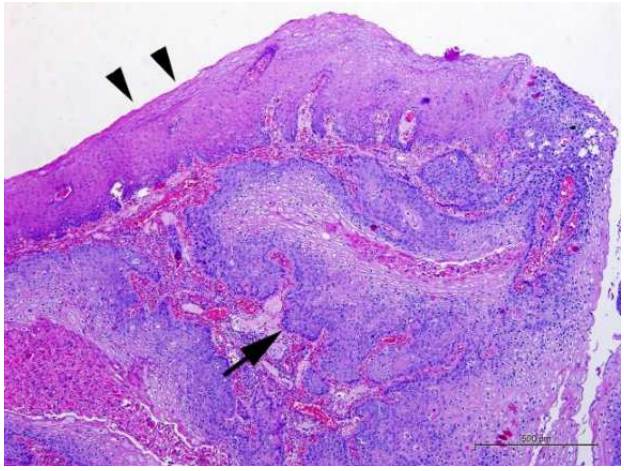

Figure 4. Metastatic oral squamous cell carcinoma in a common hippopotamus (*Hippopotamus amphibius*). Epithelial infiltrative proliferation in the oral mucosa (arrow heads) forming large nests (arrow) in the adjacent connective tissue, hematoxylin and eosin. Bar = 500 µm.

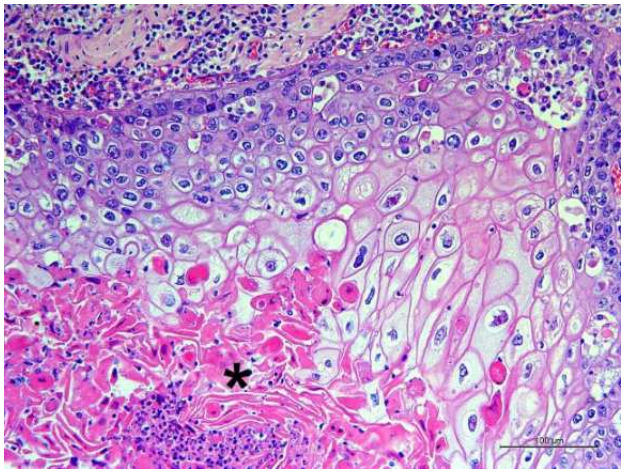

Figure 5. Metastatic oral squamous cell carcinoma in a common hippopotamus (*Hippopotamus amphibius*). Neoplastic cells with morphology compatible with the stratum spinosum and central area filled with keratin and cellular debris (*), hematoxylin and eosin. Bar = 100 µm.

Oral diseases, related to the continuous growth of canines and incisors teeth, were already observed in captive hippopotami and may culminate in recurrent and persistent oral lesions (9). Trauma followed by chronic inflammation has been described as a predisposing factor to the development of SCC, as described at the base of the horn of an Indian rhinoceros (*Rhinoceros unicornis*) (11).

SCC can be classified into five subtypes: conventional, papillary, basiloid, adenosquamous, and spindle cells SCCs (10). The tumor in this case may be classified into the conventional subtype, because of the large numbers of keratinized cells, keratin pearls, and prominent intercellular junctions. This subtype is the most common among domestic animals and usually has extremely infiltrative behavior, but rarely metastatic (10),

which emphasizes the uniqueness of this case that had multiple metastatic foci in different organs.

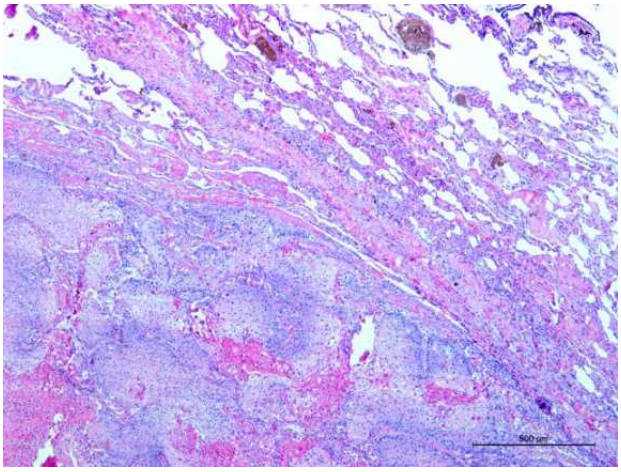

Figure 6. Metastatic oral squamous cell carcinoma in a common hippopotamus (*Hippopotamus amphibius*). Lung with a neoplastic epithelial growth morphologically similar to the oral neoplasm, hematoxylin and eosin. Bar = 500 μm.

In a study of captive pigmy hippopotamus (*Choeropsis liberiensis*), a different genus from the one reported here, belonging to 121 institutions across all continents, between years 1912 and 2014, the causes of death related to neoplasms covered 1.7% of all cases evaluated (7/404), representing 6.3% of the causes of death in geriatric patients (4/63) (4).

The neoplasia in this case, which was highly invasive, resulted in constant bleeding, evidenced by the blood in the lower airways and in the digestive tract, culminating with a severe anemia. The aggressive and invasive progression of the primary oral neoplasia associated with the multiple foci of metastasis were determinant for the death of this animal, while additional microscopic findings including anthracosis, pulmonary edema, thyroid gland hyperplasia and chronic interstitial nephritis were not considered relevant as causes of death in this case.

Acknowledgements

Work in RLS lab is supported by CNPq (Conselho Nacional de Desenvolvimento Científico e Tecnológico, Brazil), FAPEMIG (Fundação de Amparo a Pesquisa do Estado de Minas Gerais, Brazil), and CAPES (Coordenação de Aperfeiçoamento de Pessoal de Nível Superior, Brazil). RLS and TAP have fellowships from CNPq (Brazil).

References

1. Costa LF, Malta MCC, Tinoco HP, Medeiros LB, Bittar ASV, Hoffmann AR, Pierezan F, Paixão TA, Santos RL. Systemic histiocytic sarcoma in a common hippopotamus (*Hippopotamus amphibius*). J Zoo Wildl Med. 2016;47(2):650-3.
2. Cowan DF, Thurlbeck WM, Laws, RM. Some diseases of the hippopotamus in Uganda. Vet Pathol. 1967;4:553-67.
3. Duncan M, Grahn BH, Wilcock BP, Boermans H, Johnson LK, Smith DA. Pheochromocytoma associated with hypertensive lesions in a river hippopotamus (*Hippopotamus amphibius*). J Zoo Wildl Med. 1994;25:575-9.
4. Flacke GL, Tkalcic S, Steck B, Warren K, Martin GB. A Retrospective analysis of mortality in captive pygmy hippopotamus (*Choeropsis liberiensis*) From 1912 to 2014. Zoo Biol. 2016;35(6):556-69.
5. Langer S, Czerwonka N, Ternes K, Herbst W, Koehler K. Oral squamous cell carcinoma in an aged captive white rhinoceros (*Ceratotherium simim*). J Zoo Wildl Med. 2016;47(4):1090-2.
6. Lewison R, Pluháček J. (IUCN SSC Hippo Specialist Subgroup). 2017. *Hippopotamus amphibius*. The IUCN Red List of Threatened Species 2017: e.T10103A18567364. Downloaded on 02 October 2017.
7. Lucena RB, Rissi DR, Kommers GD, Pierezan F, Oliveira-Filho JC, Macêdo JT, Flores MM, Barros CS. A retrospective study of 586 tumours in Brazilian cattle. J Comp Pathol. 2011;145:20-4.
8. Miller CL, Templeton RS, Karpinski L. Successful treatment of oral squamous cell carcinoma with intralesional fluorouracil in a Malayan tapir (*Tapirus indicus*). J Zoo Wildl Med. 2000;31(2):262-4.
9. Miller MA. Hippopotamidae (hippopotamus). In: Fowler M, Miller R, editors. Zoo and wild animal medicine. St Louis: Saunders; 2003. p.602-12.
10. Munday JS, Löhr CV, Kiupel M. Tumors of Alimentary Tract. In: Meuten DJ, editor. Tumors in Domestic Animals. 5th Edition. Wiley-Blackwell; 2016. p. 499-601.
11. Naik SN, Ishwad CS, Karawale MS, Wani MV. Squamous cell carcinoma in an Indian rhinoceros. Vet Rec. 1986;118:590-1.
12. Pachaly JR, Filho LCM. Artiodactyla – Hippopotamidae. In: Cubas ZS, Silva JCR, Catão-Dias JL, editors. Tratado de Animais Selvagens Medicina Veterinária. São Paulo: Roca; 2014. p.1123-36.
13. Schiaffino F, Sander SJ, Bacares MEP, Barnes KJ, Kiupel M, Walsh T, Murray S. Cerebellar and mesencephalon neoplasia in a Nile hippopotamus (*Hippopotamus amphibius*). J Zoo Wildl Med. 2016;47:1093-6.
14. Wittschen P, Ochs A, Gruber AD. Oronasal fistula in a 53-year-old hippopotamus (*Hippopotamus amphibius*). J Comp Pathol. 2007;137:253-5.