BJVP
Brazilian Journal of Veterinary Pathology
ISSN 1983-0246

Case Report

Suppurative splenitis in a filly

Edmilson R. Daneze[1], Joel S. Montello-Neto[1], Angélica T. B. Moraes[1], Geórgia M. Magalhães[1], Brunna L. N. Sousa[1], Adriano C. V. Chicone[1], Deborah P. M. Dias[1]*

[1]Faculdade Dr. Francisco Maeda, Ituverava, SP, Brazil.
***Corresponding author**: Faculdade Dr. Francisco Maeda. Rua Domingos Nunes Macedo, s/n, Ituverava, SP, Brazil. Zip code: 14500-000. E-mail: deborah_dias@hotmail.com

Submitted January, 10th 2018, Accepted April, 4th 2018

Abstract

Splenic abscess is an uncommon condition in humans and animals. The present report describes a rare case of suppurative splenitis in a 14-month-old filly, presented with signs of mild colic, depression and hyporexia. After clinical and laboratorial evaluation, a suppurative process of undetermined location was suspected. Medical therapy and supportive care were initiated, general condition has degraded in few days, and a paracentesis was performed diagnosing peritonitis. Given the poor prognosis, euthanasia was elected. At necropsy, multiple splenic abscess and diffuse peritonitis were identified. The etiology was not determined.

Key words: abscess, horse, peritonitis, sepsis, spleen.

Introduction

The spleen is a highly vascular organ constantly exposed to infectious agents due to the role it plays in the immune system. However, chronic suppurative splenitis with formation of multiple splenic abscesses is an uncommon condition. Immunodeficiency is a major predisposing factor for the development of spleen infection and should be considered in patients subjected to corticosteroids administration and chemotherapy (5).

Suppurative splenitis of multiple etiologies are rarely reported in humans (3, 5, 10, 13, 20, 21), dogs (1, 15, 30), and cattle (22). In horses, the few cases of splenic abscess were associated with hematogenous spread of bacterial emboli (6, 28); perforation by metallic foreign bodies from the intestine (4, 7, 19, 24, 25, 33); perforation by *Gasterophilus intestinalis* (8) and *Habronema* spp. (14) larvae from stomach ulcers; erratic migration of *Strongylus* spp. (7, 12); blunt abdominal trauma (31); puncture wound into the abdominal cavity and spleen (7) or idiopathic in origin (7, 32, 33). According to these reports, splenic abscess is associated with high morbidity and mortality in horses, since treatment including antibiotics and abscesses removal are hardly successful. The poor prognosis for survival is associated with the risk of abscesses rupture into the peritoneal cavity, leading to diffuse septic peritonitis, considered a life-threatening condition in horses (7, 9). The present report describes an uncommon case of suppurative splenitis in a filly.

Case description

A 14-month-old Quarter Horse filly, weighing 280 kg, was referred to the Veterinary Teaching Hospital with the complaint of mild abdominal pain, progressive weight loss and depression from 2 weeks prior. The owners reported that imidocarb dipropionate at 4.0 mg/kg was administered for piroplasmosis, for 4 days. Upon arrival at the hospital the filly was depressed, tachycardic (64 beats/min), slightly tachypneic (20 breaths/min) and mildly dehydrated. Mucous membranes were congested and of a red color, and capillary refill time was prolonged (3 seconds). Abdominal auscultation identified intestinal hypomotility and no relevant findings were observed through rectal palpation.

 All rights reserved 2007.

Blood count showed red blood cells at lower limit, and total leukocytes at higher limit (14.200/µL) due to neutrophilia. Increased values of total protein (8.4 g/dL), fibrinogen (0.8 g/dL), urea (60 mg/dL) and creatinine (1,9 mg/dL) were found. In light of clinical features and laboratorial findings, a suppurative process was suspected. The filly received fluid therapy according to the dehydration status determined by means of clinical presentation, packed cell volume and total protein level. Ceftiofur (2.2 mg/kg IV BID), flunixin meglumine (1.1 mg/kg IM SID) and omeprazole (4 mg/kg PO q24h) were administered. On the next day, the filly remained depressed, anorexic, showed labial ptosis and severe sialorrhea. Leukocytes count increased (17.600/µL) and clinical presentation deteriorate gradually for 8 days, when signs of septic shock were evident. Paracentesis was performed and yielded a yellow turbid peritoneal fluid with inflammatory cells, featuring severe peritonitis. Given the poor prognosis, the owners were consulted, and euthanasia was elected.

Gross pathology revealed diffuse peritonitis, with deposition of fibrin on the visceral and parietal peritoneum leading to severe abdominal organ adhesions (Fig. 1A). The spleen showed severe splenomegaly with areas of necrosis and large amounts of purulent material (Figs. 1B and 1C). Other findings included pulmonary edema, concentric hypertrophy of the left ventricle, eccentric hypertrophy of the right ventricle and congestive hepatomegaly. Histological examination revealed the spleen markedly filled by neutrophils and cell debris, with areas containing activated macrophages, plasma cells and bacteria (Fig. 1D). Extensive areas of splenic necrosis were observed. Gram-negative bacteria were stained more intensively (red color). Acid alcohol fast staining techniques (ZN) were also applied, and Bacilli were not detected. The liver showed periportal infiltration of plasma cells, discrete biliary pigments in the cells and ducts, vascular congestion and hepatocyte necrosis. Tubular necrosis and lymphoplasmacytic interstitial inflammatory infiltrate was evidenced in the kidneys.

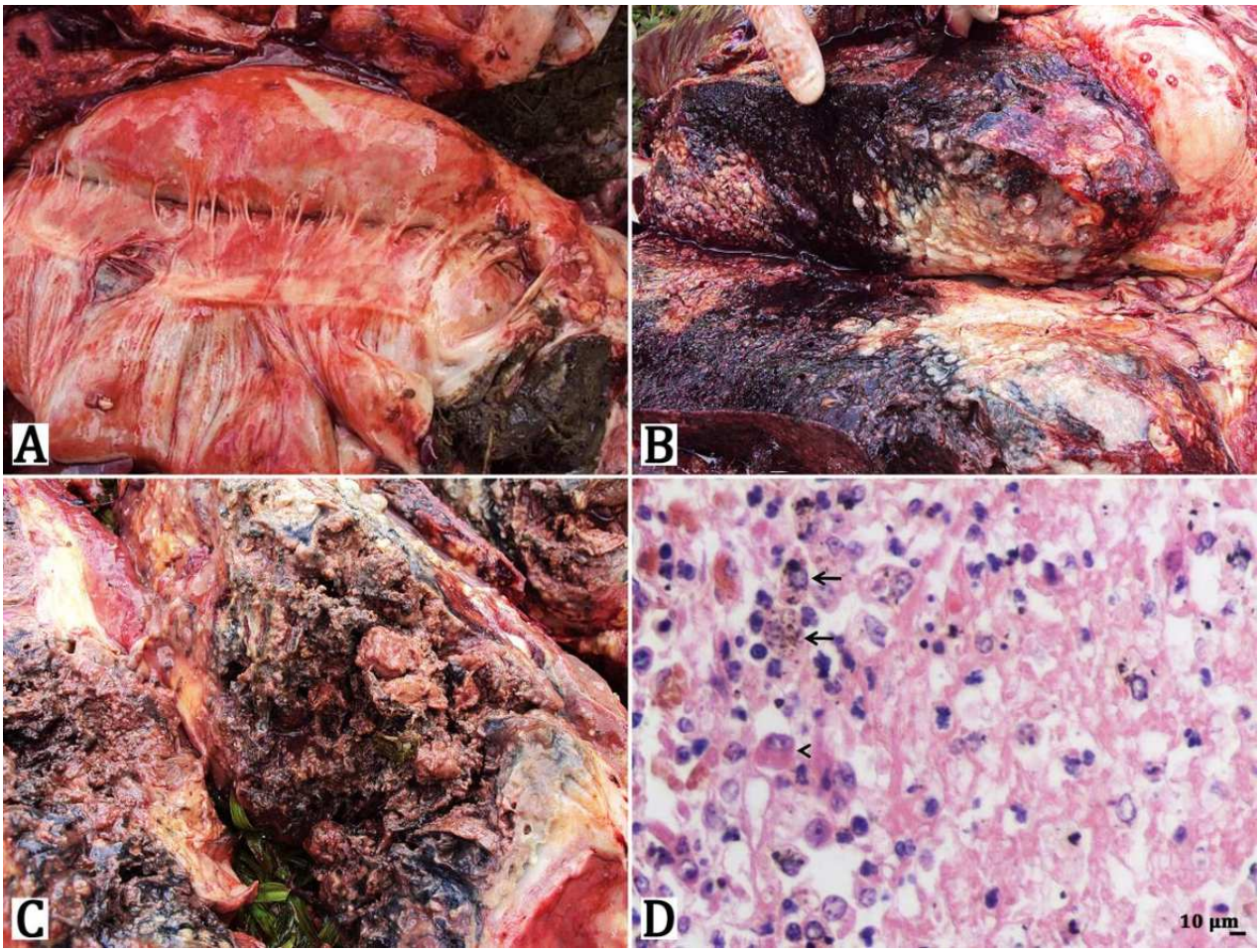

Figure 1. Images of a filly affected by splenitis. **A.** Abdominal organ adhesions. **B** and **C.** Severe abscedation and necrosis of the spleen. **D.** Photomicrograph of the spleen tissue showing cell debris and inflammatory infiltrate of neutrophils, activated macrophages (arrows) and plasma cells (arrow head). Hematoxylin & Eosin, 40x. Bar = 10µm.

Discussion

The present report concerns a 14-month-old filly presenting suppurative splenitis. Other reports of the same disorder referred to a 3-year-old pony (33), a 6-year-old mare (32), an 8-year-old gelding (31), and other horses older than 9-year-old (7, 8, 19, 24, 25, 33), showing that suppurative splenitis is more prevalent in aged horses than in foals. Gender and breed do not seem to interfere with the development of the disease (7, 8, 19, 24, 25, 31, 32, 33).

The history and clinical findings, including weight loss, depression, tachycardia, tachypnea, pyrexia, mild recurrent colic, neutrophilia and hyperfibrinogenemia on blood analysis, and an inflammatory exudate on paracentesis, featured abdominal abscessation (4, 7). These findings were not sufficient to determine the etiology of this case, and other authors also described suppurative splenitis that were idiopathic in origin (7, 32, 33). The most common etiology for spleen abscessation in horses is perforating wires from the gastrointestinal tract (4, 7, 19, 24, 25, 33). Despite a foreign body was not found embedded in the parenchyma of the spleen at necropsy, this origin could not be ruled out, since, according to Swan in 1968 (33), partial perforation of the intestinal wall reaching the spleen is sufficient to cause infection. The foreign body may perforate and pass out, therefore will not be found post mortem. Further supporting this etiology, although foreign body-associated diseases in horses are generally rare, recurrent episodes of colic could indicate abdominal organ perforation (17), and the filly had a history of 2 weeks showing mild abdominal pain.

Other option for the etiology would be the hematogenous spread of infection (6, 28). However, the filly had no history of previous suppuration. Piroplasmosis was diagnosed and treated before admission, and hepatomegaly observed at necropsy is a finding that features Rickettsial infection (12). Although piroplasmosis may lead to massive extravascular activity of splenic macrophages (34), the disease could not be associated to the development of splenic abscess. The only relation between splenitis and piroplasmosis is that both may occur in immunocompromised horses and leads to splenomegaly (6). Thus, the etiology for the present case remained unclear.

The enlarged spleen viewed at necropsy was not identified on rectal palpation performed during the first clinical evaluation, and the filly was subjected to euthanasia eight days after admission. The deterioration of its general condition could be confirmed by clinical and laboratorial findings, and it is supposed that the spleen had enlarged along the hospitalization period. Pilati and colleagues in 2017 (24) reported a case of splenitis without splenomegaly; this mare was referred for recurrent episodes of colic, clinical and laboratorial findings were normal, and one splenic abscess surrounding a metallic perforating foreign body was identified through ultrasound examination. The abscess was drained, the wire removed through laparotomy and the mare survived. Therefore, one can conclude that spleen enlargement could be absent in mild or initial cases of suppurative splenitis.

The presented signs of cardiovascular deterioration as tachycardia, tachypnea and congested mucous membranes were strongly related to sepsis following peritonitis (16, 26). Other findings related to sepsis were changes in creatinine and urea, which may be associated with multiple organ dysfunction syndrome (26). Histology confirmed acute tubular necrosis of the kidneys and hepatic disease, as observed by Dart and colleagues in 1987 (8) and Coleman and Schmitz in 2017 (7) in cases of suppurative splenitis. Peritonitis in the horse is a serious complication of abdominal organ disease and is most commonly associated with intestinal lesion. Once a suppurative process is identified in the abdominal cavity, inflammatory cells migrate, and pro-inflammatory mediators are released by activated macrophages, leading to vasodilation and increased vascular permeability. Large amounts of fluids and fibrin shift into the abdominal cavity, and the fibrinolytic activity of mesothelial cells is reduced to allow the formation of fibrin barriers around infection. Intestinal ileus is induced by means of sympathetic stimulation to reduce dissemination of bacteria in the peritoneal fluid (18). This description corroborates pyrexia, dehydration and hypomotility; increased values of leukocytes (neutrophils) and fibrinogen; the exudate yielded through paracentesis; fibrous adherences observed at necropsy; and the activated macrophages observed on histology.

Due to the similarity with other disorders involving the abdominal cavity, diagnosis of splenitis is not easy, mainly in the initial stages. Abdominal radiography is often not considered feasible in adult horses but may identify foreign bodies in individual cases (17). Ultrasound is considered a useful tool in diagnosing spleen disorders and monitoring the response to treatment (2, 7, 32). The spleen must be completely scanned to avoid missing any lesion (24). In the present report, ultrasonographic examination of the spleen was not performed because an equipment was not available, which contributed to a delay to diagnose the disorder. The definitive diagnosis was determined only at necropsy, when similar findings to other cases of suppurative splenitis (8, 33) were observed. Gram-negative bacteria, as found in the histological evaluation, were frequently cultured from splenic abscess and the most common is *Escherichia coli* (4). However, a splenic tissue culture was not carried out and precluded etiologic agent determination. Despite inconclusive, the disease was managed medically from admission for a possible suppurative process, and the prescription was in accordance to the medical treatment for abdominal abscess suggested by Arnold and Chaffin in 2012 (4).

Considering cases of suppurative splenitis in horses, there is only one report in which the horse has

responded to medical treatment and survived (32). The poor prognosis, as observed in the present case, is attributed to the easy development of diffuse peritonitis following splenic abscess that is strongly associated with high mortality rates (7, 11). Splenic abscess is also difficult to be treated medically in humans and splenectomy is considered to be the solution (20). Splenectomy in horses is not technically easy to perform due to the cranial position of the spleen, extensive ligamentous attachment and considerable vascularization (27). The laparoscopic-assisted technique provides the visualization of the visceral aspect of the spleen, and consequently a most accurate dissection of splenic ligaments and hilum vasculature (23). The horse should be hemodynamically stable and with a normal coagulation status prior to surgery, because there is the risk of splenic rupture leading to hemorrhage. Thus, an emergency intra-operative blood transfusion may be required and should be previously prepared (29). In cases of splenic abscess, massive contamination of the abdominal cavity may occur during splenectomy (25). Furthermore, optimal surgical technique is not yet described and postoperative complications as a noteworthy decrease in the immune system efficacy should de expected (29).

The history and clinical presentation are not sufficiently reliable to determine the diagnosis of suppurative splenitis in horses, and clinicians usually does not suspect of this rare disease. Therefore, recurrent colic should always be investigated by a thorough clinical examination including abdominal ultrasonography, aiming the early diagnosis and attempt of treatment for abdominal abscess. Due to the poor prognosis, as soon as suppurative splenitis is diagnosed, it is important to discuss with the owner about risks and costs of treatment.

References

1. Abdellatif A, Günther C, Peppler C, Kramer M. A rare case of splenic abscess with septic peritonitis in a German shepherd dog. BMC Vet Res. 2014;10:201.
2. Alsop EJ, Marr C, Barrelet AB, McGladdery AJ. The use of transabdominal ultrasonography in the diagnosis and management of splenic lesions in three horses. Equine Vet Educ. 2007;19(1):5-10.
3. Araujo MS, Bremer FP, Oliveira CABM, Heimovski FE, Krebs CNV. Abscesso esplênico. Relato de caso. Rev Bras Clin Med. 2011;9(4):308-10.
4. Arnold CE, Chaffin MK. Abdominal abscesses in adult horses: 61 cases (1993-2008). J Am Vet Med Assoc. 2012;241(12):1659-65.
5. Chiang IS, Lin TJ, Chiang IC, Tsai MS. Splenic abscesses: review of 29 cases. Kaohsiung J Med Sci. 2003;19(10):510-5.
6. Coelho HE. Patologia Veterinária. Barueri: Manole; 2002. 237p.
7. Coleman MC, Schmitz DG. Splenic abscessation in the horse: A retrospective study of 12 cases. Equine Vet Educ. 2017;doi:10.1111/eve.12785.
8. Dart AJ, Hutchins DR, Begg AP. Suppurative splenitis and peritonitis in a horse after gastric ulceration caused by larvae of *Gasterophilus intestinalis*. Aust Vet J. 1987;64(5):155-8.
9. Davis J. Treatment of peritonitis. Vet Clin North Am Equine Pract. 2003;19(3):765-78.
10. Divyashree S, Gupta N. Splenic abscess in immunocompetent patients managed primarily without splenectomy: a series of 7 cases. Perm J. 2017;21:16-139.
11. Dukti S, White N. Surgical complications of colic surgery. Vet Clin North Am Equine Pract. 2008;24(3):515-34.
12. Fighera RA, Graça DL. Sistema hematopoiético. In: Santos RL, Alessi AC, editors. Patologia Veterinária. São Paulo: Roca; 2010. p. 337-422.
13. Fotiadis C, Lavranos G, Patapis P, Karatzas G. Abscesses of the spleen: report of three cases. World J Gastroenterol. 2008;14(19):3088-91.
14. Fry MM, McGavin MD. Medula óssea, células sanguíneas e sistema linfático. In: Zachary JF, McGavin MD, editors. Bases da Patologia Veterinária. 5th ed. Rio de Janeiro: Elsevier; 2013. p.701-33.
15. Ginel PJ, Lucena R, Arola J, Martin MP, Mozos E. Diffuse splenomegaly caused by splenic abscessation in a dog. Vet Rec. 2001;149(11):327-9.
16. Javsicas LH. Peritonitis. In: Reed SM, Bayly WM, Sellon DC, editors. Equine Internal Medicine. 3rd ed. St. Louis: Saunders; 2010. p.895-9.
17. Lohmann K. Foreign body-associated splenic abscess in a horse. Equine Vet Educ. 2012;24(6):291-3.
18. Mair T. Peritonitis. In: Mair T, Divers T, Ducharme N, editors. Manual of Equine Gastroenterology. London: WB Saunders; 2002. p.322-30.
19. McDowall A. Traumatic splenitis in horsesAust Vet J. 1947;23(5):125.
20. Mustafa M, Menon J, Muniandy R, Rahman MSD, Tan TS. Splenic abscess: etiology, clinical spectrum and therapy. IOSR Journal of Pharmacy. 2015;5(1):37-41.
21. Ng CY, Leong EC, Chng HC. Ten-year series of splenic abscesses in a general hospital in Singapore. Ann Acad Med Singapore. 2008;37(9):749-52.
22. Nuss K, Forster E, Reichert C, Muggli E, Braun U. Splenectomy for treatment of suppurative splenitis caused by a reticular foreign body in a heifer. Vet Surg. 2009;38(4):477-80.
23. Ortved KF, Witte S, Fleming K, Nash J, Woolums AR, Peroni JF. Laparoscopic-assisted splenectomy in a horse with splenomegaly. Equine Vet Educ. 2008;20(7)357-61.
24. Pilati N, Corsalini J, Beccati F, Nannarone S, Gialletti R. Surgical treatment of an abdominal abscess caused

by a migrating iron wire from the ventral colon, a case report. J Equine Vet Sci. 2017;54:103-6.
25. Rosso A, Bullone M, Gillono E, Greppi MC, Bertuglia A. Splenic abscesses due to migrant metallic wires from small intestine in a horse. Equine Vet Educ. 2012;24(6):286-90.
26. Roy MF. Sepsis in adults and foals. Vet Clin North Am Equine Pract. 2004;20(1):41-61.
27. Roy MF, Lavoie JP, Deschamps I, Laverty S. Splenic infarction and splenectomy in a jumping horse. Equine Vet J. 2000;32(2)174-6.
28. Santos JA. Patologia especial dos animais domésticos. Rio de Janeiro: IICA; 1975. 661 p.
29. Sherlock C. The considerations and complications involved in equine splenectomy. Equine Vet Educ. 2011;23(12)612-5.
30. Spangler WL, Culbertson MR. Prevalence, type, and importance of splenic diseases in dogs: 1,480 cases (1985-1989). J Am Vet Med Assoc. 1992;200(6):829-34.
31. Spier S, Carlson GP, Nyland TG, Snyder JR, Fischer PE. Splenic hematoma and abscess as a cause of chronic weight loss in a horse. J Am Vet Med Assoc. 1986;189(5):557-9.
32. Steel CM, Lonsdale RA, Bolton JR. Successful medical treatment of splenic abscesses in a horse. Aust Vet J. 1998;76(8):541-2.
33. Swan RA. Splenitis in horses. Aust Vet J. 1968;44(10):459-61.
34. Wise LN, Pelzel-McCluskey AM, Mealey RH, Knowles DP. Equine piroplasmosis. Vet Clin North Am Equine Pract. 2014;30(3):677-93.