Braz J Vet Pathol, 2018, 11(3), 97 – 101
DOI: 10.24070/bjvp.1983-0246.v11i3p97-101

BJVP
Brazilian Journal of Veterinary Pathology
ISSN 1983-0246

Case Report

Mandibular squamous cell carcinoma in a captive Siberian tiger (*Panthera tigris altaica*)

Ayisa R. de Oliveira[1], Tatiane F. de Carvalho[1], Alexandre Arenales[1], Herlandes P. Tinoco[2], Carlyle M. Coelho[2], Maria Elvira L. T. Costa[2], Tatiane A. Paixão[3], Eduardo A. Caixeta[1], Guilherme R. G. Pinheiro[1], Renato L. Santos[1*]

[1]Departamento de Clínica e Cirurgia Veterinárias, Escola de Veterinária, Universidade Federal de Minas Gerais, 31270-901, Belo Horizonte, Minas Gerais, Brazil.
[2]Fundação de Parques Municipais e Zoobotânica de Belo Horizonte, 31365-450, Belo Horizonte, Minas Gerais, Brazil.
[3]Departamento de Patologia Geral, Instituto de Ciências Biológicas, Universidade Federal de Minas Gerais, 31279-901, Belo Horizonte, Minas Gerais, Brazil.
***Corresponding author:** Departamento de Clínica e Cirurgia Veterinária, Escola de Veterinária, Universidade Federal de Minas Gerais, Av. Presidente Antônio Carlos, 6627 – CEP 30161-970, Belo Horizonte, MG, Brazil. Phone: 55-31-3409-2239. Fax: 55-31-3409-2230. E-mail: rsantos@vet.ufmg.br

Submitted July, 08th 2018, Accepted October, 10th 2018

Abstract

Squamous cell carcinoma (SCC) is a common oral neoplasm in domestic cats, but there are only a few reports in wild felids. A captive 10-years-old, female Siberian tiger (*Panthera tigris altaica*), with history of chronic renal disease and serologically positive for *Leishmania* sp. developed a lytic mandibular nodule that was histologically diagnosed as SCC. At necropsy was also observed an exocrine pancreatic carcinoma, which was considered an incidental finding, and a chronic lympho-plasmocytic interstitial nephritis associated with a membranous glomerulopathy, compatible with the chronic renal disease presented by the animal. To the best of our knowledge this is the first report of an invasive and non-metastatic mandibular SCC in a Siberian tiger.

Key words: SCC, oral neoplasia, wild felid, pancreatic carcinoma, leishmaniasis.

Introduction

Increase in lifespan for captive wild felids is the result of better nutritional and veterinary healthcare. However, as expected, there is a consequent increase in incidence of tumors (4, 14, 20). Neoplasms represents an important cause of natural death or euthanasia in captive felids (20), which is likely due to predisposing factors including environmental pollution and aging (13, 20).

Oral neoplasms are common in domestic cats, and it is usually malignant. Squamous cell carcinoma (SCC) is the most prevalent oral neoplasm in domestic cats. Generally, it develops at mandibular, maxillary, or sublingual regions (18). In wild felids there are few reports of oral neoplasms, including a maxillary calcifying epithelial odontogenic tumor in a Siberian tiger (*Panthera tigris altaica*) (7); a maxillary malignant melanoma and an oral papillomatosis in African lion (*Panthera leo*) (10, 25); a case of oral papillomatosis in a tiger (*P. tigris*) (10) and in 11 Canadian lynx (*Lynx canadensis*) (26); three cases of oral SCC in *Lynx* spp. affecting the tongue (1), gum (9) and jaw (23); and a mandibular SCC in a North American Amur leopard (*P. pardus orientalis*) (19).

This report describes, for the first time, the clinical and pathological findings in a case of mandibular SCC in a captive Siberian tiger (*P. tigris altaica*).

Case report

A captive 10-year-old, female Siberian tiger (*P. tigris altaica*), with history of chronic renal disease and serologically positive to *Leishmania* sp., was handled periodically for checkup. A mandibular mass adjacent to the right inferior canine was detected during one of the

 All rights reserved 2007.

Braz J Vet Pathol, 2018, 11(3), 97 – 101
DOI: 10.24070/bjvp.1983-0246.v11i3p97-101

routine examinations. A radiograph demonstrated a radiolucent central area surrounded by a poorly demarcated radiopaque region. In addition, the mandibular arch, adjacent to neoformation, had a marked segmental reduction of radiopacity (Fig. 1). Biopsy was performed, resulting in a presumptive diagnosis of SCC. Euthanasia was performed due to poor prognosis.

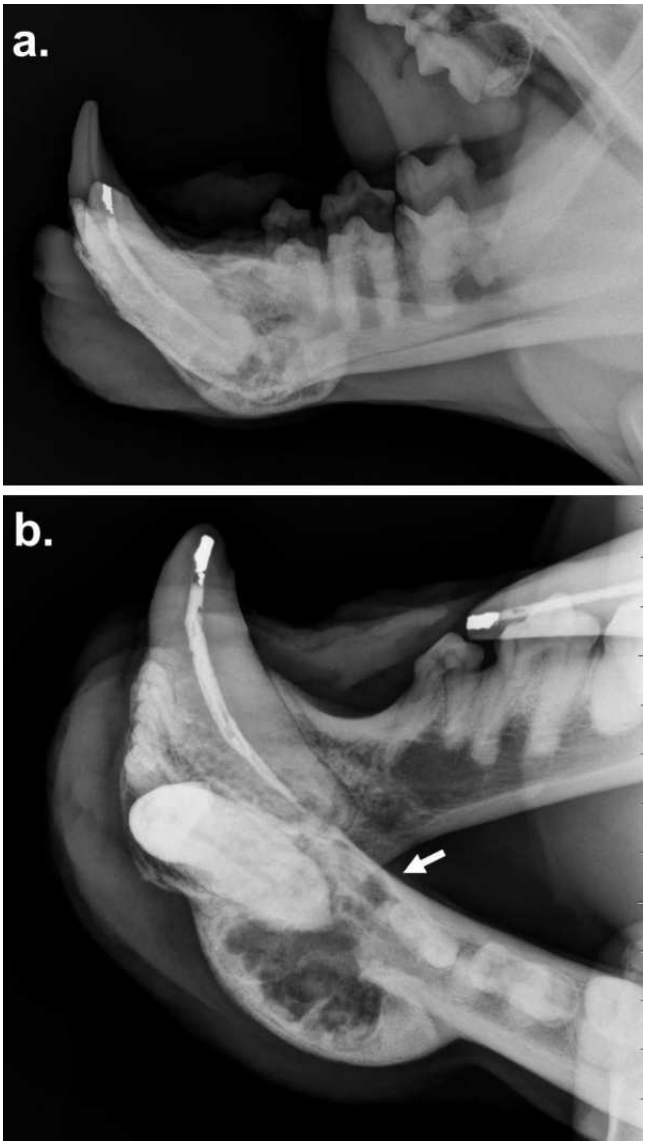

Figure 1. Oral squamous cell carcinoma in a Siberian tiger (*Panthera tigris altaica*). Radiography of the mandibular neoformation in the latero-lateral (a) and ventro-dorsal (b) projections. A rostral increase of volume with radiolucent central area and radiopaque borders is associated with a significant segmental reduction of the mandibular arch radiopacity (arrow).

Necropsy was performed immediately after death. Grossly, at the right rostral mandible there was a nodule with 6.5 x 7.5 cm (Fig. 2), which was heterogeneous on the cut surface with multifocal friable white to grey areas measuring 1-3 cm in diameter, filled with dark red, gelatinous material and circumscribed by white, gritty and firm areas.

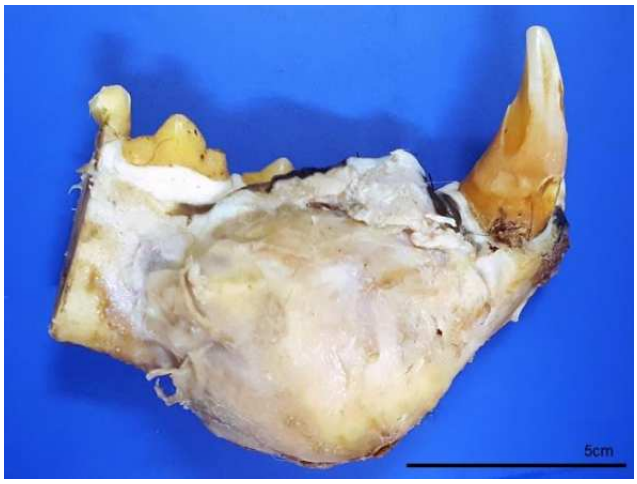

Figure 2. Oral squamous cell carcinoma in a Siberian tiger (*Panthera tigris altaica*). Nodular lesion with approximately 6.5 x 7.5 cm located rostrally in the right hemi-jaw adjacent to the right lower canine tooth.

Microscopically, there was a densely cellular, infiltrative, poorly demarcated and encapsulated neoplastic epithelial proliferation invading the subepithelial connective tissue. Neoplastic cells were arranged in nests and anastomosing trabeculae, formed by large polygonal, well demarcated cells with visible intercellular attachment (morphologically compatible with cells of the *stratum spinosum*), supported by moderate to abundant fibrovascular stroma (Fig. 3). Neoplastic cells had an abundant and fibrillar eosinophilic cytoplasm, and a large, central and ovoid nucleus containing 1-2 large and irregularly shaped nucleoli. There was moderate to severe anisokaryosis and nuclear pleomorphism with 1-2 mitotic figures per high power field. There were occasional concentric areas of lamellar keratin (keratin pearls) (Fig. 3). Therefore, the morphologic diagnosis of SCC was established. Additionally, at the margins of the neoplasm there was marked periosteal reaction, characterized by abundant trabeculae formation and severe osteoblastic hyperplasia and hypertrophy, as well as multiple areas of bone replacement by connective fibrous (fibrosis).

Grossly, there was a multinodular neoplastic proliferation in the pancreas, with 0.3 to 1 cm, dark red, and firm. Histologically, this lesion was characterized by an expansive, noninvasive, encapsulated and well demarcated epithelial neoplasm, arranged in large lobules with areas of a tubular or solid pattern. Neoplastic cells were large, well demarcated, with abundant eosinophilic and granular cytoplasm. Nuclei were round, large, and central, containing an evident basophilic nucleolus. There were moderated anisocytosis and anisokaryosis, with 4 mitotic figures per 10 high power microscopic fields (Fig.

Braz J Vet Pathol, 2018, 11(3), 97 – 101
DOI: 10.24070/bjvp.1983-0246.v11i3p97-101

4), which was diagnosed as an exocrine pancreatic carcinoma.

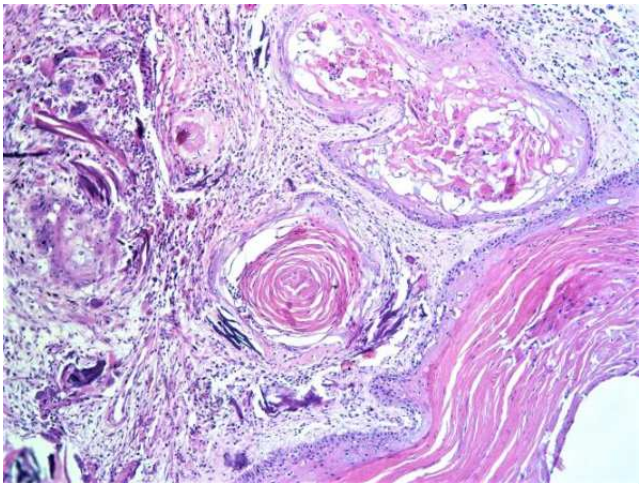

Figure 3. Oral squamous cell carcinoma in a Siberian tiger (*Panthera tigris altaica*). Neoplasm characterized by nests of well differentiated epithelial cells, with central area with "keratin pearls" and cell debris. Adjacent, there is a marked desmoplastic reaction. Hematoxylin and eosin, 100x.

Chronic renal disease was confirmed based on the observation of chronical lympho-plasmocytic interstitial nephritis associated with diffuse and moderate membranous glomerulopathy. There were no other relevant lesions, and no metastasis was observed.

Due to the history of serologic positivity for leishmaniasis, PCR targeting *Leishmania* sp. DNA was performed using DNA samples extracted from paraffin-embedded spleen and lymph nodes. DNA extraction was performed with NucleoSpin® Tissue kit (Macherey-Nagel GmbH & Co. KG, Germany) according to the manufacturer's instructions. Amplification was performed using primers targeting sequences of minicircle kinetoplast DNA (CTTTTCTGGTCCCGCGGGTAGG and CCACCTGGCCTATTTTACACCA) under previously described parameters (5). Immunohistochemistry (IHC) was also performed in the kidney, spleen, and lymph nodes as described by Tafuri et al. (27). Spleen and lymph nodes were PCR positive, but no amastigotes were observed in any of the evaluated tissue samples, either in hematoxylin and eosin-stained sections or by IHC.

Discussion

To the best of our knowledge this is the first report of an invasive mandibular SCC in a Siberian tiger. SCC is a common oral neoplasm in domestic cats (3, 24), but in wild felids there are only a few reports, three of them described in *Lynx* spp. (1, 9, 23) and one in a North American Amur leopard (19). Feline SCC is often infiltrative and ulcerative with marked osteolysis, but it is rarely metastatic (3), which is similar to this case that was highly invasive, but not metastatic.

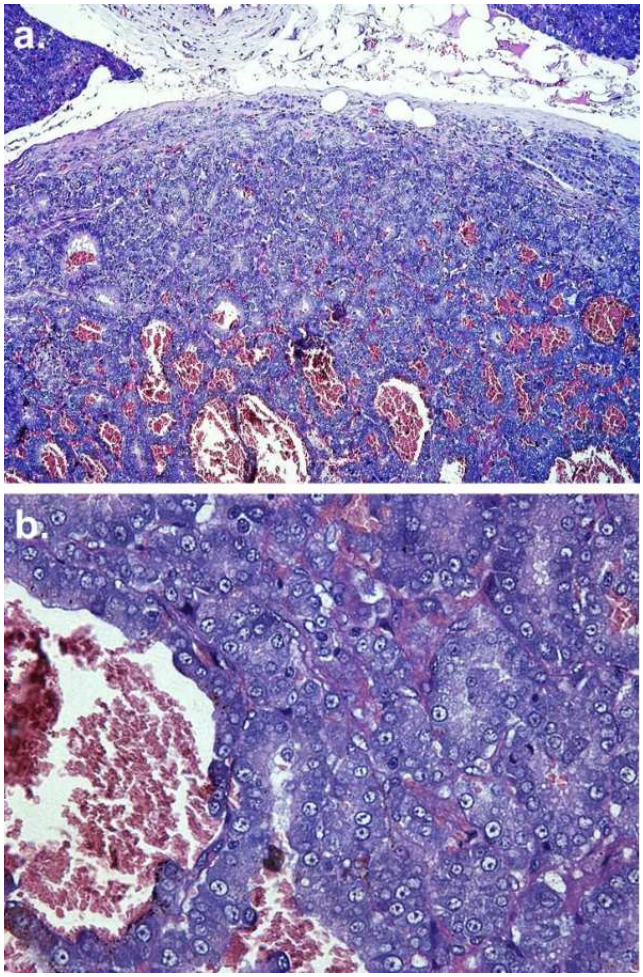

Figure 4. Exocrine pancreatic carcinoma in a Siberian tiger (*Panthera tigris altaica*). **A.** Epithelial neoformation expansive and well delimited organized predominantly in tubular formations, with several dilated capillaries filled with erythrocytes. Hematoxylin and eosin, 100x. **B.** Epithelial cells with slightly vacuolated basophilic cytoplasm, round nucleus with well evident central nucleolus and moderate mitotic index. Hematoxylin and eosin, 400x.

Development of oral SCC in cats is multifactorial, but the most important predisposing factors in this species include paste diets, use of anti-flea collars, and exposure to tobacco smoke (2, 3). Owston et al. (20) considered the urban location of the Knoxville Zoo as potential predisposing factor for the development of neoplasms in the captive felines in that institution. Similar to the Knoxville Zoo, the zoo in this case is located within the urban area of Belo Horizonte, a Brazilian city with approximately 2.5 million people (IBGE, 2017 Census) so environmental pollution may be a predisposing factor in this case.

Recent studies evaluated whether feline or human papillomavirus play a role in the development of oral neoplasia in domestic cats, but there was no confirmation of the association of these agents with oral SCC (3, 16,

17). Importantly, E6 and E7 oncogenes of papillomavirus were detected in saliva samples from two snow leopards indicating that a potential cause and effect relation with this virus should be thoroughly investigated (15). Other risk factor associated with human oral SCC is dental disease, a common condition in older cats (18).

A study developed from 1979 to 2003 at the Knoxville Zoo (20) found that 27.7% (26 animals) felids died or were euthanized due neoplastic processes. Among those animals, 11 were tigers with mean age of 13 years-old, which is slight older than the present case. There are few case reports of concurrent neoplasms in wild felids (4, 6, 11, 20, 22). For Siberian tiger, there were two reports of simultaneous neoplasms, a case of pancreatic adenocarcinoma and Brunner's gland adenoma (8), and a case of seminoma and lymphangioma (20).

Owston et al. (20) reported that all felines with pancreatic tumors, in that particular study, also had another type of neoplasia, as observed in this case. Pancreatic adenocarcinoma has been previously described in a Siberian tiger (8), but with infiltrative and metastatic behavior, which contrasts with this case, in which the pancreatic tumor was an incidental finding, with no metastasis, and not related to any apparent clinical sign.

Although this tiger was serologically and PCR positive for *Leishmania* sp. the only anatomopathological finding that could be associated with leishmaniasis in this case was the chronic renal disease. However, no amastigotes were observed within renal interstitial infiltrate or in any other organs evaluated. Serologic and PCR surveys in endemic region to leishmaniasis suggest that the feline infection to leishmaniasis is more widespread than the clinical disease (12), which supports the notion that felines may act as reservoirs (21).

Acknowledgements

Work in RLS lab is supported by CNPq (Conselho Nacional de Desenvolvimento Científico e Tecnológico, Brazil), FAPEMIG (Fundação de Amparo à Pesquisa do Estado de Minas Gerais, Brazil), and CAPES (Coordenação de Aperfeiçoamento de Pessoal de Nível Superior, Brazil). RLS and TAP have fellowships from CNPq (Brazil).

References

1. Altamura G, Eleni C, Meoli R, Cardeti G, Friedrich KG, Borzacchiello G. Tongue squamous cell carcinoma in a European lynx (*Lynx lynx*): papillomavirus infection and histologic analysis. Vet Sci. 2011;5(1):1-6.
2. Bertone ER, Snyder LA, Moore AS. Environmental and lifestyle risk factors for oral squamous cell carcinoma in domestic cats. J Vet Intern Med. 2003;17:557-62.
3. Bilgic O, Duda L, Sánchez MD, Lewis JR. Feline oral squamous cell carcinoma: clinical manifestations and literature review. J Vet Dent. 2015;32(1):30-40.
4. Cagnini DQ, Salgado BS, Linardi JL, Grandi F, Rocha RM, Rocha NS, Teixeira CR, Del Piero F, Sequeira JL. Ocular melanoma and mammary mucinous carcinoma in an African lion. BMC Vet Res. 2012;8:176.
5. Diniz SA, Melo MS, Borges AM, Bueno R, Reis BP, Tafuri WL, Nascimento EF, Santos RL. Genital lesions associated with visceral leishmaniasis and shedding of *Leishmania* sp. in the semen of naturally infected dogs. Vet Pathol. 2005;42:650-8.
6. Doster AR, Armstrong DL, Bargar TW. Seminoma and parathyroid adenoma in a snow leopard (*Panthera unica*). J Comp Pathol. 1989;100:475-80.
7. Fecchio RS, Gomes MS, Xavier JG, Kunze PE, Gioso MA. Maxillary calcifying epithelial odontogenic tumor in a Siberian tiger (*Panthera tigris altaica*). J Vet Dent. 2015;32(2):120-1.
8. Gombac M, Dolensek T, Jausovec D, Kvapil P, Svara T, Pogacnik M. Simultaneous occurrence of pancreatic adenocarcinoma and Brunner's gland adenoma in a Siberian tiger (*Panthera tigris altaica*). J Comp Pathol. 2015;153:363-7.
9. Gunson DE, Klein LV, Reid CF. Gingival squamous cell carcinoma in a Canadian lynx. J Am Vet Med Assoc. 1978;173:1228-30.
10. Junginger J,Hansmann F, Herder V, Lehmbecker A, Peters M, Beyerbach M, Wohlsein P, Baumgärtner W. Pathology in captive wild felids at German zoological gardens. Plos One. 2015;10(6):e0130573.
11. Kennedy GA, Strafuss AC. Multiple neoplasms in an aged cougar. J Zoo Animal Med. 1976;7:24-6.
12. Little SE, Lindsay DS. Section Four. Chapter 73: Leishmaniasis. In: Greene CE, editor. Infectious disease of the dog and cat. 4th ed. St Louis: Elsevier Saunders. 2012. p.734-49.
13. Lombard LS, Witte EJ. Frequency and types of tumors in mammals and birds of the Philadelphia Zoological Garden. Cancer Res. 1959;19(2):127-41.
14. Longley L. Chapter 60: Aging in Large Felids. In: Miller RE and Fowler M, editors. Fowler's Zoo and Wild Animal Medicine Current Therapy. 7th ed. St Louis: Elsevier Saunders. 2012. p.465-9.
15. Mitsouras K, Faulhaber EA, Hui G, Joslin JO, Eng C, Barr MC, Irizarry KJL. Development of PCR assay to detect papillomavirus infection in the snow leopard. Vet Res. 2011;7(38):2-11.
16. Munday JS, Howe L, French A, Squires RA, Sugiarto H. Detection of papillomaviral DNA sequences in a feline oral squamous cell carcinoma. Res Vet Sci. 2009;86:359-61.
17. Munday JS, French AF. *Felis catus* papillomavirus types 1 and 4 are rarely present in neoplastic and inflammatory oral lesions of cats. Res Vet Sci. 2015;100:220-2.

Braz J Vet Pathol, 2018, 11(3), 97 – 101
DOI: 10.24070/bjvp.1983-0246.v11i3p97-101

18. Munday JS, Löhr CV, Kiupel M. Tumors of the alimentary tract. In: Meuten DJ, editor. Tumors in domestic animals. 5th ed. Iowa: John Wiley & Sons, Inc. 2017. p.499-601.
19. Napier JE, Lund MS, Armstrong DL, McAloose D. A retrospective study of morbidity and mortality in the North American Amur leopard (*Panthera pardus orientalis*) population in zoologic institution from 1992 to 2014. J Zoo Wildl Med. 2018;49(1):70-8.
20. Owston MA, Ramsay EC, Rotstein DS. Neoplasia in felids at the Knoxville Zoological Gardens, 1979-2003. J Zoo Wildl Med. 2008;39(4):608-13.
21. Roque ALR, Jansen AM. Wild and synanthropic reservoirs of *Leishmania* species in the Americas. Int J Parasitol Parasites Wildl. 2014;3:251-62.
22. Sagartz, JW, Garner MF, Bauer RM. Multiple neoplasia in a captive jungle cat (*Felis chaus*), thyroid adenocarcinoma, gastric adenocarcinoma, renal adenoma, and Sertoli cell tumor. J Wildl Dis. 1972;8:375-80.
23. Sladakovic I, Burnum A, Blas-Machado U, Kelly LS, Garner BC, Holmes SP, Divers SJ. Mandibular Squamous Cell Carcinoma in a Bobcat (*Lynx rufus*). J Zoo Wildl Med. 2016;47:370-3.
24. Stebbins KE, Morse CC, Goldschmidt MH. Feline oral neoplasia: a ten-year survey. Vet Pathol. 1989; 26:121-8.
25. Steeil JC, Schumacher J, Baine K, Ramsay EC, Sura P, Hodshon R, Donnell RL, Lee ND. Diagnosis and treatment of a dermal malignant melanoma in an African lion (*Panthera leo*). J Zoo Wildl Med. 2013;44(3):721-7.
26. Wolfe LL, Spraker TR. Oral papillomatosis in Canada Lynx (*Lynx canadensis*). J Wildl Dis. 2007;43(4):731-3.
27. Tafuri WL, Santos RL, Arantes RME, Gonçalves R, Melo MN, Michalick MSM, Tafuri WL. An alternative immunohistochemical method for detecting *Leishmania* amastigotes in paraffin embedded canine tissues. J Immunol Methods. 2004;292:17-23.