BJVP
Brazilian Journal of Veterinary Pathology
ISSN 1983-0246

Case Report

Primary diffuse mammary hemangiosarcoma in a female dog

Antônio F. Leis Filho[1], Patricia F. Lainetti[1], Marina A. Cyrino[1], Priscila E. Kobayashi[2], Camila D. Costa[2], Laíza S. Camargo[1], Fabiana F. Souza[1], Renée Laufer-Amorim[2], Carlos E. Fonseca-Alves[2*]

[1]Department of Animal Reproduction and Veterinary Radiology, São Paulo State University – UNESP, Botucatu, São Paulo, Brazil
[2]Department of Veterinary Clinic, São Paulo State University – UNESP, Botucatu, São Paulo, Brazil
[*]**Corresponding author:** Department of Veterinary Clinic, FVMZ, São Paulo State University – UNESP, Brazil. E-mail: carlos.e.alves@unesp.br

Submitted October 30th 2017, Accepted January, 3rd 2018

Abstract

In veterinary medicine, primary mammary hemangiosarcoma is a very rare disease and there was no previous report describing the disease in dogs. Herein, we describe necropsy findings of a female dog, which presented a diffuse mammary hemangiosarcoma affecting the mammary gland. A diffuse irregular plaque was found in all mammary gland, involving the whole mammary gland tissue. The histopathological evaluation revealed neoplastic cells with an ovoid to spindle shaped basophilic and numerous atypical neoplastic tumor cells forming vascular structures. There was no glandular proliferation and no changes in the superficial dermis and no neoplastic emboli in the lymph vessels. Immunohistochemistry for vimentin, pan-cytokeratin, CK8/18 and CD31 was conducted. Positive expression was found to the pan-cytokeratin and CK8/18 by remaining epithelial cells confirmed the luminal mammary origin. Vimentin and CD31 positive expression by neoplastic cells confirmed the endothelial origin of the neoplasia. The histopathological and immunohistochemical findings supported the diagnosis of a primary mammary hemangiosarcoma.

Key words: dog, mammary neoplasia, angiosarcoma, endothelial cells, neoplasia.

Introduction

Hemangiosarcoma of the mammary gland is a mesenchymal malignant proliferation of endothelial cells from the parenchyma of the mammary gland (6). Primary mammary hemangiosarcoma is an uncommon disease in Veterinary Medicine, accounting less than 2.2% of all canine malignant mammary tumors (5, 10).

In women, the occurrence of primary breast sarcomas is also exceptionally rare, being less than 1% of all malignant breast tumors (12). Among all the malignant breast tumors, angiosarcoma (hemangiosarcoma human counterpart) represent 0.005% (1, 2). Angiosarcoma affecting mammary gland can be divided into 2 primary subtypes, mammary and cutaneous. In humans, cutaneous angiosarcoma has an important iatrogenic aspect, closely linked with the use of radiotherapy for treatment of breast cancer, being the most common post-radiation sarcoma (9).

The primary sign of breast angiosarcoma in humans is the appearance of palpable masses in the mammary parenchyma that can often show rapid growth (4). In cases in which the tumor mass becomes significantly large, signs compatible with Kasabach Merritt syndrome, such as petechial and suffusion, may occur in both the skin and internal organs. In addition, other common aspect of this syndrome is thrombocytopenia and anemia (7).

The prognosis of the human patient with primary angiosarcoma is related to tumor size, tumor grade and negative surgical margins. However, in cases of cutaneous angiosarcoma, after radiotherapy treatment for breast cancer, the prognosis is always poor (11). Primary canine hemangiosarcoma are described as a mesenchymal subtype in different mammary gland tumor classification (5, 6, 8). However, there were few previous description of a primary mammary hemangiosarcoma in veterinary literature. Thus,

 All rights reserved 2007.

this paper aimed to describe a primary hemangiosarcoma affecting the mammary gland.

Case Report

A 10-year-old female dog was admitted to the Veterinary Teaching Hospital at FMVZ – UNESP with a diffuse edema and hemorrhage of the mammary chain and history of a previous lumpectomy for a non-diagnosed mammary gland tumor one month ago. After this previous surgery, the dog presented generalized edema in the suture line and was prescribed dexamethasone (0.1 mg/kg, SID, during 5 days) and enrofloxacin (5 mg/kg, SID, during 5 days). On physical examination, it presented pale mucous membranes, enlarged popliteal lymph nodes, and there was a firm and erythematous plaque involving the whole mammary gland chain followed by a massive edema (Figs. 1A and B). Both pelvic (Fig. 1C) and thoracic (Fig. 1D) limbs had an infiltrating, irregular and erythematous tumor mass invading the medial surface. The bitch did not demonstrated pain in mammary region or during clinical manipulation.

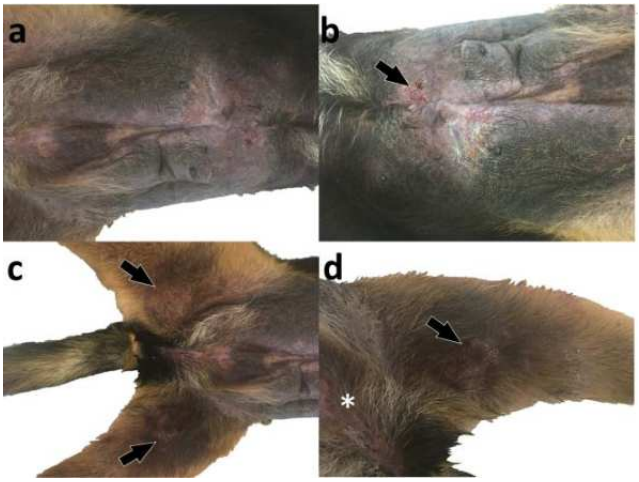

Figure 1. A 10-year-old female dog presenting a diffuse mammary gland plaque. **A.** It is possible to note edema, large purple patches and erythema. **B.** It was also observed cutaneous fissures with hemorrhage (arrow). **C.** Pelvic limbs had a bilateral infiltrating, irregular and erythematous tumor mass invading the medial surface (arrows). **D.** The medial surface of the right thoracic limb was also affected (arrow). Additionally, it was possible to observe an erythema (asterisk) in the thoracic mammary gland region.

A complete blood count (CBC) was performed and revealed a severe regenerative anemia (12% of red blood cells) and thrombocytopenia. The leukogram showed an increase in the metamyelocyte and also the segmented neutrophil count. Cytological analysis was performed and revealed a high number of erythrocytes and a presence of few binucleated undifferentiated cells, with evident nucleolus and coarse chromatin. Due the diffuse edema, the locomotion disability and the poor patient's prognosis, euthanasia was performed.

A complete necropsy was performed and we tumor growth invading the medial aspect of the left and right thigh (Fig. 1C), as well as generalized edema and hyperemia of the mammary gland and the thoracic and pelvic limbs. The macroscopic evaluation of the mammary gland revealed a diffuse edema with a huge hemorrhagic area, containing clots. It was observed a bilateral enlargement of the axial, inguinal and popliteal lymph nodes and during macroscopic evaluation, we observed cavities containing blood and clots. Thus, the histopathological evaluation suggested a mammary hemangiosarcoma with capillary appearance. Additionally, we observed multifocal necrotic area in all lymph nodes. No gross lesions were observed in internal organs and cavities. There was no involvement of the spleen, liver, heart, lungs and brain tissues. Tissue specimens from mammary gland and lymph nodes were collected and fixed in 10% neutral-buffered formalin for 48 hours. Then, tissue samples were routinely processed into paraffin blocks and stained by hematoxylin and eosin (HE) for light microscopy.

The microscopic evaluation of the mammary gland revealed pleomorphic neoplastic cells with an ovoid to spindle shaped morphology, oval and hyperchromatic nucleus, scant and basophilic cytoplasm forming vascular structures, localized to the dermis (Fig. 2). It was observed 29 mitotic figures in 10 high power filed. Interestingly, the remaining glandular mammary tissue were lined by neoplastic endothelial cells in an irregular distribution. No neoplastic infiltration was observed in the superficial dermis and there was no neoplastic embolus in the lymph vessels (Figs. 2A and B). There was a diffuse invasion of the mammary tissue by inflammatory cells (lymphocytes, macrophages) and multifocal hemorrhagic areas with hemosiderin laden macrophages (Fig. 2C). Microscopically, all lymph nodes showed extensive multifocal necrotic areas with infiltration macrophages. There was invasion of the lymph node structure with destruction of the germinal centers by an undifferentiated round to spindle shaped neoplastic cells (Fig. 2D). Additionally, it was observed neoplastic infiltration to the rectus abdominis muscle (Fig. 3). The macroscopic and histological findings suggested a mammary hemangiosarcoma with lymph node metastasis.

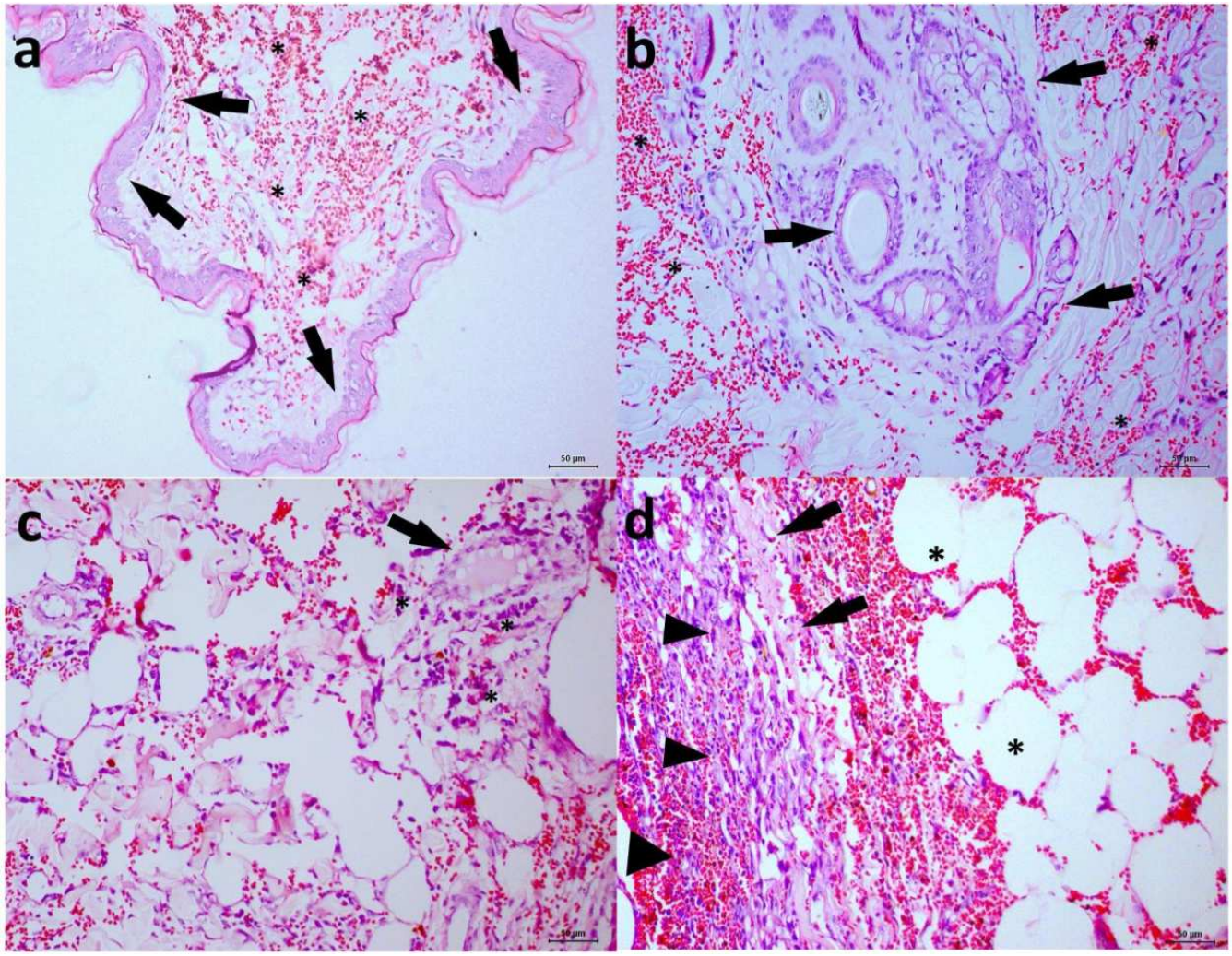

Figure 2. Histopathological evaluation of the mammary gland tissue and lymph nodes. **A.** The superficial dermis and subcutaneous tissues were not affected by the neoplastic cells (arrows). There was a diffuse subcutaneous hemorrhage (asterisk) with no evidence of neoplastic proliferation. **B.** A high power field of the adnexa cutaneous glands. Here, it was also observed hemorrhagic areas. **C.** It is possible to observe one remaining mammary gland (filled with secretion - arrow) surrounded by a neoplastic proliferation of endothelial cells forming blood vessels structures (asterisk). **D.** Lymph node parenchyma showing a diffuse hemorrhagic area. It is possible to observe hemorrhagic area in the lymph node peripheral fat (asterisk) and an invasion of the lymph node capsule (arrows). There is a diffuse neoplastic proliferation of endothelial cells forming blood vessels (arrowhead). Hematoxylin and eosin staining.

Immunohistochemical evaluation of pan-cytokeratin, CK8/18, vimentin and CD31 was performed to confirm the diagnosis. For this, antigen retrieval was performed using 10 mM sodium citrate pH 6.0 buffer in the pressure cocker (Pascal, Dako, Carpinteria, CA, USA). The peroxidase blocking was performed using peroxidase-blocking reagent (Spring Biosciences, Pleasanton, CA, USA) and protein blocking was performed using ready-to-use protein block (Pascal, Dako, Carpinteria, CA, USA). Then, the primary antibodies vimentin (monoclonal mouse, Invitrogen, Carlsbad, CA, USA) at 1:300, pan-cytokeratin (monoclonal mouse, Invitrogen, Carlsbad, CA, USA) at 1:300, CK8/18 (monoclonal mouse, Leica biosystems, Wetzlar, Germany) at 1:600 and CD31 (polyclonal rabbit, Abcam, Cambridge, UK) at the 1:50 dilution were incubated overnight at 4°C. The secondary antibody (Envision, Dako, Carpinteria, CA, USA) was incubated for 1h at room temperature and chromogen system (DAB, Dako, Carpinteria, CA, USA) was used to reveal the reaction. A normal mammary gland tissue was used as a positive control for vimentin, pan-cytokeratin, CK8/18 and CD31 antibodies. Additionally, we identified positive internal controls for all antibodies. For negative control of mouse antibodies, was used mouse universal negative control (Dako, Carpinteria, CA, USA) and for CD31 anti-rabbit antibody, the rabbit immunoglobulin fraction (Dako, Carpinteria, CA, USA) according to the manufacture's instruction.

There was positive pan-cytokeratin expression in squamous cells from superficial dermis and the adnexa glands (internal controls) and few positive mammary glands (Fig. 4A). There was no CK8/18 expression in squamous cells from dermis and cutaneous adnexa glands. However, the mammary glands had positive expression. The pan-cytokeratin and CK8/18 positive mammary glands were surrounded by neoplastic spindle cells (Fig. 4B). All epithelial structures were negative, and neoplastic cells, blood vessels and stromal cells were positive for vimentin (Fig. 4C) and CD31 (Fig. 4D).

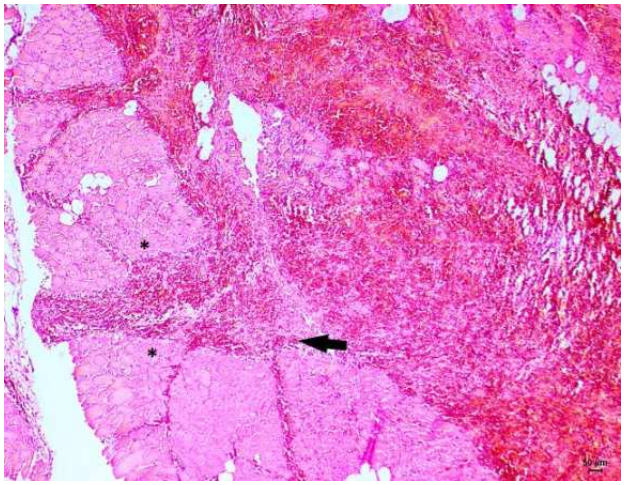

Figure 3. Microscopic evaluation of the mammary hemangiosarcoma infiltration. The neoplastic cells (arrow) were invading the rectus abdominis muscle (asterisk). It was also observed a diffuse hemorrhagic area.

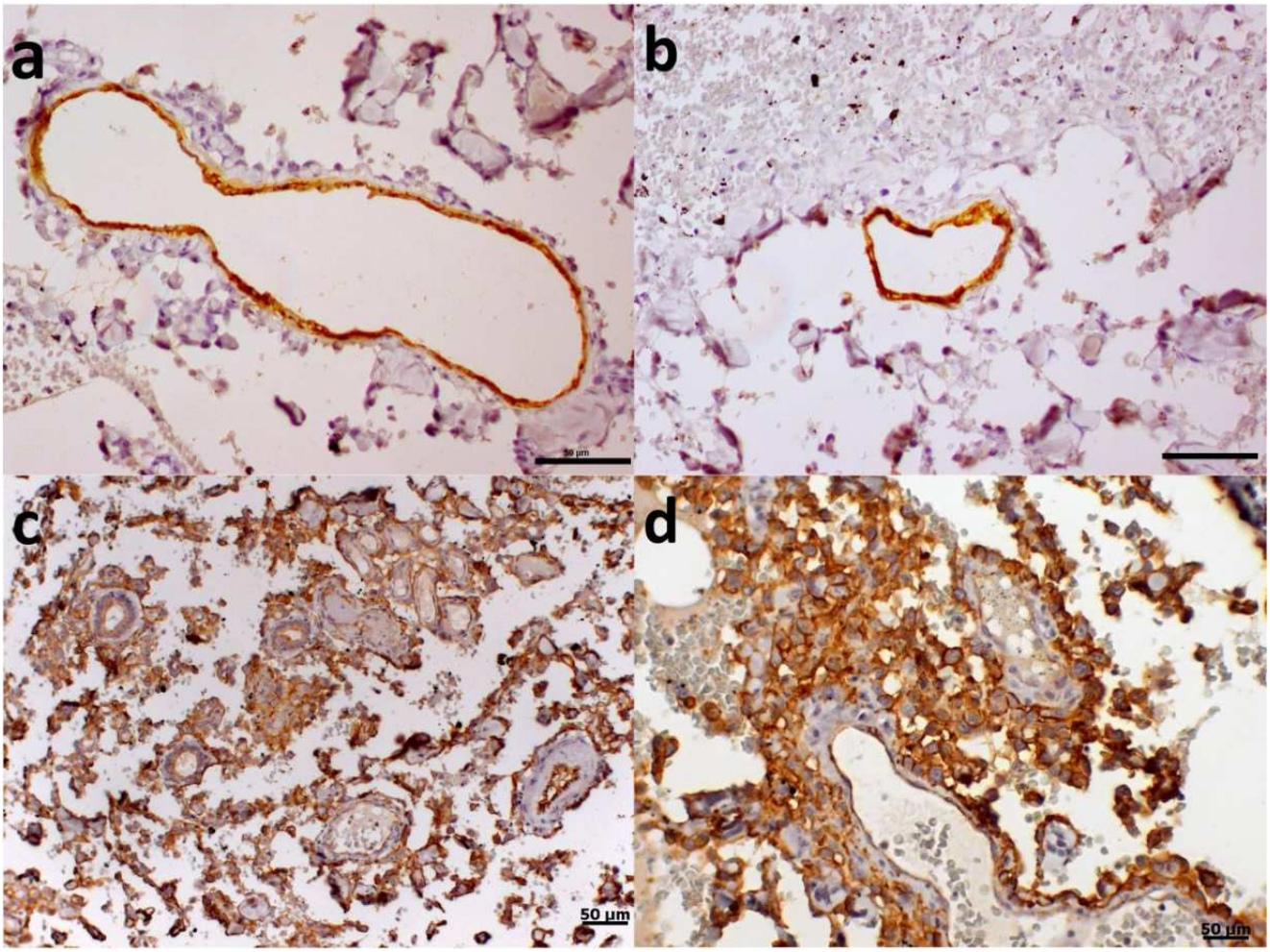

Figure 4. Immunohistochemical evaluation of pan-cytokeratin, CK8/18, vimentin and CD31 markers. **A.** Pan-cytokeratin positive expression in the mammary gland hemangiosarcoma. It is possible to observe positive mammary tubule and no expression by neoplastic cells. **B.** Positive CK8/18 expression in the remaining mammary tubule surrounded by negative neoplastic cells. **C.** Positive expression of vimentin by neoplastic cells. **D.** Positive CD31 expression by neoplastic cells. Hematoxylin counterstaining, DAB. Bar 50µ.

Discussion

Primary mammary hemangiosarcoma is a very rare histological subtype and its biological behavior and prognosis in dogs is unknown. Sala et al. (10) performed an epidemiological study of mammary tumors in female dogs in a period of 10 years and found a hemangiosarcoma frequency of 2.2%. However, this study used biopsy samples from mammary gland tumors and the authors did not provide the specific criteria to considerer these cases as primary mammary hemangiosarcoma. To our knowledge, there are no previous report of primary mammary gland hemangiosarcoma in female dogs.

In this atypical case, the animal had a history of primary mammary tumor surgically removed with no histopathological evaluation. Two days after this previous procedure, a diffuse edema and erythematous plaque involving the whole mammary glands was formed suggesting an inflammatory mammary carcinoma (IMC). The history of previous surgical procedure in patients with IMC is common. Souza et al. (13) described the clinical finding of 12 dogs with IMC and 66.66% (8/12) had secondary IMC. Thus, our first suspicious was a secondary IMC.

The cytological examination was performed, and it was possible to identify a high number of erythrocyte and few atypical cells. Unfortunately, the cytology evaluation was not able to provide a definitive diagnosis. The subject was euthanized due to the patient's poor clinical condition. During necropsy was possible to identify a diffuse subcutaneous hemorrhage in the whole mammary gland chain and the involvement of axillar lymph nodes. The histopathological examination revealed a malignant proliferation of endothelial cells with no superficial dermal or subcutaneous involvement. According to Goldschmidt et al. (6), mammary hemangiosarcoma need to arise from the mammary tissue and exclusion of dermal or subcutaneous involvement is crucial.

An interesting finding in this report was the diffuse mammary gland involvement with petechial and suffusion associated to thrombocytopenia and anemia. In humans, the angiosarcoma diagnosis associated with these clinical and laboratorial finding is called as Kasabach Merritt syndrome (7). However, there was no previous description of this syndrome in veterinary medicine. The major limitation of this case was the absence of histopathological diagnosis in the previous mammary tumor. Thus, we are not able to associate the diffuse mammary hemangiosarcoma with the previous tumor.

The histopathological evaluation revealed a mesenchymal proliferation surround remaining normal glands. We stained the tissue samples for pan-cytokeratin and CK8/18 and the epithelial glands surrounded by neoplastic cells had a pan-cytokeratin+/CK8/18+ phenotype, indicating a luminal/mammary origin. It was not expected a positive CK8/18 expression in the epithelial cells from dermis or adnexa glands from subcutaneous tissue (3). The expression of CD31 by neoplastic cells confirmed the endothelial origin.

In conclusion, we described a rare case of primary hemangiosarcoma affecting the mammary gland in a female dog, supported by CD31 positive cells surrounded by epithelial mammary gland cells. This tumor presented a very aggressive behavior, developing lymph node metastasis in a short period.

Conflict of interest

The author declared no potential conflicts of interest with respect to the research, authorship, and/or publication of this article.

References

1. Abbad F, Idrissi NC, Fatih B, Fakhir B, Drissi J, Khouchani M, Rais H. Primary breast angiosarcoma: a rare presentation of rare tumor - case report. BMC Clin Pathol. 2017;17:17.
2. Adem C, Reynolds C, Ingle JN, Nascimento AG. Primary breast sarcoma: clinicopathologic series from the Mayo Clinic and review of the literature. Br J Cancer. 2004;91(2):237-41.
3. Amin SM, Beattie A, Ling X, Jennings LJ, Guitart J. Primary Cutaneous Mammary Analog Secretory Carcinoma with ETV6-NTRK3 Translocation. Am J Dermatopathol. 2016;38(11):842-5.
4. Arora TK, Terracina KP, Soong J, Idowu MO, Takabe K. Primary and secondary angiosarcoma of the breast. Gland surgery. 2014;3(1):28-34.
5. Cassali GD, Lavalle GE, Ferreira E, Estrela-Lima A, De Nardi AB, Ghever C, Sobral RA, Amorim RL, Oliveira LO, Sueiro FAR, Beserra HEO, Bertagnolli AC, Gamba CO, Damasceno KA, Campos CB, Araujo MR, Campos LC, Monteiro LN, Nunes FC, Horta RS, Reis DC, Luvizotto MCR, Magalhães GM, Raposo JB, Ferreira AMR, Tanaka NM, Grandi F, Ubukata R, Batschinski K, Terra EM, Salvador RCL, Jark PC, Delecrodi JER, Nascimento NA, Silva DN, Silva LP, Ferreira KCRS, Frehse MS, di Santis GW, Silva EO, Guim TN, Kerr B, Cintra PP, Silva FBF, Leite JS, Mello MFV, Ferreira MLG, Fukumasu H, Salgado BS, Torres R. Consensus for the Diagnosis, Prognosis and Treatment of Canine Mammary Tumors – 2013. Braz J Vet Pathol. 2014;7(2):38-69.
6. Goldschmidt M, Peña L, Rasotto R, Zappulli V. Classification and grading of canine mammary tumors. Vet Pathol. 2011;48(1):117-31.
7. Hall GW. Kasabach–Merritt syndrome: pathogenesis and management. Br J Haematol. 2001;112(4):851-62.
8. Misdorp W. Tumors of the Mammary Gland. In: Meuten DJ, editor. Tumors in Domestic Animals. 4th ed. Ames, Iowa: Iowa State Press; 2002. p.575-606.

Braz J Vet Pathol, 2018, 11(3), 102 – 107
DOI: 10.24070/bjvp.1983-0246.v11i3p102-107

9. Pencavel TD, Hayes A. Breast sarcoma - a review of diagnosis and management. Int J Surg. 2009;7(1):20-3.
10. Salas Y, Márquez A, Diaz D, Romero L. Epidemiological Study of Mammary Tumors in Female Dogs Diagnosed during the Period 2002-2012: A Growing Animal Health Problem. PLoS One. 2015;10(5):e0127381.
11. Seinen JM, Styring E, Verstappen V, von Steyern FV, Rydholm A, Suurmeijer AJ, Hoekstra HJ. Radiation-associated angiosarcoma after breast cancer: high recurrence rate and poor survival despite surgical treatment with R0 resection. Ann Surg Oncol. 2012;19(8):2700-6.
12. Sher T, Hennessy BT, Valero V, Broglio K, Woodward WA, Trent J, Hunt KK, Hortobagyi GN. Primary angiosarcomas of the breast. Cancer. 2007;110(1):173-8.
13. Souza CHM, Toledo-Piza E, Amorin R, Barboza A, Tobias KM. Inflammatory mammary carcinoma in 12 dogs: clinical features, cyclooxygenase-2 expression, and response to piroxicam treatment. Can Vet J. 2009;50(5):506-10.