BJVP
Brazilian Journal of Veterinary Pathology
ISSN 1983-0246

Case Report

Pulmonary adenocarcinoma in mare

Mayane Faccin[1], Filipe K. Cestari[1], Mônica R. Matos[1], João Pedro Cavasin[1], Anna Zimmermann[2], Flávio H. Carvalho[2], Geane M. Pagliosa[3], Aline M. Viott[4*]

[1]Veterinary Pathology Laboratory, Universidade Federal do Paraná (UFPR), Rua Pioneiro, 2153, Jardim Dallas, 85950-000, Palotina, PR, Brazil.
[2]Clinic and Surgery of Farming Animals, Universidade Federal do Paraná (UFPR), Rua Pioneiro, 2153, Jardim Dallas, 85950-000, Palotina, PR, Brazil.
[3]Adjunct Professor of Clinic and Surgery of Farming Animals, Universidade Federal do Paraná (UFPR), Rua Pioneiro, 2153, Jardim Dallas, 85950-000, Palotina, PR, Brazil.
[4]Adjunct Professor of Veterinary Pathology, Universidade Federal do Paraná (UFPR), Rua Pioneiro, 2153, Jardim Dallas, 85950-000, Palotina, PR, Brazil.
*__Corresponding author:__ E-mail: alinedemarco@gmail.com.br

Submitted July, 7th 2017, Accepted October, 16th 2018

Abstract

Primary lung neoplasms are infrequent in veterinary medicine, particularly in large animals. The most frequently affected species are dogs and cats. These neoplasias are usually malignant and the adenocarcinoma type is the most frequent. This paper describes a case of pulmonary adenocarcinoma in a mare, including its pathological and immunohistochemical features. The animal had natural death and was submitted for necropsy. Diffuse jaundice, splenomegaly due to red pulp hyperplasia, pulmonary edema and congestion were observed. Cytological evaluation of the spleen revealed intracytoplasmatic structures in erythrocytes, compatible with *Babesia* sp. Histopathology of the lung revealed a neoplastic proliferation of epithelial cells, forming acinar and tubular structures supported by a fibrovascular stroma. Immunohistochemistry of such lesions was positive for cytokeratin and napsin A, negative for vimentin and thyroid transcription factor 1, corroborating the diagnosis of adenocarcinoma. Lung carcinomas in equines are described in animals ranging from four to 23 years old, without breed or sex predisposition. Clinical signs, when present, are related to the compromise of respiratory function, which was not observed in the present case. Pulmonary neoplasms must be considered among the diagnostics of chronic respiratory diseases. Histopathological and immunohistochemistry exams are highly valuable for classification of primary lung neoplasms.

Key words: carcinoma, pulmonary, primary pulmonary neoplasm.

Introduction

Primary lung neoplasms are usually malignant, most frequent in old dogs and cats and less common in farm animals, possibly because they do not have the opportunity to reach older age (12). Among all types of pulmonary neoplasms, adenocarcinoma is the most frequent, followed by squamous cell carcinoma, bronchial gland carcinoma and alveolar carcinoma (15).

Primary lung neoplasms are rare in equines. Among 38 individuals affected by thoracic neoplasms, only two cases (5.3%) of neoplasia were found primarily from lungs (14). This paper aims to describe the pathological and immunohistochemical aspects of an equine pulmonary adenocarcinoma.

Case report

A 23 years old mare of undefined breed was received for necropsy at the Veterinary Pathology Laboratory, Universidade Federal do Paraná, Palotina. The mare presented with lethargy the day before, leading to death during the following night. No other clinical signs were reported. Necropsy revealed mild wasting and jaundice, slight splenomegaly due to red pulp hyperplasia and mild reddish discoloration of the kidneys (hemoglobinuria). Lungs exhibited severe diffuse edema

 All rights reserved 2007.

and emphysematous borders with bilateral focally extensive hemorrhage, between the cranial and caudal lobes (Fig. 1). Other macroscopic findings include marked enlargement of the hypophysis and focal, mild, ulcerative gastritis. Fragments of tissues were fixed in 10% formalin, embedded in paraffin, and routinely processed for hematoxylin and eosin staining (13).



Figure 1. Lung, pulmonary adenocarcinoma, equine, undefined breed, female, 23 years. Reddish, humid character, subcrepitant, indicative of edema and congestion (asterisk).

Microscopically, mild, multifocal suppurative pericarditis was observed. Multiple foci of perilobular and periportal to bridging fibrosis with mild cholestasis (cirrhosis) and multifocal suppurative hepatitis. The kidney had diffuse nephrosis of proximal tubules, and the spleen had marked diffuse red pulp hyperplasia, hemosiderosis and intraerythrocytic basophilic, club-shaped structures compatible with *Babesia* sp. The spleen revealed diffuse, marked red pulp hyperplasia, hemosiderosis and erythrocytes with intracytoplasmic, basophilic, club-shaped structures, compatible with *Babesia* sp. A hypophyseal adenoma was also observed.

Histological analysis of both lung hemispheres revealed multiple small foci of moderately cellular, well-demarcated, infiltrative, non-encapsulated neoplastic proliferation of bronchial epithelium, moderately cellular, well-demarcated, infiltrative, non-encapsulated. Cells were organized in acinar structures resembling atypical bronchioles, grouped over a vast fibrovascular stroma. Cytoplasm of these cells was moderate, irregular and slightly vacuolated. Nucleus was big, round, eccentric, loose chromatin, with one big nucleolus. Anisocytosis and anisokaryosis varied from mild to accentuated. There were one or two mitosis per high power field (Figs. 2 and 3). A few neutrophils were present inside the neoplastic acinus. Peripheral to the neoplastic tissue, areas of emphysema, moderate lymphohystioplasmocytic bronchitis and peribronchitis with accentuated fibrosis were observed. Fragments of lung neoplasm were submitted to immunohistochemistry with pancytokeratin (pan CK) (Fig. 4), cytokeratin 7 (CK7) (Fig. 5), thyroid transcription factor-1 (TTF-1) (Fig. 6), napsin A (Fig. 7) and vimentin antibodies (17). Specimens were positive for CK pan, CK7 and napsin A and negative for TTF-1 and vimentin. As no other foci of neoplasia were grossly evident on other organs and the animal did not have record of previous neoplasia, the diagnosis of the pulmonary lesion was of primary pulmonary adenocarcinoma of acinar type.

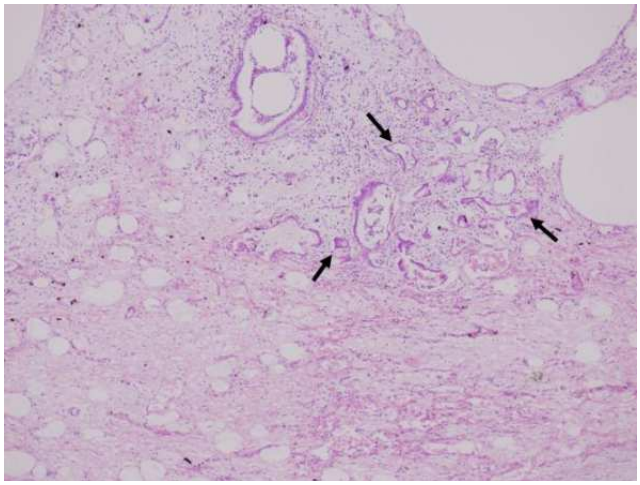

Figure 2. Lung, pulmonary adenocarcinoma, equine, undefined breed, female, 23 years. A malignant neoplastic proliferation of bronchial epithelium, with formation of primitive bronchioles (arrows) is observed. (HE. 4X).

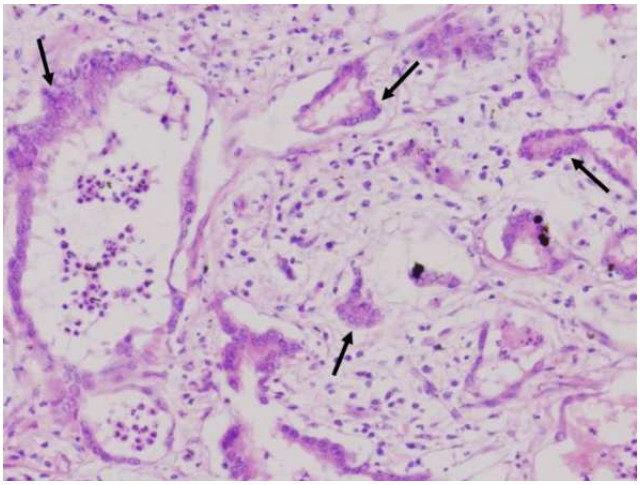

Figure 3. Lung, pulmonary adenocarcinoma, equine, undefined breed, female, 23 years. Cells with vesiculous nuclei, loose chromatin and evident nucleoli (arrows). (HE. 20X).

Discussion

Primary pulmonary carcinomas have already been described in equines (4, 7), bovines (8, 16), rodents (1), dogs (2) and cats (13). Although considered a disease of older animals (12), lung carcinomas have been reported in

equines between 4 (7) and 23 years (4). Literature does not cite breed or sex predisposition, but most reports describe the disease in females, as seen in this case (14, 4). Purebred or mixed breed animals can be affected (4, 7, 14).

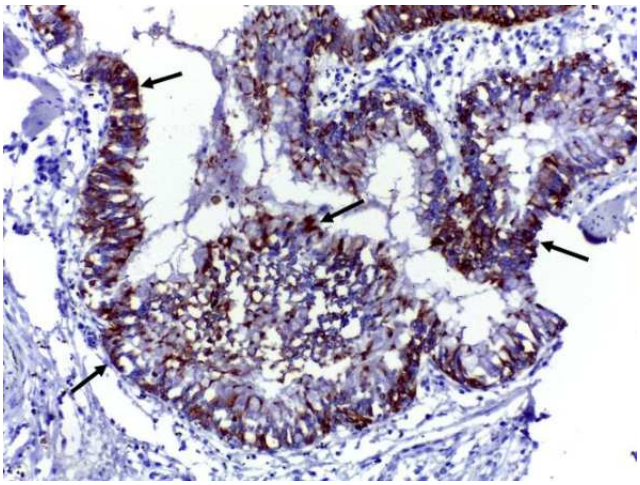

Figure 4. Lung, pulmonary adenocarcinoma, equine, undefined breed, female, 23 years. Positive staining of bronchial epithelium for pan CK (arrows). Immunohistochemistry (10X).

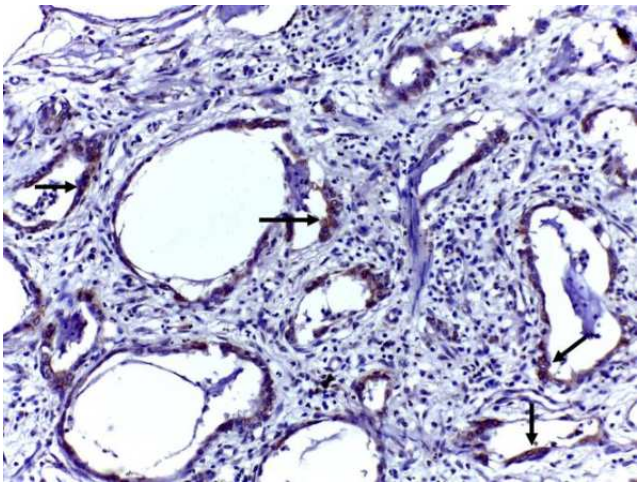

Figure 5. Lung, pulmonary adenocarcinoma, equine, undefined breed, female, 23 years. Positive staining of bronchial epithelium for CK-7 (arrows). Immunohistochemistry (10X).

Clinical signs, when present, are related to compression, invasion or obstruction of the anatomical structures affected, but respiratory failure usually occurs when a great part of lung parenchyma is compromised (6). In this case, except for lethargy, other clinical signs were not observed, especially, no evidence of pulmonary disease was noted clinically. Affected equines generally present inappetence, weight loss, lethargy, dyspnea, chronic coughing, intermittent fever, and serous or bloody nasal secretion, with two to five weeks of rapid evolution (4, 7, 14). Systolic murmur and tachycardia may be observed when there is cardiac impairment due to metastasis (7). In other affected species, clinical signs tend to be similar (2, 8, 11, 16).

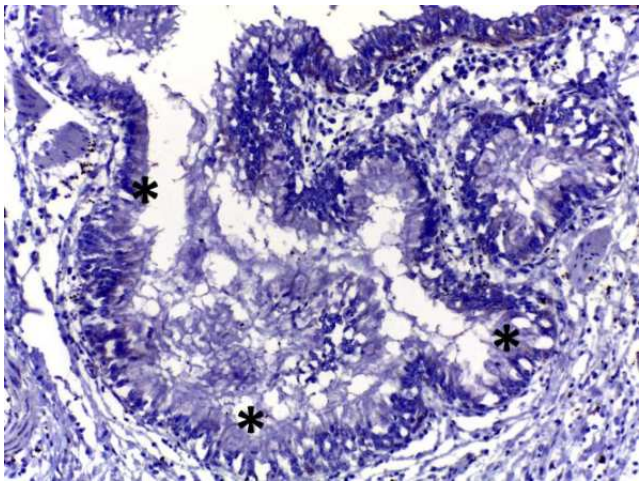

Figure 6. Lung, pulmonary adenocarcinoma, equine, undefined breed, female, 23 years. Negative staining of bronchial epithelium for TTF-1 (asterisks). Immunohistochemistry (10X).

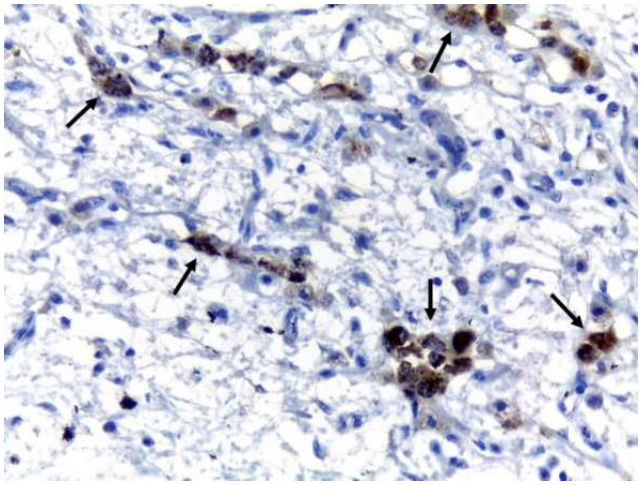

Figure 7. Lung, pulmonary adenocarcinoma, equine, undefined breed, female, 23 years. Positive staining of bronchial epithelium for Napsin A (arrows). Immunohistochemistry (40X).

The most important macroscopic and microscopic findings observed in this case, such as splenomegaly, hemolysis, hemoglobinuria, red pulp hyperplasia, hemosiderosis, nephrosis, intra-erythrocyte parasitic structures compatible with *Babesia* sp., are indicative of equine babesiosis. This disease, also called piroplasmosis, is caused by *Theileria equi* and/or *Babesia caballi*. Clinical signs and pathological findings are a consequence of intravascular hemolysis, leading to death as a consequence of shock and respiratory distress due to severe anemia (21). In the present case, shock was aggravated by pulmonary edema and hemorrhage observed.

 All rights reserved 2007.

Macroscopic analysis of lung tissue did not reveal lesions suggestive of neoplasia, diverging from literature that describes single or multiple, well demarcated nodules, surrounded by fibrous tissue, varying from white, to yellow, to red, reaching over to 40 cm in diameter (4, 7, 14). In equines, metastasis has been reported to lymph nodes, mediastinum, adrenal glands, heart, blood vessels, kidneys, muscles and distant lymph nodes (7,14). In bovines, masses tend to be multiple, up to 10 cm in diameter, eventually forming a large mass encompassing the mediastinal and epigastric lymph nodes and part of the liver (8, 16). Frequently, pulmonary carcinomas in bovines are incidental findings at slaughterhouses (8, 19). Differently from farm animals, in dogs and cats neoplastic masses are usually multiple, ranging from 0.3 cm to 5 cm in diameter. In these species, metastasis has been reported to regional lymph nodes and semimembranosus muscle (2, 11). In addition, cats can show lameness as a consequence of metastasis to the dorsal region of distal phalanges and under the epidermis of the pads (6). On this report, the pulmonary adenocarcinoma was an incidental finding. Nonetheless, due to the babesiosis, death occurred before any clinical signs or grossly detectable lesions.

Generally, human pulmonary adenocarcinomas may be histologically classified according to tumoral organization in adenocarcinoma *in situ*, minimally invasive, lepidic predominant, papillary predominant, acinar predominant, solid, and micropapillary predominant (20). In dogs, classification of adenocarcinomas is based on tumoral differentiation, pleomorphism grading, nucleoli size, presence of necrosis, fibrosis, mitotic index, and demarcation of the mass (6). However, more aggressive neoplasms tend to have solid or acinar pattern, disorganized or multiple cells layer overlaying papillae, neoplastic invasion of tumoral stroma and adjacent alveoli (6).

Histologic findings observed in this case were consistent with the described literature, except for the mitotic index described for others pulmonary adenocarcinomas in horses. While a high mitotic index has been reported (7, 14), a low mitotic index has also been stated, similar to the observed in this case (4). This may be explained by variation in malignancy and histological subtype in each report. In a single case, one well-differentiated equine pulmonary adenocarcinoma displayed bone metaplasia of the associated connective tissue (14).

Non-neoplastic microscopic findings were also observed in this report, such as emphysema, moderate lymphohystioplasmacytic bronchitis and peribronchitis with accentuated fibrosis. Other authors described lesions associated with pulmonary neoplasms, including hemorrhage, hemosiderosis, necrosis, fibrin, and infiltrate of neutrophils, lymphocytes, reactive macrophages, and bacterial colonies, which can be found either adjacent to the neoplasm or on the contralateral lung (4, 7).

Useful immunohistochemical markers to differentiate primary pulmonary neoplasias include pancytokeratin, which identifies epithelial cell origin, and specific cytokeratins, such as CK-7, specific for glandular epithelium (18). On the present case, positivity for pan CK and CK-7 indicates epithelial and glandular origin of the neoplasia. Napsin A is a marker of pulmonary adenocarcinomas, renal cell carcinomas, ovarian adenocarcinomas, and clear cell adenocarcinomas of ovary and uterus (10), whereas TTF-1 is a marker expressed in normal lung and thyroid tissue, as well as neoplastic (3). Testing for these two markers is recommended to determinate the origin of lung neoplasia (10). The samples were positive to Napsin A and negative to TTF-1. Negativity of the sample for such markers, like TTF-1, is possibly due to prolonged fixation (3) or technique sensibility, which ranges from 64% to 95% in several studies (6). There was immunoreactivity for TTF-1 in other components of lung (Figure 6), but not in the tumor cells. What demonstrates that in this case, probably, the technique sensibility was low. Moreover, Napsin A can be positive in up to 83% of the cases of pulmonary adenocarcinomas, versus only 57% of positivity of the TTF-1 (9). The samples were negative for vimentin. Some pulmonary carcinomas may be vimentin positive, mostly the less differentiated, that undergo mesenchymal transformation, which was not observed in this report (5).

According to the histopathological findings, the positivity for Napsin A of neoplastic cells of the lung and the absence of neoplasia in other organs, the diagnosis of the lesion in the lung was primary pulmonary adenocarcinoma acinar type.

Primary pulmonary neoplasms are rare and can be considered an incidental necropsy finding in the absence of clinical signs and death due to other causes. It must be included among differential diagnosis in the presence of chronic respiratory signs that are nonresponsive to treatment. Use of histopathology and immunohistochemistry techniques is necessary for distinguishing between primary pulmonary neoplasia and metastasis to the lungs.

References

1. Costa LF, Malta MCC, Tinoco HP, Medeiros LB, Bittar ASV, Hoffmann AR, Pierezan F, Paixão TA, Santos RL. Systemic histiocytic sarcoma in a common hippopotamus (*Hippopotamus amphibius*). J Zoo Wildl Med. 2016;47(2):650-3.
2. Bertazzolo W, Zuliani D, Pogliani E, Caniatti M, Bussadori C. Diffuse bronchiolo-alveolar carcinoma in a dog. J Small Anim Pract. 2002;43(6):265-8.
3. Bettini G, Marconato L, Morini M, Ferrari F. Thyroid transcription faction-1 immunohistochemistry: diagnostic tool and malignancy marker in canine malignant lung tumours. Vet Comp Oncol. 2009;7(1):28-37.

 All rights reserved 2007.

4. Binanti D, Stancari G, Fantinato E, Zucca E, Zani DD, Sironi G, Ferrucci, F, Riccaboni P. A case of bronchioloalveolar carcinoma in a mare. J Equine Vet Sci. 2013;33(9):751-5.
5. Burgess HJ, Kerr ME. Cytokeratin and vimentin co-expression in 21 canine primary pulmonary epithelial neoplasms. J Vet Diagn Invest. 2009;21(6):815-20.
6. Caswell JL, Williams KJ. Respiratory system. In: Maxie MG, editor. Jubb, Kennedy & Palmer's Pathology of domestic animals. 6th ed. St. Louis: Saunders Elsevier; 2016. p. 465-591.
7. Dill SG, Moise NS, Meschter CL. Cardiac failure in a stallion secondary to metastasis of an anaplastic pulmonary carcinoma. Equine Vet J. 1986;18(5):414-7.
8. Kadota K, Ito K, Kamikawa S. Ultrastructure and origin of adenocarcinomas detected in the lungs of three cows. J Comp Pathol. 1986;96(4):407-14.
9. Kim JH, Kim YS, Choi YD, Lee JS, Park CS. Utility of napsin A and thyroid transcription factor 1 in differentiating metastatic pulmonary from non-pulmonary adenocarcinoma in pleural effusion. Acta Cytol. 2011;55(3):266-70.
10. Kim MY, Go H, Koh J, Lee K, Min HS, Kim SA, Jeon YK, Lee HS, Moon KC, Park SY, Kim WH, Chung DH. Napsin A is a useful marker for metastatic adenocarcinomas of pulmonary origin. Histopathology. 2014;65(2):195-206.
11. Langlais LM, Gibson J, Taylor JA, Caswell JL. Pulmonary adenocarcinoma with metastasis to skeletal muscle in a cat. Can Vet J. 2006;47(11):1122-3.
12. López A, Martinson SA. In: Zachary JF, editor. Pathologic Basis of Veterinary Disease. 6th ed. St. Louis: Elsevier; 2017. p. 471-560.
13. Luna LG. Manual of histologic staining methods of the Armed Forces Institute of Pathology. 3rd ed. London: McGraw Hill Book Co.; 1968. 258p.
14. Mair, TS, Brown, PJ. Clinical and pathological features of thoracic neoplasia in the horse. Equine Vet J. 1993;23(3):220-3.
15. Moulton JE, Von Tscharner C, Schneider R. Classification of lung carcinomas in the dog and cat. Vet Pathol. 1981;18(4):513-28.
16. Okada Y, Ochiai K, Osaki K, Kimura T, Itakura C. Bronchiolar-alveolar carcinoma in a cow. J Comp Pathol. 1998;118(1):69-74.
17. Ramos-Vara JA, Miller MA. When tissue antigens and antibodies get along: revisiting the technical aspects of immunohistochemistry - the red, brown, and blue technique. Vet Pathol. 2014;51(1):42-87.
18. Tan J, Sidhu G, Greco MA, Ballard H, Wieczorek R. Villin, cytokeratin 7, and cytokeratin 20 expression in pulmonary adenocarcinoma with ultrastructural evidence of microvilli with rootlets. Hum Pathol. 1998;29(4):390-6.
19. Tessele B, Barros CSL. Tumores em bovinos encontrados em abatedouros frigoríficos. Pesq Vet Bras. 2016;36(3):145-60.
20. Travis WD, Brambilla E, Noguchi M, Nicholson AG, Geisinger KR, Yatabe Y, Beer DG, Powell CA, Riely GJ, Van Schil PE, Garg K, Austin JH, Asamura H, Rusch VW, Hirsch FR, Scagliotti G, Mitsudomi T, Huber RM, Ishikawa Y, Jett J, Sanchez-Cespedes M, Sculier JP, Takahashi T, Tsuboi M, Vansteenkiste J, Wistuba I, Yang PC, Aberle D, Brambilla C, Flieder D, Franklin W, Gazdar A, Gould M, Hasleton P, Henderson D, Johnson B, Johnson D, Kerr K, Kuriyama K, Lee JS, Miller VA, Petersen I, Roggli V, Saijo N, Thunnissen E, Tsao M, Yankelewitz D. International association for the study of lung cancer/American Thoracic Society/European Respiratory Society international multidisciplinary classification of lung adenocarcinoma. J Thorac Oncol. 2011;6(2):244-85.
21. Valli, VE. Hematopoietic system. In: Maxie MG, editor. Jubb, Kennedy & Palmer's Pathology of domestic animals. 6th ed. St. Louis: Saunders Elsevier; 2016. p. 102-268.