



Case Report

Papillary renal adenoma in a toco toucan (*Ramphastos toco*)

Alexandre Arenales¹, Frank A. de O. Toledo¹, Ayisa R. de Oliveira¹, Nayara F. de Paula¹, Lucas B. S. de Oliveira², Carlyle M. Coelho², Herlandes P. Tinoco², Renato L. Santos¹

¹Escola de Veterinária, Universidade Federal de Minas Gerais, Belo Horizonte, MG, Brazil. Av. Antônio Carlos, 6627 - São Luiz, Belo Horizonte - MG, 31270-901.

²Jardim Zoológico - Fundação de Parques Municipais e Zoobotânica de Belo Horizonte, 31365-450, Belo Horizonte, Minas Gerais, Brazil.

*Corresponding author: rsantos@vet.ufmg.br

Submitted June 26th 2018, Accepted October 4th 2018

Abstract

Primary renal neoplasms are infrequent in domestic animals and birds, being budgerigars an exception. This report describes a papillary renal adenoma in a toco toucan (*Ramphastos toco*), which was euthanized due to poor prognosis after surgical intervention of phalanx fractures in both wings. Grossly, the caudal pole of the right kidney had a nodular lesion measuring 3.5 x 1.7 x 1.5 cm. Microscopically, there was a well delimited neoplasm arranged in large and coalescent papillary structures composed by a single layer of epithelial cells. There was mild to moderate nuclear and cytoplasmic pleomorphism, whereas mitotic figures were absent. In conclusion, this tumor was considered as an accidental finding, which is similar to the majority of adenomas reported in domestic mammals.

Key words: zoo, renal tumor, avian oncology, wild animals, birds.

Introduction

Primary renal neoplasms are infrequent in domestic mammals (6) and birds (8), with only a few reports of kidney tumors (2, 3, 7). In toucans, there is a report of renal tumor in a channel-billed toucan (*Ramphastos vitellinus*) that was described as a bilateral tubular renal adenomatosis (5). Even though in a large retrospective study (4), which includes toucans, only 4 cases of tumors in Piciformes were found. *Ramphastos toco* is a wide range South American bird, and it is considered as “least concern” by IUCN red list (1). In this report we describe an incidental finding of papillary renal adenoma in a captive toco toucan (*Ramphastos toco*).

Case report

An adult toco toucan (*Ramphastos toco*) was euthanized due to poor prognosis after an unsatisfactory clinical recovery from a surgical intervention of phalanx

fractures in both wings. At necropsy, the caudal pole of the right kidney had a firm, well demarcated, reddish, and slightly multilobulated nodule measuring 3.5 x 1.7 x 1.5 cm (Fig. 1). In addition to the phalanx fractures and renal growth, there were no other relevant lesions.

Microscopically, there was a well circumscribed, expansive, poorly encapsulated, and noninvasive neoplastic tissue compressing the adjacent remaining renal tubules (Fig. 2). The neoplasm was arranged in large and coalescent papillary structures lined by a single layer of columnar and well differentiated epithelial cells, which was sustained by scant fibrous stroma. The epithelial neoplastic cells were characterized by slightly fibrillar, eosinophilic, and scarce to moderate cytoplasm; large, lateralized, and round to elongated nucleus containing granular chromatin and a single prominent nucleolus. There was mild to moderate anisokaryosis and anisocytosis and absence of mitotic figures. These microscopic findings supported the morphologic diagnosis of papillary renal

adenoma. No evidences of micro metastasis were observed in any tissues.

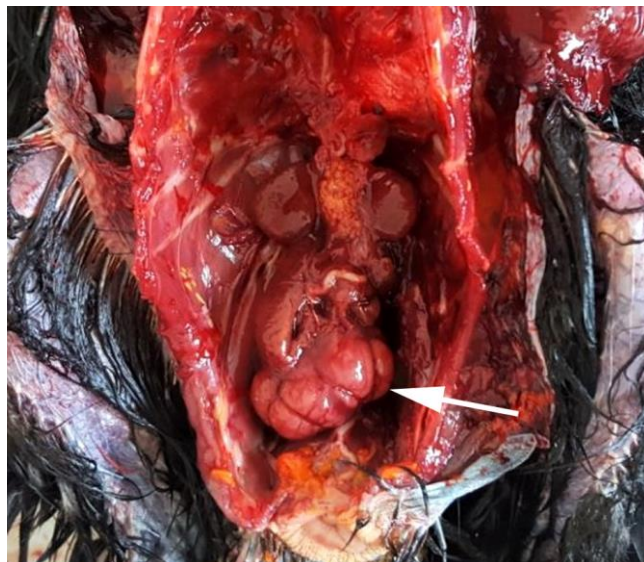


Figure 1. Papillary renal adenoma in a toco toucan (*Ramphastos toco*). Neoplastic growth in the caudal pole of the right kidney (arrow).

Discussion

There are only a few previous reports of renal neoplasms in birds. Effron et al. (1977) (3) found only five renal tumors in a total of 5,957 necropsies of captive wild birds. In contrast to the rarity of this tumor in other species, budgerigars are an exception. Blackmore et al. (1966) (2) found 44 nephroblastomas in 168 caged budgerigars, whereas Neumann and Kummerfeld (1983) (7) described 47 cases of kidney tumor in a total of 74 budgerigars with clinical signs of abdominal tumor. Here we describe a case of papillary renal adenoma in an adult and captive toco toucan with no previous clinical signs related to the neoplasm.

Macroscopic findings in this case were similar to primary renal adenomas in domestic mammals (6), which are usually solitary, well demarcated, unencapsulated and unilateral. However, Mainez et al. (2015) (5) described in a channel-billed toucan (*Ramphastos vitellinus*) a different macroscopic pattern characterized by multiple and coalescent tumors that were microscopically diagnosed as adenomatosis with tubular and some areas of papillary organization. Renal tumor in pet birds usually appears in the cranial portion of the kidney (9), although in this case the neoplasm developed at the caudal pole of the kidney.

Histologically, renal adenomas are also described in domestic mammals and may be classified as tubular, papillary, or solid depending on the predominant morphology (6). As in our case, the papillary subtype is characterized by single layered epithelium with intraluminal projections. This pattern was also described in a case of adenocarcinoma in budgerigars (10). In five cases

described by Effron et al. (1977) (3), there was no benign papillary subtype. They were classified as tubular adenoma (1), tubular adenoma of medulla (1), cortical tubular adenoma (1), and adenocarcinoma (2). Moreover, Mainez et al. (2015) (5) describes multiples adenomas with predominantly tubular pattern.

Finally, considering that this toucan was euthanized and the absence of metastasis, this tumor was considered as an accidental finding. The same usually occurs in domestic mammals (6) and birds (8) with renal adenomas, where renal diseases and tumors are presumably underdiagnosed mainly because the clinical signs are only detectable in more severe circumstances.

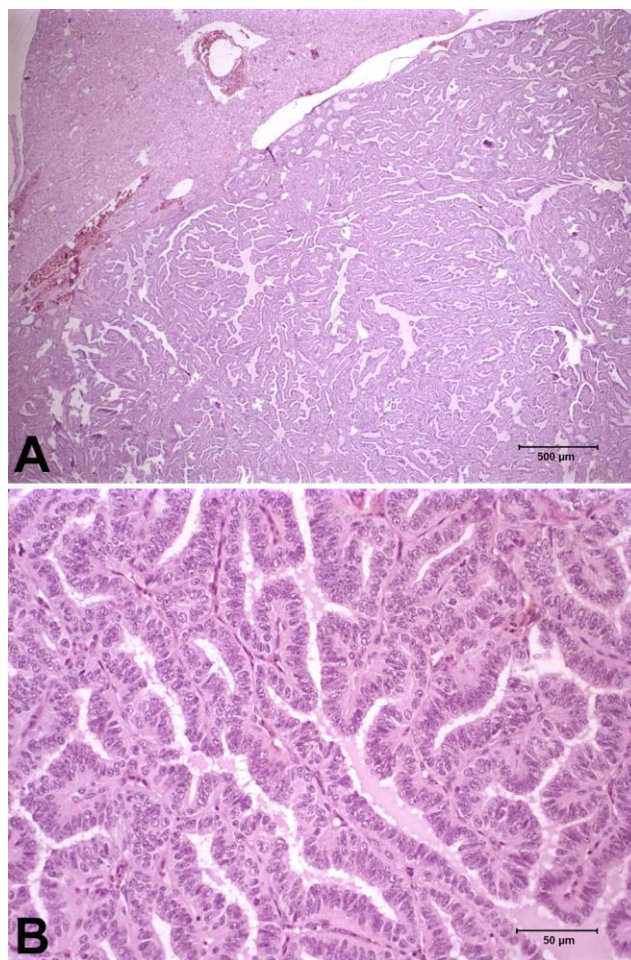


Figure 2. Papillary renal adenoma in a toco toucan (*Ramphastos toco*). **A.** Expansive neoplastic tissue that compress the normal parenchyma, arranged in large and coalescent papillary projections. Hematoxylin and eosin; bar: 500 µm. **B.** Higher magnification demonstrating the single well differentiated epithelial layer lining the papillary projections. Hematoxylin and eosin; bar: 50 µm.

Acknowledgements

Work in RLS lab is supported by CNPq (Conselho Nacional de Desenvolvimento Científico e

Tecnológico, Brazil), FAPEMIG (Fundação de Amparo a Pesquisa do Estado de Minas Gerais, Brazil), and CAPES (Coordenação de Aperfeiçoamento de Pessoal de Nível Superior, Brazil). RLS has a fellowship from CNPq (Brazil).

References

1. BirdLife International. 2017. *Ramphastos toco* (amended version of 2016 assessment). The IUCN Red List of Threatened Species 2017: e.T22682164A113557535. <http://dx.doi.org/10.2305/IUCN.UK.2017-1.RLTS.T22682164A113557535.en>. Downloaded on 22 April 2018.
2. Blackmore DK. The clinical approach to tumours in cage birds - The pathology and incidence of neoplasia in cage birds. *J Small Anim Pract.* 1966;7:217-23.
3. Effron M, Griner L, Benirschke K. Nature and rate of neoplasia found in captive wild mammals, birds, and reptiles at necropsy. *J Natl Cancer Inst.* 1977;59(1):185-98.
4. Garner MM. Overview of tumors. Section II: a retrospective study of case submissions to a specialty diagnostic service. In: Harrison GJ, Light-foot TL, eds. *Clinical Avian Medicine. Vol II.* Palm Beach, FL: Spix Publishing; 2006. p.566-71.
5. Mainez M, Cardona T, Such R, Juan-Sallés C, Garner MM. Bilateral Renal Tubular Neoplasm in a channel-billed Toucan (*Ramphastos vitellinus*). *J Avian Med Surg.* 2015;29(1):46-50.
6. Meuten DJ, Meuten TLK. Tumors of the urinary system. In Meuten DJ, ed. *Tumors of domestic animals.* 5th ed. New Jersey: John Wiley & Sons, Inc; 2017. p.632-88.
7. Neumann U, Kummerfeld N. Neoplasm in budgerigars (*Melopsittacus undulatus*) clinical, pathomorphological and serological findings with special consideration of kidney tumours. *Avian Pathol.* 1983;12:353-62.
8. Pollock C. Diagnosis and treatment of avian renal disease. *Vet Clin Exot Anim.* 2006;9:107-28.
9. Reavill DR. Tumors of pet birds. *Vet Clin Exot Anim.* 2004;7:537-60.
10. VanToor AJ, Zwart P, Kaal GF. Adenocarcinoma of the kidney in two budgerigars. *Avian Pathol.* 1984;13:145-50.