BJVP Brazilian Journal of Veterinary Pathology ISSN 1983-0246

Case Report

Hemorrhagic cystitis caused by extraintestinal pathogenic *Escherichia coli* in a dog (*Canis lupus familiaris*)

Agustina Troncellito[1], Karina C. Fresneda[2], Janet D. Moore[2], Chitrita DebRoy[3], Carolina Escobar[4], Francisco R. Carvallo[2*]

[1]Faculty of Veterinary Sciences, Central Buenos Aires Province National University. General Pinto 399, Tandil, Argentina.
[2]California Animal Health and Food Safety Laboratory. 105 W Central Ave, San Bernardino, CA 92408
[3]*E. coli* reference center, The Pennsylvania State University. 115 Henning Building University Park, PA 16802.
[4]School of Veterinary Medicine, Andres Bello University. Republica 255, Santiago, Chile.
***Corresponding author:** California Animal Health and Food Safety Laboratory – San Bernardino branch. University of California-Davis. 105 W Central Ave, San Bernardino, CA 92408. E-mail: fcarvallo@ucdavis.edu

Submitted August, 20th 2018, Accepted December, 19th 2019

Abstract

Escherichia coli strains that are able to colonize outside of the gastrointestinal tract are classified as extraintestinal pathogenic *E. coli* (ExpEC). A 6.5 female German shepherd dog with history of fever and hematuria was submitted for necropsy. Extensive transmural hemorrhagic cystitis with necrotizing vasculitis was identified in the urinary bladder. Multifocal thrombosis and intralesional bacteria were seen in the kidneys, liver, spleen and brain. *E. coli* O88:H4 was isolated in pure culture from the urinary bladder and other organs. This strain carried the virulence genes *cnf-1*, *sfa*, *fim*, *hlyD* and *PapGIII* which are associated with ExpEC strains.

Key words: urinary infection, ExpEC, septicemia.

Introduction

Escherichia coli is a gram negative, medium size bacterial rod (0.4-0.6 x 2-3 µm) commonly found in the distal small intestine and large intestine of all mammals (4,11). *E. coli* can be a commensal inhabitant and exists in a symbiotic state or it can be a pathogenic bacteria (4). Pathogenic *E. coli* can be further divided into those causing enteric disease and those associated with extraintestinal disease (5, 11). The types of *E. coli* that cause enteric disease include enterotoxigenic and enteropathogenic strains. *E. coli* strains that are able to colonize and cause lesions outside of the gastrointestinal tract are classified as extraintestinal pathogenic *E. coli* (ExpEC) (2, 4, 5, 11).

ExpEC has virulence factors that confer the ability to produce septicemia, pneumonia, meningitis, mastitis and urogenital tract infections in several species (11). *E. coli* is the most commonly isolated infectious agent in cases of human and canine urinary tract infection, and several different sequence types have been isolated (9). This report describes a case of hemorrhagic cystitis associated with ExpEC in a dog (*Canis lupus familiaris*).

Case report

A 6.5 year old, spayed female German shepherd dog was presented with fever (40.3ºC), sialorrhea, emesis, dyspnea, muscle tremors, bilateral mydriasis, ataxia, disorientation and hematuria. Thoracic radiographs were within normal limits. An in house Packed Cell Volume (PCV) and chemistry profile revealed moderate azotemia, increased total protein, albumin and globulins. At that time the PCV was 73%, so the azotemia and hyperproteinemia were attributed to dehydration. A second CBC, chemistry and urinalysis were sent to a reference veterinary laboratory. A high PCV (66%, RI 36-60%) was observed together with a mild mature neutrophilia (13158/µL; RI 2060-10600/µL) and mild monocytosis (1224/µL; RI 0-840/µL), interpreted as inflammation. The chemistry

profile revealed mild azotemia (BUN 50 mg/dL; RI 6-31 mg/dL and creatinine 2.2 mg/dL; RI 0.5-1.6 mg/dL), hyperphosphatemia (10 mg/dL; RI 2.5-6 mg/dL) and hypernatremia (180 mEq/L; RI 139-154 mEq/L) that were attributed to dehydration, even though the acid base status of the patient could cause changes in electrolytes. No significant differences were observed compared with the first chemistry performed the day before. An increased AST (290 IU/L; RI 15-66 IU/L) and CPK (1862 IU/L; RI 58-895 IU/L) was noted, compatible with muscle damage. The urine specific gravity was 1.040, which indicated and adequate renal concentrating ability, which supports the suspected pre-renal azotemia. The urinalysis revealed red urine with large numbers of red blood cells and protein.

The patient failed to respond to supportive treatment including oxygen, intravenous fluids and gastric protectants, and after a few hours, the dog was prostrate with labored breathing, body temperature of 41.7ºC, and heart rate of 150 beats/minute. Due to increased progression of signs and failure to respond to all treatments, the owner requested the euthanasia.

At gross examination, the urinary bladder contained approximately 30 mL of opaque, dark red urine, the bladder apex was transmurally dark red/black, slightly thickened and firm, with an irregular, slightly nodular mucosal surface, which was also disrupted by several slender, sagittally oriented, dark red/black, slightly raised linear tracts that extended from apex to base (Fig. 1). No significant gross findings were detected in other organs. Histologically, acute, severe cystitis was characterized by multifocal to coalescing, transmural hemorrhages, superficial mucosal necrosis, multifocal necrotizing vasculitis, thrombosis and fibrinocellular exudation with moderate numbers of neutrophils and occasional macrophages within the lamina propria-submucosa (Fig. 2). Small numbers of Gram-negative bacilli were identified along the mucosal surface and within blood vessels (Fig. 2, inset). Lesions in other organs included thrombosis in liver, kidney, spleen and brain, and acute renal tubular necrosis.

Aseptically collected swabs of urine, urinary bladder wall, liver, spleen and brain were streaked onto blood agar plates, which were incubated at 37ºC under aerobic and microaerophilic conditions. After 24h, a pure culture of a gram negative, β-hemolytic rod was detected on all plates. The biochemical profile included gas production on triple sugar iron agar (A/Ag), urease (-), sulfur (-), indole (+) and motility (+) on SIM agar, and citrate (-) on Simmons citrate agar. The API 20E® (Lyon, France) profile identified this isolate as *E. coli* (99.5%). This isolate was submitted to the *E. coli* reference center at The Pennsylvania State University. Typing of the isolate revealed that it belonged to serogroup O88 and H4. Additionally, the bacteria were tested for genes encoding numerous virulence factors (Table 1) as previously described (3), identifying a profile characteristic for ExpEC. Other Ancillary tests were performed, including *Rickettsia ricketsii* PCR and fluorescence antibody test for *Leptospira* spp., both with negative results.



Figure 1. Urinary bladder. Hemorrhagic mucosa with numerous linear dark red/black tracts that extended from apex to base.

Discussion

Hemorrhagic cystitis and septicemia caused by ExpEC in a female dog is reported in this case. Different strains of *E. coli* have been described and these can be commensal organisms, intestinal pathogens or extraintestinal pathogenic strains (11, 16). *E. coli* colonizes the intestinal tract of all mammals a few hours after birth and persists throughout life, becoming the most important commensal organism of the small intestine (14). ExpEC can produce opportunistic extraintestinal infections, ranging from urinary tract infection to meningitis in humans and animals (11, 14). ExpEC is reported to cause lesions due to the presence of virulence factors such as α-hemolysin (hlyD), cytotoxic necrotizing factor toxin (cnf1), papG alleles and different adhesins (14). In particular, the *papGIII* allele is the predominant *papG* variant of *E. coli* isolates from dogs and humans with urinary tract infection (3). *E. coli* producing cnf-1 is referred to as necrotoxic *E. coli*, which has been isolated from humans with urinary infection and sporadically, in cases of child diarrhea (6, 13).

 All rights reserved 2007.

Table 1. Serotype and virulence factors of extraintestinal pathogenic *Escherichia coli* isolated from a female German shepherd dog with hemorrhagic cystitis.*

O type	H type	*cnf*1	*cnf*2	*PAI*	*papA*	*ompT*	*fimH*	*papEF*	*traT*	*ireA*	*ibeA*	*hlyD*	*fyuA*	*iroN*	*sfa*	*iss*
88	4	+	-	+	-	+	+	+	+	-	+	+	+	+	+	-

kii	*papGII*	*Iha*	*cvaC*	*papGI*	*sfaS*	*K1*	*rfc*	*cdt*	*focG*	*papGIII*	*papC*	*kpsII*	*uidA*	*Usp*
+	-	-	-	-	+	+	-	-	-	+	+	-	+	+

* + = positive; - = negative; *cnf*1 and 2: Cytotoxic necrotizing factor toxin; *PAI*: Pathogenicity island; *pap*: Pilus associated with pyelonephritis fimbriae; *ompT*: outer membrane protease T; *fimH*: D-mannose specific adhesion fimbriae; *traT*: serum resistance associated protectin; *ireA*: iron regulated element siderophore; *ibeA*: invasion of brain endothelium A; *hlyD*: alpha hemolysin toxin; *fyuA*: *Yersinia* siderophore receptor; *iroN*: novel catecholate siderophore receptor; *sfa*: S fimbriae; *iss*: increased serum survival protectin; *kps* and *kii*: group II capsular polysaccharide synthesis protectin; *Iha*: novel non-hemagglutinin adhesion; *cvaC*: colicin V synthesis protein protectin; *sfaS*: pilus tip adhesion, S fimbriae (sialic acid specific); *K1*: capsular polysaccharide antigen protectin; *rfc*: O-antigen polymerase; *cdt*: cytolethal distending toxin; *focG*: pilus tip molecule, F1C (sialic acid specific); *uidA*: Beta-D-glucoronidase; *Usp*: uropathogenic specific protein.

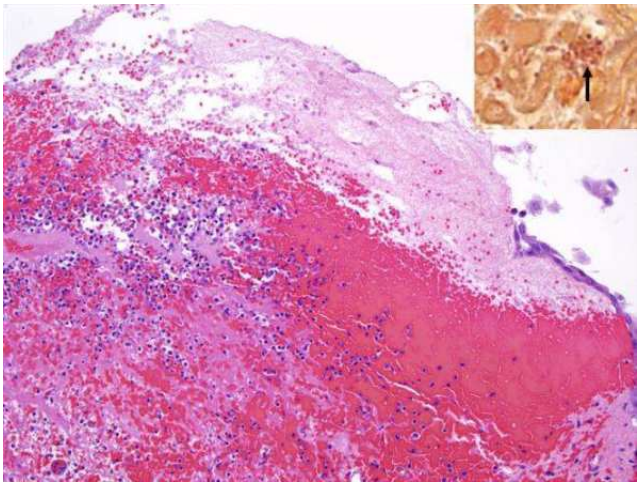

Figure 2. Urinary bladder. Extensive hemorrhages in the submucosa, with fibrin, neutrophilic infiltrates and desquamation of adjacent epithelium. Hematoxylin and eosin, 100X. Inset: Few Gram-negative rods (arrow) present within the inflammatory foci. Brown and Brenn stain, 600X.

Infections with ExpEC have a relevant role in human health as this group of bacteria has a significant zoonotic potential. Exposure to dog and dog feces is recognized as an important risk factor for the development of urinary tract infections in women (18). In addition, transmission of the bacterium from humans to dogs has also been proposed (15). Regarding *E. coli* sequence types associated with canine and human urinary tract infections, there are some similarities, but mostly marked differences between *E. coli* isolates, which provides some support of cross host species sharing of strains (9). Two theories have been postulated regarding the presence of ExpEC in the urinary tract. The so-called "prevalence theory" states that because there is a high number of *E. coli* in feces, it is easy for these microorganisms to reach the urinary tract. The so-called "special pathogenicity theory" states that ExpEC has a selective advantage because of virulence genes which specifically favor the infection of extraintestinal sites (4). In dogs and cats, studies with large populations of animals have identified a wide variety of strains that are capable of inducing urinary infections, some of them with classic genetic profiles of ExpEC and others that do not carry the characteristic genes, which does support the "special pathogenicity" hypothesis (2, 9). Some researchers consider that ExpEC virulence factors evolved with the commensal lifestyle, which promotes colonization and survival of the normal gut environment (5, 17). In other words, extraintestinal infections have been interpreted as a coincidental by-product of commensalism. Interestingly, male dogs are more likely to ExpEC isolates than non-ExpEC isolates, indicating that virulence-associated genes may be necessary to overcome the anatomical barrier to UTIs in males (9). In addition, virulence genes in humans and animals are different, which suggest a difference in virulence requirement for *E. coli* binding urothelium in different species (2, 9).

Other causes of hemorrhagic cystitis in dogs include *Nocardia asteroides* (1), and treatment with carboplatin (10) or cyclophosphamide (8). Another cause of extensive urinary bladder hemorrhages in dogs include tumors, such as transitional cell carcinoma (12). All these causes were ruled out in this case.

In conclusion, we report a bacterial infection causing hemorrhagic cystitis and septicemia in a female dog, which likely originated after an ascending bacterial infection. Virulence factors detected in the strain of *E. coli* isolated are characteristic for ExpEC. We highlight the importance of genetic characterization of *E. coli* isolated from the urinary tract in dogs, which sometimes is overlooked as a contaminant.

Acknowledgements

The authors acknowledge Dr. Francisco Uzal for the English review of this manuscript, and Mrs. Juliann Beingesser, Mrs. Paula M. Yant and Mr. Ray A. Cazarez for their technical support.

References

1. Buoro IBJ, Mande JD, Nyamwange SB. Isolation of *Nocardia asteroides* from a dog with haemorrhagic cystitis. J Small Anim Pract. 1993;34:99-102.
2. Hutton TA, Innes GK, Harel J, Garneau P, Cucchiara A, Schifferli DM, Rankin SC. Phylogroup and virulence gene association with clinical characteristics of *Escherichia coli* urinary tract infections form dogs and cats. J Vet Diagnost Invest. 2018;30:64-70.
3. Johnson JR, O'Bryan TT, Low DA, Ling G, Delavari P, Fasching C, Russo TA, Carlino U, Stell AL. Evidence of commonality between canine and human extraintestinal pathogenic *Escherichia coli* that express papG allele III. Infect Immun. 2000;68: 3327-36.
4. Katouli M. Population structure of gut *Escherichia coli* and its role in development of extra-intestinal infections. Iran J Microbiol. 2010;2:59-72.
5. Köhler CD, Dobrindt U. What defines extraintestinal pathogenic *Escherichia coli*? Int J Med Microbiol. 2011;301:642-47.
6. Johnson JR, Stell AL. Extended virulence genotypes of *Escherichia coli* strains from patients with urosepsis in relation to phylogeny and host compromise. J Infect Dis. 2000;181:261-72.
7. Johnson JR, Stell AL, Delavari P, Murray AC, Kuskowski M, Gaastra W. Phylogenetic and pathotypic similarities between *Escherichia coli* isolates from urinary tract infection in dog and intraintestinal infection in humans. J Infect Dis. 2001;183:897-906.
8. Laing EJ, Miller CW, Cochrane SM. Treatment of cyclophosphamide-induced hemorrhagic cystitis in five dogs. J Am Vet Med Assoc. 1988;193:233-6.
9. Lecuyer TE, Byrne BA, Daniels JB, Diaz-Campos DV, Kennitra Hammac G, Miller CB, Besser TE, Davis MA. Population structure and antimicrobial resistance if canine uropathogenic *Escherichia coli*. J Clin Microbiol. 2018; 56:e00788-18. https://doi.org/10.1128/JCM.00788-18.
10. MacDonald V, Dickinson R. Hemorrhagic cystitis in a dog receiving carboplatin. J Am Anim Hosp Assoc. 2014;50:67-70.
11. Markey B, Leonard F, Archambault M, Cullinane A, Maguire D. Enterobacteriaceae. In: Markey B, Leonard F, Archambault M, Cullinane A, Maguire D (editors). Clinical veterinary microbiology. 2nd ed. Philadelphia: Elsevier; 2013. p. 239-274.
12. Meuten DJ, Meuten TLK. Tumors of the urinary system. In: DJ Meuten, editor. Tumors in domestic animals, 5h ed. Ames: Wiley Blackwell publishing; 2017. p. 632-688.
13. Paciorek J. Virulence properties of *Escherichia coli* fecal strains isolated in Poland from healthy children and strains belonging to serogroups O18, O26, O44, O86, O126 and O127 isolated from children with diarrhoea. J Med Microbiol. 2002;51:548-56.
14. Quinn PJ, Markey BK, Leonard FC, Fitzpatrick ES, Fanning S, Hartigan PJ. Enterobacteriaceae. In: Quinn M, Leonard F, Fanning S and Hartigan PJ (editors.) Veterinary microbiology and microbial disease. 2nd ed. Ames:Wiley-Blackwell; 2011. p. 263-86.
15. Reeves PR, Liu B, Zhou Z, Li D, Guo D, Ren Y, Clabots C, Lan R, Johnson JR, Wang L. Rates of mutation and host transmission for an *Escherichia coli* clone over three years. PLoS One. 2011:6:e26907. https://doi.org/10.1371/journal.pone.0026907.
16. Sura R, HJ Van Kruiningen, C DebRoy, LS Hinckley, KJ Greenberg, Z Gordon, RA French. Extraintestinal pathogenic *Escherichia coli*-induced acute necrotizing pneumonia in cats. Zoonoses Public Health. 2007;54:307-13.
17. Tourret J, Denamur E. Populations phylogenomics of Extraintestinal pathogenic *Escherichia coli*. Microbiol Spectrum. 2016;4(1):UTI-0010-2012. doi:10.1128/microbiolspec.UTI-0010-2012.
18. Ukah UV, Glass M, Avery B, Daignault D, Mulvey MR, Reid-Smith RJ, Parmley EJ, Portt A, Boerlin P, Manges AR. Risk factors for acquisition of multidrug-resistant *Escherichia coli* and development of community-acquired urinary tract infections. Epidemiol Infect. 2018;146:46-7.

 All rights reserved 2007.