Braz J Vet Pathol, 2019, 12(1), 19 – 23
DOI: 10.24070/bjvp.1983-0246.v12i1p19-23

BJVP
Brazilian Journal of Veterinary Pathology
ISSN 1983-0246

Case Report

Systemic granulomatous disease in dairy cattle from Argentina

Ernesto R. Odriozola[1*], Matias A. Dorsch[2*], Rubén D. Caffarena[3], Ana Rita Moreira[1], Eduardo L. Fernández[1], Eleonora L. Morrell[1], Germán J. Cantón[1*]

[1]Instituto Nacional de Tecnología Agropecuaria, EEA Balcarce, Ruta 226 km 73,5, (7620) Balcarce, Argentina.
[2]Facultad de Ciencias Agrarias, Universidad Nacional de Mar del Plata, Ruta 226 km 73,5, (7620) Balcarce, Argentina.
[3]Plataforma de Investigación en Salud Animal, Instituto Nacional de Investigación Agropecuaria (INIA), Ruta 50 km 11, La Estanzuela, (70000) Colonia, Uruguay.
*These authors contributed equally to this work.
***Corresponding author:** Germán J. Cantón; E-mail: canton.german@inta.gob.ar

Submitted August, 28th 2018, Accepted December, 3rd 2018

Abstract

An outbreak of systemic granulomatous disease of unknown etiology was diagnosed in a dairy herd from Argentina. Eleven out of 211 cows manifested hyperthermia, depression, alopecia, pruritus, decreased milk production and death in most cases. During necropsy, multifocal petechial hemorrhages in glottis and vulva, white multifocal nodules in the liver and splenomegaly with subcapsular petechial hemorrhages were observed. Both kidneys were diffuse pale and enlarged. Systemic granulomatous hepatitis, myocarditis, pancreatitis and nephritis were observed. Water and food samples tested negative for Arsenic and T2 toxin, respectively. *Fusarium equiseti* was isolated from alfalfa hay samples. *Vicia* spp. was not consumed by the affected herd and no other cause of vetch-like disease was registered. Other causes of granulomatous lesions (*Mycobacterium* spp. and fungal infections) were discarded. The systemic granulomatous disease was suggestive of a type IV hypersensitivity reaction. Although the sensitizing agent was not determined, two components of the ration were suspected: cotton seed and bone ash. Both of them were introduced one month prior to the detection of the first affected cow and the disease resolved since they were removed from the diet.

Key words: systemic granulomatous disease, vetch-like, dairy cattle.

Introduction

Systemic granulomatous disease, also known as vetch-like disease, has been sporadically reported worldwide. Vetch-like disease shares similar clinical and pathological characteristics with hairy vetch (*Vicia villosa*) poisoning, although the etiology is unknown (11). In the former, citrus pulp poisoning (9, 15), diureido-isobutane (DUIB) (3), dicyandiamide (DCD) (5) and silages treated with commercial additives have been identified as the main causes (8, 10, 17). All these presentations are characterized by systemic granulomatous lesions in several tissues, strongly suggesting a type IV hypersensitivity reaction in the development of the lesions (11). This hypersensitivity reaction occurs due to the interaction of T lymphocytes with the specific antigen to which they have been previously sensitized, resulting in a chronic cell mediated response (7, 16).

This report describes the clinical-pathological findings of an outbreak of systemic granulomatous disease of unknown etiology in dairy cattle from Argentina, diagnosed by the Specialized Veterinary Diagnostic Service (SDVE) of the National Institute of Agricultural Technology (INTA) EEA Balcarce.

Case report

An outbreak of systemic granulomatous disease occurred since December 2008 until July 2009 in a dairy farm located in General San Martín Department, Córdoba province, Argentina (32°24′37″S 63°13′53″W).

One hundred and fifty-seven cows and 54 heifers were fed with maize silage, alfalfa silage, maize flour,

 All rights reserved 2007.

alfalfa hay, sorghum silage, cotton seed, soybean expeller, mineral mixture and bone ash (treated at 600°C). Cotton seed and bone ash had been added to the ration one month before the first case was detected. Animals were vaccinated to prevent anthrax and clostridial diseases twice a year. In addition, they were vaccinated to prevent reproductive diseases, neonatal diarrhea and bovine respiratory disease. Copper was administered twice a year and anthelminthic before calving.

The first affected cow was detected on December of 2008. Between January and July of 2009, other 7 cows were affected. Four of them were unsuccessfully treated with Penicillin, antihistamines and Dexamethasone before death. On July 2009, veterinary pathologists visited the farm. Clinical examination was performed on 3 symptomatic lactating cows. Blood samples were obtained for serum biochemistry and complete blood count. The biochemical tests were performed using commercially available kits for aspartate aminotransferase (AST), alanine aminotransferase (ALT), gamma glutamyl transferase (GGT), creatinine and urea (Wiener Laboratorios SAIC, Rosario, Argentina). Total plasma protein and albumin were determined using spectrophotometry. Thin Layer Chromatography (TLC) to detect T2 toxin was performed on ration components (12). Water samples and cotton seed samples were tested for Arsenic using hydride generation method (4). Isolation and typification of fungi were performed in the alfalfa hay samples. One affected cow was euthanized according to the regulations of Animal Ethics Committee of INTA and autopsied. Heart, liver, spleen, kidney, muscle, lung, pancreas, skin, adrenal gland, lymph node and salivary gland samples were taken and fixed in 10% neutral buffered formalin, embedded in paraffin wax, sectioned at 4-5 µm and stained with Hematoxylin and Eosin (HE) for histologic examination. Sections of kidney and liver were also stained with Ziehl – Neelsen (ZN) and Periodic acid–Schiff (PAS) staining methods to detect *Mycobacterium* spp. and fungi, respectively.

Liver and kidney samples were aseptically collected and inoculated simultaneously onto 7% bovine blood Columbia agar plates and MacConkey agar plates. The former were incubated in 5% CO_2 at 37°C for 48 h, while the latter were incubated under aerobic conditions at 37°C for 24 h.

Morbidity rate was 5.2% (11/211) and lethality rate was 72.7% (8/11). Three out of the 11 cows recovered, and subsequently one of them – that had manifested depression and facial alopecia - aborted a 6-month-old fetus. Among those affected, 9 were high-producing dairy adult cows and only 2 were heifers. No more affected animals were detected once the cotton seed and bone ash were removed from the ration.

Table 1 summarizes the clinical signs, the outcome and gross lesions found in seven affected animals. Briefly, scattered areas of alopecic skin, mostly affecting head, neck, mammary glands and inner thigh regions were detected (Fig. 1). Vulva and nostrils had mucous-hemorrhagic exudate. One cow manifested hyperthermia and marked loss of body condition. Milk production decreased and it was almost nil in some cases. During necropsy, petechial hemorrhages in glottis and vaginal mucosa, and fibrin clots around the bladder were observed. Multiple ~1-cm-diameter, whitish, rounded nodules on the surface and internally in hepatic parenchyma were evident grossly. Splenomegaly and multifocal subcapsular petechiae were seen in the spleen. Kidneys were enlarged and they both had a marked pale diffuse color and multiple whitish foci of 5-10 mm diameter on the external surface (Fig. 2). Numerous whitish striations radially oriented from the renal cortex to the corticomedular region were observed. Serohemorrhagic edema was found around the capsule of the left kidney. Pancreas had an edematous appearance.



Figure 1. Multifocal to coalescence areas of alopecic skin in muzzle, head and neck of an affected cow.



Figure 2. Marked pallor and multiple whitish spotlights on the external surface of the kidney.

Histologic examination revealed a multifocal, severe, non-encapsulated granulomatous infiltrate in kidneys, prescapular lymph nodes and pancreas (Fig. 3). Inflammatory cells consisted of lymphocytes and

macrophages, admixed with a moderate number of epithelioid macrophages and few plasmatic cells. Occasionally, multinucleated giant cells both foreign-body

Table 1. Information about age, treatment, clinical signs, outcome and gross lesions observed in seven affected cows.

Animal ID	Age (years)	Treatment	Clinical findings and outcome	Gross lesions
1785	6	Penicillin, antihistamine	Bloody mucous discharge from nostrils and vulva. Nasal petechiae, alopecia of head, neck, udder and perineum, pruritus, drop in milk production, death	Not registered
1921	2.5	Penicillin, antihistamine	Alopecia of head and neck, pruritus, vulval and nasal petechiae, death	Subcapsular petechiae in spleen, petechiae on mucosal surfaces
1699	5.5	Penicillin, antihistamine	Poor body condition, drop in milk production, patchy alopecic areas, death	Petechiae and ecchymosis on serosal and mucosal surfaces
1599	7.5	Penicillin, antihistamine, Dexamethasone	Mild facial alopecia, pyrexia, drop in milk production, death	Petechiae and ecchymosis on serosal surfaces, diffuse suffusive hemorrhage in epicardium
1638	6	-	Depression, pruritus, facial alopecia, serous discharge from nose	-
1914	2.5	Dexamethasone	Depression, alopecia of the head, abortion	-
1565	6	-	Depression, pruritus, alopecia of the head, udder and thigh, serous discharge from nose, submandibular edema, pyrexia. Euthanasia	Petechiae in glottis and vulva, white nodules in kidneys and hepatic surface, perirenal edema, splenomegaly

and Langhans type were seen (Fig. 4). Adrenal cortex, myocardium, salivary glands and skin were also affected. In these tissues, the inflammatory reaction varied from moderate and multifocal to severe and diffuse, and it consisted mainly of lymphocytes and macrophages (Fig. 5). The liver had similar infiltrates with moderate amount of eosinophils and neutrophils in the periportal spaces (Fig. 6). Furthermore, the hepatic parenchyma showed multiple random foci of coagulative necrosis, composed of central necrotic debris and surrounded by large numbers of reactive macrophages.

Vicia spp. was not present in any of the feedstuff included in the diet. Ziehl-Neelsen and PAS stains were negative for *Mycobacterium* spp. and fungi, respectively.

Serum biochemical and hematological test of the three cows analyzed were unremarkable. Isolation of kidney and liver samples resulted negative for clinically and pathologically relevant aerobic and microaerobic bacteria. Arsenic and T2 toxin were not detected on water and feed samples, respectively. Alfalfa hay had 18000 CFU/g of *Fusarium equiseti.*

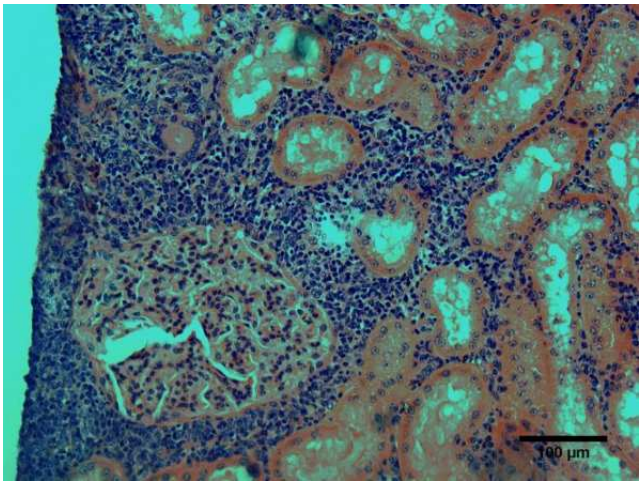

Figure 3. Granulomatous inflammatory reaction characterized by lymphoplasmacytic infiltrates with few eosinophils in the interstitium of the renal cortex (HE 200x).

DOI: 10.24070/bjvp.1983-0246.v12i1p19-23

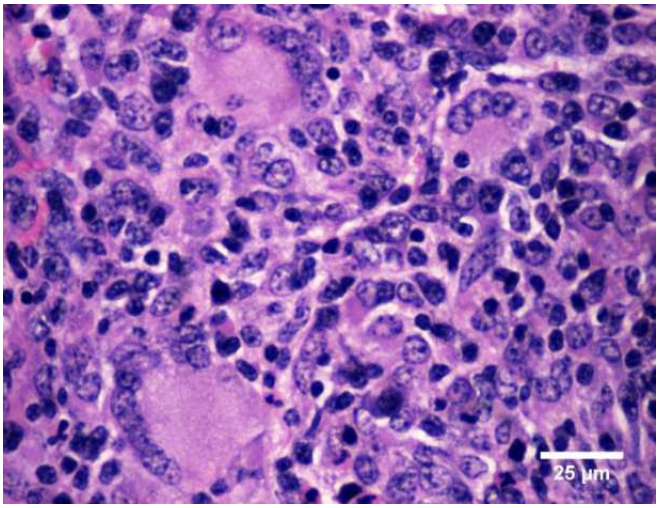

Figure 4. Multiple multinucleated giant cells in the interstitium of the renal cortex (HE 400x).

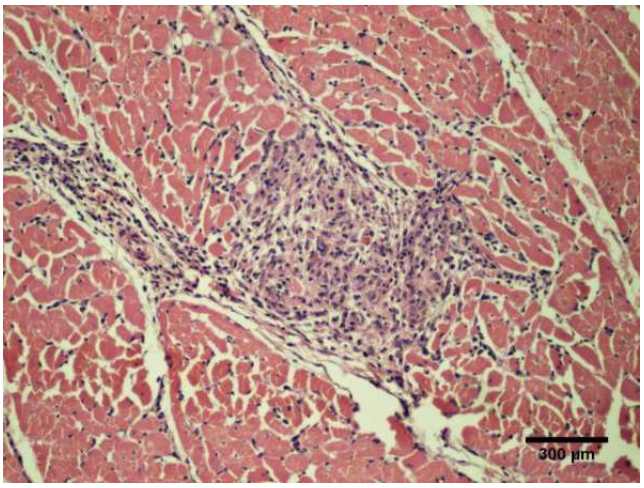

Figure 5. Focal lymphohistiocytic inflammatory myocarditis (HE 100x).

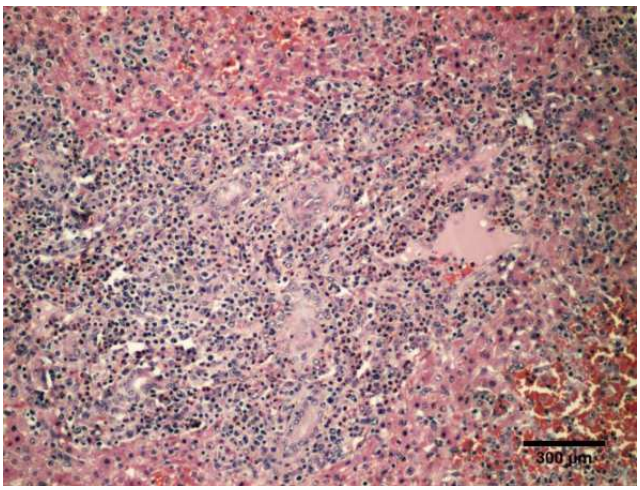

Figure 6. Severe, periportal infiltration of lymphocytes and macrophages with moderate amounts of eosinophils and neutrophils and biliary duct hyperplasia (HE 100x).

Discussion

This work describes a systemic granulomatous disease in livestock from Argentina for the first time. The clinical-pathological and epidemiological findings similar to previous reports (5, 10, 11, 16) and the lack of response to the treatment (2, 10, 14), support this diagnosis.

Unfortunately, the etiology could not be determined. Nevertheless, several observations provide strong evidence that two components of the ration (cotton seed and bone ash) could be involved in the presentation of this disease. This theory was based on 1) both components of the ration had been introduced one month prior to the detection of the first affected cow, and 2) no more cases were registered after these elements were removed from the ration.

The period of exposition to the suspected sensitizing agent would be long enough to trigger a type IV hypersensitivity reaction. Although in other reports this period was 6 to 14 weeks (9, 15), delayed-type hypersensitivity usually requires 24 - 48 h to develop (16).

Epidemiological rates and the most frequently affected categories were coincident with previous reports (2, 9, 14, 17, 18).

Clinical course and some clinical signs described herein were consistent with previous reports (1, 3, 14). However, jaundice, melena, hematuria and pale mucous membranes were not observed in this case, unlike other reports (9, 14). One of the surviving cows aborted a 6-month-old fetus as it has been previously reported (5, 14, 17). It has been speculated that abortion might be due to the systemic inflammatory reaction (5).

Most of the pathological findings were consistent with previous reports (1, 2, 5, 9, 11, 14, 15). However, no hemorrhagic syndrome was evident in the euthanised cow, as it was previously described by other authors (8, 14, 15). Nevertheless, according to the practitioners attending this farm, severe and hemorrhagic lesions were observed in necropsies previously performed on affected animals that died spontaneously (Fig. 7). The hemorrhagic crisis is probably a terminal event of this pathological syndrome (2, 9, 15). For this reason, it was not observed in the euthanised cow.

Histopathological findings also agreed with previous reports (3, 5, 8, 9, 14, 15). These granulomatous cellular infiltrates are characteristic of systemic granulomatous disease and allow it to be differentiated from other causes of systemic bleeding disorders, such as infection with *Bacillus anthracis*, intoxication from *Pteridium aquilinum* ingestion or bovine viral diarrhea type 2 infection (14).

Other causes of granulomatous inflammatory reactions – *Vicia* spp. poisoning, mycobacterial and fungal infections - were also excluded. *Fusarium equiseti* is a normal inhabitant of the soil and to the best of our knowledge; it is not pathogenic for cattle (6).

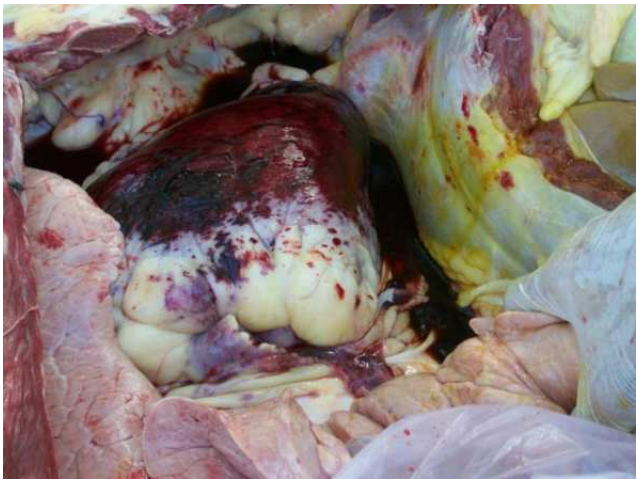

Figure 7. Severe and diffuse suffusive hemorrhage in epicardium.

Even though biochemical and hematological alterations have been reported, these parameters were normal in the three examined cows (5, 8, 14, 15, 17, 18). This is probably associated with the course and progression of the disease, as two of the three animals that were tested recovered and the remaining one was euthanized.

Although it was not possible to identify the sensitizing agent, our findings suggest that this case could be described as a systemic granulomatous disease or vetch-like disease. Many animals were exposed to the suspected sensitizing agents, but only a few developed the disease. This result was probably influenced by individual susceptibility (5, 9).

Regardless of the etiology, systemic granulomatous disease lesions are usually characteristic and very similar, according to previous reports (3, 5, 8, 9, 14, 15). Therefore, they are likely to be produced by the same chemical compound. Further studies are necessary in order to elucidate the pathogenesis of the disease.

References

1. Andrews AH, Longstaffe JA, Newton AC, Musa I. Acute Fatal Haemorrhagic Syndrome in Dairy Cows. Vet Rec. 1983;112(26):614.
2. Bellino C, Iussich S, Biasato I, Peletto S, Caruso C, Gianella P, Cagnasso A, D'Angelo A. Potential Pathogenetic Role of Bovine Herpesvirus 4 in Two Dairy Cows with Dermatitis-Pyrexia-Hemorrhagic Syndrome. J Clin Microbiol. 2015;53(8):2763-7.
3. Breukink HJ, Gruys E, Holzhauer C, Westenbroek AC. Pyrexia with dermatitis in dairy cows. Vet Rec. 1978;103:221-2.
4. Bundaleska JM, Stafilov T, Arpadjan S. Direct analysis of natural waters for arsenic species by hydride generation atomic absorption spectrometry. Int J Environ Anal Chem. 2005;85(3):199-207.
5. Cayzer J, Buckle KN, Munday JS, Ledgard SF, Heiser A, Thatcher A. Systemic granulomatous disease in dairy cattle during a dicyandiamide feeding trial. N Z Vet J. 2018;66(2):108-13.
6. Goswami RS, Dong Y, Punja ZK. Host range and mycotoxin production by *Fusarium equiseti* isolates originating from ginseng fields. Can J Plant Pathol. 2008;30:155-60.
7. Hargis AM, Ginn PE. The integument. In: McGavin MD, Zachary JF, editors. Pathologic Basis of Veterinary Disease. 5th ed. St. Louis: Mosby; 2012. p. 972-1084.
8. Holden AR. Two outbreaks of pyrexia with dermatitis in dairy cows. Vet Rec. 1980;106:413-4.
9. Iizuka A, Haritani M, Shiono M, Sato M, Fukuda O, Hagiwara A, Miyazaki S, Tanimura N, Kimura K, Nakazawa K, Kobayashi M, Takahashi T, Saito T, Fukai K. An outbreak of systemic granulomatous disease in cows with high milk yields. J Vet Med Sci. 2005;67:693-9.
10. Matthews JG, Shreeve BJ. Pyrexia/pruritis/haemorrhagic syndrome in dairy cows. Vet Rec. 1978;103:408-9.
11. Mauldin EA, Peters J. Integumentary system. In: Maxie MG, editor. Jubb, Kennedy and Palmer's Pathology of Domestic Animals. 6th ed. v.1. Philadelphia: Saunders Elsevier; 2016. p. 509-736.
12. Omurtag GZ, Yazicioğlu D. Determination of T-2toxin in grain and grain products by HPLC and TLC. J. Environ. Sci. Health B. 2000,35(6):797-807.
13. Panciera RJ, Mosier DA, Ritchey JW. Hairy vetch (*Vicia villosa* Roth) poisoning in cattle: update and experimental induction of disease. J Vet Diagn Invest. 1992;4:318-25.
14. Rawdon TG, Buckle KN, Lawrence KE, Thompson KG, Julian AF, Vaatstra BL, Johnstone AC, Weston JF, Fairley RA. Systemic Granulomatous and Haemorrhagic Syndrome in New Zealand Dairy Cattle. N Z Vet J. 2017;65(3):156-62.
15. Saunders GK, Blodgett DJ, Hutchins TA, Prater RM, Robertson JL, Friday PA, Scarratt WK. Suspected citrus pulp toxicosis in dairy cattle. J Vet Diagn Invest. 2000;12:269-71.
16. Snyder, PW. Diseases of Immunity. In: McGavin MD, Zachary JF, editors. Pathologic Basis of Veterinary Disease. 5th ed. St. Louis: Mosby; 2012. p. 242-88.
17. Thomas GW. Pyrexia with dermatitis in dairy cows. Vet Rec. 1978;102:368.
18. Turner SJ, Kelly DF, Spackman D. Pyrexia with dermatitis in dairy cows. Vet Rec. 1978;102:488-9.

 All rights reserved 2007.