

**Original Full Paper****Anatomopathological and molecular studies of Marek's disease virus in India**Sivam Visnuvinayagam^{1*}, Bana B. Dash², Rajamani Barathidasan³, Kuppusamy Mayilkumar⁴, Ganapathy Selvaraju⁵¹ICAR-Central Institute of Fisheries Technology.²Project Directorate on FMD, Mukteswar, Uttarakhand, India.³Division of pathology, Indian Veterinary Research Institute, Izatnagar, Bareilly, Uttar Pradesh, India.⁴Research Scholar, Division of pathology, Indian Veterinary Research Institute, Izatnagar, Bareilly, Uttar Pradesh, India.⁵Professor, Veterinary college and Research Institute, Namakkal, Tamil Nadu, India.

*Corresponding Author: ICAR-Central Institute of Fisheries Technology

E-mail: visnuvinayagam@yahoo.co.in, Phone: +91-9920634127 (M); +91-484-2412300. Fax: +91 484 2668212

Submitted January, 26th 2019, Accepted May, 26th 2019**Abstract**

In India, increasing incidence of Marek's Disease Virus (MDV) outbreaks are being reported even in vaccinated poultry farms. Hence identifying the new emerging pathotype of MDV is necessary for successful control through vaccination. Birds received in the *post mortem* section of The Avian Disease Laboratory, Indian Veterinary Research Institute, were screened for the presence of MDV by collecting neoplastic tissues, spleen and feather follicles. Screening was carried out by polymerase chain reaction (PCR) and histopathological examination. Among the tested 150 birds' tissue samples, 35 bird tissue samples were found positive for MDV. Based on pathotyping specific PCR, it was found that 34 birds tissues were affected virulent MDV and one birds tissue was affected with very virulent MDV. Since, HVT vaccine will not protect the very virulent pathotype, combined vaccine of SB-1 and HVT can be administered to control the very virulent MDV. Among the MD infected birds, neoplastic liver is most commonly encountered. Spleen tissue samples was found to be more suitable for the DNA isolation for PCR.

Key words: Marek's Disease, Marek's Disease Virus, Virulent MDV, Very virulent MDV, *Gallid alpha herpesvirus 2*.**Introduction**

Intensive rearing system is a key factor for the fastest growth of poultry sector in India and also a crucial factor for disease outbreaks (3). Marek's disease (MD) is one of the important emerging diseases that break vaccine immunity and cause new outbreaks in vaccinated flocks (22). It causes severe immunosuppression in early chick hood, leading to increased incidences of other viral, bacterial, fungal or parasitic infections, resulting into increased mortality and productivity and economic losses (3). MDV affects the all chicken of all age groups birds, a genetic makeup of the chicken playing major role for the resistance or susceptibility (10).

In field conditions, after introduction of new type of MD vaccines, a decade later, a new pathotype of MD is being evolved with higher virulence, which can overcome the vaccine immunity (5). Before 1970s, pathotype of the MD was classified as classical and acute forms. In the classical form, mostly paralysis was observed with less neoplasia formation in affected birds and the mortality also showed fewer percentages than the acute form. In the acute form, the affected birds may not show the paralytic symptom, instead of high level of lymphoid cell infiltration in liver, spleen ovary, kidneys, lungs, heart and proventriculus was observed (5). After introduction of serotype 3 vaccine i.e., HVT (FC126), the acute form of MD was controlled. Globally, HVT vaccine is being used

to control the MDV infection. The term acute was coined during 1970s; but, now-a-days it is considered as a moderate/mild pathotype type (M). During 1980s virulent (V) pathotype also appeared in farms, which were also effectively controlled by the HVT vaccines (22). After a short pause, in 1980s, MD outbreaks was reported in HVT vaccinated poultry farms (20); which was identified as very virulent (VV) pathotype. Since HVT vaccine was not able to protect VV MDV pathotype, bivalent (combo) vaccine was practiced i.e., combination of Serotype 1 and 2 (HVT+ SB1) to control the MDV. The bivalent vaccine was very effective during the 1980s to control the VV pathotype (5). Later, in 1990, a very virulent plus (VV+) strain of Marek's disease virus (MDV) appeared in the US. It can able to cause disease even in bivalent vaccinated farms (21). The devastating VV+ MDV was successfully controlled by the introduction of the new serotype 1 vaccine viz. CVI988. The strain CVI988 was selected owing to its low oncogenic potential again it was 26 -35 times passaged in duck embryo fibroblasts (5). In 1992, the appearance of hyper virulent pathotype was noticed in Italy; which can able to overcome the immunity of the Serotype 1 vaccine i.e., CVI-988 (3, 17). Generally, most of the vaccines are prepared by attenuate the virulent virus in cell culture or Embryonated Chicken Egg (18), ironically in the Marek's Disease substantial amount researches have been carried out to increase the potency of the vaccine virus for effective control of MD.

In India increasing incidence of MD outbreaks are being reported even in vaccinated poultry farms (9, 16). Hence identifying the new emerging pathotype of MDV that is escaping the vaccinal immunity with the use of vaccine strain (HVT strain) is necessary for successful vaccination programmes. Agar Gel Precipitation Test (AGPT) is the commonly used for the confirmation of MDV in the field from the feathers follicles of affected birds. But, it cannot differentiate the pathotype; moreover HVT vaccinated birds also gives the positive result in AGPT. Hence, the application of improved molecular diagnostic techniques, such as polymerase chain reaction (PCR) is necessary to differentiate the pathotypes. If MD outbreak occurs in the poultry farm, the identification of virulent nature of the MDV is an inevitable tool to develop the control measures. Eg. If outbreaks occur due to Virulent Pathotype, it can be controlled by administration of HVT vaccine. If it is affected by very virulent pathotype, it can be controlled by the bivalent vaccine i.e., HVT+ SB1. If the outbreak is due to very virulent plus pathotype, it can be controlled by vaccination with serotype 1 vaccine viz., CVI988. In some situation, even if the farm is vaccinated with HVT strain, still the virulent pathotype outbreaks occur in the vaccinated flock; it indicates the vaccine failure. Using this molecular tool, the cause for the outbreaks can be identified i.e., whether due to the emergence of new pathotype or to establish the cause of vaccine failure. So, the study was planned to identify the MDV pathotype in India in order to use a

suitable vaccine for the control the spread of MDV infection in commercial or breeder poultry flocks.

Material and Methods

Birds

Birds received for *post mortem* investigation in the Avian Disease Laboratory, Indian Veterinary Research Institute (IVRI) were screened for the presence of MDV infection irrespective of age (2 – 70 months), breed and sex, for a period of two years. Since, enlargement of liver was also found in the lymphoid leucosis (LL), all the liver sample and other neoplastic tissues were collected for differential diagnosis. In addition samples of spleen and feather follicle were also collected and processed for MDV investigation. One portion of the studied samples was processed for the histopathological study, being and stained with haematoxylin and eosin (H&E). The other portion of the samples was stored at -80o C for molecular studies by polymerase chain reaction (PCR) to differentiate pathotypes of MDV.

Preparation of APES coated slides for immunohistochemistry

Microscopic slides were washed by immersing in 2% labolene detergent in pre-warmed distilled water (DW) for 30 minutes. Followed thorough rinsing in DW, acetone and air dried (at 37°C). For coating, slides were immersed in 2% (v/v) 3-aminopropyle triethoxysilane (APES) for 30 minutes. Finally, the slides were rinsed gently in acetone, then in distilled water and air dried at 37o C (11).

Preparation of sections for immune-staining

4µm thick serial sections were sectioned from appropriately selected tissue blocks, based on the screening of H&E slides by using rotary microtome on to APES coated slides and dried overnight at 37oC. The sections were de-paraffinized at 60°C, for 1 hr and air dried. Sections were rehydrated via series of graded alcohols (absolute alcohol I and II to quench the xylene, followed by 95%, 90% and then 70% alcohols) followed by gently rinsing in tap water and then sections were rinsed in PBS (pH 7.4).

Proliferate Cell Nuclear Antigen (PCNA) staining Technique

PCNA was immuno-histochemically determined using formalin fixed paraffin embedded tissue as per Yu et al. (23).

Indirect Fluorescent Antibody Technique (IFAT)

Doubtful MD tumour tissues were further conformed by the IFAT as per the standard procedure and visualized under a fluorescent microscope (12).

DNA Isolation for PCR

DNA was isolated from the tissue of various organ in MD suspected birds as per Ausubel et al. (1) and the purity of DNA was checked in spectrophotometer by 260/280 ratio.

Primers for MDV Serotype 1: PCR was carried out for serotype 1 specific region of MDV-gA using the following primers i.e., F: CATGCAAGTCATTATGCGTGAC R: TGTTTCCATTCTGTCTCCAAGA. Amplification of 200bp product indicates the presence of serotype 1 virus (24).

Primers for VV MDV: Primers designed specifically to target against the LTR region of MDV were used for amplification of the VV pathotype. The following primers

were used i.e., F: TACTTCCTATATAGATTGAGACGT and R: GAGATCCTCGTAAGGTGTAATATA as described by Becker et al. (2). Amplified product size of 434/585 indicates the presence of VV pathotype in the affected birds.

Results

Gross Pathology

Enlargement of liver was most frequently observed in the affected birds. Few liver samples show tiny (1-2 mm) to large size (5 – 7 mm) with whitish patches were found (Fig. 1). In addition, tumours were also found in spleen (Fig. 2A), ovaries (Fig. 2D and 2E) and intestines. The size for the tumours in various organs were usually 1 mm (white foci) to a maximum of 7 mm size (nodule type) (Fig. 2F). Neoplasia was rarely observed in heart (Fig. 2B) and in two cases observed in proventriculus i.e., Thickening and slight enlargement were observed (Fig. 2C).

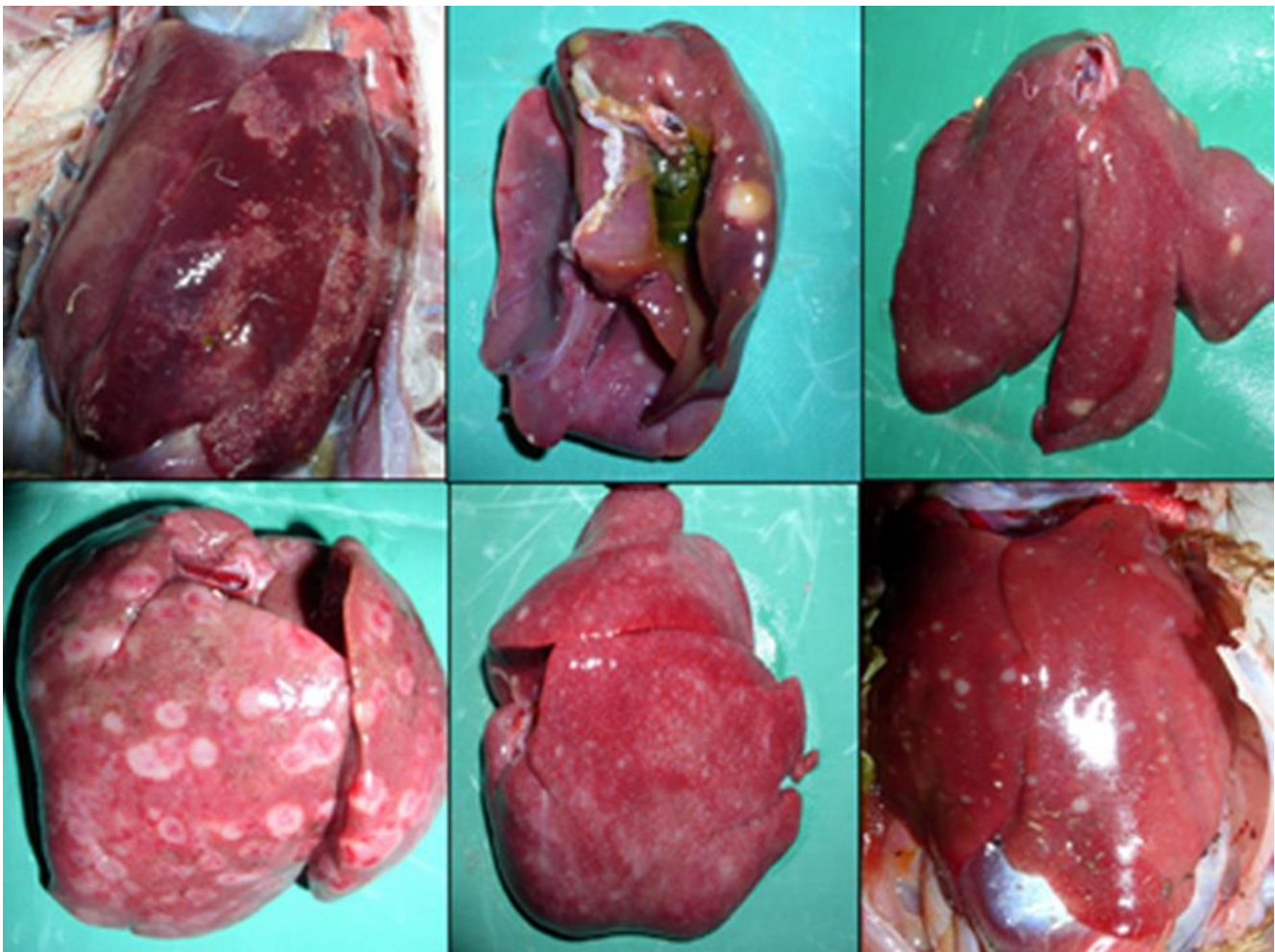


Figure 1. Livers from layer bird showing small milliary white foci to solid focal lymphoid tumors.

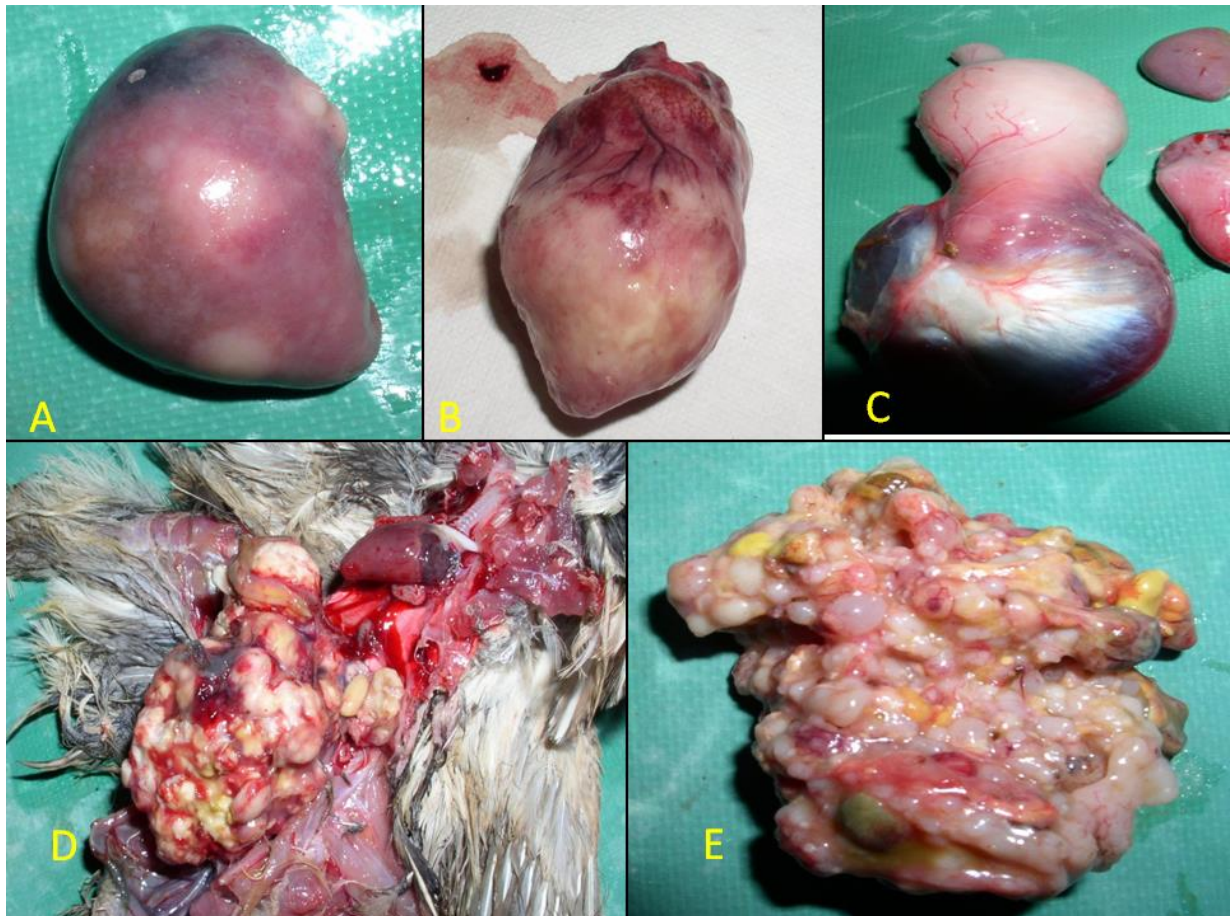


Figure 2. A. Spleen showing diffuse enlargement with varied size, neoplastic areas. B. Heart showing diffuse enlargement with greyish white areas. C. Congestion, enlargement and thickening of proventriculus. D and E. Ovary showing greyish white, large, neoplastic lymphoid growth.

Histopathology

Liver: All liver samples showed mild to moderate sinusoidal dilatation with engorgement of central vein along with perivascular lymphoid foci containing numerous pleomorphic lymphocytes. Moderate to severe perivascular lymphoid infiltration were also observed consisting of pleomorphic lymphocytes. Diffuse to marked fatty degeneration of lymphocyte with dilated sinusoids and mild pleomorphic lymphocytic infiltrations were observed (Fig. 3A and 3B).

Spleen: Most of the spleen samples showed severe and diffuse lymphoid depletion of foci of lymphoid follicles consisting of pleomorphic lymphocytes and engorgements of sinusoids were noticed in few areas of spleen of affected birds (Fig. 3C).

Heart: Two heart samples showing lymphoid foci consist of pleomorphic lymphocytes and marked lymphocyte infiltration was noticed between the myocytes (Fig. 3D).

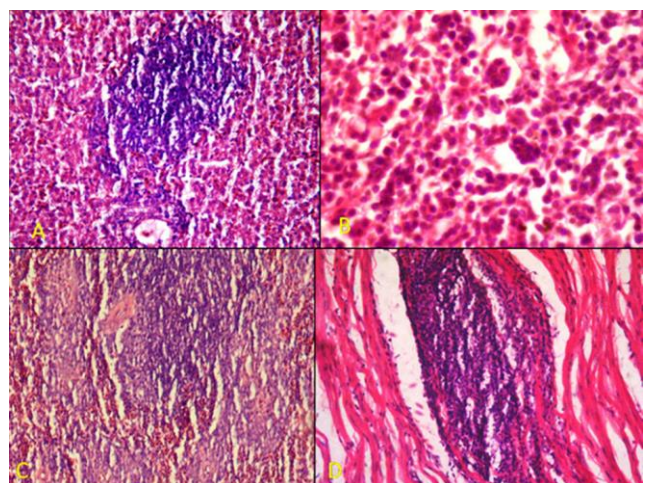


Figure 3. A. Liver showing marked perivascular infiltration of pleomorphic mononuclear cells (H&E × 200). B. Higher magnification of A, showing pleomorphic lymphocytes, lymphoblast and few multinucleated cells (H&E ×1000). C. Spleen showing infiltration of pleomorphic lymphocytes in lymphocytic (H&E ×100). D. Myocardium showing focal area of lymphocytic focal infiltration (H&E × 200).

Brain: Few birds showed perivascular cuffing (Fig. 4B) in the brain.

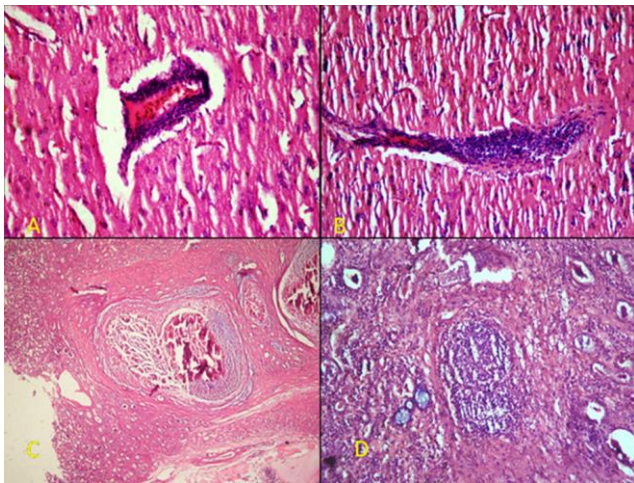


Figure 4. A. Brain showing perivascular cuffing (H&E 400X). B. Brain showing endotheliosis (H&E 200X). C. Kidney showing central area of necrosis and calcification surrounded by fibroblastic reaction (H&E 40X). D. Kidney showing foci of neoplastic lymphoid area surrounded by mild fibroplasia (H&E 100X).

Kidney: All the affected kidney samples showed moderate to severe diffused pleomorphic lymphocytic infiltration and tubular degeneration along with foci of pleomorphic infiltrations were noticed in the glomerulus. Fibrosarcomatus proliferation containing a focal area of pleomorphic lymphocytic infiltration was observed.

Sciatic Nerve: All affected sciatic nerve showed massive infiltration of pleomorphic lymphocytes in perineural space and congested perineural blood vessels and encroachment of pleomorphic lymphocytes and lymphoblasts cells in between nerve fibres.

Proventriculus: A diffuse thickening of lamina propria consisting of proliferating fibroblast and pleomorphic lymphocytic infiltration (Fig. 5C and D).

Immuno-histochemistry

PCNA staining: In kidney, interstitial infiltration of lymphocytic cells showed strong PCNA positivity and moderate to strong PCNA positive cells were observed in focal lymphocytic neoplastic cells. Mild to moderate infiltration of PCNA positive cells were observed in the liver, spleen and proventriculus of affected birds (Fig. 6A & B).

Indirect Fluorescent Antibody Test (IFAT)

Doubtful MD samples were further confirmed by the IFAT technique with MD specific anti serum (Charles

River, USA) Kidney sections which showed foci of lymphocytic cells exhibit strong positive signals (Fig. 6C and D).

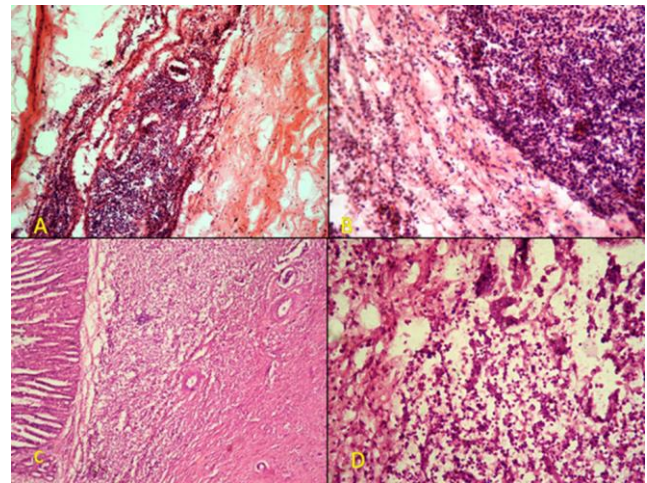


Figure 5. A. Sciatic nerve showing massive infiltration of pleomorphic lymphocytes in perineural space (H&E 100X). B. Higher magnification of A (H&E 400X). C. Proventriculus showing diffuse infiltration of mononuclear cells in the lamina propria with fibroplasia (H&E 100X). D. Proventriculus showing pleomorphic lymphocytes and lymphoblasts (H&E 400X).

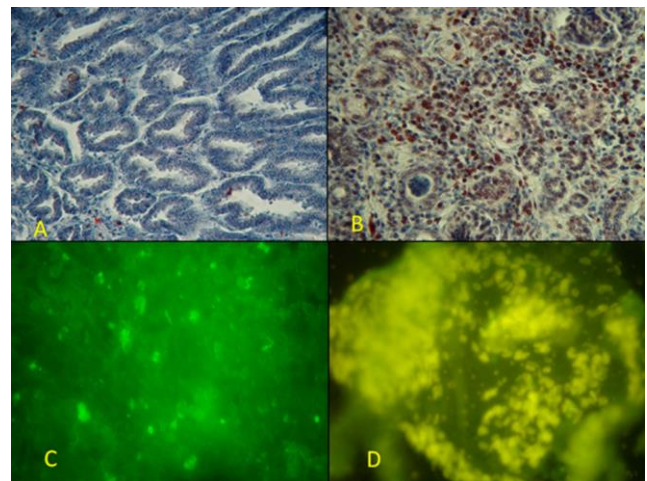


Figure 6. A. PCNA negative control kidney showing no immunostaining of tubular epithelium (IPDAB- MH 400X). B. Kidney showing foci of strong nuclear PCNA-positive immunostained neoplastic lymphoid cells (IPDAB-MH 400X). C. IFAT control- kidney showing no positivity (FITC 100X). D. Kidney numerous tumour cells showing specific apple green fluorescence (FITC 400X).

Polymerase chain reaction (PCR)

PCR for MDV Serotype 1 Virus: Amplification of 200bp product in the PCR indicated the presence of MDV serotype 1 (Fig. 7). DNA isolated from the spleen sample was able to amplify the PCR product as compared to other

organ. Poor amplification of PCR product was observed from the neoplastic liver tissue. Amplification was not obtained from all analyzed neoplastic tissue samples. On the other hand, negative results for MDV serotype 1 in PCR were noted in case of tumour samples from ovary, kidney and proventriculus. Similarly, DNA was also isolated from the Feather follicles; but the isolated DNA was very low in concentration, and only three samples were found positive among the 35 feather follicle samples.

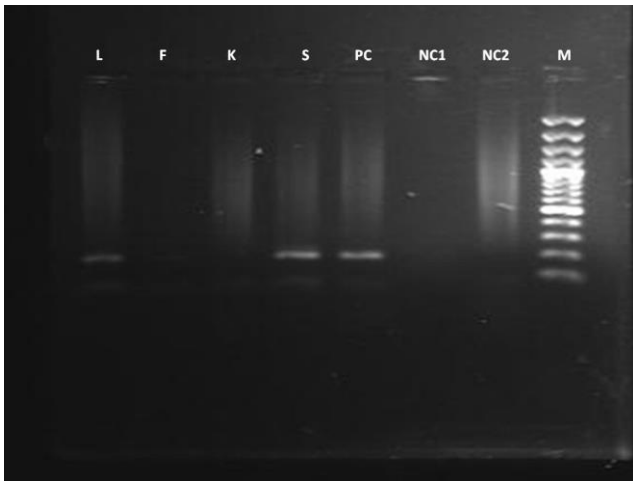


Figure 7. Amplification of 200 bp for serotype 1 virus, L: Liver, F: Feather Follicles, K: Kidney, S: Spleen, PC: Positive control, NC1: Negative control 1 (without DNA), NC2: Negative control 2 (with DNA), M: leader.

PCR for VV MDV: DNA positive samples were further tested for pathotype determination and only one bird tissue showed positive for VV pathotype i.e., Amplification of 434 bp (Fig. 8) indicate the VV pathotype.

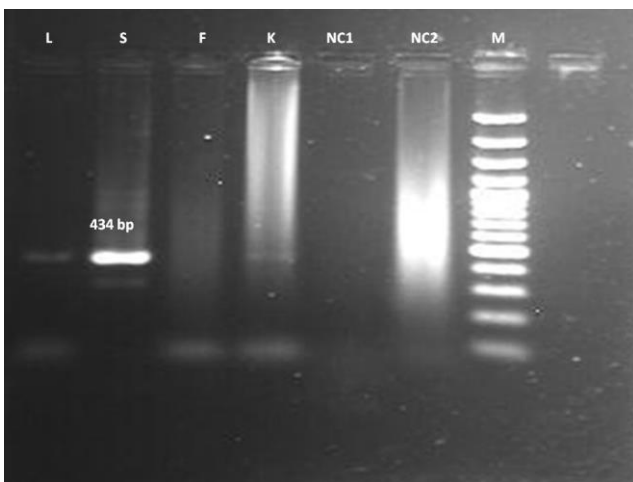


Figure 8. Amplification of 434bp band for the very virulent pathotype virus, L: Liver tissue, S: Spleen tissue, F: Feather Follicles, K: Kidney, NC1: Negative control-1 (without DNA), NC2: Negative control-2 (with DNA), M: Leader.

Discussion

In the present study, MDV was screened in the birds received in the *post mortem* service, as well as from a commercial poultry farm samples, irrespective of age, and sex, for a period of two years of study. Collected samples were processed for histopathology in order to differentiate MD from LL. Simultaneously, all the neoplastic tissues were collected and sent for the molecular diagnosis. Peripheral blood lymphocytes (PBL) are suitable organ for the testing of virus in the live birds, but, in dead birds, it is not possible to collect it. As per the previous report by Islam et al., (2001) (7); spleen tissue is equally sensitive PBL to detect the MDV by PCR. Hence, along with neoplasia samples, spleen samples were also collected and sent for molecular confirmation.

Based on the gross lesions, it was observed that the liver was the most predominantly affected organ for MDV. All liver samples showed gross lesions, with diffuse enlargement, fewer had white patches or smaller nodule i.e., milliary type size from 1 mm to 7 mm (nodules). Payne and Venugopal (15) also reported the diffuse enlargement and presence of nodules in the MD affected birds, that usually is confused with lymphoid leucosis (14). Few birds showed ovarian MDV-related-tumours and only in one case there was heart and intestine tumours (19). Two cases of proventriculus thickening were observed in MD affected birds. Similarly, Eid et al. (4) also reported that proventriculus thickening in the MD affected birds. Lymphoproliferative lesions in wide range of organs such as liver, gonads, lung, proventriculus and heart also reported in OIE (14).

The histopathological examination showed the characteristic lesions of MD, such as pleomorphic lymphocyte infiltration in a wide range of organs as previously described by Witter and Schat (18). Neoplastic cell infiltrations were mostly large and focal, as described by Payne and Venugopal (14). Also, splenic lymphocytic depletion was in accordance with similar results, previously reported by Davison and Nair (3). In brain, endotheliosis and perivascular cuffing are two of the major lesions of the paralytic form of MD. Even though perivascular cuffing is not pathognomonic for MD, it is not observed in all MD cases as described by the Witter and Schat (19). Jarosinski et al. (8) stated that the over production of proinflammatory cytokines are responsible for the pathological changes in the brain. They also observed that virulent strain is able to replicate better in the brain and spleen tissues, than the less virulent strain; thus would be a major factor for the neurological signs. So, histopathological section of brain will be useful for differential diagnosis from LL and less virulent MDV.

PCR was successfully carried out by using DNA from tumour as well as spleen samples from necropsied and affected birds. Thus, spleen tissues are proposed to be remarkably suitable target for the detection of MDV even in absence of MD associated tumours. Islam et al. (7)

recommended that spleen samples are more suitable for amplification of PCR product. Since all the MD affected birds showed liver neoplasia, the amplified PCR product was poor or not clear. Better result was observed in the spleen tissue; even though there was no tumor. All remaining organs included in our study showed poor results for the amplification of MDV. PCR was also carried out for the feather follicle samples as described by the Handberg et al. (6). Our results highlighted that only 3 out of 35 of the analyzed feather follicle samples were positive by PCR. Hence, we concluded that feather follicle samples were not suitable for the molecular identification of MD by PCR.

All 35 MDV positive samples were, then, checked for pathotype identification showing positivity for the serotype 1 of MDV and finally tested for the very virulent types of the studied virus. Similarly, Raja et al. (16) collected 173 tissue samples and screened MDV by PCR in India. This Indian work found 22 positive samples for MDV serotype 1 from 173 samples; among them 11 were VV pathotype.

In our study, suspected histopathological sections, in which pleomorphic lymphocytic cells needed to be confirming for MDV were firstly processed by PCNA immunohistochemistry and later subjected to fluorescent antibody technique. Morris et al. (13) also described similarly results concerning PCNA staining.

In the present study, we concluded that spleen samples were the optimal tissue in order to isolate DNA and carry out PCR for MDV pathotype identification. Regarding the performed postmortem examination of affected birds, the location of tumours was mainly in livers. Feather follicles were not suitable samples for the identification MD by PCR. Among the 35 bird's sample tested, only one bird was positive for VV MDV, the remaining samples were virulent pathotype. Since HVT vaccine was not able to protect the birds from the VV pathotype; a bivalent vaccine, such as the combination of Serotype 1 and 2 (HVT+ SB1), is recommended to control MD in the poultry flocks for better management of MD virus infection in India.

Acknowledgement

The experimental work carried out by Mr. (Late) Dinesh Chandra Pant, Technical Officer, Avian Disease Section is greatly acknowledged.

Conflict of Interest

The authors declare that they have no conflict of interest

References

1. Ausubel FM, Brent R, Kingston RE, Moore DD, Seidman JG, Smith JA, Struhl K. Current protocols in

molecular biology. 1st ed. Hoboken: Wiley; 1992. 231p.

2. Becker Y, Tabor E, Asher Y, Davidson I, Malkinson M, Witter RL. PCR detection of amplified 132 bp repeats in Marek's disease virus type 1 (MDV-1) DNA can serve as an indicator for critical genomic rearrangement leading to the attenuation of virus virulence. *Virus genes*. 1993;7(3):277-87.
3. Davison F & Nair V, editors. Marek's Disease: An Evolving Problem. London: Elsevier Academic Press; 2004. p.98-111.
4. Eid AE, Abd-Elattieff HA, Ellakany HF, Abou-Rawash AR, AbdEl-Hamid HS. Studies on tumor disease viruses in chickens in Egypt. *Alexandria J Vet Sci*. 2019;60(1):184-95.
5. Gimeno IM. Marek's disease vaccines: a solution for today but a worry for tomorrow?. *Vaccine*. 2008;26(suppl 3):31-41.
6. Handberg KJ, Nielsen OL, Jorgensen PH. The use of serotype 1-and serotype 3-specific polymerase chain reaction for the detection of Marek's disease virus in chickens. *Avian Pathol*. 2001;30(3):243-9.
7. Islam MF, Walkden-Brown SW, Burgess SK, Groves PJ. Marek's disease in broiler chickens: effect of route of infection and herpesvirus of turkey-vaccination status on detection of virus from blood or spleen by polymerase chain reaction, and on weights of birds, bursa and spleen. *Avian Pathol*. 2001;30(6):621-8.
8. Jarosinski KW, Njaa BL, O'connell PH, Schat KA. Pro-inflammatory responses in chicken spleen and brain tissues after infection with very virulent plus Marek's disease virus. *Viral Immunol*. 2005;18(1):148-61.
9. Kamaldeep PC, Sharma C, Narang G. Occurrence of Marek's disease in vaccinated poultry flocks of Haryana (India). *Int J Poult Sci*. 2007;6(5):372-7.
10. Lamont SJ. The chicken major histocompatibility complex and disease. *Rev Sci Tech Off Int Epiz*. 1998;17:128-34.
11. Maddox PH, Jenkins D. 3-Aminopropyltriethoxysilane (APES): a new advance in section adhesion. *J Clin Pathol*. 1987;40(10):1256.
12. Mitchell A, Goodwin A. Centrocestiasis (gill trematode disease). FHS blue book: suggested procedures for the detection and identification of certain finfish and shellfish pathogens. Bethesda, Maryland: American Fisheries Society Book Series. 2004. 12p.
13. Morris GF, Mathews MB. Regulation of proliferating cell nuclear antigen during the cell cycle. *J Biol Chem*. 1989;264(23):13856-64.
14. OIE, 2018. International Office of Epizootics. Biological Standards Commission, International Office of Epizootics. International Committee. Manual of diagnostic tests and vaccines for terrestrial animals: mammals, birds and bees. Office international des épizooties; 2018. Available from:

<http://www.oie.int/standard-setting/terrestrial-manual/access-online>.

15. Payne LN, Venugopal K. Neoplastic diseases: Marek's disease, avian leukosis and reticuloendotheliosis. *Rev Sci Tech Off Int Epiz.* 2000;19(2):544-60.
16. Raja A, Dhinakar RG, Bhuvaneswari P, Balachandran C, Kumanan K. Detection of virulent Marek's disease virus in poultry in India. *Acta Virologica.* 2009;53(4):255.
17. Schumacher D, Tischer BK, Teifke JP, Wink K, Osterrieder N. Generation of a permanent cell line that supports efficient growth of Marek's disease virus (MDV) by constitutive expression of MDV glycoprotein E. *J Gen Virol.* 2002;83(8):1987-92.
18. Visnuvinayagam S, Sukumar K. Assessment of the pathogenicity of cell-culture-adapted Newcastle disease virus strain Komarov. *Braz J Microbiol.* 2015;46(3):861-5.
19. Witter and Schat, Marek's disease, In: *Diseases of Poultry.* 11th ed. Saif YM., Barnes HJ, Glisson JR, Fadly A M, McDougald LR, Swayne DE, editors. Iowa State University Press, 2003. p.407-65.
20. Witter RL, Sharma JM, Fadly AM. Pathogenicity of variant Marek's disease virus isolants in vaccinated and unvaccinated chickens. *Avian Dis.* 1980;1:210-32.
21. Witter RL, Li D, Jones D, Lee LF, Kung HJ. Retroviral insertional mutagenesis of a herpesvirus: a Marek's disease virus mutant attenuated for oncogenicity but not for immunosuppression or in vivo replication. *Avian Dis.* 1997;1:407-21.
22. Witter RL, Calnek BW, Buscaglia C, Gimeno IM, Schat KA. Classification of Marek's disease viruses according to pathotype: philosophy and methodology. *Avian Pathol.* 2005;34(2):75-90.
23. Yu CW, Hall PA, Fletcher CD, Camplejohn RS, Waseem NH, Lane DP, Levison DA. Haemangiopericytomas: the prognostic value of immunohistochemical staining with a monoclonal antibody to proliferating cell nuclear antigen (PCNA). *Histopathology.* 1991;19(1):29-34.
24. Zhu GS, Ojima T, Hironaka T, Ihara T, Mizukoshi N, Kato A, Ueda S, Hirai K. Differentiation of oncogenic and nononcogenic strains of Marek's disease virus type 1 by using polymerase chain reaction DNA amplification. *Avian Dis.* 1992;1:637-45.