



## Original Full Paper

# A review of neoplastic and non-neoplastic canine skin tumours in Trinidad from 2010-2015

Rod Suepaul, Stacy Rajh, Karelma Frontera-Acevedo\*, Indira Pargass, Sharianne Suepaul

Department of Basic Veterinary Sciences, School of Veterinary Medicine, Faculty of Medical Sciences, School of Veterinary Medicine, University of West Indies, Champ Fleurs, Trinidad.

\*Corresponding author: E-mail: [Karelma.fronteraacevedo@sta.uwi.edu](mailto:Karelma.fronteraacevedo@sta.uwi.edu)Submitted November, 12<sup>th</sup> 2018, Accepted March, 1<sup>st</sup> 2019

---

## Abstract

This retrospective study was performed on samples submitted to the Pathology Unit of the School of Veterinary Medicine, Faculty of Medical Sciences, St. Augustine, Trinidad, during the period 2010 to 2015. A total of 471 non-inflammatory cutaneous masses were analyzed, of which 225 (47.8%) were malignant, 202 (42.9%) were benign and 44 (9.3%) were non-neoplastic. The most common malignant tumors were haemangiosarcoma, 50 (22.2%); mast cell tumour, 49 (21.8%); soft tissue sarcoma 35 (15.6%), lymphoma, 20 (8.9%) and melanoma 20 (8.9%). The most common benign tumors were haemangioma, 39 (19.3%); lipoma, 27 (13.4%), trichoblastoma, 26 (12.9%), histiocytoma 25 (12.4%), plasma cell tumor, 23 (11.4%) and papilloma 9 (4.5%). Common non-neoplastic skin lesions included collagen naevi, 26 (59.1%) and follicular cysts, 11 (25.0%). Mixed breed dogs 241 (51.2%), was most frequently represented with neoplasms followed by Rottweilers 50 (10.6%) and Pit bulls 48 (10.1%).

**Key words:** canine, skin, neoplasia, comparative oncology, pathology, Trinidad.

---

## Introduction

Canine neoplasia continues to be an important disease in dogs worldwide. In a UK study, it accounted for 27% of all deaths in purebred dogs (1). Dogs share our living environment and sometimes diet, which exposes them to similar risk factors as humans (2). Neoplasia is seen primarily in older dogs and with increased lifespans of dogs due to advances in veterinary medicine, one might expect an increase in neoplasia cases (3).

In dogs, the skin has been one of the most common organs affected by neoplasia (4, 5). Skin neoplasia is readily detected by owners and easily accessed by veterinarians for diagnostic testing, a factor which is likely to contribute to the relatively high volume of skin biopsy submissions to diagnostic laboratories (6, 7). In Trinidad, the skin is the tissue most frequently sampled for biopsy, accounting for 69% (2010-2015) of the submissions to the histopathology laboratory at the School of Veterinary Medicine, The University of the West Indies (SVM).

The prevalence of different types of skin neoplasia has been shown to vary in different regions; however, other factors such as breed prevalence in different geographical locations may affect the outcome of such studies (4, 7, 8). In one study in the UK, it was found that the most common tumor type was canine cutaneous histiocytoma, followed by lipoma, adenoma, soft tissue sarcoma, mast cell tumor, and lymphoma (8). A recent study on the neighbouring island of Grenada (4) found that the some of the most common skin neoplasms, were haemangiosarcoma, histiocytoma, melanocytoma and mast cell tumor.

Geographical location may also influence the types of neoplasia that dogs develop, especially as it pertains to UV induced neoplasms. Grenada, like Trinidad, is a tropical island and the exposure to year round high levels of UV radiation could influence the types of neoplasms that develop in the skin, such as haemangiosarcoma, which are known to be induced by UV radiation and was the most commonly detected neoplasm in that study (4, 9). Exposure to UV radiation also

contributes to the development of dermal haemangioma and squamous cell carcinoma (9-11). Areas of skin, especially on the ventral abdomen in dogs, which are light haired or non-pigmented are more likely to develop dermal haemangiosarcoma (11). On the other hand, dogs with heavily pigmented skin such as Schnauzers and Scottish Terriers, are more likely to develop cutaneous melanoma (12).

Exposure or access to other carcinogenic agents may also affect the type of neoplasm that develops. Dogs living close to industrialized areas have been shown to be more prone to developing neoplasia (13). In developing countries, where the laws governing proper disposal and handling of waste material and chemicals may not be adequately enforced, this may result in an increased risk of developing cancer.

Breed has been associated with certain types of skin neoplasia. Boxers, Labrador and Golden Retrievers, Shar-peis, Bulldogs, Boston terriers, Pitbull Terriers, Fox Terriers, Weimerainers, Cocker Spaniels, Rhodesian Ridgebacks, Dachshunds, Australian Cattle Dogs, Beagles, Schnauzers and Pug dogs are breeds that are predisposed to develop mast cell tumor (14-16). The Bernese mountain Dog and Flat Coated Retriever are well known for its susceptibility to histiocytic sarcoma (7, 9, 17). The Golden Retriever is more likely to develop mast cell tumor, lymphoma and haemangiosarcoma (7).

Certain breeds such as Boxers, Bullmastiff and Bulldog may have a higher risk for the development of lymphoma when compared to other breeds (18). Breed type can also affect the prognosis for melanocytic neoplasms, as one study has found that over 75% of this tumor type exhibits benign behavior in the Doberman and Miniature Schnauzer, whereas more than 85% of melanocytic neoplasms are malignant in the Miniature Poodle (19). The Giant Schnauzer is predisposed to develop squamous cell carcinomas (4, 20). The outcome of breed prevalence studies also depends on the breed prevalence within the population at risk, which may explain the differences found in studies from different countries (7, 8). In Trinidad, the popular pure breeds include the Rottweiler, Pitbull and the German Shepherd, and typical neoplasia associated with these breeds can influence the relative prevalence of different skin neoplasia types.

Mast cell tumor (MCTs) are estimated to represent up to 21 percent of all skin tumors (14). Melanocytic tumor in dogs account for 4% of cutaneous tumors (19). The rate of occurrence of different types of cutaneous neoplasia in Trinidad is currently unknown and this study aims to highlight the common types of these tumors and determine if there is any breed, age or sex influence on cutaneous neoplasia in Trinidad.

## Material and methods

This retrospective study was conducted on the skin tumors cases submitted to the Veterinary Anatomical Pathology Laboratory Unit of the SVM during the period spanning 2010 to 2015. The necropsy and biopsy reports for canines were reviewed, and those with a diagnosis of a non-inflammatory skin mass were extracted. These tumors were classified as benign, malignant and non-neoplastic masses. Details of the diagnosed neoplasm, location, age, breed and sex were tabulated using Microsoft Excel 360. The data was then analyzed using Statistical Package for Social Sciences (SPSS) version 22. Chi-squared testing, ANOVA and multiple comparisons were performed on the data using SPSS. All dogs that were not recorded as a pure breed were considered to be mixed.

## Results

A total of 471 non-inflammatory skin masses were found, with 44 (44/471) being non neoplastic, 202 (202/471) being benign and 225 (225/471) were malignant (Figure 1). In all three categories, mixed breeds (241/471) were the most common affected, followed by Rottweilers (50/471) and Pitbulls (48/471). Mixed breeds were also the most common for each of the neoplasm except for papilloma, for which there were only 9 cases.

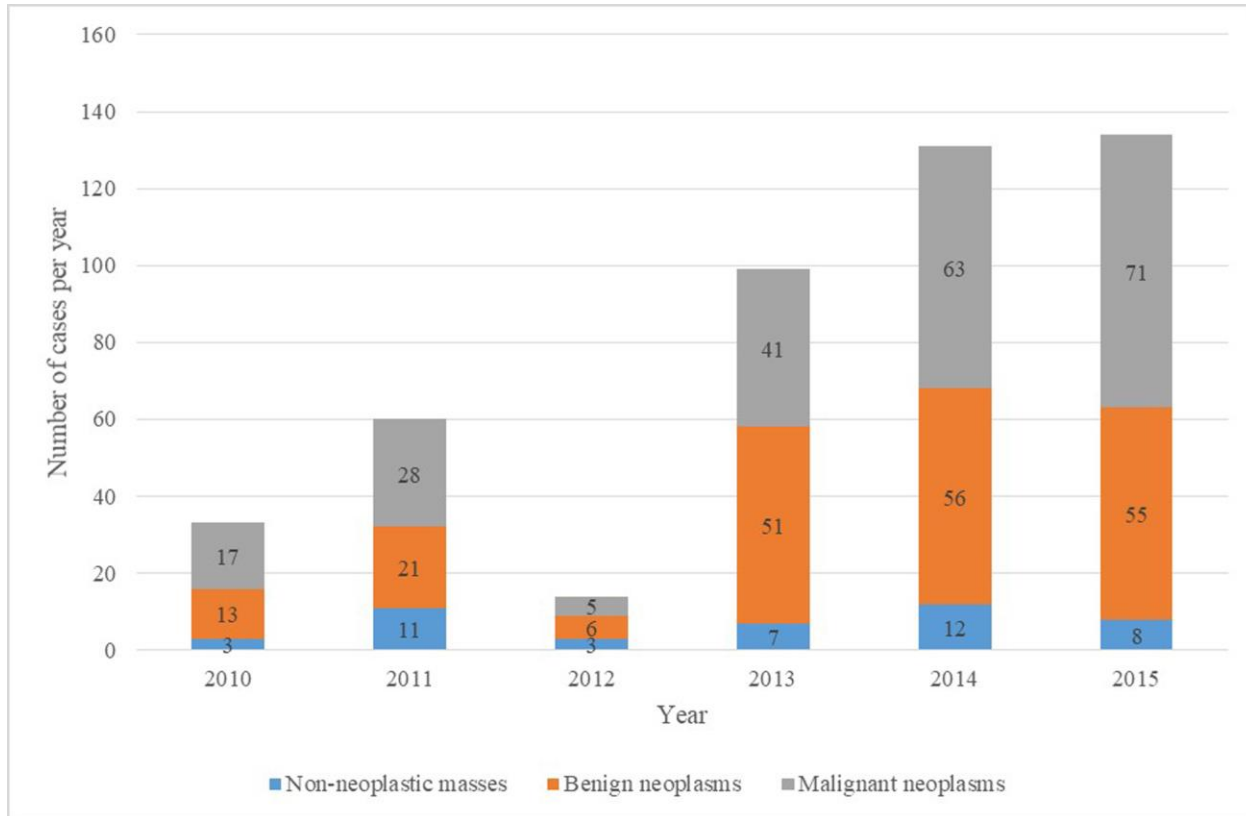
Dogs in the senior age bracket (> 6 years old) were the most commonly affected in all categories (255/424) whilst those considered young dogs (0-3 years old), were the least affected (26/424). The age was only recorded for 424 of the 471 dogs. No sex predilection was determined to be significant for any of the masses investigated in this study. The mean age of skin mass development was slightly higher for malignant neoplasms (7.8 yrs.) than for benign (7.54 yrs.) or non-neoplastic masses (7.27 yrs.), however, this was not statistically significant in this study.

Over the period of the study, the number of masses submitted annually showed a general increase from 33 in 2010 to 134 in 2015, with the exception of 2012, when there was a reduction to 14. Among the non-neoplastic skin masses, collagenous hamartomas (26/44) and follicular cysts (11/44) were found to be the most commonly occurring. Haemangioma (39/202), were found to be the most commonly occurring benign cutaneous neoplasm, followed by lipoma (27/202), trichoblastoma (26/202), histiocytomas (25/202), plasma cell tumor (23/202) and papilloma (9/202) (Table 1). Rottweiler (16/202), Pitbull (16/202) and German Shepherd (12/202) were the commonly affected pure breeds.

The most commonly malignant cutaneous tumor was t haemangiosarcoma (50/225), followed by mast cell tumor (49/225), soft tissue sarcoma (35/225), lymphoma (20/225), melanoma (20/225) and squamous cell carcinoma (10/225) (Table 2). Pitbull (14/50) was the most commonly affected pure breed with

haemangiosarcoma. Mixed breed dogs were the most commonly affected for all of the malignant cutaneous neoplasms (117/225), followed by Rottweiler (29/225) and Pitbull (28/225). The Rottweiler was the second most commonly affected breed for the following

neoplasms: plasma cell tumors, lymphoma, soft tissue sarcomas and fibrosarcoma. Pitbull was the third most commonly affected breed overall with malignant tumors (28/225), and the second most commonly affected breed for mast cell tumor (6/49).



**Figure 1.** Graphic representation of the type of skin masses in dogs, from 2010 until 2015, in Trinidad.

**Table 1.** Benign skin neoplasms that were observed (n+151) in dogs for the years 2010-2015

Type of benign neoplasm	Number of cases (%)	Breeds (number)
Haemangioma	39 (19.3%)	Mixed 17 Pit bull 7 Rottweiler 0 Doberman 0 German Shepherd 5 Other 10
Lipoma	27 (13.4%)	Mixed 17 Pit bull 1 Rottweiler 1 Doberman 0 German Shepherd 0 Other 8
Trichoblastoma	26 (12.9%)	Mixed 17 Pit bull 2 Rottweiler 0 Doberman 0 German Shepherd 3 Other 4
Histiocytoma	25 (12.4%)	Mixed 5 Pit bull 2 Rottweiler 5 Doberman 1 German Shepherd 1 Other 11
Plasma cell tumour	23 (11.4%)	Mixed 10 Pit bull 2 Rottweiler 4 Doberman 0 German Shepherd 0 Other 7
Papilloma	9 (4.5%)	Mixed 2 Pit bull 2 Rottweiler 3 Doberman 0 German Shepherd 0 Other 2
Other	53 (26.2%)	Mixed 29 Pit bull 0 Rottweiler 3 Doberman 0 German Shepherd 3 Other 18
Total	202 (100%)	Mixed 97 Pit bull 16 Rottweiler 16 Doberman 1 German Shepherd 12 Other 60

**Table 2.** Malignant skin neoplasms that were observed (n=242) in dogs for the years 2012-2015.

Type of malignant neoplasm	Number of cases (%)	Breeds (number)
Haemangiosarcoma	50 (22.2%)	Mixed 23 Pit bull 14 Rottweiler 0 Doberman 2 German Shepherd 1 Other 10
Mast cell tumour	49 (21.8%)	Mixed 26 Pit bull 6 Rottweiler 3 Doberman 0 German Shepherd 0 Other 14
Soft tissue sarcoma	35 (15.6%)	Mixed 17 Pit bull 2 Rottweiler 0 Doberman 0 German Shepherd 3 Other 4
Lymphosarcoma	20 (8.9%)	Mixed 11 Pit bull 2 Rottweiler 3 Doberman 0 German Shepherd 1 Other 3
Melanoma	20 (8.9%)	Mixed 9 Pit bull 1 Rottweiler 7 Doberman 2 German Shepherd 1 Other 0
Squamous cell carcinoma	10 (4.4%)	Mixed 7 Pit bull 1 Rottweiler 1 Doberman 0 German Shepherd 0 Other 1
Undifferentiated round cell tumour	10 (4.4%)	Mixed 3 Pit bull 2 Rottweiler 3 Doberman 0 German Shepherd 0 Other 2
Other	47 (20.8%)	Mixed 30 Pit bull 1 Rottweiler 9 Doberman 1 German Shepherd 1 Other 5
Total	225 (100%)	Mixed 122 Pit bull 28 Rottweiler 29 Doberman 6 German Shepherd 5 Other 35

## Discussion

Over the period of the study, the general increase in the number of cutaneous masses submitted for histopathological examination was possibly due to increased public and/or veterinary practitioner awareness of the services available at the SVM, for which active marketing began in 2010. However, culturally, owners are not always willing to pay for histopathology services and the number of cases received may under represent tumor number.

As expected, older dogs (> 6 years old) were the most commonly affected by all categories of masses (255/424). Neoplasia is a disease of older dogs (3) and the average of occurrence for most of the neoplasms found would fall into the senior age bracket. The number of dogs involved in the study would likely have affected the detection of statistically significant trends in age for the individual masses. Due to the low number of submissions, no sex predilection could be determined for any of the breeds or neoplasms in this study.

While certain purebred dogs are generally more affected by particular types of skin tumors, in this study, Mixed breed dogs were over represented for all of the tumors, which is different from other studies (5, 21). Assessment of the effect of breed on the different types of neoplasia did not reveal significant findings. Among the pure bred dogs, the Rottweiler was the breed in which most of the skin neoplasia occurred. Pitbull, which is thought to be a popular breed in Trinidad, had the second highest incidence of skin masses. The popularity of these two breeds may have contributed to the high numbers of particular types of neoplasms encountered.

Collagenous hamartoma (26/44), was the most common non-neoplastic lesion found in this study, in accordance to the literature (22). This finding was in contrast to the Grenada study, where this was one of the lesser occurring non-neoplastic tumors (4). Follicular cysts (11/44) were the second most common non-neoplastic masses in this study as in other study (23). They are often removed due to concern for possible neoplasia, and hence are likely to be one of the common masses submitted for histopathology.

Not surprisingly, haemangioma (39/202) and haemangiosarcoma (50/225) were found to be the most commonly occurring benign and malignant skin neoplasms, respectively, in this study. These two tumors are associated with UV radiation (9, 10), and it is no surprise that they are the most common neoplasms, as Trinidad is a tropical country and there is year round exposure to sunlight.

Lipoma (27/202) was found to be the second most common benign skin neoplasm in this study, and are noted as being common in the dog (22). Trichoblastoma (26/202) were the third most common benign cutaneous neoplasm and are common in the dogs between 4-10 years of age (6). The fourth most common benign cutaneous

neoplasm was the histiocytoma (25/202), which occurs predominantly in dogs under 4-years-old (22), again however, no significant age predilection was found in this stud.

Plasma cell tumor (23/202) occurred mainly in older dogs, contributing to the higher occurrence of this type of neoplasia in senior animals. Breeds which have been noted to be preferentially affected by plasma cell tumor were Terriers, Cocker Spaniels, Standard Poodles (22). However, none of these breeds were popular in our study, as these breeds are not considered to be very common in Trinidad. Papilloma (9/202) is also another common skin neoplasm in dogs, and in most species affects younger animals (6).

Mast cell tumor has been noted elsewhere as the most frequent malignant skin neoplasm in dogs representing up to 21% of skin neoplasms, with no known sex or age predilection (14). In this study while they did account for 21.8% of the malignant skin neoplasms, they were the second most common malignant skin neoplasm detected. However, total number of dogs affected was only 1 less than the most common malignant tumor. In this study, soft tissue sarcoma was the third most common malignant neoplasm. This type of neoplasm was found to be the most common type in one UK study (8). Cutaneous lymphoma was the fourth most common malignant tumor. Breeds predisposed include English Cocker Spaniels, Bulldogs, Boxers, Scottish Terriers and Golden Retrievers, which are all uncommon in Trinidad (22).

The Rottweiler was the pure breed mostly affected by melanoma, the dark pigment of the coat may be a likely contributing factor as with schnauzers and Scottish Terriers (12). UV radiation also plays a role in the development of squamous cell carcinoma (10) and would be an important factor in the common occurrence of this neoplasm in this study in a tropical country. (23).

In conclusion, haemangiosarcoma and haemangioma, both UV induced tumors, were the highest occurring malignant and benign neoplasms in this study on a tropical island. Mixed breeds were the most commonly affected, which is likely due to the high prevalence of mixed bred dogs on the island. Older dogs were more commonly affected. The study was limited by the volume of cases but does represent all of the skin biopsy submission for the period stated, as there was no other histopathology service available on the island.

## References

1. Adams VJ, Evans KM, Sampson J, Wood JL. Methods and mortality results of a health survey of purebred dogs in the UK. *J Small Anim Pract.* 2010;51(10):512-24.
2. Pinho SS, Carvalho S, Cabral J, Reis CA, Gartner F. Canine tumors: a spontaneous animal model of human carcinogenesis. *Transl Res.* 2012;159(3):165-72.

3. Bonnett BN, Egenvall A, Olson P, Hedhammar A. Mortality in insured Swedish dogs: rates and causes of death in various breeds. *Vet Rec.* 1997;141(2):40-4.
4. Chikweto A, McNeil P, Bhaiyat MI, Stone D, Sharma RN. Neoplastic and nonneoplastic cutaneous tumors of dogs in Grenada, West Indies. *ISRN Vet Sci.* 2011;2011:416435.
5. Graf R, Pospischil A, Guscetti F, Meier D, Welle M, Dettwiler M. Cutaneous Tumors in Swiss Dogs: Retrospective Data From the Swiss Canine Cancer Registry, 2008-2013. *Vet Pathol.* 2018;55(6):809-20.
6. Goldschmidt MH, Goldschmidt KH. Epithelial and Melanocytic Tumors of the Skin. In: Meuten DJ, editor. *Tumors in domestic animals.* 5th ed. Iowa: John Wiley & Sons Inc.; 2017. p. 88-141.
7. Dobson JM. Breed-predispositions to cancer in pedigree dogs. *ISRN Vet Sci.* 2013;2013:941275.
8. Dobson JM, Samuel S, Milstein H, Rogers K, Wood JL. Canine neoplasia in the UK: estimates of incidence rates from a population of insured dogs. *J Small Anim Pract.* 2002;43(6):240-6.
9. Hargis AM, Ihrke PJ, Spangler WL, Stannard AA. A retrospective clinicopathologic study of 212 dogs with cutaneous hemangiomas and hemangiosarcomas. *Vet Pathol.* 1992;29(4):316-28.
10. Nikula KJ, Benjamin SA, Angleton GM, Saunders WJ, Lee AC. Ultraviolet radiation, solar dermatosis, and cutaneous neoplasia in beagle dogs. *Radiat Res.* 1992;129(1):11-8.
11. Ward H, Fox LE, Calderwood-Mays MB, Hammer AS, Couto CG. Cutaneous hemangiosarcoma in 25 dogs: a retrospective study. *J Vet Intern Med.* 1994;8(5):345-8.
12. Goldschmidt MH, Shofer FS. *Skin tumors of the dog and cat.* 1st ed. Oxford England; New York: Pergamon Press; 1992. xi, 316 p.
13. Vascellari M, Baioni E, Ru G, Carminato A, Mutinelli F. Animal tumour registry of two provinces in northern Italy: incidence of spontaneous tumours in dogs and cats. *BMC Vet Res.* 2009;5:39.
14. Kiupel M. Mast Cell Tumors. In: Meuten DJ, editor. *Tumors in domestic animals.* 5th ed. Iowa: John Wiley & Sons Inc.; 2017. p. 176-202.
15. Gruntzig K, Graf R, Boo G, Guscetti F, Hassig M, Axhausen KW, Fabrikant S, Welle M, Meier D, Folkers G, Pospischil A. Swiss Canine Cancer Registry 1955-2008: Occurrence of the Most Common Tumour Diagnoses and Influence of Age, Breed, Body Size, Sex and Neutering Status on Tumour Development. *J Comp Pathol.* 2016;155(2-3):156-70.
16. Villamil JA, Henry CJ, Bryan JN, Ellersieck M, Schultz L, Tyler JW, Hahn AW. Identification of the most common cutaneous neoplasms in dogs and evaluation of breed and age distributions for selected neoplasms. *J Am Vet Med Assoc.* 2011;239(7):960-5.
17. Abadie J, Hedan B, Cadieu E, De Brito C, Devauchelle P, Bourgain C, Parker HG, Vaysse A, Margaritte-Jeannin P, Galibert F, Ostrander EA, André C. Epidemiology, pathology, and genetics of histiocytic sarcoma in the Bernese mountain dog breed. *J Hered.* 2009;100(1):S19-27.
18. Onions DE. A prospective survey of familial canine lymphosarcoma. *J Natl Cancer Inst.* 1984;72(4):909-12.
19. Bolon B, Calderwood Mays MB, Hall BJ. Characteristics of canine melanomas and comparison of histology and DNA ploidy to their biologic behavior. *Vet Pathol.* 1990;27(2):96-102.
20. Belluco S, Brisebard E, Watrelot D, Pillet E, Marchal T, Ponce F. Digital squamous cell carcinoma in dogs: epidemiological, histological, and immunohistochemical study. *Vet Pathol.* 2013;50(6):1078-82.
21. Bronden LB, Nielsen SS, Toft N, Kristensen AT. Data from the Danish veterinary cancer registry on the occurrence and distribution of neoplasms in dogs in Denmark. *Vet Rec.* 2010;166(19):586-90.
22. Hendrick MJ. Mesenchymal Tumors of the Skin and Soft Tissues. In: Meuten DJ, editor. *Tumors in domestic animals.* 5th ed. Iowa: John Wiley & Sons Inc.; 2017. p. 142-75.
23. Hargis AM, Myers S. The Integument. In: Zachary JF, editor. *Pathologic basis of veterinary disease.* 6th ed. St. Louis, Missouri: Elsevier; 2017. p. 1009-146.