



Case Report

Perinatal mortality in cattle associated with goitre

Juan F. Micheloud^{1,2}, Leandro H. Olmos^{1,2}, Juan A. Garcia³, Guillermo A. Mattioli⁴, Francisco A. Uzal^{5*}

¹Instituto Nacional de Tecnología Agropecuaria, Área de Salud Animal, Salta, Argentina.

²Facultad de Ciencias Veterinarias, Universidad Católica de Salta, Salta, Argentina.

³Consejo Nacional de Investigaciones Científicas y Técnicas, Buenos Aires, Argentina.

⁴Laboratorio de Minerales, Facultad de Ciencias Veterinarias, Universidad Nacional de La Plata, La Plata, Argentina.

⁵California Animal Health and Food Safety Laboratory System, School of Veterinary Medicine, University of California-Davis, San Bernardino, California, USA.

*Corresponding author: California Animal Health and Food Safety Laboratory System, School of Veterinary Medicine, University of California-Davis, 105 W Central Ave, 92408, San Bernardino, CA, USA. E-mail: fuzal@cahfs.ucdavis.edu

Submitted March, 1st 2019, Accepted May, 8th 2019

Abstract

The role of iodine in ruminant reproductive function is well known. However, studies about the impact of this deficiency in reproductive performance of cattle are scarce. This paper describes stillbirth episodes in three beef cow herds in northwest Argentina. The stillbirth losses ranged between 15.8 and 25%. Grossly, the thyroid glands presented diffuse, bilateral and symmetric enlargement. Microscopically, follicular epithelium showed severe hyperplasia and hypertrophy, forming multiple stratified layers of large cuboidal cells, with papillary projections into the follicular lumen. Free thyroxine (T4f) mean levels in serum from aborted cows and heifers was 0.63 ± 0.05 ng/dl. A diagnosis of congenital goiter was performed based on these findings. Following the diagnosis, the herds were supplemented orally and parentally with iodine. Mean T4f level post-treatment was 0.80 ± 0.05 ng/dl and the stillbirth rate dropped sharply.

Key words: reproductive losses, congenital goiter, iodine deficiency.

Introduction

Beef bovine production in Argentina over the past decade or so has been characterized by relocation to marginal lands, and reduction of stock. The net consequence of the first is an increase in the numbers of cattle heads in the northwest and northeast regions of the country (11). In addition, the average national weaning rate did not exceeded 65% due to, among other causes, high perinatal losses. The latter are defined as death that occurs immediately before, during or up to 48 hours after birth (1).

The role of iodine on reproductive function is well known (17, 18). In ruminants, the metabolism of the maternal thyroid gland is fundamental for fetal growth and development (14). Thyroxine (T4) synthesis and its conversion into tri-iodo-thyronine (T3) depends on the

integrity of the thyroid gland and the adequate supply of maternal iodine (17, 18).

Reproductive losses associated with iodine deficiency in cattle and other animal species have been described throughout world (12, 14, 17). However, information about perinatal calf mortality associated with iodine deficiency in South America is scant (6, 9). This paper describes three outbreaks of perinatal calf mortality associated with iodine deficiency and goiter in northwestern Argentina.

Case Report

The outbreaks occurred in three beef cattle farms (E1, E2 and E3) of the Argentinean northwest. The location, production characteristics and number of cattle per herd are shown in Table 1. All affected cows were in

excellent nutritional condition and did not show clinical abnormalities before or after the abortions. Affected calves (n=33) were born dead or died between a few minutes and several hours after birth. No placental retention was observed. The calves that were born alive presented in

respiratory difficulty, reduction of the suction reflex and were unable to stand. Edema in craneo-ventral area of the neck was observed in one animal.

Table 1. Location, signalment and mortality rate in three farms with goiter-associated perinatal mortality pre and post treatment with iodine.

Farms	Location	Categories of animals present in ranch	N° of heads in ranch	Breed	Feeding	Perinatal mortality rate	
						Pre-treatment	Post-treatment
E1	29°44'68"S 63°25'49" W (Santiago del Estero province)	Heifers	140	Brangus	<i>Gatton panic</i> grazing	15.8 %	0 %
E2	24°86'88"S 65°59'20"W (Salta province)	Cows and heifers	120	Crossbreed	Mixed natural pasture grazing + sorghum silage (<i>ad libitum</i>)	25 %	12%
E3	25°09'49"S 65°49'67" W (Salta province)	Cows and heifers	20	Aberdeen Angus	Mixed natural pasture grazing + corn silage (12 kg/head/day)	20 %	3.6 %

The Specialized Veterinary Diagnostic Service of the National Institute of Agricultural Technology in Salta, Argentina (SDVE-INTA, Salta), received three dead calves

(N1, N2 and N3) originating in each of the farms included in this study, respectively. Signalment of these three animals is summarized in Table 2.

Table 2. Signalment and thyroid gland weight of three calves necropsied with goiter.

Calves	Breed	Sex	Body weight	Thyroid gland weight	Thyroid gland weight/ Body weight
N1	Brangus	Male	25 kg	24 g	0.92 %
N2	Crossbreed	Female	23 kg	48 g	2.08 %
N3	Aberdeen Angus	Male	19 kg	68 g	3.57%

Full necropsies were performed on the three calves. The thyroid gland of the three calves were diffusely hyperemic and had diffuse, bilateral and symmetric enlargement (Fig. 1). The total weight of the thyroid gland was 24, 48 and 68 g for animals N1, N2 and N3, respectively (Table 1). In addition, calf N3 showed mild subcutaneous edema in the ventral area of the upper neck. No other significant gross abnormalities were observed in any of the three calves examined.

Samples of thyroid gland, liver, spleen, kidney, lung, lymph nodes, brain and spinal cord from each calf were collected and fixed in 10% buffered, pH 7.2 formalin for 24-48 h and processed routinely to produce 5 µm thick hematoxylin and eosin sections.

Microscopically, the most striking lesions were observed in the thyroid gland and they were similar in the three animals. They consisted of very small and irregular follicles with the lumen almost completely obliterated and absence of colloid. The follicular epithelium showed severe and diffuse hyperplasia and hypertrophy (Fig. 1) and presented up to three layers of cells, and papillary projections into the follicular lumen. Occasionally, mitotic

figures were observed in follicular epithelial cells. Two calves presented partial atelectasis in the cranial lobes of both lungs. No other significant microscopic abnormalities were observed in any other tissue of the three calves examined.

Blood without anticoagulant was collected from 20, 15 and 10 non-aborted adult cows in each herd, respectively (Table 3). Aborted cows had been culled and were no longer available for sampling. The first set of samples was collected during the last gestation trimester. The serum was separated and processed to determine levels of free thyroxine (T4f) by radioimmunoassay in solid phase as previously described (2). In these cows, the average T4f level was 0.63 ± 0.05 ng/dl (Table 3). Normal range of T4f is 0.7±0.18 (13).

In view of these results, cows in the three herds were treated with iodine. In E1 and E2, a commercial iodine product (4 g of organic iodine/100 ml) was used subcutaneously at the dose recommended by the manufacturer (15 ml/animal). In E3 a solution of metallic iodine (12g/100 ml) and potassium iodide (8.57g /100 ml) was spread daily on the food (corn silage) at an

approximate dose of 0.05ml/animal. About 30 days post-treatment, the animals were sampled for the determination of T4f again. The T4f levels increased significantly in the three herds after treatment with an average T4 level of 0.80

± 0.05 ng/dl (Table 3). The number of dead or weak calves in the three herds was drastically reduced in the next calving season (Table 1).

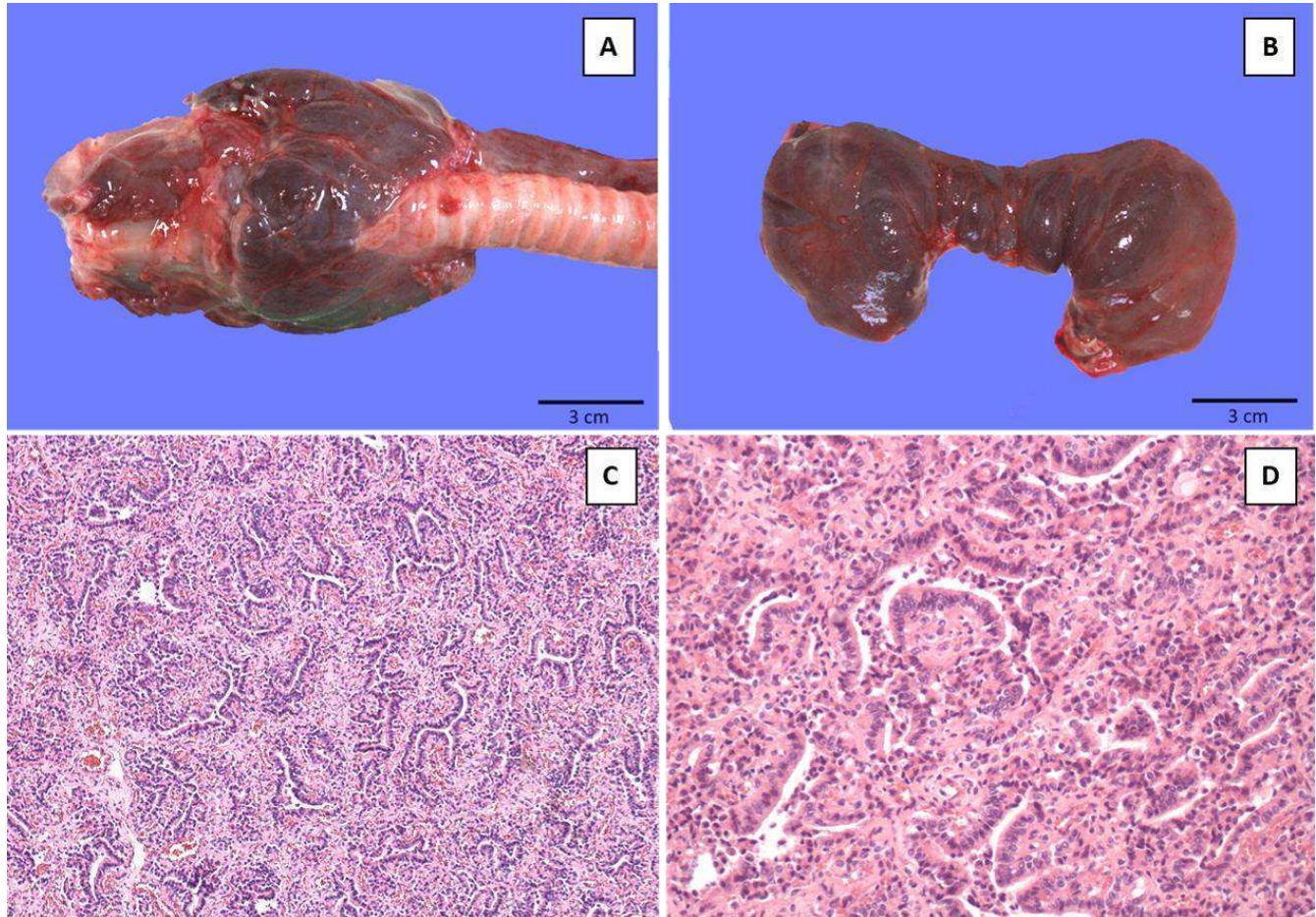


Figure 1. Calf thyroid gland. **A** and **B.** Bilateral and symmetrical increment in size. **C** and **D.** Diffuse hyperplasia of follicular cells, forming papillary projections and obliterating the follicular lumen. Colloid is absent. H&E stain.

Table 3. Free thyroxine (T4f) levels in cows of three farms before and after iodine treatment.

Farm	n	Pre-treatment T4f (ng/dl)	Post-treatment T4f (ng/dl)
E1	20	0,69 \pm 0,08a	0,86 \pm 0,08b
E2	15	0,54 \pm 0,04a	0,68 \pm 0,03b
E3	10	0,67 \pm 0,05a	0,87 \pm 0,04b
Average	45	0,63 \pm 0,05a	0,80 \pm 0,05b

T4f reference (adult cattle) = 0,7 \pm 0,18 ng/dl. (Paulíková et al., 2011).

Discussion

Based on epidemiology, gross, microscopic and biochemical findings, a diagnosis of congenital diffuse goiter due to iodine deficiency was established. This diagnosis was further confirmed when after treating cows with iodine, T4f levels increased and perinatal mortality was reduced.

Nichols et al. (1949) found that in bovine fetuses the relative growth of the thyroid glands is constant in relation to body weight. According to Underwood and Suttle (18) the thyroid gland weight of a normal calf is 14 g or less; a weight >18 g is indicative of congenital goiter. Thyroids weighing between 14 and 18 g are considered borderline for a diagnosis of congenital goiter. In our study, the weight of the thyroid glands of the three calves

was well above 18 g. In cases of goiter, the follicular cell hyperplasia is caused by the persistent stimulation of thyroid-stimulating hormone (TSH) on these cells in response to low peripheral concentrations of T3 and T4 (15, 18), which was the case in these animals.

Matamoros et al. (7) suggested that T4f is the most appropriate hormone to evaluate thyroid function in cattle. Supporting this recommendation, Contreras et al (2) found normal levels of T3 but low levels of T4f in animals with subclinical hypothyroidism. However, the levels of T4f suggested as normal are variable in the literature (3, 18). In the present study, all animals of the three study herds received iodine supplementation, after which the neonatal losses dropped dramatically and no new cases of goiter were observed. These findings suggest that the hypothyroidism observed was the result of iodine deficiency. In E2, although perinatal mortality rates decreased, the levels continued to be high post iodine administration. It was speculated that this was due to the fact that concentrations of T4f persisted at subnormal levels after applying iodine.

In ruminants under extensive grazing conditions, the possible origins of hypothyroidism are: 1) forage and water with low iodine concentration, 2) selenium deficiency, and 3) ingestion of goitrogens contained in plants or other food (17). No goitrogenic plants species were observed in the grazing area of any of the herds. The presence of the same problem in three distinct farms of the same region, suggests the low concentration of iodine in forage as a fundamental cause of hypothyroidism. The Argentine northwest is known for iodine deficiency in the human population (17). Studies about iodine deficiency in animals are, however, scarce. García Torregrosa (5) reported low concentrations of iodine in bovine milk from the Lerma Valley in Salta province, while Marin et al. (6) reported reproductive losses due to different infectious causes and assumed to be predisposed by iodine deficiency in a breeding herd from the San Martín County in the same province. In the present study, an analysis of infectious causes on mortality rate was not carried out. However, the gross and microscopic features observed and the response to iodine supplementation in the three herds strongly suggests that iodine deficiency was the most probable cause of the perinatal losses.

In ruminants and other animals, hypothyroidism is characterized, amongst other problems, by reproductive disorders such as infertility, prolonged gestation, abortions, and increased perinatal mortality rates (8). The birth of weak calves that have difficulty incorporating and suckling is a frequent finding in iodine deficiency as seen in the three herds presented here (6, 18). Thyroid hormones are essential to maintain the basal metabolism and thermoregulation of newborns (17, 18).

Selenium deficiency can also induce hypothyroidism because the conversion of T4 to T3, which is the active form of thyroid hormone in tissues, requires the action of the enzyme deiodinase, which is selenium-

dependent (18). The concentration of selenium in the animals of this study was not measured and therefore selenium co-deficiency cannot completely be ruled out. However, the significant clinical improvement observed after iodine supplementation suggests that the main cause of hypothyroidism in these animals was iodine and not selenium deficiency. Furthermore, no gross or microscopic lesions suggestive of selenium deficiency were seen in any of the animals of this study (4).

Acknowledgements

This study was supported by grants from Instituto Nacional de Tecnología Agropecuaria and Consejo de Investigación de la Universidad Católica de Salta, both in Argentina. We thank the Dr. Carlos Campero and Dr. Daniel Aguirre for their critical review of this manuscript.

References

1. Campero CM, Canton GJ. Introducción y patogénesis de las pérdidas reproductivas en bovinos. In: Campero CM, Canton GJ, Moore DP, editors. Abortos y otras pérdidas reproductivas en bovinos: Diagnóstico y control. Buenos Aires, Argentina, Hemisferio Sur. 2017. p.12-22.
2. Contreras PA, Ruiz V, Wittwer F, Böhmwald H. Valores sanguíneos de triyodotironina (T3) y tiroxina (T4) en vacas lecheras de sur de Chile. X Congreso Chileno de Medicina Veterinaria, Valdivia, Abril, 1998. p. 135-6.
3. Contreras PA, Wittwer F, Ruiz V, Robles A, Böhmwald H. Valores sanguíneos de triyodotironina y tiroxina en vacas frisón negro a pastoreo. Arch Med Vet. 1999;31:205-10.
4. Davis AJ, Myburgh JG. Investigation of stillbirths, perinatal mortality and weakness in beef calves with low-selenium whole blood concentrations. J S Afr Vet Assoc. 2016;87:1336.
5. García Torregrosa MD. Estudio de los niveles de yodo en bovinos lecheros del Valle de Lerma, provincia de Salta. Rev Arg Prod An. 1986;16:83-4.
6. Marín RE, Cantón G, Campero CM. Pérdidas reproductivas por causas infecciosas asociadas a deficiencia de yodo en un rodeo de cría del Noroeste Argentino. Vet Arg. 2009;34:1852-8.
7. Matamoros R, Gomez C, Andaur M. Hormonas de utilidad diagnóstica en Medicina Veterinaria. Arch Med Vet. 2002;34:167-82.
8. McClure TJ. Infertilidad nutricional y metabólica de la vaca. Edit. Acribia, 1st ed. Zaragoza, España. 1995. p.45-63.
9. Martins KPF, Fonseca TRS, Silva ES, Munhoz, TCP, Dias GHS, Galiza GJN, Oliveira LGS, Boabaid FM. Bócio em bovinos. Pesq Vet Bras. 2018;38:1030-7.

10. Nichols CW, Chaikoff IL, Wolff J. The relative growth of the thyroid gland in the bovine fetus. *Endocrinology*. 1949;44:502-9.
11. Observatorio Ganadero. Caracterización regional: Noroeste Argentino. Salta. Observatorio de la Cadena de la Carne Bovina de Argentina, informe N°3, sección 3. Buenos Aires, Argentina. 2013. p.18.
12. Panziera W, Kowalski AP, de Galiza GJN, Bianchi RM, Pires Espíndola J, Machado Cardoso M, Castagna de Vargas A, Almeida Figuera R. Bócio congênito em caprinos no Noroeste do Rio Grande do Sul, Brasil. *Cienc Rural*. 2014;12:2217-20.
13. Paulíková I, Seidel H, Nagy O, Tóthová C, Kovác G. Concentrations of thyroid hormones in various age categories of ruminants and swine. *Acta Veterinaria*. 2011;61:489-503.
14. Piosik PA, Van Groenigen M, Van Doorn J, Baas F, De Vijlder JM. Effects of maternal thyroid status on thyroid hormones and growth in congenitally hypothyroid goat foetuses during the second half of gestation. *Endocrinology*. 1997;138:5-11.
15. Rosol TJ, Gröne A. Endocrine glands, In: Maxie G, editor, Jubb, Kennedy and Palmer's Pathology of Domestic Animals. 6th ed. Vol. 3. San Diego: Elsevier. 2016. p. 269-357.
16. Salvaneschi JP, García JR. El bocio endémico en la República Argentina Antecedentes, extensión y magnitud de la endemia, antes y después del empleo de la sal enriquecida con yodo: Primera Parte. *Rev Arg End Met*. 2009;46:35-57.
17. Singh R, Beigh SA. Diseases of thyroid in animals and their management. In: Carreira RP, editor. *Insights from Veterinary Medicine*. In Tech, s.l. <http://dx.doi.org/10.5772/55377>. 2013. p.233-40.
18. Underwood EJ, Suttle NF. Yodo. In: Underwood EJ, Suttle NF, editors. *Los minerales en la nutrición del ganado*. Zaragoza, España: Acribia. 2003. p. 349-80.