Braz J Vet Pathol, 2019, 12(2), 53 – 57
DOI: 10.24070/bjvp.1983-0246.v12i2p53-57

BJVP
Brazilian Journal of Veterinary Pathology
ISSN 1983-0246

Case Report

A case of orbital extra-adrenal paraganglioma in a quarter horse

Letizia Tomassini*, Ilaria Pettinari, Elvio Lepri, Rodolfo Gialletti, Enrico Bellezza, Leonardo Leonardi

University of Perugia, Department of Veterinary Medicine, 06126 Perugia, Italy.
***Corresponding author:** E-mail: letizia_tomassini@hotmail.com

Submitted January, 26th 2019, Accepted March, 25th 2019

Abstract

Paragangliomas are tumors originating from paraganglia cells which represent a considerable constituent of the dispersed neuroendocrine system. Rarely these tumors are found within the orbital region. This report documents a case of primary extra-adrenal paraganglioma in a 15-year-old female quarter horse, diagnosed on the basis of clinical signs, gross anatomopathological, histopathological and immunohistochemical investigations. Clinical diagnostics led to full appreciation of the severe tumor invasiveness and to an informed decision by the owner for euthanasia. Gross inspection confirmed the previous clinical assessments of exophthalmos consequential to pressure from the orbital neoplasia, revealing a mass infiltrating into surrounding tissues. Histopathology and immunohistochemistry allowed for the final diagnosis of paraganglioma. Histology sections showed a partially encapsulated infiltrative mass with multifocal angiotropic growth, and composed of polygonal cells organized in nests, packets, and bundles supported by a fibrovascular stroma. The lobules were lined peripherally by spindle cells. The tumor was highly vascular with blood-filled lacunae and multifocal to coalescing areas of liquefactive necrosis. The polygonal cells were characterized by indistinct borders, lightly eosinophilic cytoplasm with moderate amount of granules, round or oval central nuclei with stippled chromatin ("salt and pepper" appearance) and inconspicuous nucleoli. Immunohistochemistry aided in the diagnostic discrimination of paraganglioma from neuroendocrine carcinoma and in the assessment of tumor differentiation. Orbital paraganglioma holds low likelihood for animal survival, but may have good prognosis when timely addressed.

Key words: extra-adrenal paraganglioma, equine, exophthalmos, orbital.

Introduction

The paraganglion system, represented by a wide paraganglia network located in different tissues as individual cells or cell aggregates, embodies a major component of the dispersed neuroendocrine system (4). Paraganglia cells originate embryonically from the neural crest, and during the pre-partum developmental stages migrate eventually establishing in the adrenal medulla and in extra-adrenal sites of the head, neck, mediastinum, retro-peritoneum, and abdomen regions. Depending on the anatomic location, paraganglia can be associated with the sympathetic autonomic nervous system (so called chromaffin paraganglia based on positive staining with chrome containing dyes) or the parasympathetic autonomic nervous system (non-chromaffin paraganglia). Paragangliomas, the tumors arising from paraganglia cells, may cause a wide range of clinical and pathological signs depending on functional secreting activity and anatomic location (7). Chromaffin (sympathetic) paragangliomas can be either adrenal (pheochromocytoma) or extra-adrenal, and both can induce clinical conditions due to release of catecholamines. Non-chromaffin (parasympathetic) extra-adrenal paragangliomas are slow-growing non-secreting tumors, and clinical signs are usually a consequence of tumor local invasiveness and rarely metastases. A peculiar and rare extra-adrenal paraganglioma may be found in the orbit in horses, likely originating as primary tumor from non-chromaffin paraganglia situated near the ciliary ganglion (8). Most often, exophthalmos and infiltration into adjacent tissues are the main clinical and anatomopathological manifestations from this type of tumor.

 All rights reserved 2007.

Braz J Vet Pathol, 2019, 12(2), 53 – 57
DOI: 10.24070/bjvp.1983-0246.v12i2p53-57

Here we describe a case of primary extra-adrenal paraganglioma of the orbit in a 15-year-old quarter horse mare, with a special focus on histopathology and immunohistochemistry (IHC) evaluations.

Case report

A 15-year-old Quarter Horse mare was referred to the hospital of the veterinary medicine department at the University of Perugia with signs of progressive exophthalmos, chemosis of conjunctiva and ocular exudation at the right eye. Prior to admission date, the clinical history had been three years of non-painful exophthalmos and blindness of the right eye for which the referring veterinarian suspected a neoplasia. The animal was otherwise in good overall health.

The animal was sedated and ultrasound, rhinoscopy, and X-rays were performed. Ultrasound examination of the right eye displayed a retro-bulbar, hyperechogenic, parenchymatous mass. Further clinical investigation performed by endoscopy of the upper respiratory tract and right frontal sinus revealed tumor protrusion into the right nasal cavity (Fig. 1). Finally, X-ray examination clearly showed diffuse osteolysis and mass infiltration into the sphenopalatine and caudal maxillary sinuses, while the frontal sinus did not seem affected. A cytological sampling via transcutaneous fine needle aspiration (FNA) was attempted but the quality of the sample was poor; a suspicion of neoplasia was reached based on the absence of inflammatory cells and the presence of parenchymal, but no otherwise specified, cells.

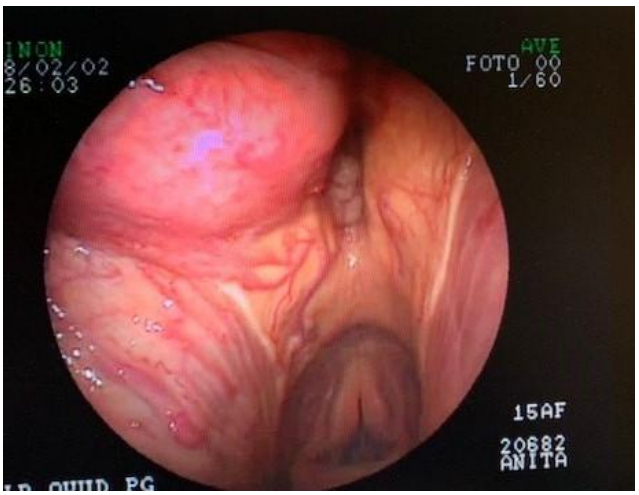

Figure 1. Endoscopic image of paraganglioma grown in the left orbital region and protruding into the pharynx cavity.

Due to poor clinical conditions, mass invasiveness, and unfavorable prognosis, the owner decided to proceed to euthanasia; a full necropsy was performed.

Gross examination confirmed all previous clinical diagnostics, showing tumor infiltration into the right conchal sinus with diffuse right orbit osteolysis (Fig. 2). The mass measured 8.0 x 6.0 x 10 cm, appeared partially encapsulated and hemorrhagic with ulcerated mucosal surface. No metastatic dissemination and organ colonization was detected, nor were other lesions found during necropsy. Tissue specimens were collected, fixed in 10% buffered formalin, processed according to routine laboratory procedures, embedded in paraffin wax, cut at 5 µm slides, and stained with hematoxylin and eosin. Histology sections showed a partially encapsulated infiltrative mass with multifocal angiotropic growth; the mass was composed of polygonal cells organized in nests, packets, and bundles, and supported by a fine fibrovascular stroma (Fig. 3). The lobules were lined peripherally by spindle cells. The tumor was highly vascular with blood-filled lacunae and multifocal to coalescing areas of liquefactive necrosis. The polygonal cells were characterized by indistinct borders, lightly eosinophilic cytoplasm with moderate amount of granules, round or oval central nuclei with stippled chromatin ("salt and pepper" appearance) and inconspicuous nucleoli. Anisocytosis and anisokaryosis were mild and mitoses very sporadic (mitotic count was 2/10 High Power Fields).



Figure 2. Gross appearance of exophthalmos caused by orbital paraganglioma and head cut surface showing osteolysis determined by tumor's infiltration.

Further investigations were performed by use of immunohistochemistry techniques. Briefly, previously paraffin included tissue samples were serially sectioned to a thickness of 2-3 µm, deparaffinized and rehydrated to distillated water. Antibodies used for immunohistochemistry were: anti-Neuron-Specific Enolase (NSE), anti-Glial Fibrillary Acidic Protein (GFAP), anti- pancytokeratins (CK), anti-Vimentin, anti-Synaptophysin, and anti-Chromogranin A. Except for the latter, which did not require antigen retrieval pretreatment, the slides used for the remaining immunostains were pretreated as follows: a 20 minute microwave treatment in

Braz J Vet Pathol, 2019, 12(2), 53 – 57
DOI: 10.24070/bjvp.1983-0246.v12i2p53-57

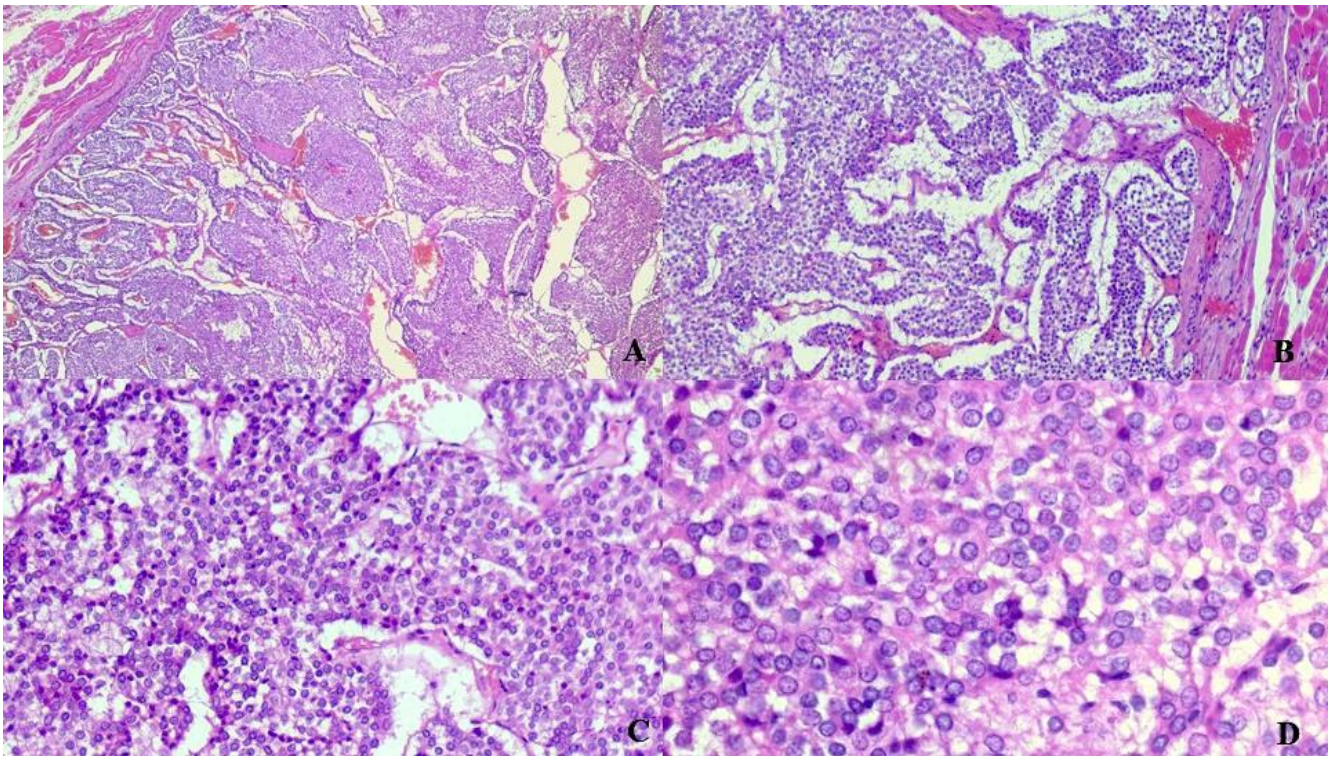

Figure 3. A-D. Paraganglioma histopathological features. Pictures **A** and **B**, particularly, show diffuse tumor angiotropic growth and its high vascularization with blood-filled lacunae. Hematoxylin-Eosin stain. 40x (A), 10x (B), 200x (C), 400x (D).

pH6 (in preparation for downstream reaction with antibodies to NSE and GFAP) or in pH9 (in preparation for downstream reaction with antibodies to CK AE1/AE3, Vimentin, Synaptophysin). Sections were treated with 3% H_2O_2 for endogenous peroxidase activity inhibition, and incubated in a moist chamber with a protein block for 10 minutes. Antibodies were diluted according to specific requirements: anti-CK (AE1/AE3; Dako; 1:200), anti-vimentin (V9; Dako; 1:200), anti-chromogranin A (Dako; 1:200), anti-NSE (BBS/NC/VI-H14; Dako; 1:100), anti-GFAP (Dako; 1:1000), anti-synaptophysin (SY38; Dako; 1:30). Sections were incubated with antibodies for two hours at room temperature, then with biotin anti-rabbit and anti-mouse secondary antibodies, and finally with streptavidin-peroxidase. The antigen-antibody binding sites were identified by AEC chromogen. Sections were counterstained with Mayer's haematoxylin, and slides visualized by light microscopy. Specific positive controls were used: skin tissue for cytokeratin, fibrosarcoma for vimentin, adrenal gland for chromogranin, brain cortex for NSE, and spinal cord for synaptophysin and GFAP. The tumor had diffuse strong cytoplasmic immunostaining to anti-chromogranin, anti-synaptophysin, anti-vimentin and anti-NSE while anti-GFAP showed only multifocal small linear streaks among neoplastic cells, interpreted as cytoplasmic processes of sustentacular cells; the tumor was negative to anti-cytokeratin (Fig. 4).

Final and overall considerations of gross and microscopic lesions, and immunohistochemistry reactions led to the diagnosis of a well differentiated ocular extra-adrenal paraganglioma.

Discussion

In our report we describe the clinical and anatomopathological features of primary orbital paraganglioma from a 15-year-old mare. Extra-adrenal paragangliomas are only occasionally found in animal species, most commonly in dogs, and usually form in the mediastinal and retroperitoneal regions (8). Paragangliomas' growth in the orbital region appears to be a feature of the horse species. To date, a few cases of orbital paraganglioma in horses have been reported, presenting non painful progressive exophthalmia as the most important and common clinical sign (1, 2, 6). This tumor has been described in literature as a non-metastasizing and non-secreting tumor. Therefore, clinical signs leading, in severe cases, to unfavorable prognosis have been a function of tumor location (in connection with the brain, sinuses, airways, and surrounding bones) and infiltrative behavior. In previously described cases, exenteration surgery was performed and a good proportion of patients survived the procedure continuing to live a normal life afterwards. When the medical condition was of

Braz J Vet Pathol, 2019, 12(2), 53 – 57
DOI: 10.24070/bjvp.1983-0246.v12i2p53-57

poorest prognosis, the affected animals were euthanized immediately post-surgery after owner's request. In our case, clinical evaluations revealed right orbit and surrounding tissues heavily compromised by severe tumor infiltration, and, despite the absence of metastases, prognosis was considered poor, leading to euthanasia request by the owner.

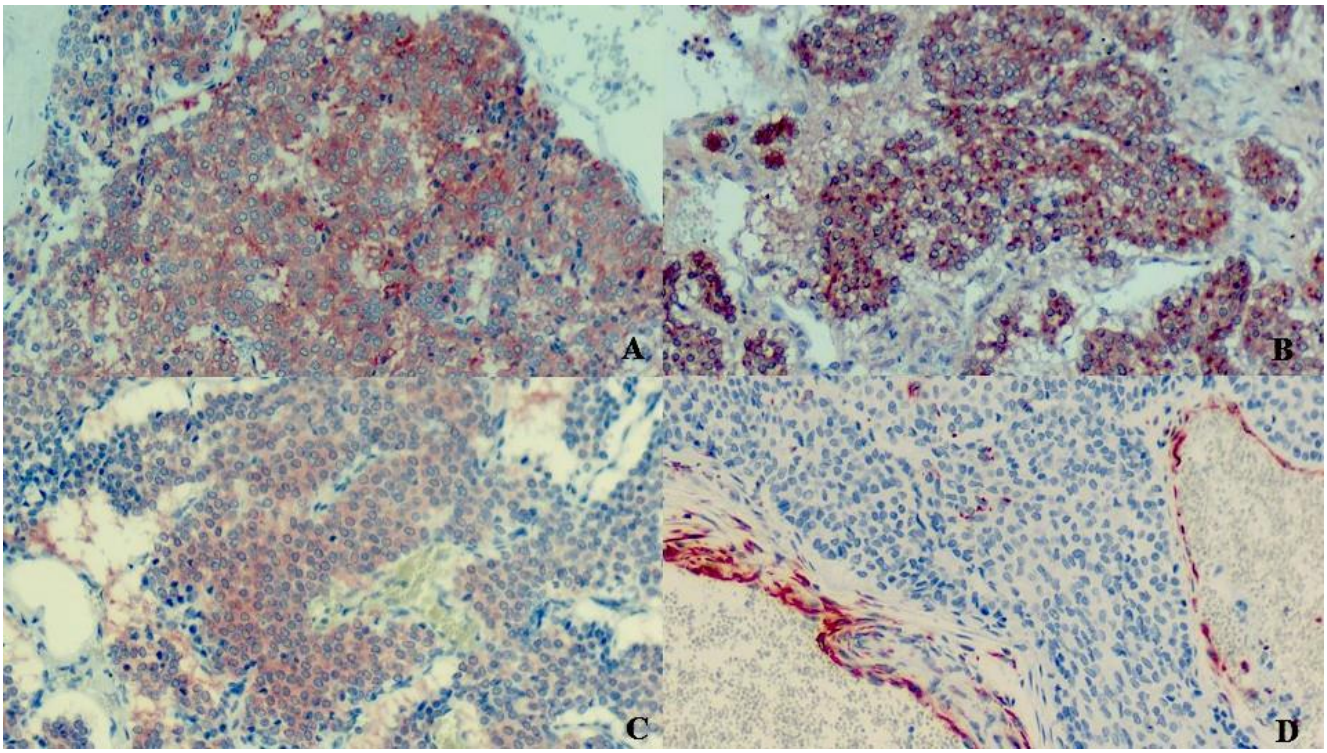

Figure 4. Immunohistochemical features of paraganglioma by use of several antigens. **A.** Anti-Synaptophysin. **B.** Anti-Chromogranin. **C.** Anti-NSE. **D.** Anti-Vimentin stain. A, B and C figures show diffuse strong cytoplasmic immunostaining, while anti-vimentin stain is focal and strongly positive, highlighting fibrovascular connective cells (stroma). Immunoperoxidase 200x.

The definitive diagnosis of paraganglioma cannot be reached without support from histopathology and immunostaining diagnostics. The WHO histological descriptions for human and domestic animals paraganliomas define this neuroendocrine neoplasm as benign, encapsulated, made of neuronal chief cells organized in compact nests (Zellballen) and surrounded by sustentacular cells, featured with a fine capillary network, and displaying rare mitoses (3, 5). In this case, we overall found no exception to the classical histopathology description with the exception that the tumor we examined had only focal encapsulation with distinct infiltrative behavior. The IHC tests that were performed significantly aided in making the final and definitive diagnosis. On immunohistochemistry the tumor was intensely positive to NSE, Chromogranin, Synaptophysin, and Vimentin, multifocally positive to GFAP in scattered fashion, and negative to Cytokeratin. NSE, Chromogranin, and Synaptophysin are biomarkers expressed by the neuroendocrine chief cells, and the combined testing for the three antigens allows for the most confident diagnosis of paraganglioma (4). NSE use has 100% sensitivity but low specificity for paraganglioma detection, as the antigen can be found also in other types of tissues, and irrespective of the degree of tumor differentiation. Chromogranin use, instead, has the highest specificity for neuroendocrine cells but may perform with low sensitivity when the tissue is undergoing malignant progression: the marker is located in the granules of the cytoplasm, and poorly differentiated tumors tend to express limited to no granulation, consequently yielding negative results. Synaptophysin is an antigen specifically found in tumors of neuroendocrine tissues and its expression is independent of the stage of tumor differentiation. Therefore, its immunohistochemistry stain holds the highest sensitivity and the highest specificity for paraganglioma diagnosis. GFAP is a biomarker expressed by the sustentacular cells of neuronal neuroendocrine tissue, and its expression decreases with progression towards malignancy until becoming completely absent in high grade malignant tumors. GFAP is therefore useful in neuroendocrine neoplasms diagnosis and in tumor differentiation assessment. The tissue we examined by GFAP was multifocally positive, consistent with the finding of a well differentiated tumor. Positive IHC reaction to vimentin highlighted the paraganglioma's fibrovascular network distribution and confirmed

accordance to the classical description of paragangliomas that includes the presence of a supporting connective tissue. Finally, the negative reaction to cytokeratin allowed differential diagnosis from neuroendocrine carcinomas which often result positive to cytokeratin biomarkers (9, 10).

In conclusion, we described a primary orbital paraganglioma in an adult mare. Clinical and anatomopathological morphologic and immunohistochemistry evaluations revealed that the tumor was per se slow-growing, well differentiated but infiltrative. Poor prognosis and final decision for euthanasia was determined by the extent of tumor invasion into vital surrounding tissues and the extent of related damages. Early detection and early surgery by exenteration may be warranted in similar medical situations to grant the animal's survival.

References

1. Basher AW, Severin GA, Chavkin MJ, Frank AA. Orbital neuroendocrine tumors in three horses. J Am Vet Med Assoc. 1997;210(5):668-71.
2. Goodhead AD, Venter IJ, Nesbit JW. Retrobulbar Extra-Adrenal Paraganglioma in a Horse and its Surgical Removal by Orbitotomy. Vet Comp Ophthalmol. 1997;7(2):96-100.
3. Kiupel M, Capen C, Miller M, Smedley R. Histological Classification of Tumors of the Endocrine System of Domestic Animals. Second Series Volume XII. Washington DC: Armed Forces Institute of Pathology; 2008. p. 64-9.
4. Kliewer KE, Cochran AJ. A review of the histology, ultrastructure, immunohistology, and molecular biology of extra-adrenal paragangliomas. Arch Pathol Lab Med. 1989;113(11):1209-18.
5. Louis DN, Ohgaki H, Wiestler OD, Cavenee WK, Ellison DW, Figarella-Branger D, Perry A, Reifenberger G, von Deimling A. Paraganglioma. In: Louis DN, Ohgaki H, Wiestler OD, Cavenee WK, editors. WHO Classification of Tumours of the Central Nervous System. International Agency for Research on Cancer (IARC); 2016. p. 164-7.
6. Miesner T, Wilkie D, Gemensky-Metzler A, Weisbrode S, Colitz C. Extra-adrenal paraganglioma of the equine orbit: six cases. Vet Ophthalmol. 2009;12(4):263-8.
7. Rosol TJ, Grone A. Endocrine Glands. In: Maxie MG, editor. Jubb, Kennedy & Palmer's Pathology of Domestic Animals. St. Louis: Elsevier; 2016. p. 348-56.
8. Rosol TJ, Meuten DJ. Tumors of the Endocrine Glands. In: Meuten DJ, editor. Tumors in Domestic Animals. 5th ed. Ames: Wiley Blackwell; 2017. p. 832-3.
9. Sako T, Shimoyama Y, Akihara Y, Ohmachi T, Yamashita K, Kadosawa T, Nakade T, Uchida E, Okamoto M, Hirayama K, Taniyama H. Neuroendocrine carcinoma in the nasal cavity of ten dogs. J Comp Pathol. 2005;133(2-3):155-63.
10. Wilson DW. Tumors of the Respiratory Tract. In: Meuten DJ, editor. Tumors in Domestic Animals. 5th ed. Ames: Wiley Blackwell; 2017. p. 473.