Braz J Vet Pathol, 2019, 12(2), 63 -68
DOI: 10.24070/bjvp.1983-0246.v12i2p63-68

BJVP
Brazilian Journal of Veterinary Pathology
ISSN 1983-0246

Case Report

Cardiac fibroelastosis associated with thromboembolism and paresis in a cat - Case report

Thaynara P. Carvalho[1], Ayisa R. Oliveira[1], Mirtha S. Duarte[1], Lucas A. Rezende[1], Maira S. Oliveira[1], Beatriz N. T. Ribeiro[1], Amanda M. S. Reis[2], Rogéria Serakides[1], Natália M. Ocarino[1*]

[1]Departamento de Clínica e Cirurgia, Escola de Veterinária, Universidade Federal de Minas Gerais, Belo Horizonte, Brazil.
[2]Departamento de Morfologia, Instituto de Ciências Biológicas, Universidade Federal de Minas Gerais, Belo Horizonte, Brazil.
***Corresponding author:** PhD, Msc. Professor at *Departamento de Clínica e Cirurgia* – Veterinary school of *Universidade Federal de Minas Gerais*. E-mail: nataliaocarino@gmail.com. Full mailing address: Departamento de Clínica e Cirurgia Veterinária, Escola de Veterinária, Universidade Federal de Minas Gerais, Av. Presidente Antônio Carlos, 6627 – CEP 30161-970, Belo Horizonte, MG, Brazil. Phone: 55(31) 3409-2229

Submitted March, 8th 2019, Accepted June, 4th 2019

Abstract

A two-year-old, male, non-castrated cat was referred to the veterinary hospital with a three-month history of paresis of the pelvic limbs. Clinical examination revealed a discreet muffling of cardiac sounds and the presence of a degree III/VI holosystolic murmur. The animal was hospitalized and died of cardiorespiratory arrest. The heart had a thickened left ventricular endocardium characterized by the deposition of a fibrous white matter that was firmly adhered to the endocardium and also observed on the epicardium. Renal infarctions and thrombi in the atrium and bifurcation of the aorta were found. Microscopically, in the endocardium of the left ventricular chamber there was a diffuse and disorganized deposition of fibrous connective tissue filled with elastic fibers of varying thickness. In the left ventricular epicardium, the same lesion was observed, but with less extension. Clinical and anatomopathological findings were consistent with primary left ventricular endocardial and left ventricular epicardial fibroelastosis with secondary left ventricular congestive heart failure, thromboembolism and paresis.

Key words: cardiology, heart, feline, fibroelastosis, thrombosis.

Introduction

Primary endocardial fibroelastosis (EFE) is a congenital heart disease of unknown origin that affects humans and animals and is characterized by the deposition of collagen fibers and elastic fibers, mainly in the endocardium, resulting in the thickening of the endocardium and consequent ventricular hypertrophy and atrial dilatation (19). When secondary, EFE occurs in response to various cardiac diseases such as endocarditis and viral myocarditis (13, 15), left hypoplastic heart syndrome (13, 14) and autoimmune reactions (1). Endocardial fibroelastosis should be differentiated from fibroelastoma, which is a benign primary cardiac tumor of the heart valves or adjacent endocardium, reported in humans as the cause of valve flux obstruction (9).

Macroscopically, fibroelastosis is characterized by a diffuse opaque and whitish endocardial thickening predominantly in the left ventricle (13, 18). In humans, fibroelastosis can lead to hemiplegia, paresis and seizures secondary to thromboembolism (7). However, these signs and lesions had not been described in animals with cardiac fibroelastosis.

Among domestic animals, the cat is the main species affected, and endocardial fibroelastosis is most frequently observed in Siamese and Burmese breeds (19, 25). Compared to other heart defects, fibroelastosis has a relatively low occurrence. In a study of 162 cats with congenital defects, fibroelastosis was diagnosed in only one animal (21).

This lesion has also been described in tigers (11), calves (8), horses (2), dogs (16) and experimentally reproduced in rats (6). However, none of these reported

Braz J Vet Pathol, 2019, 12(2), 63 -68
DOI: 10.24070/bjvp.1983-0246.v12i2p63-68

cases has described its association with thromboembolism, with a clinical picture of paresis, as has already been described in humans (7). This paper aims to report a case of cardiac fibroelastosis associated with aortic and atrial thromboembolism with consequent paresis in a common cat.

Case report

A two-year-old, male, non-castrated cat was referred to the veterinary hospital with a three-month history of paresis of the pelvic limbs. Since it presented aggressive behavior, the cat was sedated with dexmedetomidine and propofol in order for a proper clinical evaluation and complementary exams to be performed.

During the physical exam, the main changes observed were a discreet stifling of cardiac sounds and a grade III/VI holosystolic murmur with a greater intensive point in mitral focus; palpation of the femoral artery (bilateral) demonstrated the absence of pulse and reduced temperature at the extremities of the pelvic limbs.

After measuring all of the alterations, myocardial disease with cardiomegaly and thrombosis was suspected; therefore, an echocardiographic Doppler exam was performed under sedation.

The equipment used was an Esaote MyLab 40 Vet, with a multifrequency sector transducer (4 to 7.5 MHz) and the images were taken as recommended for the species (16). The results are shown in table 1.

Table 1. Echocardiographic variables obtained from a two-year-old common cat with left heart fibroelastosis and thromboembolism.

Variables*	Values**	Normal Reference interval***
LA/Ao	3.6	< 1.4
VSd (mm)	9.3	3.2 – 5.3
VSs (mm)	8.3	4.6 – 8.7
LVd (mm)	12.1	9.7 – 19.4
LVs (mm)	8.6	4.5 – 11.2
LVWd (mm)	9.6	3.2 – 5.3
LVWs (mm)	11.5	5.2 – 9.0
Mitral valve regurgitation flow (m/s)	3.1	-

*LA/Ao: left atrium to aorta ratio in short-axis view; VSd: ventricular septum at diastole; VSs: ventricular septum at systole; LVd: left ventricle at diastole; LVs: left ventricle at systole; LVWd: left ventricular wall at diastole; LVWs: left ventricular wall at systole. **Mean of three measurements. ***(10).

The observed changes included a serious left atrial dilatation with a smoke-like echo, serious thickening of the interventricular septum and posterior wall of the left ventricle and a small amount of pericardial effusion (Fig. 1).

The animal was admitted to the clinic and died of cardiorespiratory arrest one hour after the exams. The animal was then referred to the veterinary pathology sector of the same institution for a necropsy exam.

At necropsy the animal had good body condition and the visible mucosas were moderately cyanotic. In the heart evaluation, moderate hydropericardium (10 mL) was noted. In the left ventricle epicardium, there were multifocal areas with coalescent hemorrhages that deepened into the myocardium and two focally extensive areas with a deposit of a firmly attached fibrous white matter (Fig. 2A). During the necropsy, it was noted that the walls of the left ventricle were moderately thickened with a reduction of the cardiac chamber. The endocardium was diffusely thickened with a smooth whitish and glossy surface (Fig. 2B).

The left atrium had a dilated chamber with a yellowish, friable material adhered to the endothelium of the atrium (thrombus). In the abdominal aorta, near the bifurcation with the iliac arteries, there was a material with the same characteristics described in the atrium filling the entire lumen of the vessel (thrombus-plunger) (Fig. 3A). In addition, infarctions were observed in the kidneys (Fig. 3B) and heart.

Intense congestion and pulmonary edema were also observed, with moderate congestive splenomegaly and petechiae in the thymus and pancreas. Fragments of all abdominal and thoracic organs were collected and fixed in 10% buffered formaldehyde solution for 24 hours. Subsequently, the material was submitted to routine histological processing, stained with hematoxylin and eosin (HE) and evaluated by optical microscopy.

Microscopically, in the endocardium of the left ventricular chamber there was a diffuse and disorganized deposition of fibrous connective tissue with a thickness varying from 20 to 400 μm (Fig. 4). Verhoeff and Masson trichrome staining confirmed that this fibrillar material consisted of elastic and collagen fibers, respectively (Fig. 4). Found in the epicardium were multifocal areas with characteristics similar with those observed in the endocardium but associated with neovascularization and hypertrophy of the mesothelial epithelium. In the myocardium there were multifocal areas of intense

Braz J Vet Pathol, 2019, 12(2), 63 -68
DOI: 10.24070/bjvp.1983-0246.v12i2p63-68

hemorrhage and infarction. In the kidney, there were also multiple infarctions with vascular thrombi.

The clinical and pathological findings were consistent with left ventricular primary endocardial and epicardial fibroelastosis with secondary congestive heart failure, thromboembolism and paresis.

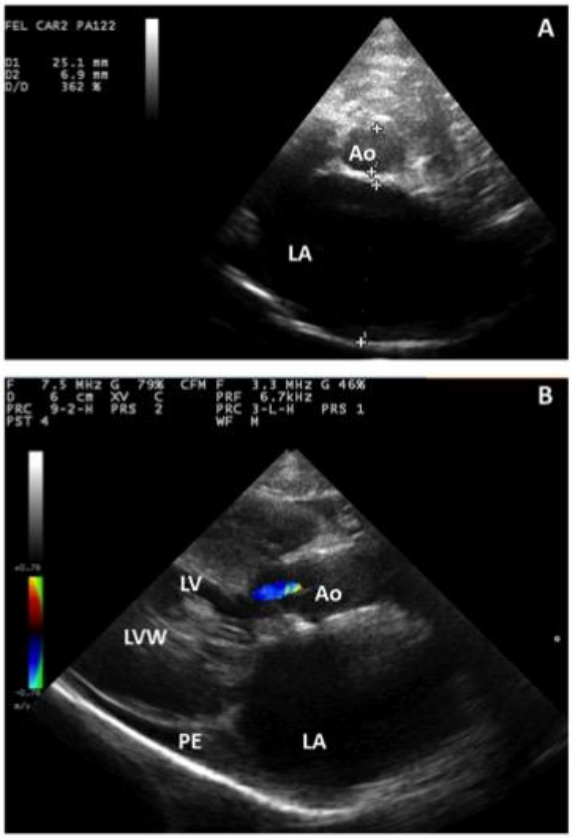

Figure 1. Echocardiography images of male two-year-old cat with limb paresis. **A.** Right short-axis view showing the severe left atrial dilation (LA/Ao 3.62). **B.** Right long-axis view showing the hypertrophic left ventricular wall and pericardial effusion. LA: left atrium; Ao: aorta; LV: left ventricle; LVW: left ventricular wall; PE: pericardial effusion.

Discussion

Taking the clinical signals of paresis of the hind limbs, cold extremities, and the absence of a femoral pulse, it was suspected that thromboembolism was due to heart disease with left atrial dilatation, hence the necessary available echodopplercardiography (3).

The accomplishment of this test, which had to be carried out with animal sedation, provided adequate two-dimensional images for the correct evaluation of the cardiac chambers and ventricular myocardium thickness, but it made it impossible to evaluate the cardiac function and limited the study of the valvular flows due to the influence of the drugs used for sedation, which reduced the heart rate (4, 23).

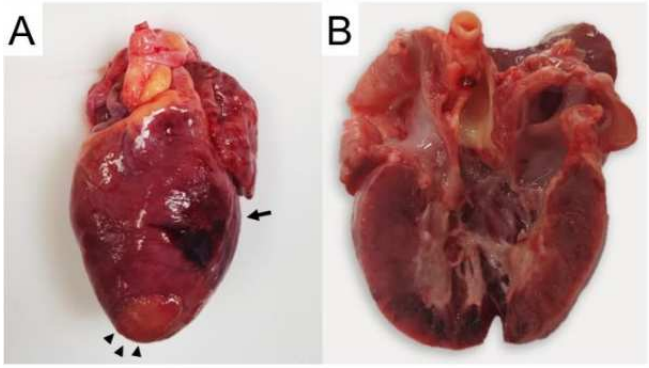

Figure 2. Macroscopic images of the heart of a cat. **A.** Multifocal areas with bleeding coalescence and the deposit of focally extensive white matter (arrow and arrowhead). **B.** Longitudinal cut of the heart with the deposition of white matter in the endocardium and myocardium.

The findings of severe dilation of the left atrium have been reported in other cases of EFE in animals (2, 8, 11). The dilatation and smoke-like signal in their interior suggest blood stasis and what predisposes the formation of thrombus (10). The phenomenon of embolism is a secondary signal of cardiac decompensation and detachment of the endocardium mural thrombi (7). The clinical signal that the cat presented suggested a thromboembolism and was the reason for the medical appointment, but the vascular ultrasound was not done because the cat was unstable at the end of the exam. Stabilizing the cat was chosen in order to perform new exams; however, the cat died before the new tests could be performed.

In addition, during the necropsy hemorrhagic foci in multiples organs such as the kidney, bladder, thymus, heart, pancreas and lung were observed. These hemorrhages may occur due thrombosis, secondary to EFE, and thus causing activation of coagulation factors (12). Hemorrhages may also be associated with cardiovascular changes in EFE.

The echocardiographic examination showed mitral valve systolic reflux, justifying the presence of the murmur, and pericardial effusion, causing the suffocation of the cardiac sounds. Overall, echocardiographic findings closely resembled late-stage hypertrophic cardiomyopathy, with severe alterations in concentric left ventricular hypertrophy, atrial dilatation, smoke signal, and pericardial effusion (5). However, it was unexpected to find such a clinically advanced situation of hypertrophic cardiomyopathy in an animal less than two years old. In this age group, the most plausible diagnosis would be congenital heart disease with the most common being ventricular septal defect and tricuspid valve dysplasia (17), but the echocardiographic findings did not suggest these diseases. Thus, among the congenital heart diseases, the

Braz J Vet Pathol, 2019, 12(2), 63 -68
DOI: 10.24070/bjvp.1983-0246.v12i2p63-68

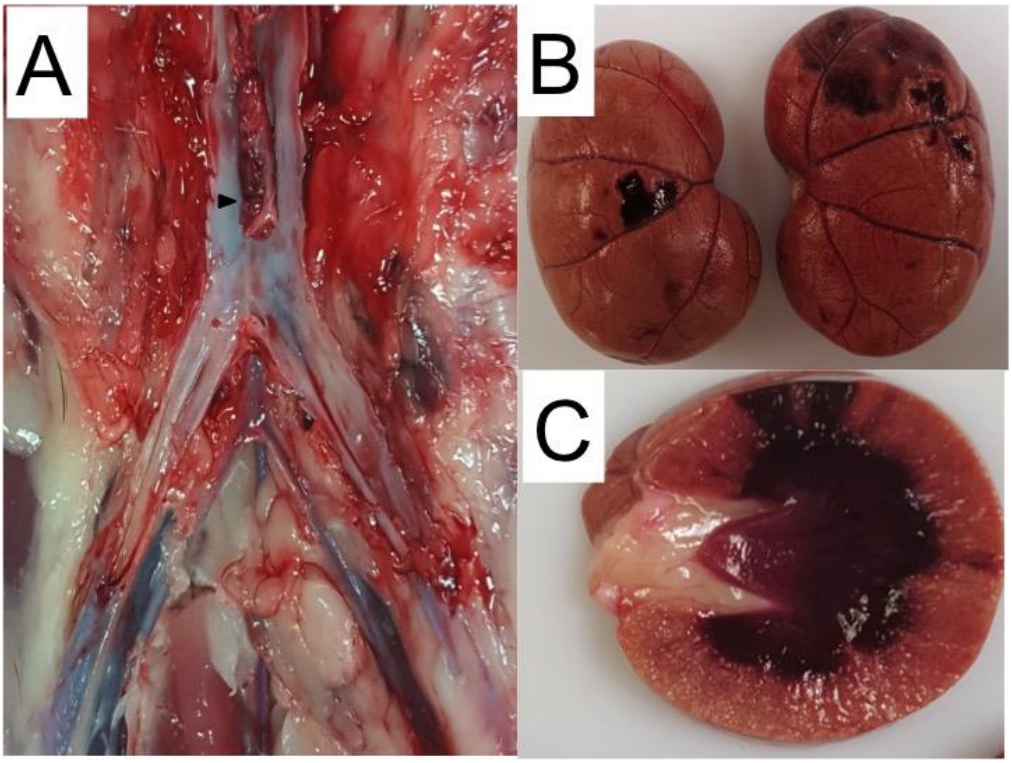

Figure 3. Images of the aorta and kidney artery showing thrombi and infarction, respectively, in a two-year-old cat with a history of paresis of the hind limbs. **A.** Aorta at the height of the iliac bifurcation with presence of opaque, irregular material, with adherence to the vessel (tip of the arrow). **B.** Kidney macroscopy with multifocal areas of wedge-shaped renal infarct (in "c").

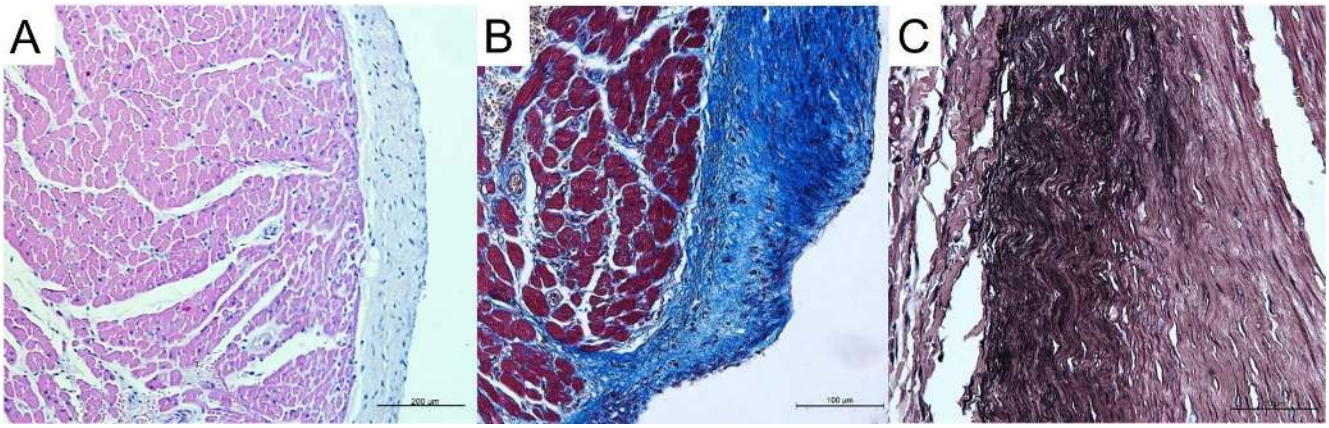

Figure 4. Histological images of the endocardium of the left ventricular chamber of the heart of a cat. **A.** Diffuse deposition of collagen fibers over the endocardium. Hematoxylin-eosin, 10x. **B.** Deposition of disorganized collagen fibers of variable thickness over the endocardium. Masson's trichrome, 20x. **C.** Disorganized and variable thickness deposition of collagen fibers stained in pink and elastic fibers stained black over the endocardium. Verhoeff, 40x.

main clinical diagnosis is usually fibroelastosis. In this case, the diagnosis is usually suspect, because its histopathological confirmation is rarely achieved in routine examinations, given the sentimental appeal of owners who are reluctant to allow a necropsy exam for their animals. Likewise, the diagnosis is, most of the time, reached by the exclusion of other congenital heart diseases and the more frequent myocardial diseases.

Information on the occurrence of endocardial fibroelastosis is contradictory. Some literature showed a low incidence in cats (17), while others presented it as a frequent lesion in the same specie (25). In general, there are few reports of fibroelastosis in veterinary medicine and to authors' knowledge it appears to be the first report of fibroelastosis associated with thromboembolism and paresis in cats. The patient in question died during hospitalization, making it impossible to perform adequate

treatments for heart failure and the prevention of thrombus formation with use of, among others, beta-blockers, diuretics and platelet aggregation inhibitors (3).

In humans, primary EFE is described as a familiar condition (25). In cats, it is believed that in some less severe forms of the lesion with few clinical signs, the affected animals may be able to reach the reproductive stage and transmit this condition to future litters (25). Despite being a condition associated with Siamese and Burmese breeds, (20) describes cases of EFS in four common cats of the United Kingdom. In the present report, the cat was not purebred but there is no information about the parents' origin.

It is believed that EFE is an underdiagnosed heart disease (25). Lesions are limited to the heart, while secondary heart failure can be observed. The lesion is progressive and begins with endocardial edema and the dilatation of lymphatic vessels, which predisposes the synthesis of collagen fibers and elastic fibers (20, 25). The older fibers will organize and form a thick, opaque layer, while the new fibers are deposited on the surface (25). This endocardial fibrosis progressively involves cardiac conductive fibers, such as Purkinje fibers, resulting in degenerative changes (19, 25). This change is observed microscopically only in animals younger than two months of age (20, 25), justifying their absence in this case.

The primary lesion is usually restricted to the endocardium and it is hypothesized that the fibroblasts that synthesize collagen and elastic fibers originate from endocardial endothelial cells via aberrant endothelial-mesenchymal transition (22). However, more recently it was identified in a murine experimental model that most of the fibroblasts are derived from the embryonic epicardium instead of the embryonic endocardium (24), justifying the presence of this alteration in multiple foci of the epicardium of the animal in this study.

References

1. Aoki H, Inamura N, Kawazu Y, Nakaiama M, Kayatani F. Fetal echocardiographic assessment of endocardial fibroelastosis in maternal anti-SSA antibody-associated complete heart block. Circulation J. 2011;75(5):1215-21.
2. Belgrave RL, Hines MT, Lahmers KK, Selon DC, Tobias AH. Case Report Endocardial fibroelastosis in a Thoroughbred foal. Equine Vet Educ. 2002;14(2): 77-82.
3. Boon JA, Vet. Echocardio. 2nd ed. Oxford, UK: Wiley-Blackwell; 2011. 767p.
4. Chetboul V, Sampedrano CC, Tissier R, Gouni V, Saponaro V, Nicolle AP, Pouchelon JL. Quantitative assessment of velocities of the annulus of the left atrioventricular valve and left ventricular free wall in healthy cats by use of two-dimensional color tissue Doppler imaging. Am J Vet Res. 2006;67:250-8.
5. Dahlback B. Blood coagulation. Lancet. 2000;355:1627-32.
6. Friehs I, Illigens B, Melnychenko I, Zhong-Hu T, Zeisberg E, Del Nido PJ. An animal model of endocardial fibroelastosis. The J Surgil Res. 2013,182:94-100.
7. George L, Branch MD, Robert F, Castle MD. Thromboembolic complications in primary endocardia fibroelastosis. The J Pediatr. 1966;6(2):250-8.
8. Gopal T, Leipold HW, Dennis SM. Congenital cardiac defects in calves. Ame J of Vet Research. 1986;47(5):1120-1.
9. Grinda JM, Couetil JP, Chauvaud S, D'Attellis N, Berrebi A, Fabiani JN, Deloche A, Carpentier A. Cardiac valve papillary fibroelastoma: surgical excision for revealed or potential embolisation. J Thorac Cardiovasc Surg. 1999;117:106-10.
10. Hogan DF. Feline cardiogenic arterial thromboembolism: prevention and therapy. Vet Clin North Am Small Animal Pract. 2017;7(5):1065-82.
11. Kiira T, Rodriguez J, Andrew C,Cushing BVS, Berna,CE, Ramsay CD, Craig LE, Gompf RE. Endocardial fibroelastosis in two related tiger cubs (*Panthera tigris*). J Vet Cardiol. 2017;20(1):73-77.
12. Lee SH, Na S, Kim N, Ban MG, Shin SE, Oh YJ. The effects of dexmedetomidine on myocardial function assessed by tissue Doppler echocardiography during general anesthesia in patients with diastolic dysfunction: a CONSORT-prospective, randomized, controlled trial. Medicine (Baltimore). 2016;95(6):e2805.
13. Lurie PR. Changing concepts of endocardial fibroelastosis. Cardiol Young. 2010;20:115-23.
14. McElhinney DB, Vogel M, Benson CB, Marshall AC, Wilkins-Haug LE, Silva V, Tworetzky W. Assessment of left ventricular endocardial fibroelastosis in fetuses with aortic stenosis and evolving hypoplastic left heart syndrome. Am J Cardiol. 2010;106:1792-7.
15. Ni J, Bowles NE, Kim YH, Demmler G, Kearney D, Brincker JT, Towbin JA.Viral infection of the myocardium in endocardial fibroelastosis. Molecular evidence for the role of mumps virus as an etiologic agent. Circulation. 1997;95(1):133-9.
16. Patterson DF. Canine congenital heart disease: epidemiology and etiological hypotheses. J Small Anim Pract. 1971;12(5):263-87.
17. Payne JR, Borgeat K, Connolly DJ, Boswood A, Dennis S, Wagner T, Menaut P, Maerz I, Evans D, Simons VE, Brodbelt DC, Fuentes VL. Prognostic indicators in cats with hypertrophic cardiomyopathy. J Vet Intern Med. 2013;27(6):1427-36.
18. Perloff JK, Marelli AJ. Clinical Recognition of Congenital Heart Disease. 6th ed. Philadelphia, PA: Elvesier Saunders. Endocardial Fibroelastosis. 2012;p.141-6.

Braz J Vet Pathol, 2019, 12(2), 63 -68
DOI: 10.24070/bjvp.1983-0246.v12i2p63-68

19. Robinson WF, Robinson NA. Cardiovascular System. In: Jubb, K., Kennedy, P., Palmer, N. Pathology of domestic animals. 6th ed. St. Louis, Missouri:Elsevier. 2016; vol. 3. p.572.
20. Rozengurt N. Endocardial fibroelastosis in common domestic cats in the UK. J Comp Pathol. 1994;110:295-301.
21. Tidholm A, Ljungvall I, Michal J, Haggstrom J, Hoglund K. Congenital heart defects in cats: a retrospective study of 162 cats (1996-2013). J Vet Cardiol. 2015;17(1):215-19.
22. Xu X, Friehs I, Zhong Hu T, Melnychenko I, Tampe B, Alnour F,Lascone M, Kalluri R, Zeisberg M, Del Nido PJ, Zeisberg EZ. Endocardial fibroelastosis is caused by aberrant endothelial to mesenchymal transition. Circulation Res. 2015:116(5):116:857-66.
23. Ward JL, Schober KE, Fuentes VL, Bonagura JD. Effects of sedation on echocardiographic variables of left atrial and left ventricular function in healthy cats. J Feline Med Surg. 2012;14(10):678-85.
24. Zhang H, Huang X, Liu K, Li Y, Tian X, Wang Y, Zhang L, Yu Y, Wang H, Hu R, Wang F, Chen T, Wang QC, Quiao Z, Zhang L, Zhou B. Fibroblasts in an endocardial fibroelastosis disease model mainly originate from mesenchymal derivatives of epicardium. Cell Res. 2017:27(9):1-21.
25. Zook BC, Paasch LH. Endocardial fibroelastosis in Burmese cats. Am J Pathol. 1982:106:435-8.