BJVP
Brazilian Journal of Veterinary Pathology

Case report

Platynosomum fastosum infection in two cats in Belo Horizonte, Minas Gerais State – Brazil.

Ana L. S. Vieira[1], Roselene Ecco[1], Walter S. Lima[2], Roberto M. C. Guedes[1*]

[1]Departamento de Clínica e Cirurgia, Escola de Veterinária, UFMG - Universidade Federal de Minas Gerais, Belo Horizonte, MG, Brazil.
[2]Departamento de Parasitologia, Instituto de Ciências Biológicas, UFMG.
***Corresponding author:** Roberto M. C. Guedes. Departamento de Clínica e Cirurgia, Escola de Veterinária, Universidade Federal de Minas Gerais. Av. Antônio Carlos, 6627. Pampulha. Belo Horizonte, MG, CEP 31270-901 – Brazil. E-mail: guedes@vet.ufmg.br

Submitted November 16th 2009, Accepted February 19th 2009

Abstract

This report describes two cases of cat infection by *Platynosomum fastosum* in the city of Belo Horizonte, Minas Gerais, Brazil. In case 1, a female shorthair presented at necropsy high infestation by this fluke and had macroscopic and microscopic lesions related to *P. fastosum*. In case 2, a female shorthair was submitted to necropsy and did not show significant lesions. At Histopathological exam of liver there were a few biliary ducts with flukes with the same characteristics of case 1. In both cases, the diagnosis of *P. fastosum* was based on morphology of this fluke at histology exam. Additionally , in case 1 a parasitological analysis was performed . To authors knowledge this is the first report of *P. fastosum* in the city of Belo Horizonte and emphasizes the importance of considering this agent in the differentials related to cholangitis in cats.

Key Words: Cholangiohepatitis, *Platynosomum fastosum*, cat.

Introduction

Platynosomum fastosum, also known as (syn.) *Platynosomum concinnun* (1), is a feline (domestic and wild cats) liver fluke associate with cholangitis and cholangiohepatitis in this species (3). *P. fastosum* has been reported in many countries, such as Bahamas (5), Malaysia (9) Nigeria (4), United States (3,7), British Guiana , Brazil and Puerto Rico (1). In Brazil, it was reported in the states of São Paulo (8,13), Bahia (11), Rio de Janeiro (10), Amazon (12) and Minas Gerais state (6).

P. fastosum is a common fluke of cats and its prevalence in Rio de Janeiro (45%) and São Paulo (5%) has been studied (10). There is only one report of its occurrence in the state of Minas Gerais, in Uberlândia (6). The objective of this report is to describe two cases of cat infection by *P. fastosum* presented in the Veterinary Hospital (UMFG) of the Universidade Federal de Minas Gerais in the city of Belo Horizonte, state of Minas Gerais - Brazil.

Case 1

An adult female shorthair cat was submitted to necropsy at veterinary teaching hospital at the Universidade Federal de Minas Gerais (UFMG). No clinical information was available. Uppon necropsy, the animal was emaciated and with mild oral and ocular jaundice. The liver was slightly enlarged, yellowish, with intercalated friable and firm areas, and with evident lobular pattern. Dilated and thickned biliary ducts associated with severe catarrhal exsudate were evident on cut surface of the liver (Figure 1). The gallbladder was distended and highly infested with flukes ranging to 4 mm to 5 mm in length (figure 2). The parasites were also seen in biliary ducts. There were no significant lesions in other organs.

 All rights reserved 2007.

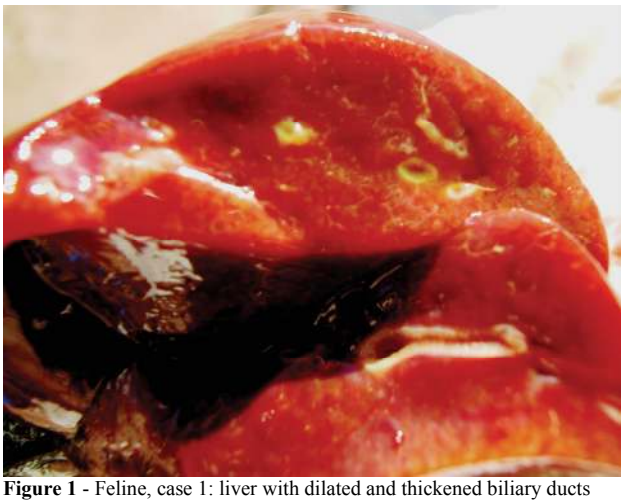

Figure 1 - Feline, case 1: liver with dilated and thickened biliary ducts associated with severe catarrhal exsudate on cut surface.

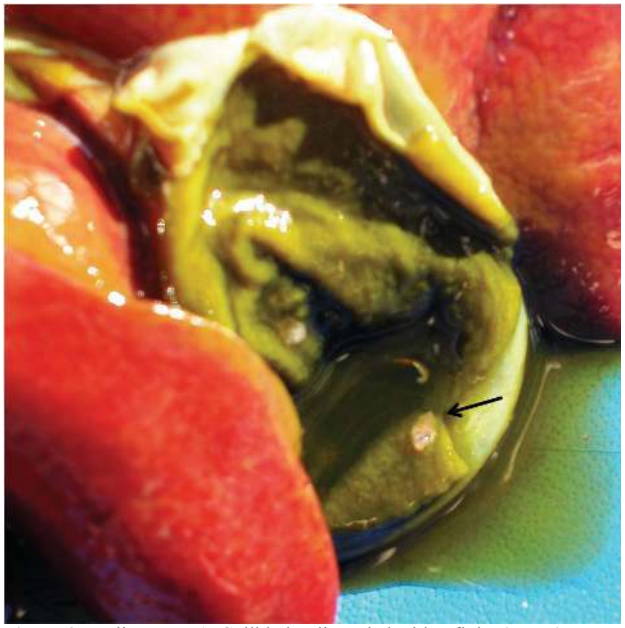

Figure 2 - Feline, case 1: Gallblader distended with a fluke (arrow).

Tissue samples were collected, fixed in 10% neutral-buffered formalin, routinely processed and embedded in paraffin. Sections of 5 µm were stained with hematoxylin and eosin. Flukes were also collected for parasitological analysis.

Histological changes were detected in the liver and characterized by intense ectasia and papillary hyperplasia and proliferation of biliary ducts surrounded by severe fibrosis (figure 3, arrow). There was mild lymphoplasmocytic infiltrate confined to the portal area. Inside affected ducts, cross-sections of adults trematodeos, characterized by a thin cuticule, no celomatic cavity, one sucker and both male and female organs, which contained operculated eggs were observed (figure 3). There were no lesions in other organs.

Parasitological analysis detected a flat parasite ranging from 4 to 8 mm in length, with eggs ranging 34 to 50 µm. The fluke had a smooth external cuticle, subterminal oral sucker, intestinal caeca not sinuous. The parasite was hermaphroditic with elongated and longitudinal paired of testes, located at the horizontal position. Ovary was transversally elongated and located behind the testes. The uterus comprehended all the posterior region of the parasite. The well-developed vittelline glands lie mainly in the lateral regions of the body (figure 4).

Based on gross, histopathological and parasitological findings the lesion was diagnosed as cholangitis, lymphoplasmocytic, chronic, with biliary hyperplasia, ectasia and fibrosis, severe, diffuse with intralesional fluke compatible with *P. fastosum*.

Case 2

A female domestic shorthair, senile cat was submitted to *post mortem* evaluation after clinical manifestation of depression, dehydrated, vomit, ocular and nasal purulent discharges and dyspneia. Hematological evaluation demonstrated mild leucopenia. No other alterations were observed in blood analysis. At necropsy, the cat was emaciated, mild icteric, anemic and had a mild pulmonary edema. The liver was diffusely yellowish with a few consistent areas. No other gross lesion was observed.

During necropsy tissue samples of liver, lungs, intestine, kidneys, heart, spleen, central nervous system and bone marrow were collected for histological evaluation. All tissue samples were processed for histological examination as described above.

Histopathological evaluation of liver revealed intense periportal and biliary periductal fibrosis, biliary ductal proliferation, moderate cholestasis, ectasia and hyperplasia of few biliary ducts that had a fluke with the same characteristics mentioned in case 1, *P. fastosum*. Spleen and kidney were histologically normal.

The biliary lesion observed in this case was an incidental finding and likely not related to the cause of death.

Discussion

P. fastosum completes its life cycle using two intermediate hosts. Miracidia are present inside eggs when these are shed in the cat feces. After embryonated eggs from cats feces are ingested by snails (*Subulina octona*), aproximately 15 miracidia emerge and migrate to the connective tissue and crop of this mollusk. During a period of 28 days, the miracidia develop to sporocysts I and multiply, generating a great number of sporocysts II, which migrate to the soil through the breathing pores of the snail (10). The sporocysts II maturate in the environment for 30 days, when they will contain many cercariae.

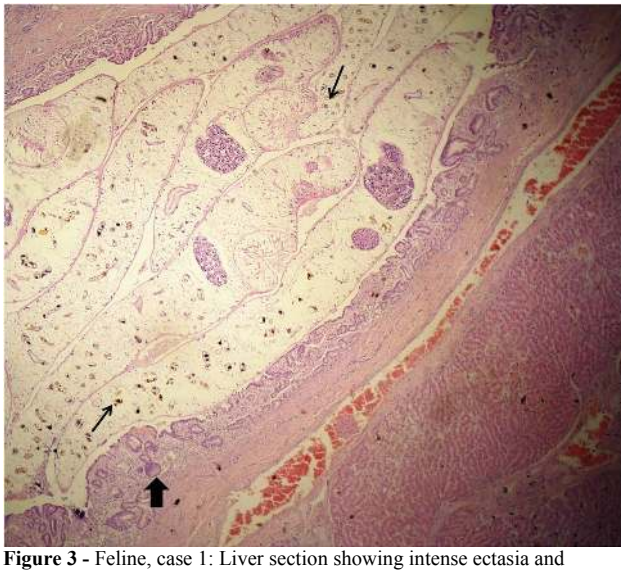

Figure 3 - Feline, case 1: Liver section showing intense ectasia and papillary hyperplasia of billiary ducts surrounded by severe fibrosis (large arrow). Inside affected ducts, cross-sections of adults trematodeos characterized by a thin cuticule, no celomatic cavity, one sucker and both male and female organs, which contained operculated eggs were observed (arrows), HE 25x

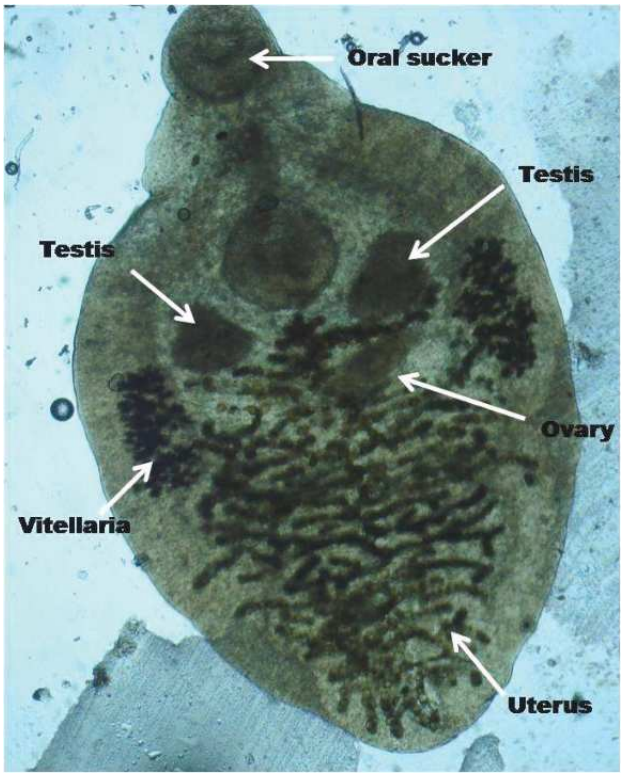

Figure 4 - *P. fastosum*: adult trematodeo characterized by a thin cuticule, no celomatic cavity, one-sucker and both male and female organs , 2,5x.

These forms of the parasite can be ingested by paratenic hosts such as bettles. Lizards, geckos, salamanders and toads, second intermediate hosts, get infected by ingesting sporocysts II from the soil or by ingesting the paratenic host. In either case, the metacercariae will be released and remain encysted in the gallbladder of the second intermediare host until being ingested by the final host (2). Cats become infected after ingestion of second intermediate hosts containing these metacercaries (2). In the cat, cercariae are released in the upper digestive tract, enter the biliary tree and complete its life cycle. After 8 to 12 weeks fluke eggs start to be shed in the feces to the environment. This cycle occurs in tropical and semitropical climates (1).

Clinical signs of cats infected by *P. fastosum* are unspecific and include emaciation, anorexia, depression, vomits, diarrhea, hepatomegaly and progressive jaundice (1). In many cases, there is no clinical disease. Clinical manifestation and severity of the disease is dependent to the fluke infestation (2). In an experimental study, all cats with mild infection (125 flukes) were assimptomatic and 60 % of cats with high number of flukes (over 1000 flukes) exhibited clinical signs (1).

Gross lesions include enlargement of the liver, which can become friable and yellowish associated to distension and thickness of biliary ducts. A catarrhal inflammation of biliary tree can be present and flukes might be seen at necropsy (12). Histologically, there are a hyperplasia and ectasia of biliary ducts with fibrosis (1). There is a report of cystic formation surrounded by fibrosis related with high infestations (13).

P. fastosum causes severe colangiohepatitis (3) only in cases of high infestation (2). The lack of accurate clinical information on both cases reported here makes difficult to correlate clinical signs, macroscopic and histological lesions. In case 1, despite the absence of any clinical information, severe fluke associated with gross and histologic hepatic lesions with no other change in different organs indicate this agent as the possible cause of death. Emaciation and jaundice detected during the necropsy could be caused by the *P. fastosum* infestation.

In case 2, neither clinical signs nor anatomopathological findings were enough to determine possible causes death. In this case, the *P. fastosum* infestation was low and lesions related to it were discrete. It has been reported that cats with low infestations do not had clinical signs (2). So it is unlikely that clinical signs were only due to *P. fastosum*, although it could contribute to worsen clinical condition of the cat. For instance, the observed cholestasis, due to possible biliary ductal stenosis, could have contributed to jaundice.

P. fastosum must be included among the differential diagnosis of cats with signs of hepatobiliary disease. Other causes of cholangiohepatitis in cats include: ascending intestinal bacterial infection, pancreatitis, protozoan from Eimeriidae family, protozoan similar to *hepatozoon canis* and toxoplasmosis (3). Diagnosis of liver fluke is made based on feces parasitological exam (11), hepatic biopsy (3) and necropsy (2).

In Brazil, the prevalence of *P. fastosum* it is known in a few states (10), but not in Minas Gerais. To the authors knowledge, this is the first report of this parasite in

the city of Belo Horizonte, but it has been already reported in Minas Gerais (6). In this report in Uberlândia, 50 cats were submitted to necropsy and 20 had *P. fastosum.* This first report of this fluke in Belo Horizonte should be an alert for the presence of this agent in the metropolitan area, thus, should be considered in the differentials related to cholangitis in cats. Prevalence studies should be conducted in order to understand the real importance of this agent.

References

1. BIELSA LM., GREINER EC. Liver flukes (*Platynossomum concinnum*) in cats. *J. Am. Hosp. Assoc.,* 1985, 21, 269-274.
2. CHUNG NY., MIYAHARA AY., CHUNG G. The prevalence of feline liver flukes in the city and county of Honolulu. *J. Am. Hosp. Assoc.,* 1977, 13, 258-262.
3. DAY DG. Feline cholangiohepatitis complex. *Vet. Clin. North. Am. Smal. Anim. Pract.,* 1995, 25, 375-385.
4. IKEDE BO., LOSOS GJ. ISOUN TT. Platynossomum concinnum infection in cats in Nigeria. *Vet. Rec*., 1971, 89, 635-638.
5. LEAM G., WALKER I.E. The occurrence of Platynossomum fastosum in domestic cats in the Bahamas. *Vet. Rec.*, 1963, 75, 46-48.
6. MUNDIN TCD., OLIVEIRA JUNIOR SD., RODRIGUES DC., CURY MC. Freqüência de helmintos em gatos de Uberlândia, Minas Gerais. *Arq. Bras. Med. Vet. Zootec.,* 2004 56, 562-563.
7. PALUMBO NE., PERRI SF., LOO BS., TAYLOR D., REECE V. Cat liver fluke, *Platynossomum concinnum*, in Hawaii. *Am. J. Vet. Res*., 1974, 35, 145.
8. RAGOZO AMA., MURANDIAN V., RAMOS E SILVA JC., CARAVIERI R. AMAJONER VR., MAGNABOSCO, C., GENNARI, SM. Ocorrência de parasitos gastrointestinais em fezes de gatos das cidades de São Paulo e Guarulhos. *Braz. J. Vet. Res. Anim. Sci*, 2002,39, 244-246.
9. RETNASABAPATHY A., PRATHAP K. The Liver fluke platynossomum fastosum in domestic cats. *Vet. Rec.*, 1971, 88, 62-65.
10. SALOMÃO M., SOUZA-DANTAS LM., MENDES-DE-ALMEIDA F., BRANCO AS., BASTOS OPM., STERMAN F., LABARTHE N. Ultrasonography in hepatobiliary evaluation of domestic cats (*felis catus,* L., 1978) infected by *Platynossomum* Looss, 1907. *Intern. J. Appl. Res. Vet. Med.*, 2005, 3, 271-279.
11. SAMPAIO MAS., BERLIM CM., ANGELIM AJGL., GONDIM LFP., ALMEIDA MAO. Infecção natural pelo *Platynossomum* Loss 1907, em gato no município de Salvador, Bahia. *Rev. Bras. Saude. Prod. An.*, 2006, 7, 01-06.
12. STALKER MJ., HAYES MA. Liver and biliary system. In: MAXIE MG. *Jubb, Kennedy and* Palmer*'s Pathology of domestic animals volume 2*. Ed. Saunders Elsevier, 2007, 297-388.
13. XAVIER FG., MORATO GS., RIGHI DA., MAIORKA PC., SPINOSA HS. Cystic liver disease related to high *Platynossomum fastosum* infection in a domestic cat. *J fel med surg*, 2006, 9, 51-53.