



Case Report

Extraosseous aneurysmal bone cyst in dogs: a report of two cases

Viviana Cubillo-Rodríguez¹, Daniel Barrantes-Murillo², Alejandro Alfaro-Alarcón^{2*}

¹Estudiante de Internado Rotatorio, Escuela de Medicina Veterinaria, Universidad Nacional de Costa Rica (UNA).

²Departamento de Patología Veterinaria, Escuela de Medicina Veterinaria, Universidad Nacional de Costa Rica (UNA).

*Corresponding author: alejandro.alfaro.alarcon@una.cr

Submitted August, 7th 2018, Accepted February, 27th 2019

Abstract

During a routine check-up in a 6-year-old intact male Labrador Retriever and a 6-year-old intact male Boxer, a mass in their pelvic cavities was found. Both dogs were clinically healthy and did not display any clinical symptoms. The masses were surgically removed and sent to a pathology laboratory for analysis. The histopathological evaluation of both lesions diagnosis was: extraosseous aneurysmal bone cysts. This report describes the macroscopic and histopathological characteristics of the cysts in both patients.

Key words: aneurysmal bone cyst, extraosseous, histopathology.

Introduction

Conventional aneurysmal bone cysts (ABCs) are benign, intra-osseous, cyst-like, osteolytic and expansive lesions that can develop in any bone in the skeletal system, but generally occur eccentrically in the metaphysis of long bones (24, 31). They may arise *de novo* (primary ABC) or can be occur secondarily in other benign or malignant bone tumors (secondary ABC). Currently, cytogenetic and molecular studies in human patients suggest that primary ABC is a neoplastic process rather than reactive lesion (14, 17).

The term aneurysmal bone cyst is only a descriptive concept not related to the etiology of the lesion. This lesion is not a true aneurysm, but it is named aneurysmal because of its blowout distension appearance, and is called cyst due to the lesion often presents as a blood-filled cavity, but it does not have an epithelial lining (4, 15).

A few cases of ABC have been reported in dogs (1, 18, 19, 20, 22, 23, 26, 27), horses (6, 9, 13, 16, 21, 28, 29), cats (4, 5, 25, 32), bulls (3, 12), and birds (7, 8). This type of lesion has been reported in the bones of the mandible (3, 6, 12, 13, 21), metatarsals (9, 16, 28),

metacarpals (8, 29), scapula (4, 31), pelvis (18, 25), humerus (20, 23, 26), tibia (22), rib (5), lumbar vertebrae (27), ulna (1), penile bone (19), carpus (7) and skull (8). Due to the infrequent occurrence and variability of the cases, it has not been possible to make predispositions about the species, sex, breed, and age of the patients.

Extraosseous ABC is a very rare lesion in humans and animals. It has the same histomorphological characteristics as its intraosseous counterpart, but it originates in soft tissue. Only 26 cases have been reported in humans (14), and one case in the veterinary medical literature, which developed in the soft tissue of the perianal region of a canine (2).

Since these lesions are so infrequent, ABCs and their extraosseous variants pose a diagnostic challenge for veterinary clinicians and pathologists. The objective of this report is the histopathological description of two cases of extraosseous aneurysmal bone cysts located in the pelvic cavity, which were discovered during a routine medical examination.

Case Report

Report on Case 1

A 6-year old cryptorchid Labrador Retriever was admitted to a private veterinary clinic to undergo an orchietomy. No symptoms were detected during the preoperative clinical evaluation. During the surgical procedure, a mass was detected in the soft tissue of the floor of the pelvic cavity, close to the prostate gland. The mass was removed, fixed in 10% formalin and sent to the Pathology Department of the Universidad Nacional de Costa Rica for histopathological study.

The mass was processed to obtain histological sections, which were stained with Hematoxylin & Eosin (H&E) following routine procedures. In addition, several sections of the mass were obtained for immunohistochemical staining. In this procedure, monoclonal mouse antibodies were used as a primary antibody to detect vimentin (M0725; 1:200, Dako).

Biotinylated anti-mouse immunoglobulin G (Dako, Code E0433) diluted in buffered saline at a concentration of 1:200 was used as a secondary antibody. Antigen recovery was performed at 97 °C (206.6 °F) using buffered sodium citrate, pH 6.0 (Dako Target Retrieval Solution, Code S1699), for 30 minutes in a water bath. The activity of the endogenous peroxidase was blocked with hydrogen peroxide for 10 minutes (Dual Endogenous Enzyme Block, Code S2003). Diaminobenzidine (Dako, Code K0679) was used as a chromogen.

Macroscopically, the dimensions of the mass were 16 x 14 x 7 cm; it was irregular, hard, and had a cyst-like appearance with superficial bone spicules 4 mm long. The cut surface presented irregular bone projections that formed multiple cavities which proliferated towards the lumen of the mass, and contained bloody fluid (Fig. 1).

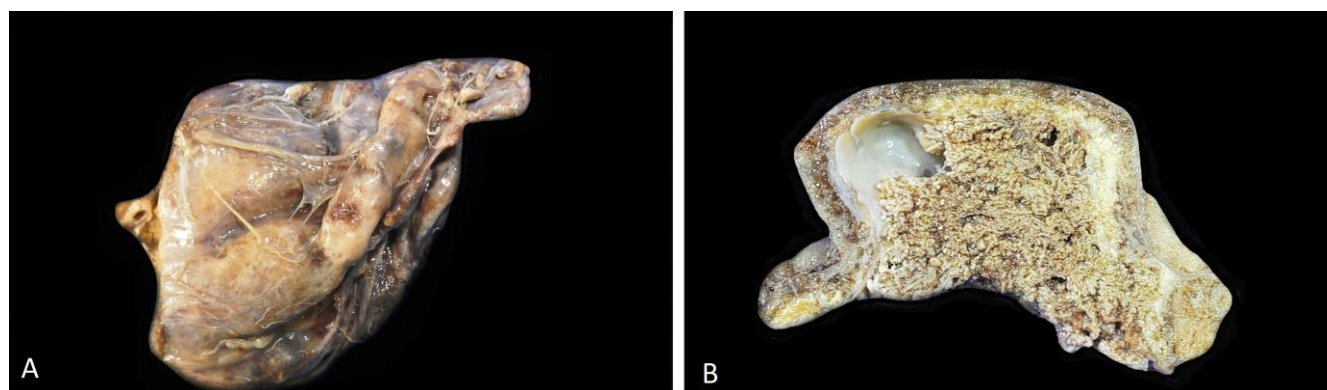

Figure 1. Gross appearance of an extrasosseous ABC in Case 1. **A.** External appearance. **B.** Cut surface. Note the bony projections that make up the cavities in the lumen of the cyst.

Histologically, cyst wall was composed of layers of fibroblast proliferation, connective tissue and reactive bone (Fig. 2A). Fibroblasts were arranged in a granular basophilic stroma (mucin matrix). The cells had oval nuclei with condensed chromatin and indistinct nucleoli. The cytoplasm was sparse, fibrillar and eosinophilic. Multifocally, there were multiple dilated blood vessels and hemosiderin-laden macrophages in the connective tissue

(Fig. 2B). Bone tissue growth in spicules and trabeculae with moderate osteoblastic activity and presence of osteoclast-type giant cells (Fig. 2C). Immunohistochemistry (IHC) revealed diffuse cytoplasmic positivity for vimentin in most connective tissue cells (Fig. 3). An extrasosseous aneurysmal bone cyst was diagnosed, based on the histopathological and immunohistochemical findings.

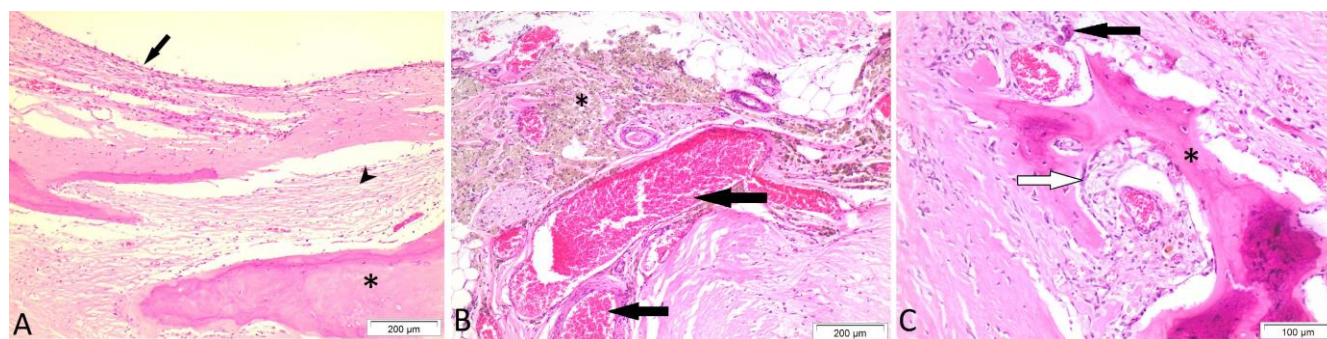


Figure 2. Histopathological appearance of the lesion in Case 1. **A.** Cyst wall was composed of layers of fibroblast proliferation (arrow), connective tissue (arrowhead) and reactive bone (asterisk). **B.** Multifocal dilation of blood vessels (arrows) surrounded by connective tissue and macrophages phagocytosing hemosiderin (asterisk). **C.** Bone spicules (asterisk) with osteoblastic activity (white arrow) and presence of osteoclasts (black arrow). H&E stain.

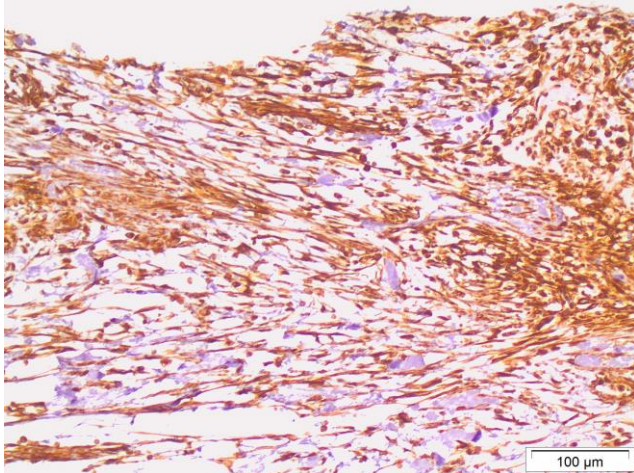


Figure 3. Immunohistochemical evaluation of an extrasosseous ABC. Strong vimentin positivity in the cytoplasm of connective tissue cells.

Report on Case 2

A 6-year-old intact male Boxer underwent a routine medical examination. An abdominal ultrasound was performed at the request of the owner, which detected a mass caudal to the urinary bladder. No other clinical abnormalities were found. The patient underwent an exploratory laparotomy in which the mass was extracted. It adhered to the floor of the pelvic cavity in association with soft tissue, without adherence to bone tissue. The mass was fixed in 10% formalin and sent to the Pathology Department of the Universidad Nacional de Costa Rica for histopathological study. The mass was processed routinely, embedded in paraffin and stained with Hematoxylin & Eosin (H&E). Immunohistochemistry was performed following the process described in Case 1.

The dimensions of the mass were 12 x 8 x 4.5 cm; it had an irregular shape and hard bony walls. When cut, multiple trabeculae of connective tissue were found which formed septa in the cavity of the cyst (multicavity). Multiple bony papillary projections attached to the cyst wall, with bloody contents were observed on the surface (Fig. 4).

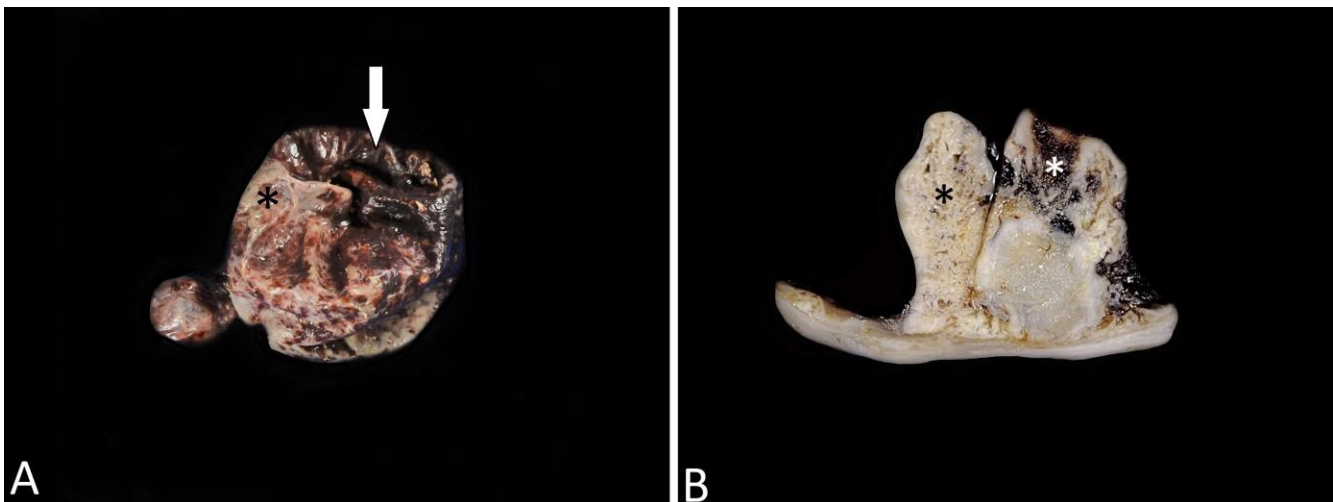


Figure 4. Gross appearance of an extrasosseous ABC in Case 2. **A.** Note the irregular shape (arrow) and the bony wall (asterisk). **B.** Cut surface. Bony wall was composed of multiples bony papillary projections (black asterisk) with bloody content (white asterisk).

Histologically, cyst wall was composed of a proliferation of mesenchymal cells resembling an endothelium, a thick layer of fibrous tissue and reactive bone with chondroid metaplasia (Fig. 5A and B). The fibroblast cells form a solid growth pattern, with marked cell cohesion in a stroma of fibrous tissue (Fig. 5B). The nucleus is oval and paracentral in position with fine granular chromatin and 1-2 basophilic nucleoli. The cytoplasm is sparse and fibrillar with indistinguishable edges. The mitotic count is low. Abundant macrophages phagocytosing hemosiderin, extensive hemorrhages, and osteoclast-type giant cells were observed in the septa (Fig. 5C and D). There were irregular foci of mineralization within the bone lamella. Fibroblasts were positive for vimentin, represented as a fine granular

precipitate within the cytoplasm. Based on histopathological and immunohistochemical findings an extrasosseous aneurysmal bone cyst was diagnosed.

Discussion

ABC is an unusual lesion that was first described in humans by Jaffe and Lichtenstein in 1942 (11). Macroscopically, they are lesions with multiple cystic cavities with bloody contents, with internal trabeculae of solid tissue. Histologically, they consist of cavernous spaces delimited by septa of connective tissue with the presence of giant multinucleated cells, macrophages phagocytosing hemosiderin and bone spicules with osteoblastic activity. In addition, they can contain solid

areas with proliferations of fibroblasts and occasional mitotic figures. The septa may contain thin or thick bone spicules with prominent osteoblastic activity. This lesion

must be differentiated from telangiectatic osteosarcoma, hemangiosarcoma and benign bone cyst (31).

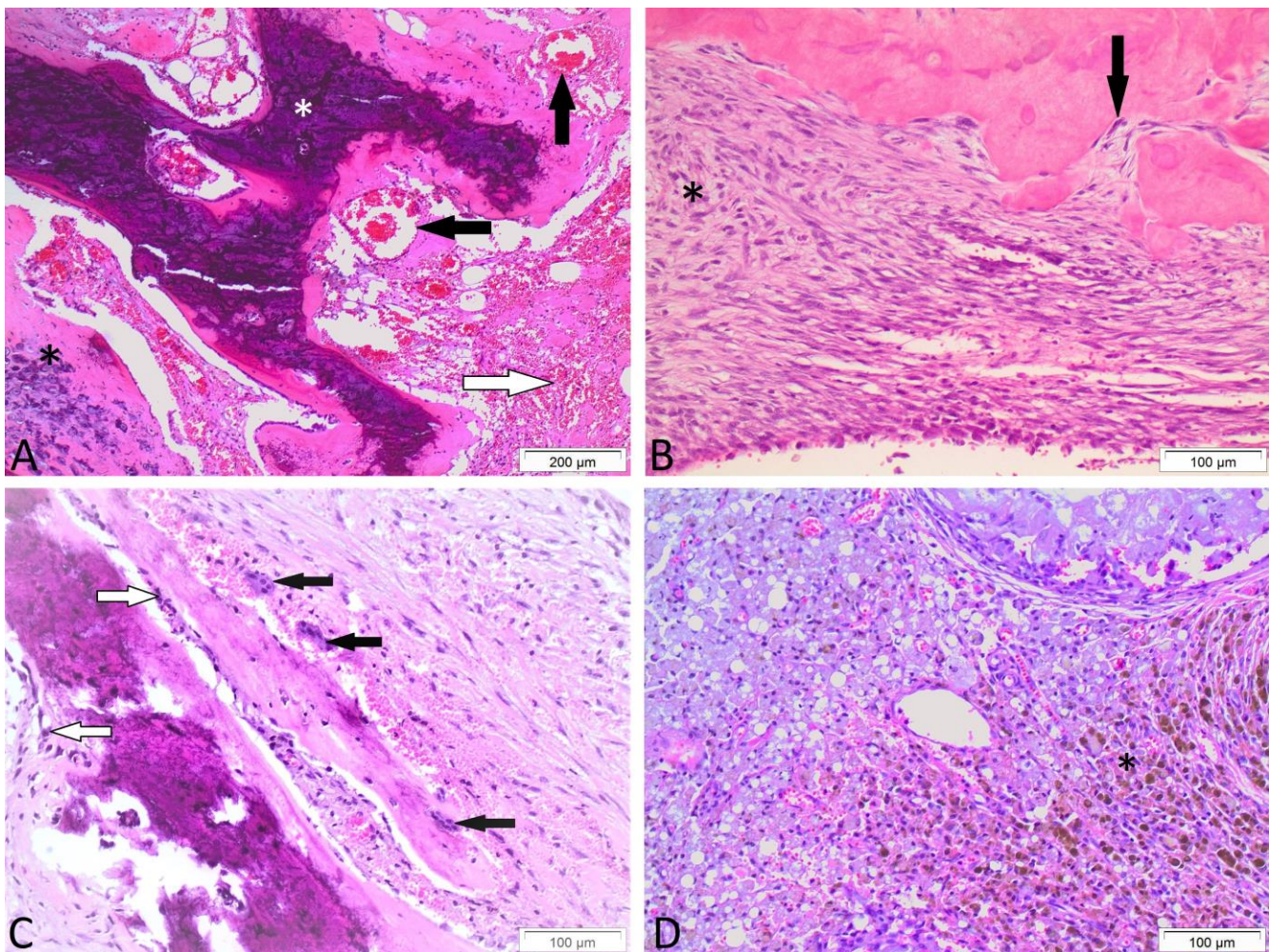


Figure 5. Histopathological appearance of the cyst wall in Case 2. **A.** Cyst wall with multifocal dilated blood vessels (black arrows) surrounded by bone tissue with foci of mineralization (white asterisk), chondroid metaplasia (black asterisk) and hemorrhage areas (white arrow). **B.** Areas of fibrous tissue proliferation (asterisk) and osteoblastic activity (arrow). **C.** Presence of bone spicules with multiple osteoclasts (black arrow) and osteoblast activity (white arrow). **D.** Connective tissue septa with large amounts of hemosiderin-laden macrophages (asterisk). H&E stain.

The extrasosseous variant of ABC has the same characteristics described for intra-bone lesions, but it originates in soft tissue (14). The present work describes the case of two canines with the extrasosseous ABC variant, developing from the soft tissue of the pelvic cavity without involvement of the adjacent bones. Histologically, the description of the cyst present in this report agrees with the characteristics described for a conventional ABC. In addition, immunohistochemical staining was also performed showing strong vimentin positivity due to the presence of abundant connective tissue cells. This finding is congruent with an immunohistochemistry study performed in 25 human cases of ABC that revealed strong vimentin positivity in this lesion (30).

Both cases in this report were discovered incidentally, and surgical removal of the cysts was not a challenge for the surgeon. In the first case of extrasosseous ABC reported in veterinary medicine, the lesion developed in the soft tissue of the perianal region of a canine. In human patients, the most frequent site of occurrence is in a lower limb, followed by the arm and shoulder regions. Other regions include the palm, groin, common carotid artery and abdominal wall. In addition, a slight bias towards occurrence in women has been reported (14).

With regard to the pathogenesis of the lesion, different hypotheses have been proposed to explain the development of the cyst; however, it has not been possible to establish a definitive pathogenesis. Theories include hemodynamic disturbances, trauma, vascular lesions, and

cystic degeneration due to a previous lesion (14). On the other hand, recent studies in human patients with primary ABCs suggest a neoplastic origin of the lesion (10, 33). In both cases reported in this article it was not possible to establish the origin of the lesion, since they were incidental findings in clinically healthy patients without a history of any previous lesion.

The main clinical indicator in patients with ABC is progressive pain related to compression of tissues near the cyst, and pain from intraosseous lesions due to bone destruction; however, the symptoms may vary depending on the anatomical region in which the lesion is located (4). In the first extraosseous ABC case reported in Veterinary Medicine, the canine displayed gait difficulty and weakness in its pelvic limbs, both of which were associated with pain related to dyschezia, due to the anatomical location of the cyst (2). In both cases described in this article, no previous symptoms were reported by the owners or by the clinician carrying out the medical examination; in spite of this, we consider that given the size of the masses and their proximity to the urethra and the rectum, the animals might have experienced dysuria and/or dyschezia.

Based on the histopathological findings, the main differential diagnosis of extraosseous ABC is extraosseous osteosarcoma; however, the cellular atypia and anaplasia present in the extraosseous osteosarcoma septa permit differentiating between both pathologies. Other differential diagnosis that may be considered are: ossifying myositis, giant cell tumors in soft tissues, osteoma in soft tissue, extraosseous telangiectatic osteosarcoma and ossifying fibromyxoid tumor (10, 14, 17).

Conventional ABCs have a high risk of local recurrence, and treatment must therefore involve complete removal of the cyst (15, 23). Complete excision, amputation or curettage with adjunctive therapy, such as cementation, cryotherapy or embolization, is recommended (23). On the other hand, the recurrence of the extraosseous counterpart occurs infrequently after total removal. In a study carried out with five human patients with soft tissue ABC, only one local recurrence was reported as a consequence of incomplete initial excision (17). In the first report of an extraosseous ABC in a canine, the complete removal of the ABC was performed in the soft tissue of the perianal region and no recurrence was found in the follow-up examination performed 11 months after treatment (2). In both of the cases reported in the present article, an excisional biopsy was performed on the cysts from which the masses were completely extracted, and the prognosis is therefore quite favorable.

In conclusion, this study presents the morphological description of an unusual lesion with an atypical occurrence. The histopathological description of this lesion is necessary to obtain a diagnostic confirmation of the lesion, as well as to rule out other pathologies with an unfavorable prognosis, such as extraosseous osteosarcoma. Clinically, total removal of the mass is

necessary to avoid local recurrence of the lesion, producing a favorable prognosis.

References

1. Barnhart MD. Malignant transformation of an aneurysmal bone cyst in a dog. *Vet Surg.* 2002;31:519-24.
2. Barni BS, Santos ER, Rosa, NS, Lopes, DJ, Hesse KL, Pavarini SP, Contesini EA. Cisto ósseo aneurismático em tecido mole em um cão [Aneurysmal bone cyst in soft tissue in a dog]. *Arq Bras Med Vet Zootec.* 2017;69(1):106-10.
3. Belknap EB, Brodie S, Lowry J, Getzeltman R. Aneurysmal bone cyst in a Holstein bull. *J Am Vet Med Assoc.* 1992;201(9):1413-6.
4. Benamou J, Lussier B, Alexander K, Gains M, Savard C. Use of magnetic resonance imaging and histopathologic findings for diagnosis of an aneurysmal bone cyst in the scapula of a cat. *J Am Vet Med Assoc.* 2012;240(1):69-74.
5. Biller DS, Johnson GC, Bichard SJ, Fingland RB. Aneurysmal bone cyst in a rib of a cat. *J Am Vet Med Assoc.* 1987;190(9):1193-5
6. Bryant U, Fallon L, Lee M, Pool R. Congenital aneurysmal bone cyst. *J Eq Vet Sc.* 2012;32:320-3.
7. Grosset C, Reyes-Gómez E, Hedley J, Stambouli F. Aneurysmal Bone Cyst on the carpus of an African Collared Dove. *J Avian Med Surg.* 2012;26(1):11-6.
8. Heatly JJ, Thomas NT, Mitchell MA, Partington BP, Wayne T. Trauma-induced Aneurysmal Bone Cyst in two Psittacine Species (*Cacatua alba* and *Nymphicus hollandicus*). *J Zoo Wildl Med.* 2004;35(2):185-96.
9. Herbach N, Terboven C, Lambrecht P. Solid aneurysmal bone cyst of the distal metatarsus in a horse. *Open J Pathol.* 2016;6:88-92.
10. Jacquot C, Szymanska J, Nemana L, Steinbach LS, Horvai A. Soft-tissue aneurysmal bone cyst with translocation t(17;17) (p13; q21) corresponding to COL1A1 and USP6 loci. *Skeletal radiol.* 2015;44:1695-9.
11. Jaffe HL, Lichtenstein L. Solitary unicameral bone cyst: with emphasis on the roentgen picture, the pathologic appearance and the pathogenesis. *Arch surg.* 1942;44:1004-25.
12. Kiliç N, Yaygöl R. Case report: Congenital aneurysmal bone cyst in a Holstein calf. *Rev Med Vet.* 2013;164(4):179-82.
13. Lamb CR, Schelling SH. Congenital aneurysmal bone cyst in the mandible of a foal. *Eq Vet J.* 1989;21(2):130-2.
14. López L, Rodríguez M, Siegal G, Wei S. Extraskelatal aneurysmal bone cyst: Report of a case and review of the literature. *Path Res Pract.* 2017;213(11):1445-9.
15. Mankin H, Hornicek F, Ortiz-Cruz E, Villafuerte J, Gebhardt M. Aneurysmal Bone Cyst: A Review of 150 Patients. *J Clin Onc.* 2005;23(27):6756-62.

16. Momiyama N, Tagami M, Tsunoda N, Taniyama H. Aneurysmal bone cyst in a colt. *J Eq Vet Ed.* 1999;11(5):243-6.
17. Nielsen GP, Fletcher DM, Smith MA, Rybak L, Rosenber AE. Soft Tissue Aneurysmal Bone Cyst: A Clinopathologic study of five cases. *Am J Surg Pathol.* 2002;26(1):64-9.
18. Nomura K, Sato K. Pelvic aneurysmal bone cyst in a dog. *J Vet Med Sci.* 1997;59(11):1027-30.
19. Ojeda T, de Souza A, Matsubara FM, Quintas AM, de Almeida JQ. Obstrução urinária por cisto ósseo aneurismático no osso peniano de um cão [Urinary obstruction caused by an aneurysmal bone cyst in a dog's penile bone]. *Cien Rur.* 2010;4(1):186-9.
20. Pernell RT, Dunstan RW, DeCampo CE. Aneurysmal bone cyst in a six-month-old dog. *J Am Vet Med Assoc.* 1992;20(12):1897-9.
21. Purdy C. Mandibular aneurysmal bone cyst in a horse. *Eq Pract.* 1985;7:22-4.
22. Renegar WR, Thornburg LP, Burk RL, Stoll SG. Aneurysmal bone cyst in the dog: a case report. *J Am Anim Hosp Assoc.* 1979;15(2):191-5.
23. Sarierler M, Cullu E, Yurekli Y, Birincioglu S. Bone cement treatment for aneurysmal bone cyst in a dog. *J Vet Med Sci.* 2004;66(9):1137-42.
24. Sasaki H, Nagano S, Shimada H, Yokouchi M, Setoguchi T, Ishidou Y, Kunigou O, Maehara K, Komiya S. Diagnosing and discriminating between primary and secondary aneurysmal bone cyst. *Onc Lett.* 2017;13:2290-6.
25. Saunders JH, Heimann M, Taeymans O, Snaps FR. Aneurysmal bone cyst in the pelvis of a cat. *Vlaams Diergen Tijds.* 2003;72:424-8.
26. Shimada A, Yanagida M, Umemura T, Tsukamoto S, Sukanuma. Aneurysmal bone cyst in a dog. *J Vet Med Sci.* 1996;58:1037-8.
27. Shiroma JT, Weisbrode SE, Biller DS, Olmstead ML. Pathological fracture of an aneurysmal bone cyst in a lumbar vertebra of a dog. *J Am Vet Med Assoc.* 1993;29(5):434-7.
28. Steiner JV, Rendano VT. Aneurysmal bone cyst in the horse. *Cor Vet.* 1982;72(1):57-63.
29. Thomas HL, Livesey MA, Caswell JL. Multiple aneurysmal bone cyst in a foal. *Can Vet J.* 1997;38:570-3.
30. Szendroi M, Arató G, Ezzati A, Hüttl K, Szavcsur P. Aneurysmal bone cyst: its pathogenesis based on angiographic, immunohistochemical and electron microscopic studies. *Pathol Oncol Res.* 1998;4(4):277-81.
31. Thompson KG, Dittmer KE. Tumors of bone. In: Maxie MG, editor. *Jubb, Kennedy & Palmer's Pathology of domestic animals.* Iowa: Wiley Blackwell; 2017. 6ed. p. 421.
32. Walker MA, Duncan JR, Shaw JW, Chapman WW. Aneurysmal bone cyst in a cat. *J Am Vet Med Assoc.* 1975;167(10):933-4.
33. Ye Y, Pringle L, Lau AW, Riquelme DN, Wang H, Jiang T, Lev D, Welman A, Blobel G, Oliveira AM, Chou M. TRE17/USP6 oncogene translocated in aneurysmal bone cyst induces matrix metalloproteinase production via activation of NF κ B. *Oncogene.* 2010;29(25):3619-29.