



## Case Report

# *Schistosomus reflexus* in dogs: Case report

Daniel Cala<sup>1,2,3</sup>, Huber Sánchez<sup>4</sup>, Roxana Jaimes<sup>4</sup>, Milena Hernández<sup>2,4</sup>, Jefferson Y. Aguinaga<sup>3\*</sup>

<sup>1</sup>Grupo de Investigación Tecnológica Agropecuaria del Bajo Cauca, Servicio Nacional de Aprendizaje (SENA).

<sup>2</sup>Grupo de Investigación Los Araucos.

<sup>3</sup>Centro de Aquicultura da Unesp, Universidade Estadual Paulista. Via de Acesso Prof. Paulo Donato Castellane, s/n 14884-900 - Jaboticabal, SP/Brazil.  
Phone: (16) 3209-7477.

<sup>4</sup>Facultad de Medicina Veterinaria Zootecnia, Universidad Cooperativa de Colombia sede Arauca, Granja el Picure kilómetro 1 vía Caño Limón, Arauca, Arauca, Colombia. Phone: +57-7-8857963.

\*Corresponding author: E-mail: [jefyunis@gmail.com](mailto:jefyunis@gmail.com)

Submitted November, 20<sup>th</sup> 2018, Accepted February, 19<sup>th</sup> 2019

---

## Abstract

The *Schistosomus reflexus* (SR) etymologically refers to an abdominal and / or thoracic cleft with eventration of viscera. This pathology is diagnosed more frequently in ruminants such as cattle and sheep compared to few cases reported in dogs. According to reports, this is the fourth case of SR that is reported in canines. This condition is likely caused by various factors such as endocrine, alimentary, metabolic, hereditary and teratogenic in the first third of gestation, leading to disorders in embryonic development. In this report, a two-year-old canine Pinscher that presented clinical signs of birth was taken to the Veterinary hospital. Four puppies were born; three of them presented morphological malformations, being compatible with SR. It was observed abdominal cleft associated to abdominal and thoracic ventral midline defect, eventration with exposure of viscera (liver, intestines, and spleen), cleft palate, proptosis and microcephaly.

**Key words:** canine, eventration, congenital defects, fetuses, neonatology.

---

## Introduction

*Schistosomus reflexus* (SR) is a Greek term that refers to a fetal disorder with a split abdomen (1). It is considered the most fatal neonatal lesion (3, 8). It is characterized by a congenital anomaly of the *linea alba* fusion in the belly of the animal, which prevents the complete closure of the abdominal or thoracic cavities (7, 11, 20).

The main alteration in the skeleton is an acute angulation of the spine, a severe ventral curvature of the fetus defined as an abnormal anteroposterior curvature, which is observed as a dorsal approximation of the head with the tail (4, 9, 16, 21). This alteration has been described in veterinary obstetrics, mainly in cows, swine (1, 20), goats and mules (7).

In ruminants, it is frequently associated to dystocic birth (6), ankylosis of the extremities (22), complete malformation of the midline and agenesis of the

rectus abdominis muscles (19), mandibular prognathism, unilateral amelia and mild hydrocephalus (12). In rhinos, it was observed abdominoschisis with eventration, lumbar scoliosis and lateral dorsal displacement of the pelvis (13). In sea turtles of 29 days of embryonic development, SR reduces shell formation, induces scoliosis, lordosis, viscera exposure and spinal inversion (2). On camels, it has generated hydrocephalus, fetal anasarca and hydropic conditions (12).

Few cases have been reported in dogs, the first case was in canine German shepherd that died 10 minutes after birth, it was observed in the necropsy the fissure in the abdomen with exposure and incomplete closure of the rib cage (18). In other case, a Bull terrier that was born alive presented complete malformation of the *linea alba*, agenesis of skin and rectus abdominis muscles (16).

The present report aimed to present the first clinical case of the presence of *Schistosomus reflexus* in a litter of canine Pinscher, in the municipality of Arauca –

Colombia. The macroscopic description of the morphological external and internal structural organs postmortem will provide more information about this disease that presents few reports in canines.

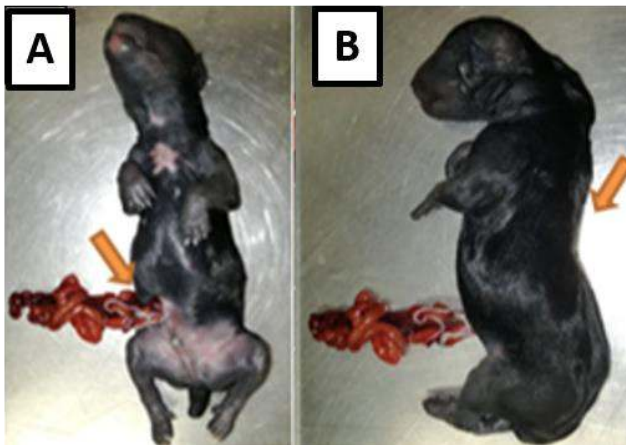### Case Report

A two-year-old female Pinscher was taken to the Small Animal Clinic of the “Cooperative University of Colombia”- Arauca, Colombia, at day 59 of gestation presenting clinical signs of birth. The owner reports that it was the first pregnancy of the animal and that was performed a previous ultrasound at 35 day of gestation, confirming pregnancy and four placentas with an average of 26.4 mm each. There was no report of any alteration in the ultrasound.

The birth was natural. Three of four puppies presented different morphological malformations compatible with SR, mainly abdominal cleft and eventration of viscera. The first was born dead. Two of them were born alive but died after approximately 10 minutes. The last one that did not present malformations is still alive and did not show any clinical signs of disease.

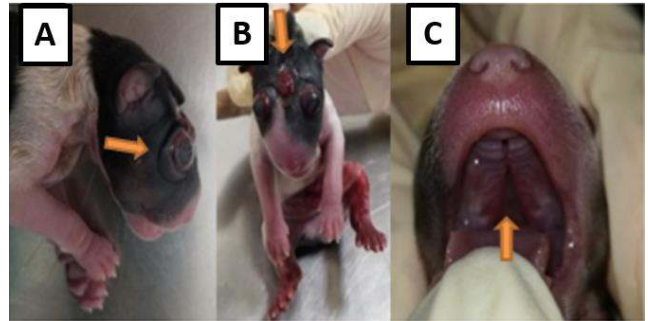#### *External macroscopic description of the puppies*

Pup 1: An incomplete closure of the *linea alba*, 1.5 x 1 cm of extension with evisceration, was observed on mesogastric region, specifically on the insertion of the umbilical cord. Posterior limbs presented (Fig. 1).



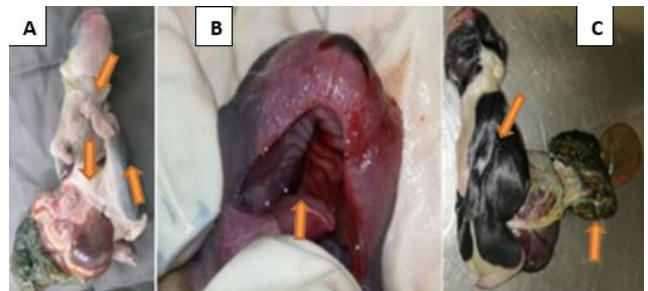
**Figure 1.** A. Evisceration. B. Scoliosis.

Pup 2: Cranial malformations, incomplete closure of the frontal region, microcephaly, proptosis and cleft palate (Fig. 2).



**Figure 2.** A. Proptosis. B. Incomplete closure of the frontal region. C. Cleft palate.

Pup 3: Scoliosis, maximum retroflexion of the spine associated to abdominal cleft from the xiphoid process to the pubis (3 x 2.3 cm of extension) with eventration of the viscera (small and large intestines, liver, stomach and spleen), placenta with meconium, abnormal formation of the legs and cleft palate (Fig. 3).



**Figure 3.** A. Abnormal formation of legs and eventration of the viscera. B. Cleft palate. C. Scoliosis and placenta with meconium

After necropsy, size and weight of the organs were recorded (Table 1). No other alterations were observed besides those described previously. It was observed that the size and weight were proportional to the total size of each pup.

After birth, it was observed no abnormality at ultrasound scan in the uterus. Blood test was within the normal values. No other clinical signs were reported by the owners.

### Discussion

The etiology, pathogenesis and incidence of *Schistosomus reflexus* (SR) are not clear or unknown, due mainly to the few cases reported worldwide. However, it is known that it is more common in ruminants than in canines. The current report represents, to our knowledge, the fourth report of this condition in dogs.

It is suspected that the occurrence of this disease is related to teratogenic alterations during the first third of gestation, preventing the complete formation of the *linea alba* and abdominal wall, leading to the exposure of the abdominal organs, which is incompatible with life (18). In

the current report, the three puppies that presented malformations were born dead or died within a few minutes.

Other authors related the appearance of this condition to an alteration in the vitelline duct of the animal during the first third of gestation related to hereditary factors (7). Kawata and Tiba (1961) mentioned that the most probable cause of this alteration is the large number of fetuses in a single pregnancy, which was not compatible with what was found in this report. Maxie et al. (2007) reported that the degree of the malformation does not depend on the nature of the environmental factors, but on the moment of embryonic development. On the other hand, Ozalp et al. (2011) attributed this pathology to

chromosomal aberrations, considered that they observed chromatin and non-homologous chromosomes mating in lymphocyte culture, of a feline with this alteration (16). Despite these possible causes that leads to the development of this pathology, the mother has not presented any medical record of nutritional, metabolic or endocrine problems. This suggests that these factors would not be involved in this process.

We didn't find any study about the percentage of puppies affected per litter. In this study was observed that 75% of the litter was affected. However, it is necessary more reports to have an adequate average. The current study it is important due to the lack of reports and information of this disease in canines.

**Table 1.** Measurements and weight of the organs of affected puppies.

Organs	Pup 1			Pup 2			Pup 3		
	W	L	Wi	W	L	Wi	W	L	Wi
Respiratory system	3	6.5	-	2	5	-	1	3.5	-
Heart	2	1.5	1.2	1.5	1.2	1	1	1	0.7
Liver	10	6.5	4	8	4	4	7	3.5	2.5
Kidneys	1	1.5	0.9	0.7	1.2	0.7	0.5	1	0.5
Weight and size of animals	107	13	-	81	11.5	-	66	10	-

W=weight (g) L= length (cm) Wi= width (cm)

## References

- Bárcenas-Ibarra A, Rojas-Lleonart I, Lozano-Guzmán RI, García-Gasca A. Schistosomus Reflexus Syndrome in Olive Ridley Sea Turtles (*Lepidochelys olivacea*). Vet Pathol. 2017;54(1):171-7.
- Bidstrup I. Schistosoma reflexum in a twin calf. Aust Vet J. 1981;57(5):251.
- Brodrick TW. Schistosomus reflexus 'howler'. Vet Rec. 1987;121(17):408.
- Van Vleet J.F. & Valentine B. Muscle and tendon. In: Maxie M.G. editor. Jubb, Kennedy & Palmer's Pathology of Domestic Animals. Philadelphia: Elsevier; 2007. p. 185-280
- Gupta RK, Singh V, Sachan V, Agrawal JK, Saxena A. Successful Management of Dystocia due to Schistosomus Reflexus Fetus in a Cow. Indian J Vet Sci Biotechnol. 2017;12(4):97-8.
- Higham DA. Schistosomus reflexus. Vet Rec. 1987;121(19):455.
- Hogger DG. Two cases of schistosoma reflexum at successive parturitions in the same cow. Vet Rec. 1965;77:502.
- Jackson PG. Schistosomus reflexus. Vet Rec. 1987;121(10):235-6.
- Kawata K, Tiba T. A rare case of Schistosomus reflexus in the cat. Jpn J Vet Res. 1961;9(4):179-81.
- Kovács BZ, Stranzinger G. Schistosoma reflexum in a female bovine fetus with synaptonemal complex abnormalities. Schweiz Arch Tierheilkd. 2002;144(2):83-7.
- Kumar A, Gaur M, Raiya SK, Ruhil S, Jeengar K, Choudhary V, Kumar M, Mehta JS, Purohit GN. Foetal arthrogryposis in a camel (*Camelus dromedarius*): A case report. J Camel Pract Res. 2013;20(1):109-11.
- Lankton JS, VanderHart DJ, Terrell SP. Schistosomus reflexus-like malformation in a southern white rhinoceros (*Ceratotherium simum simum*). J Zoo Wildl Med. 2014;45(3):708-11.
- Maxie M.G. & Robinson W.F. Cardiovascular system, In: Maxie M.G. editor. Jubb, Kennedy & Palmer's Pathology of Domestic Animals. Philadelphia: Elsevier; 2007. p. 1-105
- Molina VM, Oviedo CA, Casado A, Arias MP. Schistosomus reflexus in a canine: case report. Rev la Fac Med Vet y Zootec. 2012;59(1):49-55.
- Ozalp GR, Celikler S, Simsek G, Ozyigit MO, Inan S. A case of schistosoma reflexum in a cat with

- chromosomal aberrations. *Reprod Domest Anim.* 2011;46(2):373-6.
16. Özsoy SY, Oto C, Hazirolu R. *Schistosoma reflexum* in a dog. *Ankara Üniv Vet Fak Derg.* 2009;56(1):225-6.
  17. Pandey AK, Kumar S, Gunwant P, Verma A, Phogat JB. *Schistosomus reflexus* monster fetus in bovine and its successful management. *Res J Vet Pr.* 2017;5(2):25-7.
  18. Reyes Ávila IR, Pérez Pineda E, Pérez Freeman F, Reyes Ávila LE. Malformaciones congénitas en la crianza de cerdos del sector no especializado en el oriente de Cuba. *Arch Zootec.* 2010;59(228):601-4.
  19. Shilleto M. *Schistosomus reflexus*. *Vet Rec.* 1987;121(11):263.
  20. Singh V, Patel A, Yadav CL, Gupta RK, Saxena A. Successful management of dystocia due to ankylosed foetal monster through fetotomy in a buffalo. *Indian J Vet Sci Biotechnol.* 2017;12(3):141-2.