Braz J Vet Pathol, 2019, 12(3), 83 – 87
DOI: 10.24070/bjvp.1983-0246.v12i3p83-87

BJVP
Brazilian Journal of Veterinary Pathology
ISSN 1983-0246

Original Full Article

Lung lesions of non-vaccinated puppies affected by canine distemper virus

Gimena Feijóo[1,2], Kanji Yamasaki[3], José M. Verdes[3*]

[1]Área Farmacología, Departamento de Fisiología, Facultad de Veterinaria Universidad de la República (UdelaR), Montevideo, Uruguay.
[2]Unidad de Neurología, Centro Hospital Veterinario, Facultad de Veterinaria Universidad de la República (UdelaR), Montevideo, Uruguay.
[3]Área Patología, Departamento de Patología, Facultad de Veterinaria Universidad de la República (UdelaR), Montevideo, Uruguay.
[*]**Corresponding author:** Área Patología, Departamento de Patología, Facultad de Veterinaria, Universidad de la República, Av. Alberto Lasplaces 1620, CP 11600, Montevideo, Uruguay. E-mail: jmverdes@fvet.edu.uy

Submitted May, 26th 2019, Accepted August, 15th 2019

Abstract

Canine distemper is an uncommon disease in vaccinated domestic dogs, but presents high incidence in South America due to the lack of widespread prevention measures. The purpose of this study is to describe histological lung lesions in non-vaccinated puppies affected by canine distemper virus (CDV). The lungs of 4 non-vaccinated puppies ageing 2 to 5 months that showed respiratory signs for about 15 days were examined. Interstitial pneumonia was histologically detected in one puppy, while the other 3 showed alveolar lesions such as edema, congestion and hemorrhage. To our knowledge, there are no previous reports of pulmonary disease without interstitial pneumonia in puppies diseased by CDV. The differences observed between puppies may relate to distinct passive immune states. Remarkably, characteristic inclusion bodies of CDV were only detected in alveolar epithelial cells and macrophages of the puppy with interstitial pneumonia.

Key words: dogs, canine distemper virus, lung, histopathologic diagnosis.

Introduction

Canine distemper (CD) is currently an uncommon disease in vaccinated dogs, but remains as one the most prevalent and widespread viral diseases of domestic dogs in South America because of deficient vaccination in several countries (1, 8). It is most common between 3-6 months of age, and pups with impaired passive immunity are easily infected (3, 10). The development of characteristic lesions of this disease has been said to be strongly dependent on the immune status of affected dogs (3, 5, 10). The occurrence of pneumonia is one of the main features in dogs infected by CDV, typically interstitial pneumonia (2, 3, 4, 5, 6, 7, 9, 10, 12). In the present study, we describe the lung lesions of non-vaccinated puppies ageing 2-5 months clinically, pathologically and immunohistochemically diagnosed as affected by canine distemper, and showing a history of at least 15 days of respiratory progressive disease.

Material and methods

We studied 4 non-vaccinated puppies with clinical diagnosis of canine distemper (CD) from Toledo, Canelones, Uruguay (34°44'S / 56°05'W), between July-August 2016, 3 of them mongrel (Nº 1, 2, 4) and one Border collie (Nº 3) ageing 2 to 5 months. Two of the mongrel puppies (cases 1 and 2) were kept by the same owner but belonged to different litters. All of them presented the typical clinical neurological signs of CD, confirming CDV presence in central nervous system by immunohistochemistry (data not shown). Case No. 3 died spontaneously after the onset of neurological and respiratory signs, while the remaining puppies were euthanized upon request of the owners due to the

 All rights reserved 2007.

Braz J Vet Pathol, 2019, 12(3), 83 – 87
DOI: 10.24070/bjvp.1983-0246.v12i3p83-87

progressive deterioration of their general condition. An intravenous barbiturate overdose (100 mg/kg BW) was implemented, according to a previously approved protocol by IACUC of Facultad de Veterinaria, Universidad de la República (CEUA FVET-UdelaR N° 320/16).

Main clinical signs in cases 1 and 3 were respiratory dysfunction with nasal mucopurulent discharge, depression, anorexia, and also neurological signs including generalized seizures. In cases of 2 and 4 clinical signs were characterized by bloody diarrhea, vomiting, depression and anorexia, starting approximately 30 days before the onset of neurological signs, consisting of myoclonus, seizures, and in the case No. 4, accompanied of clinical signs of encephalitis. The puppy No. 2 had respiratory signs characterized by coughing and ocular discharge that started 5 days after the onset of the digestive signs. All animals showed skin lesions characterized by nasal and plantar hyperkeratosis.

At necropsy, the lungs and brain were fixed in a 10% buffered formalin solution, and routinely processed for histopathological evaluation. Lung histological examination of each puppy included multiple lobes of both lungs.

Results

At necropsy, gross lesions of the lungs were similar in all puppies. The lungs at handling were heavier than expected, wet and failed to collapse when the thorax was opened. Free fluid was detected in the thoracic cavities. The surface of the lungs looked edematous and with sparse foci of dark red areas with no defined pattern (Fig. 1). On the cut surface, white foamy exudates was observed in major bronchi.

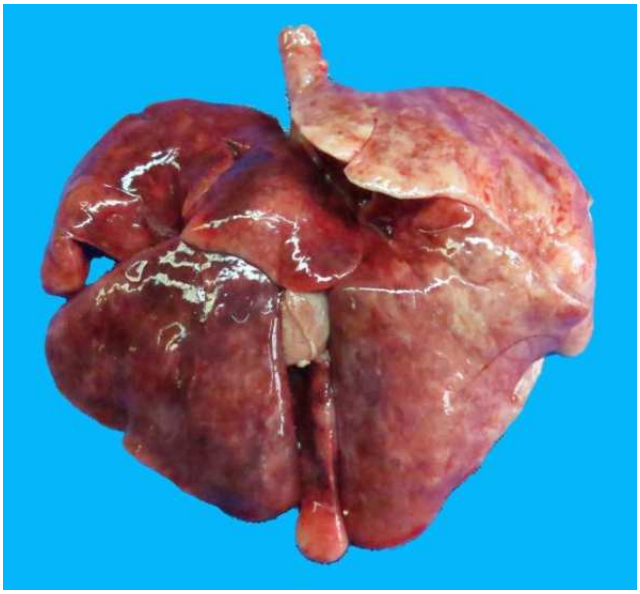

Figure 1. Animal Nº 2. Gross findings. The surface of the lungs is edematous and the color is not uniform.

Histologically, the main lesions were similar in 3 of the puppies (1, 3 and 4), in which the characteristic change was the presence of eosinophilic proteinaceous fluid in the alveolar space, accompanied by congestion and hemorrhage in the alveolar septs (Figs. 2 and 3). Although desquamated alveolar and bronchiolar epithelial cells, foamy cells and inflammatory cells were observed in alveoli and bronchioles/bronchi, these changes were not severe. Thickening of the alveolar septa with presence of inflammatory cells was not characteristic, and the infiltration of inflammatory cells with edematous changes around bronchi and bronchioles were not progressive to the respiratory alveoli. The pathological changes were similar in all histological preparations examined. In case No. 2, interstitial pneumonia was observed along with the other above-mentioned changes. Although alveolar edema, congestion and hemorrhage were also observed as in the other three cases, the interstitial pneumonia was only characteristic in puppy No. 2; the alveolar septa were thickened with infiltration of inflammatory cells (neutrophils, lymphocytes, plasma cells, mast cells and histiocytic cells), and alveolar epithelial cells were swollen. Desquamation was also observed in the alveolar lumens (Figs. 4 and 5). The alveolar and bronchiolar spaces were filled with many detached alveolar and bronchial epithelial cells, neutrophils, macrophages, lymphocytes, necrotic, foamy and multinucleated syncytial cells along with cell debris. The eosinophilic intracytoplasmic and intra-nuclear inclusion bodies within the alveolar epithelial cells and macrophages characteristic of CD were only observed in this case (Fig. 6). In addition, infiltration of various inflammatory cells, fibroblasts and edema were observed in the mucosa and submucosa of the bronchioles and bronchi (Fig. 7). The histological changes are summarized in Table 1.

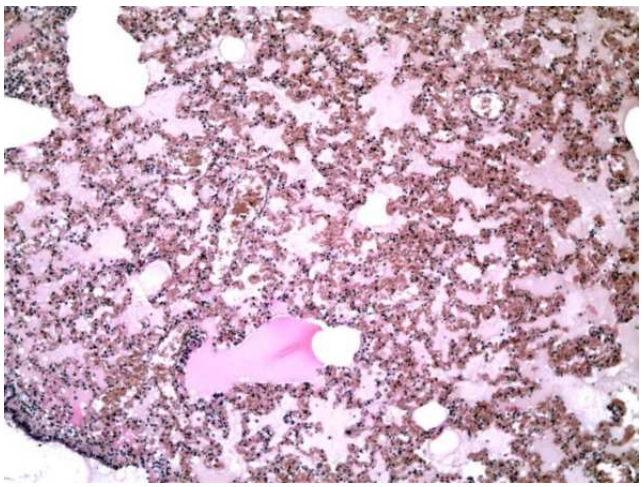

Figure 2. Animal Nº 1. Histopathological findings. Alveolar spaces are filled with eosinophilic proteinaceous fluid accompanied with congestion and hemorrhage in the alveolar septa (HE, 100x).

Braz J Vet Pathol, 2019, 12(3), 83 – 87
DOI: 10.24070/bjvp.1983-0246.v12i3p83-87

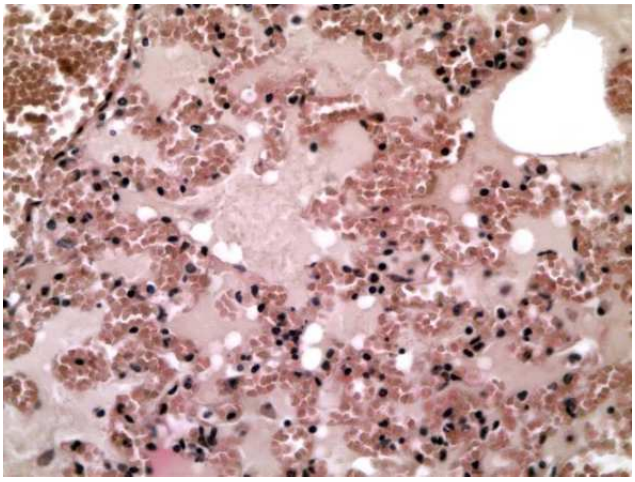

Figure 3. Histopathological findings. Same as figure 2 at higher magnification. Thickening of alveolar septa is not observed (HE, 400x).

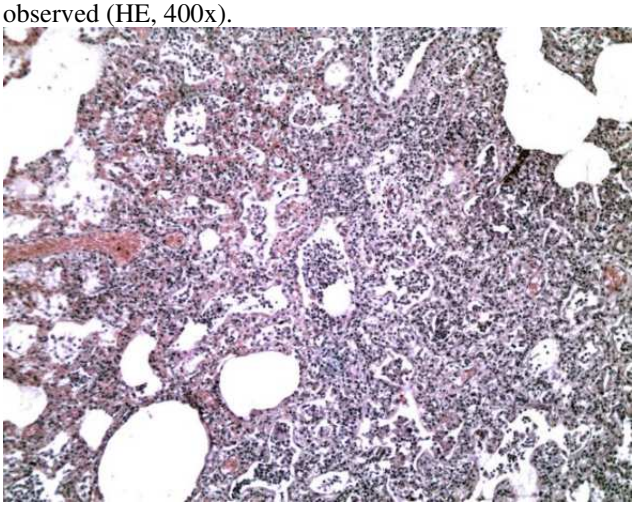

Figure 4. Animal Nº 2. Histopathological findings. Alveolar septa are thickened and with/by inflammatory cells, and alveolar epithelial cells are swollen and desquamate in the alveolar lumens (HE, 100x).

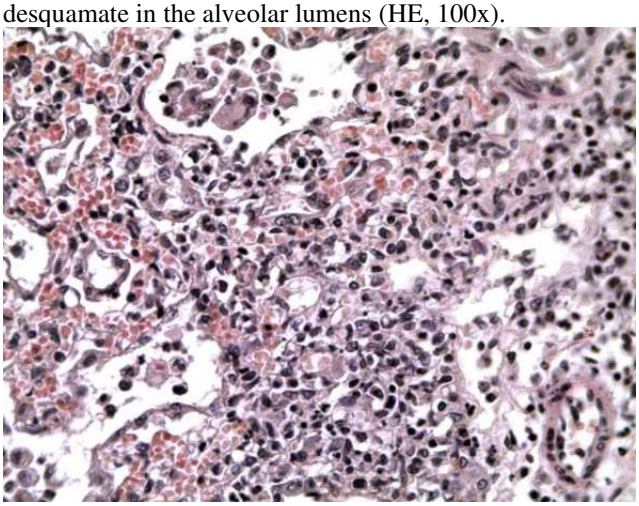

Figure 5. Histopathological findings. Same as in figure 4 at higher magnification. Thickening of alveolar septa is evident, as detached epithelial cells, macrophages and giant cells in the alveolar spaces (HE, 400x).

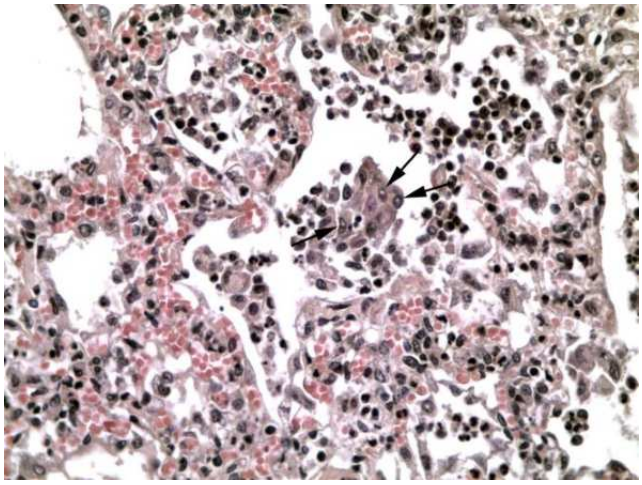

Figure 6. Animal Nº 2. Histopathological findings. Intranuclear inclusion bodies are present in desquamated alveolar epithelial cells (arrows) (HE, 400x).

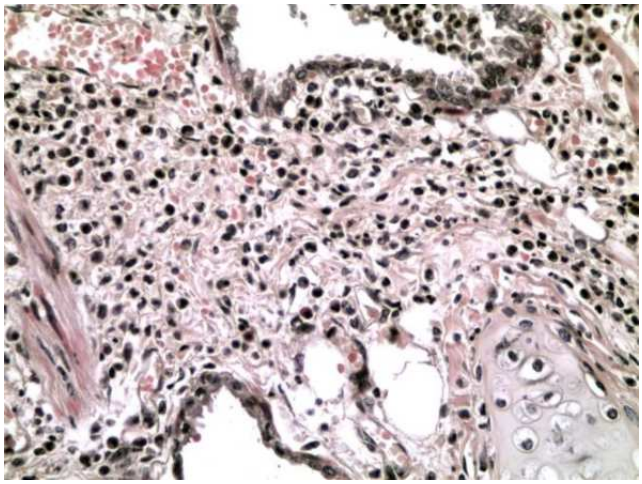

Figure 7. Animal Nº 2. Histopathological findings. Edema and inflammation can be observed in the mucosa and submucosa of bronchi (bronchial cartilage on bottom right, HE, 400x).

Discussion

The histological lung lesions reported here, in non-vaccinated pups with previous clinical, pathological and immunohistochemical diagnosis as affected by canine distemper virus (CDV), confirmed in one case, the previous information that the interstitial pneumonia is the characteristic lung lesion of the dogs clinically affected by CDV (2, 3, 4, 5, 6, 7, 10, 12). However, the edematous changes in the alveoli with congestion and hemorrhage were the main changes of the other three cases without interstitial pneumonia. Remarkably, changes in the bronchial branches did not progress in depth in the parenchyma. In addition, changes of the bronchioles/bronchi were not characteristic of what described for the disease (7, 10). To our knowledge, there are no previous reports describing alveolar edematous

changes without interstitial pneumonia in puppies infected with CDV. There were no relevant differences in age and clinical stage of respiratory disease among all examined cases. For these reasons, it was difficult to clarify why lung lesions were not similar in all cases. A possible explanation would be differences in the immune status, as it is well known that the development of the lesions is highly dependent on the passive acquisition of maternal immunoglobulins in pups infected with CDV (3, 5, 10). Although the studied puppies came from the same geographic area, another possible source of variation would be the CDV strains involved. Major CDV lineages identified worldwide are America 1 and 2, Asia 1 and 2, Europe 1, Europe wildlife, Arctic-like, and South Africa (14). It was reported that the most prevalent lineage in South America is Europe 1, recently renamed as Europe 1/South America 1 (11), present in Uruguay and southern Brazil (13). This lineage is distantly related to current vaccine strains, and whether genetic differences in the Brazilian strains of CDV might be responsible for the distemper outbreaks in local vaccinated canine populations in the region deserves further study (2, 11). There is a strong suspicious that various strains of CDV are present in South American countries (11). However, the possibility of distinct lung lesions in our study due to the different strains of CDV is low, because cases No. 1 and No. 2 were kept by the same owner and the clinical signs in these pups developed at the same time.

Table 1. Histopathological changes of puppies infected with canine distemper virus.

Case No.	Age (months)	Alveoli				Bronchi/bronchioles	
		Edematous fluid in lumen	Congestion and hemorrhages	Thickening of alveolar septa	Cellular elements in lumen	Interstitial inflammation and edema	Cellular elements in lumens
1	3	+++	+++	-	+	+	+
2	2	++	++	+++	+++	+++	+++
3	5	+++	+++	+	+	-	+++
4	4	+++	++	-	+	-	+

-; not observed, +; slight, ++; moderate, +++; severe

Inclusion bodies were detected only in the case showing interstitial pneumonia, and were not detected in the other 3 pups. From this fact, we presume that the inclusion bodies appear when lung lesions progress, and there is a large viral load. The brains of the puppies showed non-suppurative encephalomyelitis with demyelination, gliosis, cuffing and eosinophilic inclusion bodies, with the canine distemper virus antigen being positive at immunohistochemistry (unpublished data). It is very interesting that the appearance of inclusion bodies was different between organs. In a previous study one hundred dogs affected with CDV were examined for the distribution of inclusion bodies in various tissues, and in most of them they were detected in the lungs (70 dogs), followed by the brain (20 dogs) (7). Lungs seems to be candidate tissue for the detection of these diagnostic structures. On the other hand, inclusion bodies may often persist in the nervous tissue even when they are no longer detectable in other locations (3). The differences between the brain and lungs may relate to the response of each organ and/or the passive immune status of puppies.

In conclusion, alveolar edematous changes without interstitial pneumonia should be considered as histological lesions in puppies infected with CDV. Further research would help to understand the occurrence of different pathological features as related to the lineages/strains of CDV involved, passive immune status and genetic factors.

Acknowledgements

The authors would like to thank Dr. Claudio Borteiro for reviewing this manuscript. Gimena Feijoó is MSc student of Programa de Posgrados de la Facultad de Veterinaria (PPFV-UdelaR, Uruguay). José Manuel Verdes was supported by CSIC-UdelaR, PEDECIBA, and ANII (Uruguay).

References

1. Acosta-Jamett G, Surot D, Cortés M, Marambio V, Valenzuela C, Vallverdu A, Ward MP. Epidemiology of canine distemper and canine parvovirus in domestic dogs in urban and rural areas of the Araucanía region in Chile. Vet Microbiol. 2015;178:260-4.
2. Amude AM, Headley SA, Alfieri AA, Beloni SNE, Alfieri AF. Atypical necrotizing encephalitis associated with systemic canine distemper virus infection in pups. J Vet Sci. 2011;12:409-11.
3. Caswell JL, Williams KJ. Respiratory System. In: Maxie MG, editor. Jubb, Kennedy & Palmer's Pathology of domestic animals. 6th ed., vol. 2. St. Louis, Missouri: Elsevier; 2001. p. 465-591.
4. Goller KV, Fyumagwa RD, Nikolin V, East ML, Kilewo M, Speck S, Müller T, Matzke M, Wibbelt G. Fatal canine distemper infection in a pack of African wild dogs in the Serengeti ecosystem, Tanzania. Vet Microbiol. 2010;146:245-52.
5. Headley SA, Alfieri AA, Fritzen JTT, Garcia JL, Weissenböck, H, da Silva AP, Bodnar L, Okano W,

Alfieri AF, Selwyn AH. Concomitant canine distemper, infectious canine hepatitis, canine parvoviral enteritis, canine infectious tracheobronchitis, and toxoplasmosis in a puppy. J Vet Diagn Invest. 2013;25:129-35.

6. Headley SA, Shirota K, Baba T, Ikeda T, Sukura A. Diagnostic Exercise: Tyzzer's Disease, Distemper, and Coccidiosis in a Pup. Vet Pathol. 2009;46:151-4.
7. Kubo T, Kagawa Y, Taniyama H, Hasegawa A. Distribution of inclusion bodies in tissues from 100 dogs infected with canine distemper virus. J Vet Med Sci. 2007;69:527-9.
8. Negrão FJ, Gardinali NR, Headley SA, Alfieri AA, Fernandez MA, Alfieri AF. Phylogenetic analyses of the hemagglutinin gene of wild-type strains of canine distemper virus in southern Brazil. Genet Mol Res. 2013;12:2549-55.
9. Okita M, Yanai T, Ochikubo F, Gemma T, Mori T, Maseki T, Yamanouchi K, Mikami T, Kai C. Histopathological features of canine distemper recently observed in Japan. J Comp Pathol. 1997;116:403-8.
10. Pandher K, Podell B, Gould DH, Johnson BJ, Thompson S. Interstitial pneumonia in neonatal canine pups with evidence of canine distemper virus infection. J Vet Diagn Invest. 2006;18:201-4.
11. Panzera Y, Gallo Calderón M, Sarute N, Guasco S, Cardeillac A, Bonilla B, Hernández M, Francia L, Bedó G, La Torre J, Pérez R. Evidence of two co-circulating genetic lineages of canine distemper virus in South America. Virus Res. 2012;163,401-4.
12. Rodríguez-Tovar LE, Ramírez-Romero R, Valdez-Nava Y, Nevárez-Garza AM, Zárate-Ramos JJ, López A. Combined distemper-adenoviral pneumonia in a dog. Can Vet J. 2007;48:632-4.
13. Sarute N, Pérez R, Aldaz J, Alfieri AA, Alfieri AF, Name D, Llanes J, Hernández M, Francia L, Panzera Y. Molecular typing of canine distemper virus strains reveals the presence of a new genetic variant in South America. Virus Genes. 2014;48,474-8.
14. Woma TY, van Vuuren M, Bosman AM, Quan M, Oosthuizen M. Phylogenetic analysis of the haemagglutinin gene of current wild-type canine distemper viruses from South Africa: lineage Africa. Vet Microbiol. 2010;143:126-32.