BJVP
Brazilian Journal of Veterinary Pathology
ISSN 1983-0246

Original Full Paper

Hepatogenous photosensitization by *Brachiaria* spp. in sheep: first report in Mexico

Celic B. Montoya-Ménez[1], Johnatan A. Ruíz-Ramírez[2], Luis J. G. Márquez[2,3*], Adriana Méndez-Bernal[1], Elizabeth Morales-Salinas[1], Rafael Ramírez-Romero[4], Julio Martínez-Burnes[5], Alfonso López-Mayagoitia[6]

[1]Departamento de Patología. Facultad de Medicina Veterinaria y Zootecnia, Universidad Nacional Autónoma de México, Avenida Universidad 3000, Ciudad Universitaria, Delegación Coyoacán, Ciudad de México, 04510, México.
[2]Facultad de Medicina Veterinaria y Zootecnia, Universidad de Colima, Carretera Colima-Manzanillo Km 40. Colonia: La Estación. CP. 28100, Tecomán, Colima, México.
[3]Centro Universitario de Investigación y Desarrollo Agropecuario (CUIDA), Universidad de Colima, Carretera Colima-Manzanillo Km 40. Colonia: La Estación. CP. 28100, Tecomán, Colima, México.
[4]Facultad de Medicina Veterinaria y Zootecnia de la Universidad Autónoma de Nuevo León. Francisco Villa S/N, Colonia: Ex Hacienda el Canadá, Escobedo, Nuevo León, México.
[5]Facultad de Medicina Veterinaria y Zootecnia "Dr. Norberto Treviño Zapata," Km 5 Carretera Victoria-Mante, Ciudad Victoria, Tamaulipas, México.
[6]Department of Pathology and Microbiology Atlantic Veterinary College. University of Prince Edward Island, Charlottetown, PEI. Canada C1A 4P3.
*__Corresponding author:__ Dr. Luis Jorge García Márquez; E-mail: ljgm_cmv@hotmail.com

Submitted January, 30th 2019, Accepted July, 1st 2019

Abstract

Ruminants are highly susceptible to photosensitization caused by the ingestion of hepatotoxic plants. In two adjacent farms in Colima, Mexico, several sheep exhibited signs of depression and crusting dermatitis involving the ears, periorbital skin, eyelids, nostrils, and axillary regions. Results of serum biochemistry were indicative of liver injury. *Post mortem* examination revealed jaundice, craniofacial edema as well as an enlarged liver having an orange-brown discoloration; on the cut surface, the hepatic parenchyma had a subtle zonal pattern. Histopathological findings were those of severe necrotizing dermatitis, lymphoplasmacytic cholangiohepatitis, and renal tubular necrosis. Acicular crystals were microscopically and ultrastructurally evident in hepatocytes, Kupffer cells, biliary ducts, renal tubules and interstitium. The clinical, gross and microscopic findings were consistent with hepatogenous photosensitization. A field investigation revealed that affected sheep had been grazing *Brachiaria* spp., a potentially toxic grass originated from Africa and commonly cultivated in Australia and South America. This grass contains hepatotoxic saponins that cause liver injury and secondary hepatogenous photosensitization. Although frequently reported in South America, to our knowledge, this is the first report of *Brachiaria* spp. toxicity in Mexico.

Key words: sheep, plant poisoning, mulato grass, toledo grass, hepatotoxic saponins, phytoporphyrin, photodermatitis.

Introduction

Ingestion of poisonous plants causes a variety of clinical maladies in ruminants and financial problems for farmers worldwide (6, 15, 20). Animal species, chemical composition, toxic dose, and genetic predisposition are just a few of the predisposing factors concerning plant toxicity (14, 20). Plants of the genus *Brachiaria* (Panicea family) are native to Africa and were introduced for grazing purposes to Australia, Malaysia, and South America (1, 6, 19). In South America, *Brachiaria* spp. is one of the most calamitous poisonous plants, particularly in Brazil and Colombia (4, 5, 18). Some farmers and veterinarians are unaware that this grass becomes toxic when used as the sole source of feed in cattle, sheep, and horses (1). According to some reports, 1-30% of the sheep can be affected in geographical areas where *Brachiaria* spp. is grown (6, 10).

Steroidal saponins, the active toxic substance in *Brachiaria* spp., cause liver damage which in many cases culminate in hepatic failure and hepatogenous photosensitization (4, 9, 11, 13, 23). Affected sheep develop facial edema, alopecia, and necrotizing ulcerative dermatitis (1, 12, 13, 21). As with all forms of photodynamic dermatitis, the most severely affected areas of the body are those covered with thin and poorly pigmented skin such as eyelids, nostrils, and pinnae (4, 9, 13). As the condition progresses, the ruminant becomes lethargic, develop jaundice, neurological signs, and finally dies (1, 13, 21). The vast majority of reports of *Brachiaria* spp. poisoning in sheep originate from Africa, Australia, and South America, and to our knowledge, it has never been reported in Mexico.

The objective of this work is to describe the clinical, pathological and ultrastructural findings in two outbreaks of *Brachiaria* spp. toxicity in sheep raised in the tropical regions of Mexico.

Material and methods

The first outbreak occurred in September 2016 in the rural community of Loma de Fatima in the State of Colima, Mexico (Farm A). This farm had one ram, and nine pregnant Pelibüey ewes, between 10 and 12 months old, purchased 3-months earlier and put to graze in 10 hectares of cultivated Toledo grass (*Brachiaria brizantha*) (International Center for Tropical Agriculture (CIAT) #26110). According to information provided by the farmer and the local veterinarian, two animals (2/10 = 25% morbidity) were notably depressed, with anorexia, weight loss and the head down for several days. Clinical examination of affected sheep revealed bilateral edematous and crusted dermatitis affecting the eyelids, ears, and nostrils, and mucopurulent exudate was visible in the conjunctiva and nostrils. Thirty days after the initial clinical examination, one (1/10 = 10% mortality) of these sheep died (sheep 1).

The second outbreak occurred during September and October 2016 in the small community of Coahuayana, Michoacán, Mexico (Farm B). At that time, this farm had 130 mixed-breed sheep, between 10 and 12 months old, grazing in two hectares planted with "mulato grass" (*Brachiaria hibrida*) (cv. Mulato II: CIAT #36087). Sheep had been purchased in August, and the problem started a month later. The clinical signs and gross lesions were the same as those described for Farm A, and at the time, 25 sheep (25/130 = 19.2% morbidity) were affected with the clinical disease. One sheep on Farm B was found dead (sheep 2), and another (sheep 3) was euthanized with an intravenous overdose of barbiturates (5 mL/kg body weight) (Pisabental® pentobarbital sodium 6.3%) (2/130 = 1.5% mortality). Blood samples taken from other nine animals (sheep 4-12) with clinical signs (Farm B) were sent for serum biochemistry to the diagnostic laboratory. Farms A and B were located geographically close. During the months in which disease developed (September and October), environmental temperature of the two locations was similar, ranging from 30 to 33°C. In September the relative humidity was 94% to 98% and 68% to 93% during October. The rainfall was 4.7 to 6.9 inches in September and 1.5 to 4.5 inches in October. The daylight average during both months was 12 hours. The daily average incident shortwave solar energy is essentially constant in both months, remaining around 4.4 kWh throughout (National Meteorological System, 2016).

Three dead sheep were submitted for *post-mortem* examination to the Pathology Laboratory of the Faculty of Veterinary Medicine, University of Colima. Samples of liver, kidney, lungs, heart, brain, and skin were fixed in 10% buffered formalin. Fixed tissues processed and embedded in paraffin were sectioned at 5 µm and stained with Hematoxylin-Eosin. Also, liver and kidney were stained with Von-Kossa for calcium. Liver and kidney deparaffinised blocks were fixed in 2.5% glutaraldehyde and 1% osmium tetroxide, processed and embedded in epoxy resin. Semithin sections cut at 150 nm were stained with toluidine-blue and observed by light microscopy. Areas of interest were carefully chosen, and thin sections were cut at 80 nm, contrasted with uranyl acetate and lead citrate, and examined by transmission electron microscopy (Jeol 1010/60 kV).

Results

Table 1 summarizes the results of the serum biochemistry for nine affected sheep. The most notable abnormalities were a significant increase in gamma-glutamyl transferase [GGT], glutamate dehydrogenase [GLDH] and aspartate aminotransferase [AST], as well as hyperbilirubinemia and azotemia. Hematology was not done in any of these sheep.

Grossly, the three sheep (Sheep 1, 2, and 3) had similar cutaneous lesions which consisted in large ulcers in the periocular skin, ears, nostrils, and axillary regions (Fig. 1A). The affected skin revealed erythema, alopecia and severe crusting (Fig. 1A and 1B). Sheep 2 and 3 also exhibited a yellow discoloration of the oral mucosa, conjunctiva and serosal membranes that was interpreted as jaundice (Fig. 1C). These icteric changes were barely present in sheep 1. All three animals had notable craniofacial and cervical swelling, which upon dissection, revealed severe subcutaneous edema that extended into the ventral abdomen and thorax.

The liver in all sheep was moderately enlarged, but the hepatic capsule appeared smooth and unremarkable (Figs. 1C and 1D). On cut surface, the hepatic parenchyma was orange-brown and revealed a mild zonal pattern (Fig. 1D). Although the hepatic texture was slightly firmer than usual, hepatic fibrosis was not an overt gross finding. The kidneys in Sheep 3 showed a green-brown discoloration diffusely involving the cortex and medulla, but the organs were otherwise unremarkable (Fig.

1E). Histopathologic changes were not observed in the lungs, heart and brain.

Table 1. Serum biochemistry (Reference value).

Sheep Number	GGT U/L (<56)	AST U/L (<180)	GLDH U/L (<20)	TB µmol/L (0-6.8)	NCB µmol/L (0-5.1)	CB µmol/L (0-5.1)	Alb g/L (27-30)	Ca mmol/L (2.5-3.2)	P mmol/L (1.6-2.3)
4	229	495	22	131.5	79.1	52.4	26	1.98	2.63
5	431	326	34	7.4	3	4.4	24	2.37	1.35
6	485	701	20	33.9	17.9	16	29	2.51	2.22
7	65	188	25	2.5	1.5	1	26	2.13	2.52
8	302	606	32	151.8	73.8	78	25	2.15	2.18
9	377	292	58	6.40	3.2	3.2	22	2.20	1.92
10	784	378	123	5.7	2.6	3.1	28	2.49	2.14
11	186	92	7	1.5	0.2	1.3	14	1.63	1.37
12	236	121	18	1.7	0.4	1.3	26	2.38	1.9

GGT = Gamma-glutamyl transferase; AST = Aspartate aminotransferase; GLDH = Glutamate dehydrogenase; TB = Total bilirubin; UB = Unconjugated bilirubin; Alb = Albumin; Ca = Calcium; P = Phosphorus.

Significant microscopic lesions involved the skin, liver, and kidneys. The affected skin had extensive loss of the epidermis (ulceration), and a serocellular crust composed of fibrin, neutrophils, necrotic cells, and erythrocytes (Fig. 1F). The dermis and subcutaneous tissue appeared effaced by extensive edema, cellular debris, degenerating neutrophils, and some dermal blood vessels contained fibrin thrombi (Fig. 1F). Overall, the dermal vasculature appeared hypercellular with thickened arterial walls resulting from the accumulation of hypereosinophilic material mixed with neutrophils (vasculitis) (Fig 1G).

There was some dissociation of the hepatic cords and slight proliferation of connective tissue around the biliary ducts. Aggregates of lymphocytes, plasma cells, and macrophages infiltrated the periportal connective tissue (Fig. 1H). The lumen of some biliary ducts and the cytoplasm of Kupffer cells contained needle-shaped, birefringent and Von Kossa-positive crystals ranging from 20-40 µm in length (Fig. 1I). The biliary cells adjacent to the acicular crystalline structures appeared swollen, necrotic and frequently exfoliated. Clusters of histiocytic cells (macrophages) were typically surrounded these crystals. There was also single-cell degeneration and necrosis of hepatocytes, and some of these cells contained cytoplasmic vacuoles with crystalline formations similar to those present in the biliary duct. Occasionally, there was cholestasis where biliary canaliculi appeared distended with stagnant bile. Some renal tubules were distended with exfoliating cells in the lumen (Fig. 1J), and focally, few tubules and the interstitium also contained aggregates of birefringent crystals similar to those previously described in the liver. These crystals ranged from 20-40 µm in length and were also strongly positive for calcium with Von Kossa stain (Fig 1K).

Ultrastructurally, the crystals appeared as electron-lucent needle-like structures with irregular poles. These crystalline structures were observed in the cytoplasm of both hepatic and renal epithelial cells, as well as in macrophages, and biliary ducts (Fig. 1L). The rough endoplasmic reticulum of hepatocytes appeared dilated. The affected tubular cells had swollen mitochondria with loss of cristae, and crystals were also identified in the renal interstitium.

Discussion

Jaundice and ulcerative dermatitis around the eyelids, pinnae, and nares in the sheep at the time of presentation were clinically suggestive of hepatogenous photosensitization (13, 21). The serum chemistry in affected animals revealed a significant elevation of GGT, GLDH, AST and bilirubin, results that further supported the presumptive diagnosis of (5, 11). The agents involved in the outbreaks of photosensitization have not been formally investigated globaly, because in many cases it is not easy to identify the exact source of a poison involved in photosensitization, once there is a large amount of toxins and toxic plants in an agricultural setting (6, 13, 21). The most common hepatotoxicants for sheep are arsenic, copper, mycotoxins, algae, as well as a variety of poisonous plants, all of which can cause ovine photosensitization (8, 12, 14). Field investigations conducted by one of the authors (LJGM) discovered that the affected sheep had been grazing on *Brachiaria* spp. pasture, a toxic grass never considered a source of ovine photosensitization in Mexico. As expected in any other hepatogenous photosensitization (1, 12, 13, 21), the most relevant gross and microscopic findings in the sheep poisoned with *Brachiaria* spp. involved the liver, kidneys, and skin.

Photodynamic dermatitis or photosensitization is not a specific disease but rather the clinical manifestation of aberrant metabolism of photodynamic molecules, which

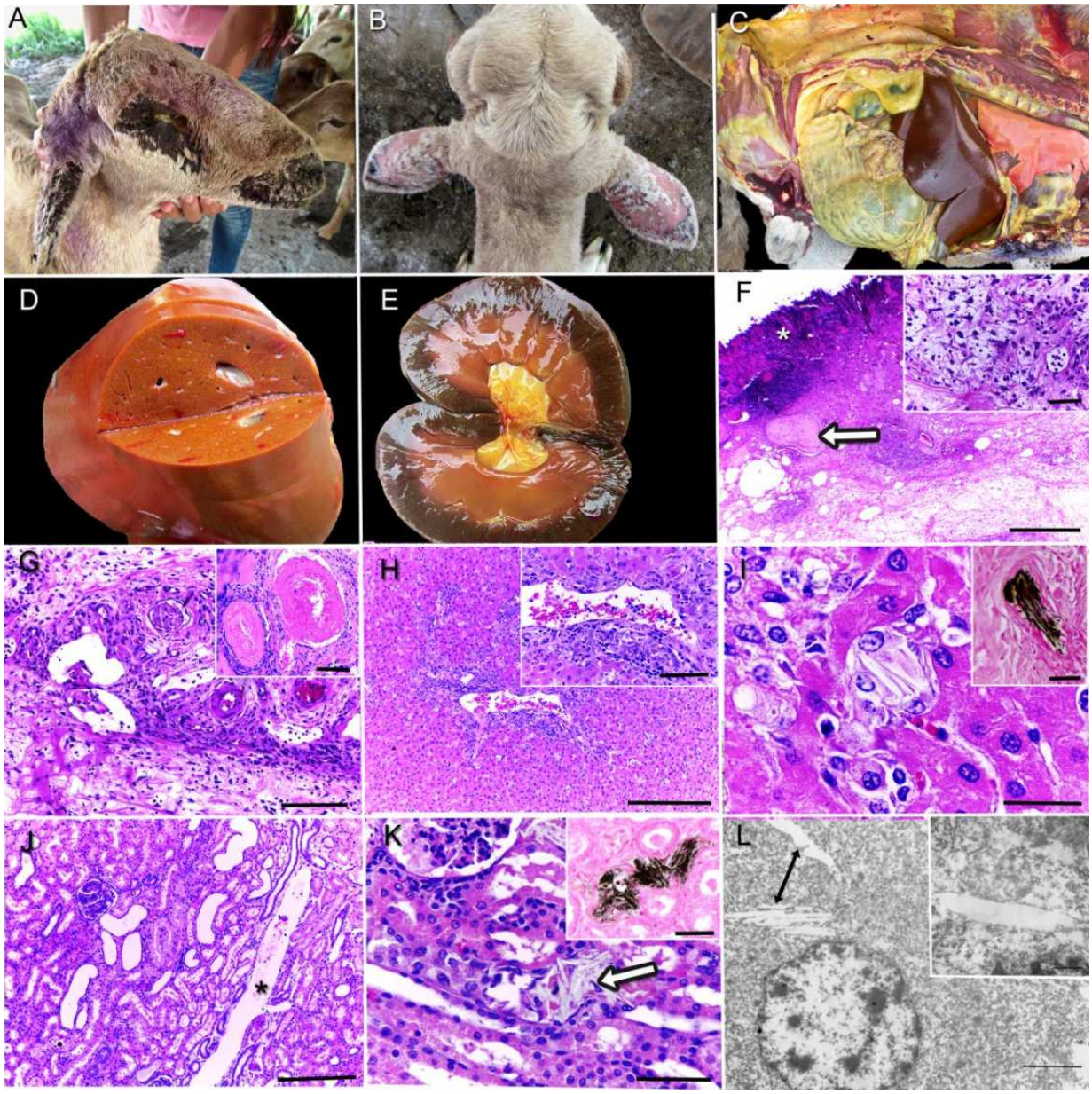

Figure 1. A. Head and neck. Extensive ulcerative and crusting dermatitis involving the periocular skin, nostrils, and lips. **B**. Ears. Bilateral loss of hair (alopecia) on the dorsal surface of the ears. Also, the skin appears red (hyperemic) and contains some exudate. **C.** Thoracic and abdominal viscera. Extensive jaundice of the subcutaneous tissue, pericardium, and peritoneum. Also, the hepatic capsule appears smooth. **D.** Liver, cut section. Orange-yellow discoloration of the hepatic parenchyma, but the liver capsule is otherwise unremarkable. **E.** Kidney, cut section. Brown discoloration of the cortex and medulla and the renal pelvis appears icteric. **F.** Skin. Extensive ulceration and crusting of the epidermis (asterisk) and a fibrin thrombus in the vasculature of the dermis (arrow). Inset: edematous separation of the dermal collagen fibers with severe necrosis and neutrophilic infiltration. Hematoxylin and eosin. Bar = 50 µm. **G.** Skin. Lymphocytes and neutrophils are infiltrating the blood vessels and perivascular spaces. Also, there is an edematous separation of the dermal connective tissue. Inset: The walls of the blood vessels in the dermis are thickened and eosinophilic. Hematoxylin and eosin. Bar = 200 µm. **H.** Liver. Increased cellularity of the periportal areas. Inset: Lymphocytes and plasma cells are infiltrating the portal veins and biliary ducts. Hematoxylin and eosin. Bar = 100 µm. **I.** Liver. Crystals embedded in the hepatic cords. Hematoxylin and eosin. Inset: These crystals stained positive for calcium. Von Koss stain. Bar = 25 µm. **J.** Kidney. Note distended tubules some of which contains exfoliated cells and cellular debris (asterisk). **K.** Kidney. Crystals embedded in the tubular cells and interstitium (arrow). Hematoxylin and eosin. Inset: These intracytoplasmic crystals stained positive for calcium. Von Koss stain. **L.** Liver. Two crystals in the cytoplasm of a hepatocyte (double-headed arrow). TEM; uranyl acetate and lead citrate. HV = 60kV. Bar= 2 µm. Inset: Close-up of intracytoplasmic crystal. TEM; Bar= 500 nm.

accumulate in the skin, cornea, and/or mucoid membranes and become activated by the UV sunlight (1, 12, 13, 16). According to the pathogenesis, there are three distinct types of photosensitization: type-I also referred to as primary photosensitization occurs when ruminants ingest plants rich in preformed photodynamic substances (8, 21). Type II is inherited and develops because of a defect in the synthesis and metabolism of endogenous photodynamic agents, like blood porphyrins in congenital porphyria (12). There is an inherited ovine form, but it happens in Corriedale sheep, not in the Pelibuey or mixed breed reported here (12). Finally, type III photosensitization, better known as hepatic or hepatogenous photosensitization, occurs in ruminants when underlying liver diseases impairs the metabolism and excretion of ingested (exogenous) phytoporphyrins, a derivative from plant chlorophyll (1, 6, 7, 8). Hepatogenous photosensitization is by far the most pervasive in ruminants worldwide (6, 14, 15, 22), and it fits well with our findings since affected sheep had the underlying liver disease caused by ingestion of *Brachiaria* spp.

The toxic principle in *Brachiaria* spp., protodioscin is produced when saponins are deglycosylated by the rumen flora (3, 23). Protodioscin targets specifically hepatocytes and biliary cells causing a crystal-associated cholangiohepatopathy (3, 7, 18). Damaged hepatocytes and biliary cells, as observed in the sheep in Mexico, have reduced capacity for hepatic excretion of phytoporphyrins, which quickly concentrate in the dermal tissue (12). Once in the skin, phytoporphyrins becomes activated by sun ultraviolet (UV) light causing epidermal necrosis through the local generation of free radicals that lead to mast cell degranulation and the release of inflammatory mediators (7, 8, 9, 12). The yearly UV index for the region in Colima is seldom less than +5, and in the summer this index can reach as high as +12. The distribution of cutaneous lesions in the sheep was typical of ruminants photosensitization where the skin poorly pigmented or having little wool is affected when exposed to the sunlight (4, 9, 11). The epidermal necrosis, edema, fibrinoid arteritis, and thrombosis were also consistent with those changes described for *Brachiaria* spp. toxicity elsewhere (1). It should be noted, however, that histopathologically, all forms of photodynamic dermatitis show similar lesions, irrespectively of the poisonous plant. One characteristic feature of ovine hepatogenous photosensitization is the edematous swelling of the head and face, colloquially referred to as "facial eczema or swollen head" (21). According to some reports, photosensitization becomes apparent 10 to 21 days after sheep graze *Brachiaria* spp. (15). This timeline between initial pasturing and clinical signs is in agreement with the history for sheep in farm B, but not entirely for Farm A. It is conceivable that sheep in Farm A ingested pastures other than *Brachiaria* spp., and therefore the levels of saponins were lower, creating a time delay in hepatotoxicity and photosensitization. Another possible explanation is an adaptive resistance to the effect of the saponins as reported for *Brachiaria* poisoning in sheep (5).

The gross and microscopic lesions in the liver of affected sheep were consistent with those previously described in natural and experimental *Brachiaria* spp. toxicity (1, 7, 9). Although mycotoxins like sporidesmin, fumonisin, or phomopsin can also cause hepatogenous photosensitization in sheep (12, 21, 22), there was no evidence of moldy feed or history of phytomycotoxicosis in the two farms.

Histologically, the biliary fibrosis with lymphoplasmacytic infiltrates and crystal formation was consistent with the hepatic lesions reported in *Brachiaria* toxicity (7, 10). The crystal-associated cholangitis is so remarkable that in the early literature, *Brachiaria* toxicosis was also called "crystal-associated hepatogenous photosensitization disease" (17). The pathogenesis for the lithogenic formation of crystals starts in the ruminal digestion where the saponins of *Brachiaria* spp. convert into β-D-glucuronides and steroidal sapogenins compounds, which precipitate into crystals in the presence of calcium (17, 18, 22). The ultrastructural changes, mainly, the presence of cleft-shaped crystalline structures in the liver and kidney were consistent with earlier reports (1).

According to several reports, not all ruminants in the herd are equally affected when fed *Bracharia* spp. (1,6, 11). Genetics and continuous exposure to this grass make animals more resilient to toxicity (11), and young sheep are more vulnerable than older ones (1). All these considerations could explain why not all the sheep in the two Mexican flocks fed *Brachairia* spp. were equally affected.

The green discoloration of the kidneys observed at necropsy, and the nephrosis and crystals in the tubules and interstitium seen microscopically were consistent with the renal changes previously reported in sheep after natural and experimental ingestion of *Brachiaria* spp. (1, 3, 10). This tropical grass causes renal lesions directly by the nephrotoxic effect of the saponins, or indirectly, by the hyperbilirubinemia of liver disease called cholemic nephrosis (2, 10). The overall clinical significance of the renal lesions in the sheep intoxicated with *Brachiaria* spp. is probably less critical than the dermal and hepatic lesions.

The clinical signs, biochemistry findings, as well as the gross and microscopic lesions in liver, kidney, and skin were the basis for the definitive diagnosis of *Brachiaria* toxicity (4). However, farmers and veterinarians in countries where this plant is not well known, like Mexico, should be fully aware that *Brachiaria* spp. represents a significant risk for hepatic photosensitization.

Conflict of interest

The authors declare that they have no conflicts of interest.

References

1. Assumaidaee AAM, Mustapha NM.Toxicity of signal grass (*Brachiaria decumbens*): a review article. J Adv Med Res. 2012;2:18-39.
2. Breshears M, Confer AW. The urinary System. In: Zachary JF, editor. Pathologic Basis of Veterinary Disease. 6th ed. St. Louis, Missouri: Elsevier; 2017. p. 617-81.
3. Brum KB, Haraguchi M, Lemos RAA, Riet-Correa F, Fioravanti MCS. Crystal-associated cholangiopathy in sheep grazing *Brachiaria decumbens* containing the saponin protodioscin. Pesq Vet Bras. 2007;27:39-42.
4. Cardona-Álvarez J, Vargas-Vilória M, Paredes-Herbach E. Clinical and histopathological study of the phototoxic dermatitis in Zebu calves in grazing of *Brachiaria decumbens*. Rev MVZ Córdoba. 2015;21(2):5366-80.
5. Castro MB, Gracindo CV, Landi MFA, Cabral Filho SLS, Resende Filho NJ, Lima EMM, Riet-Correa F. Sheep adaptation management, and investigation of inherited resistance to prevent *Brachiaria* spp. poisoning. Small Rumin Res. 2018;158:42-7.
6. Chen Y, Quinn JC, Weston LA. Loukopoulos P. The aetiology, prevalence and morbidity of outbreaks of photosensitisation in livestock: A review. Plos One, 2019;14(2):e0211625.
7. Cruz C, Driemeier D, Pires VS, Schenkel EP. Experimentally induced cholangiohepatopathy by dosing sheep with fractionated extracts from *Brachiaria decumbens*. J Vet Diagn Invest. 2001;13:170-2.
8. Cullen JM, Stalker MJ. Liver and biliary system. In: Maxie MG, editor. Jubb, Kennedy, and Palmer's Pathology of Domestic Animals. 6th ed. Vol 2. St. Louis, Missouri: Elsevier; 2016. p. 258-352.
9. Driemeier D, Colodel EM, Seitz AL, Barros SS, Cruz CEF. Study of experimentally induced lesions in sheep by grazing *Brachiaria decumbens*. Toxicon. 2002;40(7):1027-31.
10. Faccin TC, Riet-Correa F, Rodrigues FS, Santos AC, Melo GK, Silva JA, Ferreira R, Ítavo CC, Lemos RA. Poisoning by *Brachiaria brizantha* in flocks of naïve and experienced sheep. Toxicon. 2014;82:1-8.
11. Gracindo CV, Louvandini H, Riet-Correa F, Barbosa-Ferreira M, Castro MB. Performance of sheep grazing in pastures of *Brachiaria decumbens*, *Brachiaria brizantha*, *Panicum maximum*, and *Andropogon gayanus* with different protodioscin concentrations. Trop Anim Health Prod. 2014;46(5):733-7.
12. Hargis AM, Myers S. The integument: disorders of physical, radiation, or chemical injury. In: Zachary JF, editor. Pathologic Basis of Veterinary Disease. 6th ed. St. Louis, Missouri: Elsevier; 2017. p. 1009-146.
13. Hussain SM, Herling VR, Rodrigues PHM, Naz I, Khan H, Khan MT. Mini review on photosensitization by plants in grazing herbivores. Trop Anim Health Prod. 2018;50(5):925-35.
14. Kellerman TS, Coetzer JA. Hepatogenous photosensitivity diseases in South Africa. Onderstepoort J Vet Res. 1985;52:157-73.
15. Low SG. Signal grass (*Brachiaria decumbens*) toxicity in grazing ruminants. Agriculture. 2015;5(4):971-90.
16. Mauldin EA, Peters-Kennedy J. Integumentary system: actinic diseases of the skin. In: Maxie MG, editor. Jubb, Kennedy, and Palmer's Pathology of Domestic Animals. 6th ed. Vol. 1, St. Louis, Missouri: Elsevier; 2016. p. 575-80.
17. Meagher LP, Wilkins AL, Miles CO, Collin RG, Fagliari JJ. Hepatogenous photosensitization of ruminants by *Brachiaria decumbens* and *Panicum dichotomiflorum* in the absence of sporidesmin: lithogenic saponins may be responsible. Vet Hum Toxicol. 1996;38:271-4.
18. Melo GKA, Ítavo CCBF, Silva JA, Monteiro KLS, Faccin TC, Pupin RC, Heckler RF, Ítavo LC, Silva PCG, Leal PV, Lemos, RAA. Poisoning by *Brachiaria* spp. in suckling lambs supplemented and unsupplemented in a creep-feeding system. Small Rumin Res. 2018;158:30-4.
19. Miles CO, Wilkins AL, Erasmus GL, Kellerman TS. Photosensitivity in South Africa. VIII. Ovine metabolism of *Tribulus terrestris* saponins during experimentally induced geeldikkop. Onderstepoort J Vet Res. 1994;61:351-9.
20. Panter KE, Gardner DR, Lee ST, Pfister JA, Ralphs MH, Stegelmeier BL, James LF. Poisonous plants. In: Gupta RC, editor. Veterinary Toxicology Basic and Clinical Principles. 2nd ed.; Elsevier: London; 2012. p. 825-72.
21. Rowe LD. Photosensitization problems in livestock. Vet Clin North Am Food Anim Pract. 1989;5(2):301-23.
22. Smith BL, Miles CO. A Role for *Brachiaria decumbens* in hepatogenous photosensitization of ruminants?. Vet Hum Toxicol. 1993;35(3):256-7.
23. Wina E, Muetzel S, Becker K. The impact of saponins or saponin-containing plant materials on ruminant production - A review. J Agric Food Chem. 2005;53(21):8093-105.