



## Case Report

# Acute Cecal Tympany During Chemical Restraint in Free-Ranging Capybara (*Hydrochoerus hydrochaeris*) - Iatrogenic Cause and Treatment

Derek A. Rosenfield<sup>1\*</sup>, Mario A. Ferraro<sup>2</sup>, Priscila R. Yanai<sup>2</sup>, Claudia Igayara<sup>3</sup>, Cristiane S. Pizzutto<sup>1</sup>

<sup>1</sup>Department of Animal Reproduction/Wildlife, School of Veterinary Medicine and Animal Science, University of Sao Paulo, Sao, Paulo, Brazil.

<sup>2</sup>Department of Animal Surgery, School of Veterinary Medicine and Animal Science, University of Sao Paulo, Sao, Paulo, Brazil.

<sup>3</sup>Municipal Zoo, Guarulhos, São Paulo, Brazil.

\*Corresponding author: E-mail: dro@usp.br

Submitted May, 28<sup>th</sup> 2019, Accepted September, 10<sup>th</sup> 2019

## Abstract

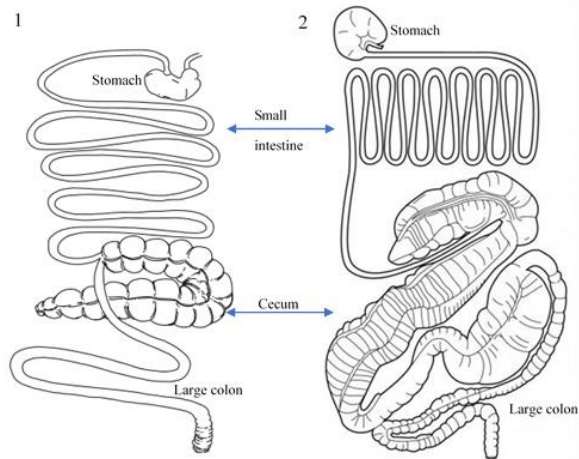
The occurrence of acute tympany, probable cause and treatment are being discussed for the first time in *Hydrochoerus hydrochaeris*, commonly known as the capybara. As part of a capybara population control study, adult male and female (n=18), prior to intervention, were physically confined and subsequently chemically immobilized with a ketamine dexmedetomidine (KD) association. Procedures included health exams, biomaterial collection, and ID markings. For surgical events, the animals were maintained under volatile anesthesia with Isoflurane. One animal, during anesthetic recovery, developed tachycardia and tachypnea, with cyanotic mucosa, and a low SPO<sub>2</sub>. During auscultation and percussion/palpation a taut abdominal wall was recognized. Shortly thereafter, the animal suffered a cardiorespiratory arrest and failed resuscitation. Immediately performed necropsy suggested death by acute respiratory and circulatory failure due to exerted pressure against the diaphragm and compression of major blood vessels, leading to hypoxia and hypovolemic shock, secondary to cecal dilation. Three animals under general anesthesia demonstrated moderate bloating and were treated by trans-abdominal catheterization for cecal decompression, successfully preventing any potential development of severe tympany. Conclusion: During chemical restraint all animals demonstrated bloat of varies degrees, suggesting iatrogenic cause brought about by adverse effects of anesthetic agents. Acute cecal tympany in sedated capybaras must be anticipated and closely monitored to prevent fatal outcome. Trans-abdominal catheterization into the cecum proved effective in treating bloat.

**Key words:** bloating, cecal decompression, trans-abdominal catheterization, rodent, anesthesia.

## Introduction

Mammals carry an active population of micro-organisms (bacteria, fungi, and protozoa) in their digestive tract, especially in herbivores, these organisms are necessary to the breakdown of fibrous vegetation, aiding in the extraction and synthesis of nutrients (9). Capybaras are hindgut, - or cecal fermenters (14), same as rats, guinea pigs, rabbits, and horses. The later, used to compare with capybara (Fig. 1) on the basis of tympany/bloat occurrence and comparable treatments. As part of a micro-organism

driven fermentation process, large quantities of gas are produced, that under normal conditions, is expelled continuously, either through eructation and/or through peristalsis-enabled flatulence. However, in hindgut fermenters, gas is only liberated by flatulence. Especially capybaras, as semi-aquatic species are obligatory nose-breather (13), have a number of particular anatomic differences when it comes to the vomitus and eructation, including an atypical emetic reflex, which makes it impossible to vomited, nor eruct, similar to equines (4, 8).



**Figure 1.** 1) Capybara digestive tract: stomach:  $\pm 2$  L; Sm intestine:  $\pm 10$  m; Cecum:  $\pm 5$  L; Lg. colon:  $\pm 1,2$  m. 2) Equine digestive tract: stomach: 10 L; Sm intestine (jejunum) 19.5 m; Cecum:  $\geq 30$  L; Lg. colon:  $\geq 7$  m. Graphic credit (1) Luis Miguel Márquez, in Moreira et al. 2013, adapted. (2) KPPUSA. 2019, adapted.

The terms tympany, bloat or bloating, meteorism, acute abdominal dilation/distention are terms that are used interchangeably in the literature, whereas the term tympany, in conjunction with a specific anatomic structure, may describe dilated organs, species, and/or age involved. I.e.: abomasal tympany, used to define accumulation of gas in the abomasum (fourth stomach of a ruminant), common in calves (10), or ruminal tympany (the first stomach of a ruminant), both are specific for species with foregut or ruminal fermentation. In hindgut, or cecal fermenters, terms commonly used are cecal tympany, gastric bloat, - tympany, - or dilation, also used for other monogastric species, including carnivorous.

All terms refereeing to potentially life-threatening gastrointestinal emergencies, involving several species, as reported in the literature (3, 10–12, 15, 16).

The etiology involved in acute cecal tympany (ACT), the term used in this report to specifically describe the excessive accumulation of gas within the capybara's cecum, similar to cecal tympany in horses. However, the causes differ.

Whereas in equines the condition might be related to digestive tract diseases, parasitism, ingestion of improper types or quantities of food or sand, among others, causing impaction or volvulus, as well as being of iatrogenic nature, potentially incited during anesthesia (1, 5, 22). The latter, actually being the investigated reason for ACT in capybaras.

Acute cecal dilation is diagnosed by identifying a taut abdominal wall through palpation and performing a sharp finger percussion over the mesogastric region, including its corresponding lateral abdominal areas. The excessive gas filled cecum exerts pressure on all

surrounding structures and organs, compressing and strangulating large blood vessels, liver and spleen, while obstructing the diaphragm's mobility, reducing intrathoracic space for lung and heart movement, compromising the cardiovascular and respiratory system, reflected by tachycardia and dyspnea respectively, cyanotic mucous membranes, sharp drop in SPO<sub>2</sub> %, and an increases capillary refill time.

Since reports on cecal disease in capybara and potential emergency procedures have never been published, no literature reference could be provided.

The purpose of this study was to report the occurrence of acute cecal tympany by examining the potentially iatrogenic etiology involved, such as adverse anesthetic effects, concurrent to the inevitable lack of pre-event fasting, and the use of sugar-rich bait. Furthermore, it was the intend to describe a treatment method of cecal decompression to alleviate bloat and to prevent acute cecal tympany in capybaras.

### Case Report I – Cecal dilation under anesthetic effects

As part of a larger research project on capybara population control, 18 adult capybaras (males n=8 / females n=10), prior to chemical restraint, were physically confined (Table 1). This project was approved by the Ethics Committee on Animal Use in Science, School of Veterinary Medicine and Animal Science, University of Sao Paulo, CEUA: 9553260816, and by the Brazilian Ministry of the Environments, Institute of Biodiversity Conservation Chico Mendes, SISBio: 54634-2.

The anesthetic protocol employed was an association of Ketamine Hydrochloride 10%, injectable, dosage 9 mg kg<sup>-1</sup> (Syntec, Brazil), and Dexmedetomidine Hydrochloride, 0.005 mg kg<sup>-1</sup>, injectable (Dexdomitor, Zoetis, Brazil), administered remotely as a single-dose (vol. 7mL, type P dart, and X-Caliber CO<sub>2</sub> projector, Pneu-Dart, Inc. Pennsylvania, USA). The alpha-2 reversal agent, Atipamezole, 0.005 mg kg<sup>-1</sup> (Antisedan, Zoetis, Brazil), was administered via hand syringe (n=5), after the animals returned into the corral for anesthetic recovery.

Continuous vital sign monitoring for non-invasive procedures was performed using an oximeter (ARSTN, China), and during general anesthesia a DX 2022+ Multiparameter Monitor (Dixtal – Philips Healthcare, Brazil).

Normal vitals: heart, - respiratory rate, and body temperature (Table 2), used as reference values, were taken from animals not under anesthetic effects, by direct auscultation, palpation, and observation. Body temperature was measured with an infrared thermometer (Digital Laser, Model KP-8005, Knup, Brazil), knowing that the result is not as accurate as a rectal inserted thermometer, thus, serving as an approximate value.

**Table 1.** General overview – affected animals (n = 18).

# Animals	Signs of tympany	Treatment	Outcome
n = 1	ACT*	n/a	n = 1 expired
n = 2	Moderate bloat	Catheterization	Cecal depression, abdominal contour returned to normal; initial vital signs of elevated heart/respiratory rate, SpO <sub>2</sub> drop, rapidly returned to normal. Acute tympany prevented, further bloat avoided, n = 2 survived
n = 15	Mild bloat	n/a	No intervention necessary, n = 15 survived

\*ACT (acute cecal tympany)

The animal, after achieved sedation, defined as the time of lateral recumbency without response to physical manipulation (palpebral reflex), was brought to the field clinic for general procedures (biometry, collection of biomaterials, and ID marking), and weight, using a digital hanging weighing scale (Mini Digital Crane Scale 300 kg, Outmate, China). For surgical procedures, such as gonadectomy, the animal was maintained under general anesthesia, using Isoflurane (mean period 50 ± 20min.).

All animals showed changes in the vital signs to various degrees: Increase of the heart rate (>70b/m); Increase in the respiratory rate (> 30 b/m), and SPO<sub>2</sub> drop (< 92%), concomitant to a tympany onset, identified by representing a slight taunt/dilated abdomen, loss of rib-cage contour.

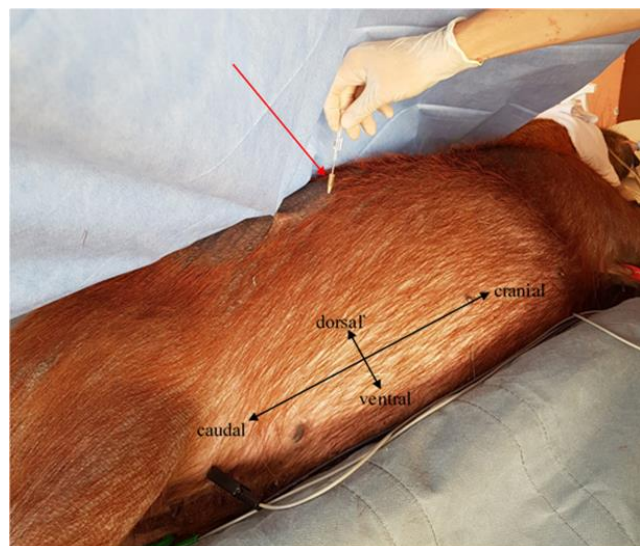
**Table 2.** Normal vital signs.

Heart rate (resting/low activity) (beats per minute)	Respiratory frequency (breath per minute)	Body temperature* (°C)
80 ± 8	40 ± 4	36,0 ± 3

Original reported vital signs of *H. hydrochaeris*, taken from non-sedated animals, during routine conditioning training. Activity intensity: resting/low. \*Body temperature measure with digital laser pointed into outer ear canal).

Animals, with change of vital signs and onset of abdominal distention was evident, as a preventive measure, were prepared with a 70% alcohol or a povidone-iodine solution and cleaned with gazes, prior to catheterization. Following, a gauge 14 catheter (14Gx2 Safelet, Nipro Medical, LTDA, Brazil) was placed percutaneously through the abdominal wall into the cecum (fig. 2). The same procedure as used in severe tympany intervention. The site of catheterization was identified by performing a finger percussion (tapping), noting tympanitic (drum-like) sounds typical for air-filled intestinal structures, compared to a dull sound of a solid or liquid-filled area (6).

Successful pressure relief was confirmed by the sudden presence of an intensive fermentation smell and improved vital signs. After the procedures, the cannula was removed, followed by a simple superficial wound treatment.



**Figure 2.** Lateral view. Red arrow: Cecal decompression by trans-abdominal catheterization, with a large diameter cannula (G14), alleviating the gas pressure from the caecum, preventing potential acute tympany/death, in a prior surgically prepared site.

## Case Report II - Acute cecal tympany (severe abdominal distention)

After executed procedures, one male capybara was returned into the corral for anesthetic recovery and positioned in lateral recumbency. Subsequently, 0,07 mL Atipamezole was administered with the intent to revert the Dexmedetomidine effects. Within ten minutes the animal attempted to get up on its feet and walk around. However, motor discoordination made the animal fall over several times and finally remained in a lateral recumbency. Hemodynamic monitoring showed the heart rate in beats/minute (HR > 90 b/m), tachypnea, with a flat respiratory movement, measured in breath/minute (RR > 80b/m), a peripheral capillary oxygen saturation (SPO<sub>2</sub> < 92 %), cyanotic mucous membranes, and a refill time (CRT) of > 4 seconds. Within minutes, the animal went into cardiorespiratory arrest after failed resuscitation attempts.

### Post-mortem necropsy findings

Immediately performed necropsy provided clear evidence of an extensive dilated cecum that quickly forced its way out of the abdominal cavity after incision (Fig. 3). Lifting the cecum, exposed the underlying viscera, with evidently altered appearance. Macroscopic diagnosis was severe dilation of the cecum and intestines due to accumulated fermentation gas. In turn, provoking compression of surrounding organs, resulting in severely congested and hypoxic mesenteric and intestinal blood vessels (Fig. 4). During examination, no evidence of volvulus or torsion was found.

This project was approved by the Ethics Committee on Animal Use in Science, School of Veterinary Medicine and Animal Science, University of Sao Paulo, CEUA: 9553260816, and by the Brazilian Ministry of the Environments, Institute of Biodiversity Conservation Chico Mendes, SISBio: 54634-2.

## Discussion

In capybaras, recognizing acute cecal tympany is not as straightforward, but diagnosis and preventive monitoring are relatively simple and fast to execute. In these case reports, ACT was considered a secondary condition, with its etiology believed to be of iatrogenic nature.

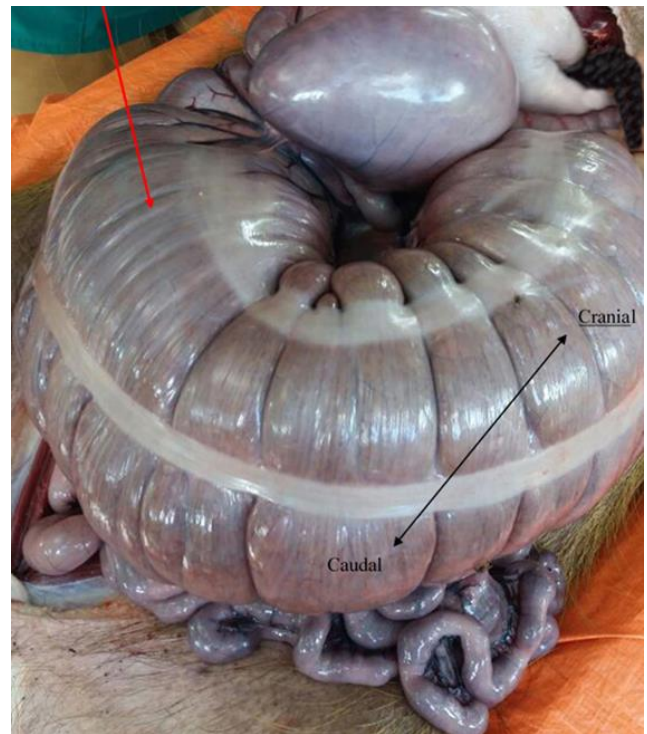Under controlled conditions, any animal about to be anesthetized should undergone minimum fasting of 6 to 12 hours, with the intent to prevent potential colic, caused by free gas formation (16). However, working with free-ranging wildlife, this preventive technique is often difficult if not impossible to implement.

As reported in several studies and species (17-19, 22), using anesthetic agents for chemical restraint or to maintain the animal anesthetized during procedures,

bloating is a common occurrence. Brought about by known adverse effects of some of the anesthetic agents used, primarily the decrease in intestinal motility, interfering with peristalsis, consequently losing the capability to eliminate excessive gas, as the findings of this report can collaborate.

In capybaras, the initial signs are rather insidious and mild. Although severe cecal dilation is associated with intensive pain, capybaras, during anesthetic recovery, did not vocalize any discomfort.

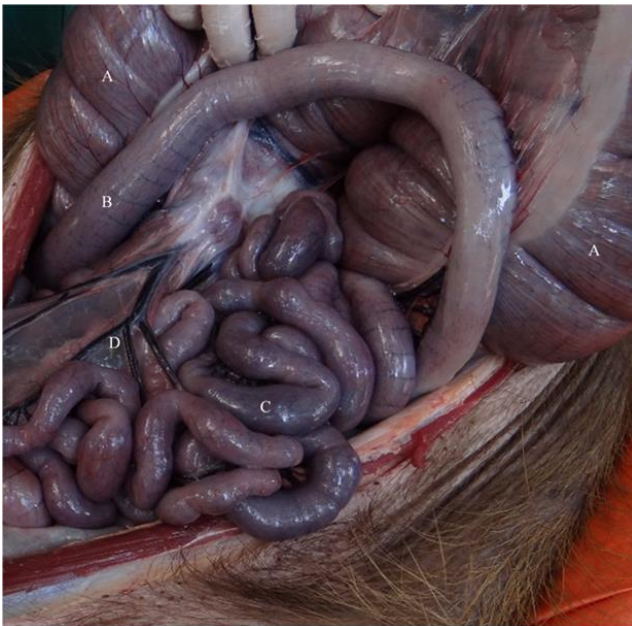Anticipating ACT, closely monitoring of the vital signs (Fig. 5), observing the subtle disappearance of the ribcage-contour, caused by the expansion of the abdominal volume, and confirmation of tympany by abdominal percussion and palpation will allow recognizing the right moment for intervention.



**Figure 3.** Ventral view: Red arrow, depicting a pale extremely dilated cecum due to excessive gas formation. Cecal curvature in caudal direction.

### Anesthetic Reversal - Atipamezole - Alpha-2 antagonist

Atipamezole (Antisedan, Zoetis, Brazil) was administered in 5 animals, in a 1:1 dosage (0,7mL IM). Time from lateral recumbency to being on four feet was relatively fast (mean 18 minutes), nevertheless, the animal was not considered fully recovered, as maintained anesthetic effects were observed, chiefly ataxia, disorientation, intermittent falls. Even with the antagonist, time to full recovery exceeded 40 minutes (Fig. 6).



**Figure 4.** Ventral view: Open abdominal cavity, showing the increased volume of the cecum with intestinal and mesenteric congested and hypoxic blood vessels (purple discoloration). A. cecum; B. colon segment; C. sm. intestines; D. congested mesenteric blood vessels.

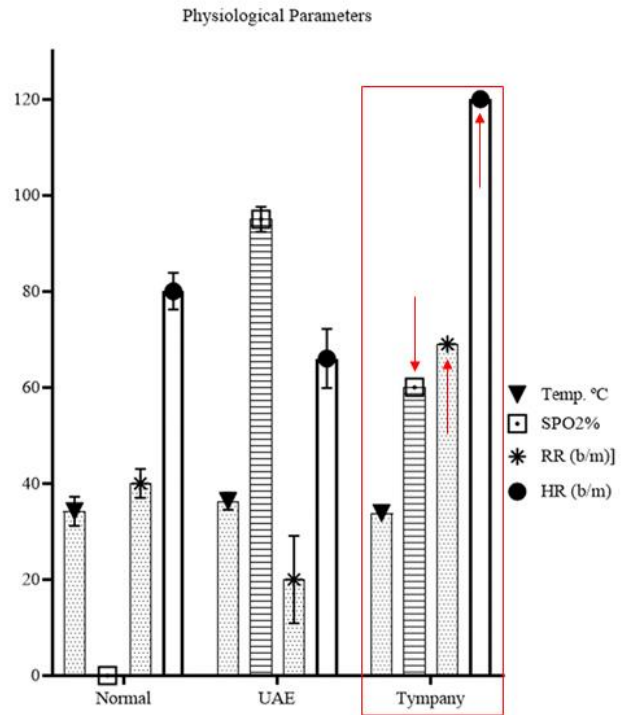
### Treatment

Cecal Decompression is a routine emergency procedure in horses, as previously described (21). The relatively simple and quick technique provided immediate improvements in the vital signs and lessening of the abdominal volume. Although no adverse effects from the procedure were observed postoperatively, attention should be paid to potential complication such as septic peritonitis (17).

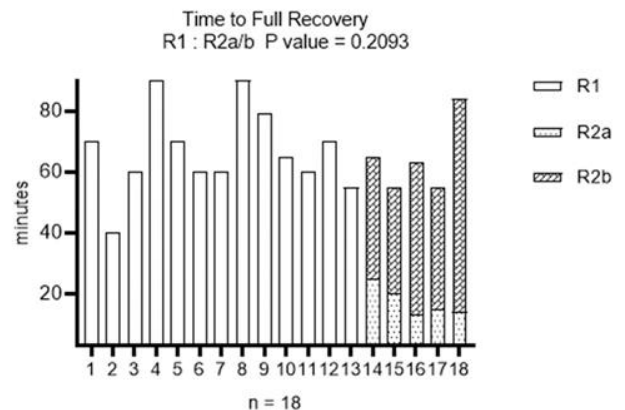
Using this technique as a routine preventive procedure, when working with anesthetized capybaras, deserves consideration. Nevertheless, more research is required to confirm any associated long-term consequence.

The other major contributing factor to acute cecal tympany is baiting and luring with high-sugary plants capybaras (private information, 2018). As fasting is not possible under field condition, the offered quantities must be held to an absolute minimum, not allowing for any real consumption in order to minimize intensive fermentation and excessive gas development.

When working with capybaras, where procedures include the necessity of chemical restraint, it is imperative for the medical professionals to anticipate ACT and are aware of cecal tympany symptoms, preventing therefore, any development into an acute condition, thus, avoiding any potential death.



**Figure 5.** Vital parameter comparison. Findings show significant vital sign differences between animals under normal condition (no anesthetic effects), animals chemically restrained (under anesthetic effects/UAE), and sedated animals, suffering acute cecal tympany, with red arrows indicating crucial vital parameter alterations. During the process from bloating to acute cecal tympany, heart rate and respiratory rate increased drastically, accompanied by a sharp SPO<sub>2</sub>% drop. \*Normal SPO<sub>2</sub> values are not available from conscious animals.



**Figure 6.** Comparing anesthetic recovery times, with and without the administration of Atipamezole as the reversal agent.

## Acknowledgements

We thank the Pneu-Dart, Inc. for their cooperation and material contributions. The project was funded by FAPESP, Sao Paulo, Brazil.

## References

1. Abutarbush SM, Carmalt JL, Shoemaker RW. Causes of gastrointestinal colic in horses in western Canada: 604 cases (1992 to 2002). *Can Vet J.* 2005;46(9):800-5.
2. Bailey PA, Hague BA, Davis M, Major MD, Zubrod CJ, Brakenhoff JE. Incidence of post-anesthetic colic in non-fasted adult equine patients. *Can Vet J.* 2016;57(12):1263-6.
3. Bowen R. Biomedical Hypertextbooks. Colorado State University. Digestive System. Pathophysiology. Herbivores. Ruminant Tympany (Bloat) [Internet]. [Cited 2019 May 2]. Available from: <http://www.vivo.colostate.edu/hbooks/pathphys/digestion/herbivores/tympany.html>.
4. Budras K-D, Sack WO, Rock S. *Anatomy of the Horse: An Illustrated Text.* Schlütersche Hanover; 2003. 135 p.
5. Dart AJ, Dowling BA, Hodgson DR. Caecal disease. *Equine Vet Educ.* 1999;11(4):182-8.
6. Duguma A. *Practical Manual on Veterinary Clinical Diagnostic Approach.* J Vet Sci Technol. 2016;7(4):1-10.
7. Herbert MK, Ritter M, Holzer P, Roewer N. Midazolam-induced inhibition of intestinal peristalsis in the guinea-pig ileum is not mediated through the benzodiazepine-binding site at the GABA<sub>A</sub>-receptor. *Eur J Anaesthesiol EJA.* 2002;19(3):220.
8. Horn CC, Kimball BA, Wang H, Kaus J, Dienel S, Nagy A, et al. Why Can't Rodents Vomit? A Comparative Behavioral, Anatomical, and Physiological Study. *PLOS ONE.* 2013;8(4):e60537.
9. Karasov WH, Douglas AE. Comparative Digestive Physiology. *Compr Physiol.* 2013;3(2):741-83.
10. Kümper H. New therapy for acute abomasal tympany in calves. *Tierarztl Prax.* 1994;22(1):25-7.
11. Majak W, McAllister TA, McCartney D, Stanford K, Cheng K-J. Bloat in Cattle. *Alberta Agriculture and Rural Development;* 2003:1-28.
12. Martinez-Pereira MA, Franceschi R da C, Coelho BP, Fünkler G da R, Zancan DM. Experimental model of tympanic colic (acute abdomen) in chinchillas (*Chinchilla lanigera*). *Lab Anim Res.* 2014;30(3):136-41.
13. Miller RE, Fowler ME. *Fowler's Zoo and Wild Animal Medicine, Volume 8 - E-Book.* St. Louis: Elsevier Health Sciences; 2014, 793 p.
14. Moreira JR, Ferraz KMPMB, Herrera EA, Macdonald DW, editors. *Capybara: Biology, Use and Conservation of an Exceptional Neotropical Species.* New York: Springer; 2013, 419 p.
15. Olaifa A, Oguntoye C. Type i free gas bloat vagal indigestion in a 10-month old west African dwarf goat: a case report. *Int J Med Rev Case Rep.* 2017;1:35-45.
16. Rahman MM, Bhuiyan MMU, Islam MT, Shamsuddin M. Efficacy of simethicone for treatment of bloat in ruminants. *Asian J Med Biol Res.* 2016;2(4):635-8.
17. Rakestraw PC, Hardy J. Chapter 37 - Large Intestine. In: Auer JA, Stick JA, editors. *Equine Surgery (Fourth Edition).* Saint Louis: W.B. Saunders; 2012. p. 454-94.
18. Tanila H, Kauppila T, Taira T. Inhibition of intestinal motility and reversal of postlaparotomy ileus by selective  $\alpha$ 2-adrenergic drugs in the rat. *Gastroenterology.* 1993;104(3):819-24.
19. Torjman MC, Joseph JI, Munsick C, Morishita M, Grunwald Z. Effects of Isoflurane on gastrointestinal motility after brief exposure in rats. *Int J Pharm.* 2005;294(1):65-71.
20. Unger L, Fouché N, Schnider D, Witte S. Peritonitis, abscessation and haemorrhage: Complications of transcutaneous caecal decompression. *Equine Vet Educ.* 2014;26(8):430-5.
21. Winsborg Y. Caecal decompression in horse, effects and complications [Internet] [Master's Dissertation]. [Copenhagen]: University of Copenhagen; 2014.
22. Zullian C, Menozzi A, Pozzoli C, Poli E, Bertini S. Effects of  $\alpha$ 2-adrenergic drugs on small intestinal motility in the horse: An in vitro study. *Vet J.* 2011;187(3):342-6.