



Short Communication

Use of Giemsa staining for the immunohistochemical counterstaining in canine melanomas: an “old and forgotten” method

Tatiany L. Silveira¹, Emerson S. Veloso¹, Ivy N. N. Gonçalves¹, Enio Ferreira^{1*}

¹Department of General Pathology, Biological Science Institute, Federal University of Minas Gerais (UFMG), Belo Horizonte, Brazil.

*Corresponding author: E-mail: enioferreira@icb.ufmg.br

Submitted June, 25th 2019, Accepted November, 4th 2019

Abstract

Melanoma is a neoplasm originating from melanocytes and represents 7% of skin tumors and the most common in oral cavity of dogs. Melanoma may present melanocytic pigment in its cytoplasm in varying quantity and its characterization by immunohistochemistry (IHC) is challenging due to the use of chromogen diaminobenzidine (DAB) which itself produces a brown product what makes difficult to distinguish from melanin pigment in this technique. To demonstrate a reliable technique, the use of the Giemsa counterstaining was performed in the IHC of melanomas with different degrees of pigmentation for different cytoplasmic, membrane and nuclear markers. The modification in the IHC technique by the counterstaining of Giemsa allows observable differences under the microscope between melanic pigment (in a blue-green stain), while the DAB chromogen will be observed in brown. With this technique, the prognostic and predictive interpretation of markers in canine melanomas may be more reliable in definitions of clinical behaviors and in experimental analyzes.

Key words: Giemsa, immunodetection, melanin, pigmented neoplasm.

Harris hematoxylin has been conventionally used for the counterstain of diaminobenzidine (DAB) chromogen in immunohistochemistry (IHC) routine since the '80s, although there are some limitations for this dye according to the antibody, tissues, and the presence of pigment (7, 10). The melanin pigment is a limiting factor in melanoma's IHC because the melanin can reduce the signal-to-noise ratio of the immunoreaction if it is in the same cell as the antigen (Ag) examined (2). The melanin in the cytoplasm of macrophages or in melanoma cells can be mistaken because the pigment color is the same as DAB in the hematoxylin counterstain, and it can also interfere in the visualization of nuclear reactions, making the correct analyses uncertain and hinder accurate interpretation (7, 9). An alternative method is the use of potassium permanganate to block melanin, but the reaction can damage certain epitopes of the cells impairing the Ag immunoreaction (2). In these cases, using an alternative counterstain is necessary to improve visualization and

interpretation, which minimizes the chance of a wrong result (9, 10).

To overcome the melanin problem and increase the efficiency of melanoma's IHC diagnostic Kamino in 1991 replaced the hematoxylin with Azure B as counterstain; as a result, the melanin stained green or blue-green, and DAB product remain brown (4). The Giemsa stain solution is also a member of the Romanowski stain group and has been used for cytology diagnostic since 1904 when reported by Gustav Giemsa in the study of Plasmodia (1). The Giemsa utilization in melanoma's IHC counterstain was described by Ramos-Vara in 2005 since the Giemsa solution is more stable than Azure B (10). By this technique using the Melan-A antigen and the DAB chromogen, it is possible to differentiate the melanin pigment in melanocytes and melanophages, in green/blue-green, from the marked in brown. It is also possible with this counterstain to distinguish the neoplastic cells to

melanophages on inflammatory infiltrates routinely present in melanomas (11).

Melanoma represents 7% of malignant skin neoplasias in dogs, and it is the most common in oral mucosas and eyes, and the second in digits, with a variable quantity of melanin in the neoplastic cells cytoplasm (5, 12, 13). The Azure Blue counterstain in melanoma's IHC use to be used in some veterinary's pathology lab until the beginning of 2000's (9, 10). In human pathology labs the Giemsa counterstain technique has still been used in the diagnostic routine for melanocytic neoplasias with high diagnostic precision and reduction of misinterpretation (6, 8, 11).

For this study we performed the immunohistochemistry without the potassium permanganate to block melanin in melanoma's slides. Sections of 4 µm sections from formalin-fixed and paraffin-embedded (FFPE) tissues were stained with hematoxylin and eosin (H&E). Each sample was re-examined independently by two pathologists (E.F. and T.S.) to confirm the diagnosis according to the criteria of the International Histological Classification of Tumors of Domestic Animals established by the WHO (3). For immunohistochemistry, FFPE sections (4 µm thick) were prepared and the detection of Melan-A, PNL-2, COX-2, EGFR and Ki-67 was carried out by the streptavidin-biotin-peroxidase complex method with a commercial detection anti-mouse/anti-rabbit system (Novolink Polymer Detection Systems; Leica Biosystems, Newcastle upon Tyne, UK) according to manufacturer's instructions. Antigen retrieval was performed by Pascal® in citrate buffer pH 6,0 (DakoCytomation Target Retrieval Solution) in 125°C for 2 min, followed by cooling for 20 min at room temperature. All sections were incubated with the primary specific antibody: Melan-A (1:100 dilution, Clone A103; Dako, Glostrup, Denmark), Melanoma Antigen (1:100 dilution, Clone PNL2; Santa Cruz Biotechnology, Dallas, Texas, USA), COX-2 (1:80 dilution, Clone SP21; Thermo Fisher Scientific, Waltham, MA, USA), Ki-67 (1:50 dilution, Clone MIB-1; Dako, Glostrup, Denmark) and EGFR (1:50 dilution, Clone 31G7; Invitrogen, Waltham, MA, USA) for 18h at 4°C. The antibody reaction products were observed with the chromogen 3,3'-diaminobenzidine tetrachloride (DAB) at DAB diluent for 3 minutes. After a final washing in distilled water, the sections were counterstained with GIEMSA (for 30 minutes) dehydrated and mounted.

For the Giemsa counterstain, in the sequence of DAB chromogen, the slides should be washed in water for 5 minutes, after pulling off the water, the slides must be covered by diluted Giemsa at 20% (water-based) for 30 minutes. The excess of Giemsa should be removed and give the slides a quick bath (2-3 passages) in Acetic Acid at 1% (water-based). Sequentially, the slides should be washed in Absolute Alcohol 3 times and submerged for 1 minute in Isopropyl Alcohol and left to dry on the

incubator for 30 minutes. Slides should then be mounted according to laboratory routine. On the microscope the melanic pigment will appear in a blue-green stain, while the DAB chromogen will be observed in brown. We tested this counterstain technique in different kind of antibody with different types of labelling (cytoplasmic, nuclear and membrane) which resulted in good differentiation between the pigment and the markers (Fig. 1A-D).

We also tried the Permanent Red (PR) and Vina Green (VG) chromogens with the Giemsa counterstain but none of those presented satisfactory results like DAB. The VG has a similar marking to green pigment staining after Giemsa counterstaining and the PR chromogens technique is incompatible with Giemsa counterstaining because the chromogen loses its color after a significant time submerged in alcohol. Furthermore, we tried the PR and VG chromogens with hematoxylin and the slides presented a worse result when compared to DAB with Giemsa, as the differentiation from the pigment to chromogen was more difficult to identify (Fig. 1E-H). We have tried this method in our diagnostic service and also in the research projects carried out in the Laboratório de Comportamento Celular (LCC) and also on Laboratório de Patologia Comparada (LPC) from Pathology Department of Universidade Federal de Minas Gerais.

The Giemsa counterstain to melanocytic neoplasms is a reliable method for attaining an accurate immunohistochemistry result, decreasing the risk of misunderstanding. We encourage the use of this counterstain technique in veterinary medicine to improve the melanoma's immunohistochemistry interpretation.

References

1. Fleischer B. Editorial: 100 years ago: Giemsa's solution for staining of plasmodia. *Trop Med Int Health*. 2004;9:755-6.
2. Elias JM. Immunohistochemical methods. In: Elias JM, editor. *Immunohistopathology. A Practical Approach to Diagnosis*. 2nd ed Chicago, IL: ASCP Press. 2003. p.1-110.
3. Goldschmidt MH, Dunstan RW, Stannard AA. Melanocytic tumors and tumor like lesions. In: Goldschmidt MH, Dunstan RW, Stannard AA, Tschärner C, Walder EJ, Yager JA, editors. *Histological classification of epithelial and melanocytic tumors of the skin of domestic animals*. 2nd ed. Washington, DC: Armed Forces Institute of Pathology, American Registry of Pathology. 1998. p.38-50.
4. Kamino H, Tarn ST. Immunoperoxidase technique modified by counterstain with azure B as a diagnostic aid in evaluating heavily pigmented melanocytic neoplasms. *J Cutan Pathol*. 1991;18:436-9.

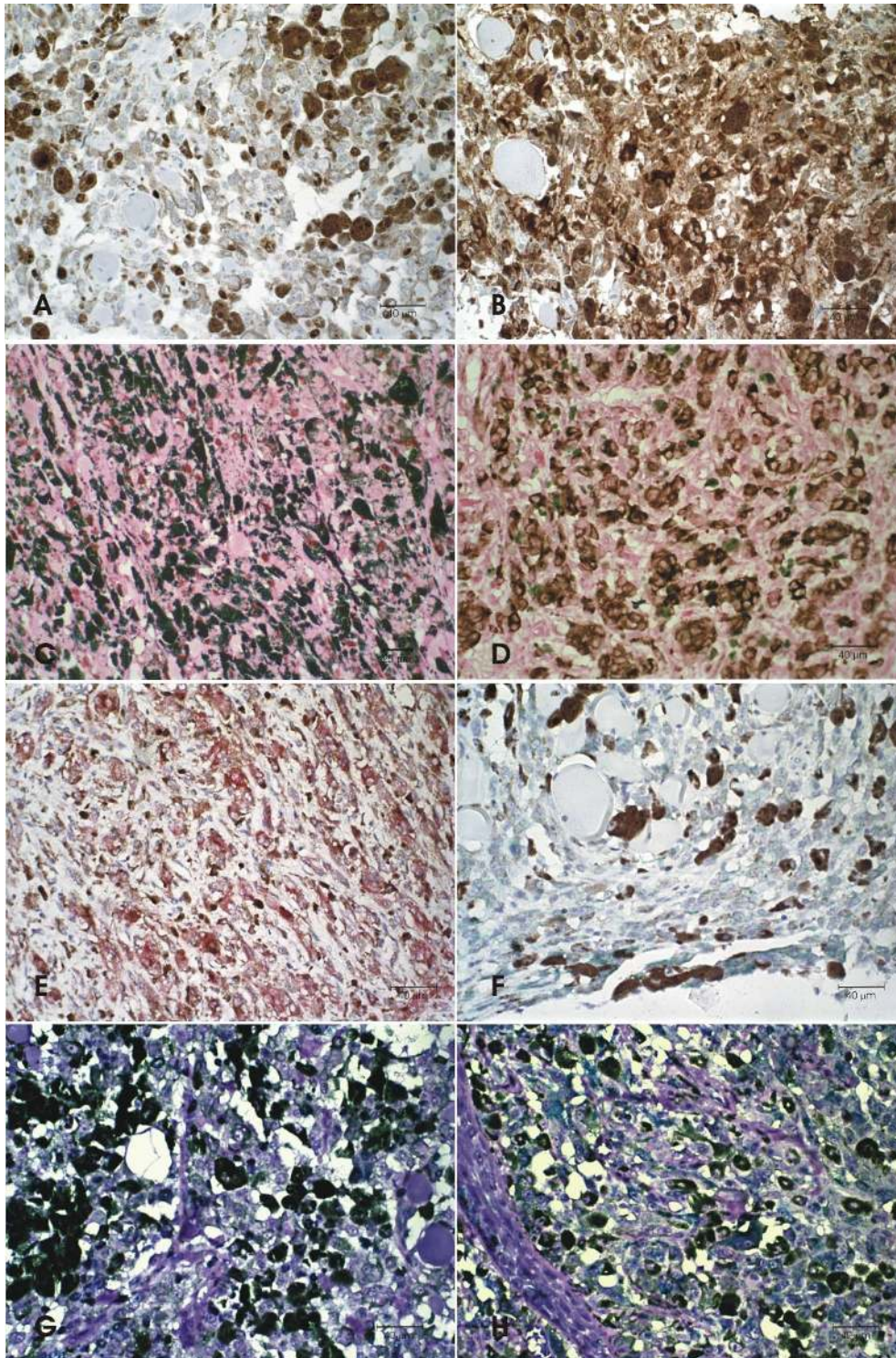


Figure 1. Skin and oral melanomas from dog with different degrees of pigmentation, Immunohistochemistry (IHC) obj 40x. **A.** Skin, IHC staining to KI-67 in neoplastic cells nuclei. DAB chromogen. Hematoxylin counterstain. **B.** Oral, IHC staining to Melan-A in neoplastic cells cytoplasm. DAB chromogen. Hematoxylin counterstain. **C.** Skin, IHC staining to KI-67 in neoplastic cells nuclei. DAB chromogen. Giemsa counterstain **D.** Oral, IHC staining to Melan-A in neoplastic cells cytoplasm. DAB chromogen. Giemsa counterstain. **E.** Oral, IHC staining to Melan-A in neoplastic cells cytoplasm. Permanent read chromogen. Hematoxylin counterstain. **F.** Skin, IHC staining to Melan-A in neoplastic cells cytoplasm. Vina Green chromogen. Hematoxylin counterstain. **G.** Skin, IHC staining to KI-67 in neoplastic cells nuclei. Vina Green chromogen. Giemsa counterstain. **H.** Skin, IHC staining to Melan-A in neoplastic cells cytoplasm. Vina Green chromogen. Giemsa counterstain.

5. Malho P, Dunn k, Donaldson D, Dubielzig RR, Birand Z, Starkey M. Investigation of prognostic indicators for human uveal melanoma as biomarkers of canine uveal melanoma metastasis. *J Small Anim Pract.* 2013;54:584-93.
6. Marques MEA, Landman G, Halpern I, Macareno RSES. Melanoma cutâneo. In: Bacchi CE, Melo CRA, Franco MF, Artigiani Neto R, editors. (Org.). *Manual de Padronização de Laudos Histopatológicos - Sociedade Brasileira de Patologia.* 4ed. Barueri-SP: Editora Manole Ltda. 2013. p.1-11.
7. Matos LL, Trufelli DC, Matos MGL, Pinhal MAS. Immunohistochemistry as an Important Tool in Biomarkers Detection and Clinical Practice. *Biomarker Insights.* 2010;5:9-20.
8. Penha M, Ferreira ER, Peres G, Campos EBP, Marques MEA, Miot HA, Espósito ACC. Melanoma primário múltiplo sincrônico em mulher jovem: relato de caso e revisão da literatura. *Diagnóstico & Tratamento.* 2017;22:154-7.
9. Ramos-Vara JA, Beissenherz ME, Miller MA, Johnson GC, Pace LW, Fard A, Kottler SJ. Retrospective Study of 338 Canine Oral Melanomas with Clinical, Histologic, and Immunohistochemical Review of 129 Cases. *Vet Pathol.* 2000;37:597-608.
10. Ramos-Vara JA. Technical Aspects of Immunohistochemistry. *Vet Pathol.* 2005;42:405-26.
11. Salvio AG, Ribeiro DA, Marques MEA. Identification of neoplastic cells in the lymphocytic infiltrate associated with thin melanomas. *Histopathol.* 2007;50:942-4.
12. Simpson RM, Bastian BC, Michael HT, Webster JD, Prasad ML, Conway CM, Prieto VM, Gary JM, Goldschmidt MH, Esplin DG, Smedley RC, Piris A, Meuten DJ, Kiupel M, Lee C-CR, Ward JM, Dwyer JE, Davis BJ, Anver MR, Molinolo AA, Hoover SB, Rodriguez-Canales J, Hewitt SM. Sporadic naturally occurring melanoma in dogs as a preclinical model for human melanoma. *Pigment Cell Melanoma Res.* 2013;27:37-47.
13. Scott DW, Miller WH, Griffin CE. Neoplastic and non-neoplastic tumors. In: Scott DW, editor. *Muller and Kirk's Small Animal Dermatology.* 6th ed. Philadelphia, US: Saunders Company, 2001. p.1333-38.