BJVP
Brazilian Journal of Veterinary Pathology
ISSN 1983-0246

Case Report

Primary hepatic fibrosarcoma in a Wistar rat (*Rattus norvegicus*)

Letícia Maria S. Silva[1], Fernanda Bresolin[1], Jane K. O. M. Prado[1], Leonardo Grouschekei[1], Andressa Zanon[1], Antonio F. Leis-Filho[2], Juliana M. Rozolen[2], Carlos E. Fonseca-Alves[2,3], Fabiana Elias[1*]

[1]Undergraduate student of Veterinary Medicine, Laboratory of Pathology, Federal University of Fronteira Sul, Brazil.
[2]Department of Veterinary Surgery and Anesthesiology, School of Veterinary Medicine and Animal Science, Sao Paulo State University – UNESP, Botucatu, SP, Brazil.
[3]Institute of Health Sciences, Universidade Paulista – UNIP, Bauru, Sao Paulo, Brazil.
[*]**Corresponding author:** E-mail: elias.fabiana@gmail.com

Submitted April, 04th 2019, Accepted September, 10th 2019

Abstract

Soft tissue sarcomas are a heterogeneous group of malignant neoplasms with different morphological patterns of mesenchymal lineage. This type of neoplasm is most commonly found in the subcutaneous tissue but is rare in solid organs, such as the liver and kidneys. This paper describes the main anatomopathological alterations in the liver of a Wistar rat (*Rattus norvegicus*) with soft tissue sarcoma. A two-year-old male pet Wistar rat was referred to the Laboratory of Veterinary Pathology at the Federal University of Fronteira Sul. The owner reported apathy and the animal died during physical examination. At necropsy, 10 ml of a reddish liquid was found in the thoracic cavity. The left lateral liver lobe contained a 5-cm mass of heterogeneous surface composed of whitish parenchyma and red multifocal lesions extending to the surface of the liver. Moreover, whitish dotted spots intercalated with dark and more friable spots were found in the whole left lateral liver lobe. Histopathological evaluation of the nodule revealed the formation of spindle cells in parallel bundles with slightly eosinophilic cytoplasm, elongated nucleus, hyperchromatic to granular chromatin, and inconspicuous nucleolus. Extracellular matrix and mineralization were also observed. An area with proliferation of spindle cells with elongated cytoplasm, round to oval nuclei, sometimes hyperchromatic, consistent with cells found in the liver was noted in the mesenteric lymph node and omental node. Masson Trichrome staining revealed tumor cells stained in blue. Immunohistochemistry was performed and revealed positive staining for vimentin and negative for pan-cytokeratin, S100, desmin and factor VIII. Thus, the histological, histochemical and immunohistochemical evaluations suggested hepatic fibrosarcoma. This report showed the histological and immunohistochemical findings of a poorly described tumor in a Wister rat in veterinary literature.

Key words: anatomopathological diagnosis, rodent, liver, neoplasm.

Introduction

Soft tissue sarcomas (STS) are a heterogeneous group of malignant neoplasms with various morphological patterns of mesenchymal lineage (1). It originates from primitive mesenchymal cells that have undergone changes in their genetic material, producing, for example, atypical striated muscle and adipose tissue (1). There are more than 50 distinct histological subtypes of sarcomas (4). The mesenchymal tissues originate from the mesoderm and are responsible for lining body cavities and forming connective and muscular tissues (10). Therefore, this type of neoplasm can be distributed in several anatomical sites.

Primary hepatic sarcomas are extremely rare in all species and the identification of the cell origin can be challenging (4, 6, 7, 10). In human medicine, the liver is the primary metastatic site for soft tissue sarcoma from different locations. However, primary hepatic soft tissue sarcomas are extremely rare (4, 6, 7). The definitive diagnosis is made through biopsy for histopathological and

immunohistochemical evaluation (1). Histopathological evaluation is necessary to define the histological subtype (10) and the immunohistochemical analysis is essential for its histogenesis (6).

Rats (*Rattus norvegicus*) have a low incidence of tumors and most neoplasms are benign (15). In a study carried out from 1980 to 1995 with 930 rats, the authors observed that the incidence of tumors was higher in males than in females, of which the endocrine and integumentary systems would be involved in 74% of cases of spontaneous neoplasms in these animals (14). The present study aimed to describe the morphological and immunohistochemical features of hepatic soft tissue sarcoma in a Wistar rat.

Case report

A two-year-old male Wistar rat (*Rattus norvegicus*) weighing 300 grams was sent to the Veterinary Pathology Laboratory of the Veterinary University Hospital Unit (LVPVUHU) of the Federal University of Fronteira Sul. In his medical history, the owner mentioned apathy, while the physical examination revealed dyspnea. During the physical examination, the animal died and was referred for necropsy. The anatomopathological evaluation showed good general condition and markedly pale mucous membranes.

At the inspection of the thoracic cavity, 10 ml of dark red liquid was found. The lung had circular, multifocal to coalescing yellowish areas, firm consistency and cystic appearance; a moderate amount of white jelly-like substance flowed while opening the lungs; the right caudal lobe showed a discrete reddish area. In the abdominal cavity, omentum revealed reddish multifocal nodules; slightly whitish after opening. The liver was increased in volume, friable, with multiples masses in the left lobe of approximately 5 cm (Fig. 1) with a heterogeneous surface composed of whitish parenchyma. The cause of death was a secondary hypovolemic shock due to liver neoplasia.

Microscopic evaluation of liver revealed proliferation of spindle cells with slightly eosinophilic cytoplasmic, elongate nucleus, hyperchromatic to granular chromatin, inconspicuous nucleolus (Fig. 2). Neoplastic cells were arranged in parallel bundles. There was a marked cellular and nuclear pleomorphism with 14 mitotic figures per 10 high-power fields (400x). In certain areas, these cells were in the middle of a slightly eosinophilic extracellular matrix. Multifocal presence of chondroid matrix, rare groups of hepatocytes, ductal hyperplasia and presence of thrombi were noted. The histopathological evaluation suggested soft tissue sarcoma.

Diffuse lymphoid hyperplasia and medullary hemorrhage were observed in the regional lymph node. An area with proliferation of spindle cells with elongated cytoplasm, round to oval nuclei, sometimes hyperchromatic, consistent with the cells found in the liver was noted. Lung showed alveolar collapse, presence of focal areas with dilatation and rupture of alveoli, type II pneumocytes hyperplasia, multifocal lymphoplasmacytic infiltrate, with the morphological diagnosis of mild, multifocal lymphoplasmacytic pneumonia associated with emphysema, but it was not possible to identify the etiological agent. Histologically, the cystic areas were characterized by circumscribed dilatations, sometimes lined with flattened epithelium. A collapse of the alveoli and foci of mixed inflammatory infiltrate were seen around the affected area. Proliferation of spindle cells with a slightly eosinophilic cytoplasmic nucleus, elongated nucleus, granular hyperchromatic chromatin, discrete nucleoli, identical to the liver, was observed in omental adipose tissue, i.e. positive for metastasis. Masson's trichrome staining was performed in the liver to confirm the tumor origin according to Buzatto et al. (5). Neoplastic cells appeared blue while adjacent normal hepatocytes stained red, suggesting a primary fibrosarcoma.



Figure 1. Gross morphology of the lateral left hepatic lobe showing a 5-centimeter diameter mass.

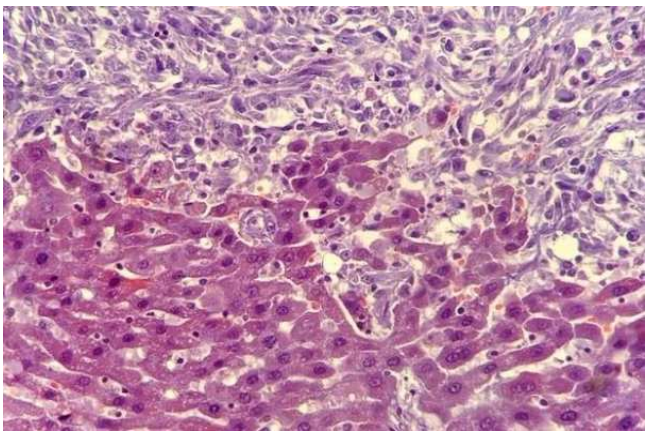

Figure 2. Histopathological evaluation of hepatic soft tissue sarcoma from a Wistar rat. It is possible to observe neoplastic fusiform cells with intense pleomorphism and nuclear atypia. An adjacent healthy hepatic tissue is also observed. Hematoxylin and eosin staining, 20x.

 All rights reserved 2007.

To confirm the tumor histogenesis, immunohistochemical analysis was performed using the antibodies pan-cytokeratin, vimentin, S100 and desmin. For immunohistochemistry (IHC), 4-µm-sections were cut from the paraffin blocks, mounted onto charged slides (StarFrost, Knittel, Germany) and kept at 55° C for 24 hours. The antigen retrieval process was performed with citrate buffer (pH 6.0) in a pressure cooker (Pascal, Dako, Carpinteria, CA, USA). The slides cooled to room temperature for 20 minutes and were incubated with 8% hydrogen peroxide diluted in methanol for 10 minutes. Afterward, the slides were washed with TRIS buffer pH 7.4 and were blocked with non-specific protein with a commercial product (Protein Block, Dako, Carpinteria, CA, USA). Then, the slides were incubated overnight with the primary antibodies: anti-pan-cytokeratin (AE1/AE3, Invitrogen, Carlsbad, CA, USA), anti-vimentin (V3, Dako, Carpinteria, CA, USA), S100 (Dako, Carpinteria, CA, USA), anti-factor VIII (Dako, Carpinteria, CA, USA) and desmin (Dako, Carpinteria, CA, USA), at dilutions of 1:300, 1:300, 1:100, 1:800 and 1:50, respectively. A polymer system was applied as the secondary antibody conjugated to peroxidase (Envision, Dako, Carpinteria, CA, USA) and 3'-diaminobenzidine tetrahydrochloride (DAB, Dako, Carpinteria, CA, USA) was used as the chromogen for a 5-min incubation, followed by Harris hematoxylin counterstain. The negative control was performed by replacing the primary antibodies with TRIS buffer solution. Normal rat skin was used as a positive control for pan-cytokeratin and vimentin. For S100 and desmin, a cerebellum sample and a rat muscle sample were used, respectively. The blood vessels were used as positive control for Factor VIII. Tumor samples were negative for pan-cytokeratin (Fig. 3A), S100 (Fig. 3B) and desmin (Fig. 3C) and positive for vimentin (Fig. 3D). Tumor samples were also negative for Factor VIII. Thus, the association between histopathology, Masson's trichrome staining, and the immunohistochemical panel indicated a primary diagnosis of fibrosarcoma.

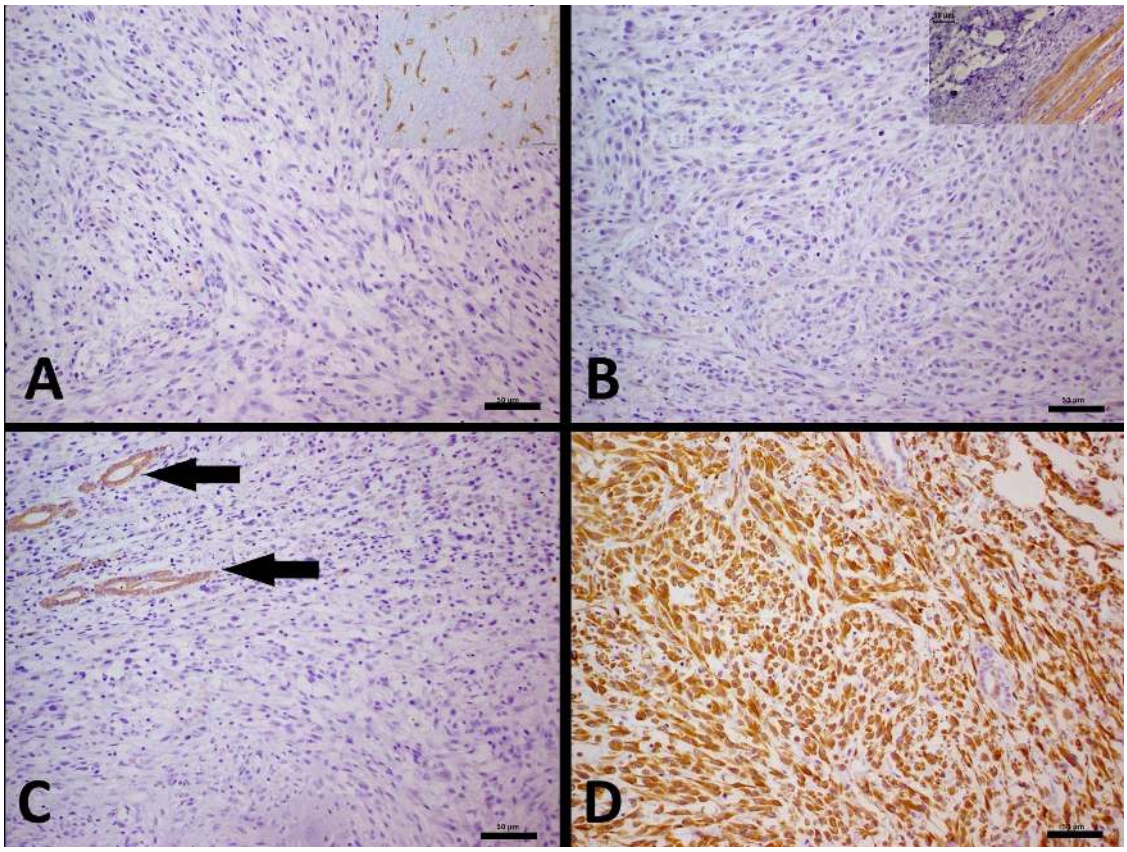

Figure 3. Immunohistochemistry staining of a hepatic fibrosarcoma. **A.** S100 immunohistochemistry of primary hepatic tumor. It is possible to observe negative expression by neoplastic fusiform cells. A normal rat cerebellum was used as positive control (insert). **B.** Negative expression of desmin in a primary hepatic soft tissue sarcoma. A normal rat muscular fiber was used as positive control (insert). **C.** Immunohistochemistry for pan-cytokeratin in a hepatic tumor. Note the negative expression of pan-cytokeratin by the fusiform cells (blue staining) and the remaining hepatic ducts showing positive pan-cytokeratin expression. **D.** Vimentin expression in a primary hepatic soft tissue sarcoma. There is a diffuse vimentin-positive expression by neoplastic cells. Scale bar 50µM.

Discussion

Soft tissue sarcomas are a very uncommon primary hepatic tumor in different species and comprise a group of tumors with similar prognosis (7, 9, 14, 15). The behavior of the tumor is variable, and metastasis is common in some species (4, 6, 7, 9, 10, 14, 15). The liver is the most common metastatic site for soft tissue sarcomas in humans, whereas in other mammals soft tissue sarcomas rarely develop metastasis (4-7, 9, 10, 14, 15, 17). In a study conducted by Walsh and Poteracki (18) with 1370 Wistar rats, the most common neoplasms were pituitary adenoma, mammary fibroadenoma, mammary adenocarcinoma, adrenal cortical adenoma and endometrial stromal polyp. Regarding neoplasms that affected the liver, hepatic adenoma (0.73% in males) and cholangioma (0.88% in males) were the most common. Thus, the prevalence of hepatocellular neoplasms in Wistar rats was low. Bomhard et al. (2) reported nine adenomas and five carcinomas in Wistar rats, totaling 2.3% of all neoplasms found.

To our knowledge, there is no previous report of a primary hepatic soft tissue sarcoma in a Wistar rat. Only one study conducted by Mahesh et al. (12), revealed a fibrosarcoma in the liver; however, this neoplasm was induced by tapeworm larvae *Strobilocerus fasciolaris*.

Since rats are laboratory animals and their lifespan is generally short, it is difficult to identify the incidence of tumors in these animals as tumors are more common in older ages. According to Trotte et al. (17), there were few tumor cases in animals up to 18 months, which can be explained by the use of rodents in experiments. The liver is responsible for metabolizing and detoxifying xenobiotics; therefore, chronic toxicity can induce hepatocarcinogenesis (11, 16). Interestingly, no previous studies with Wistar rats have revealed cartilaginous matrix formation in liver tumors. Hepatoblastoma may show the presence of osteoid and bone formation; however, the organoid structures from this neoplasm are arranged around vascular spaces, and its cells are smaller and strongly basophilic. Thus, the histological evaluation of this case suggested soft tissue sarcoma (16).

In this case report, we identified lymph node metastasis involvement with no neoplastic lesions in the other organs. Grossly, no lymph nodes showed alterations. However, we randomly collected a mediastinal lymph node for histopathological analysis. Interestingly, even without gross alteration, we identified a metastatic focus in this lymph node. In our opinion, the liver was the primary site, whereas the lymph node is a metastatic site, as lymph nodes are the most common metastatic sites for various tumors. Moreover, the lymph node and omentum are accompanied by lymphatic vessels near the tumor, thus being the first locations in contact neoplastic cells (7, 9, 14, 15).

The animal presented dyspnea during the physical examination, indicating lung involvement. However, the histological evaluation of the lungs was negative for metastasis. Although the macroscopic evaluation of the organ raised suspicions of metastasis due to multifocal round structures, the microscopic analysis allowed the final diagnosis of mild, multifocal lymphoplasmacytic pneumonia associated with BALT hyperplasia. Thus, the suspicious of metastasis foci in the lung was discarded.

The cause of death was a secondary hypovolemic shock due to liver neoplasia. The size of the neoplasm caused an acute vascular collapse due to tumor rupture. It has already been described by Ferraz et al. (8), which reported the risk of death from hypovolemic shock due to tumor rupture.

The microscopic features found in the liver suggested a tumor of mesenchymal origin. Among the malignant mesenchymal tumors, leiomyosarcoma and fibrosarcoma are the most common histological pattern. According to Barros (1), mesenchymal neoplasms are usually spindle-shaped; as such, these cells are arranged and interlocked in bundles. Moreover, it was observed moderate to intense pleomorphism and cellular atypia. Pan-cytokeratin negative expression excluded the possibility of an undifferentiated hepatic carcinoma, while S100, factor VIII and desmin staining excluded a neuronal, vascular and muscle origin, and the positive vimentin expression indicated a mesenchymal tumor (7).

Conclusions

The morphological, histopathological, histochemical and immunohistochemical features confirmed a fibrosarcoma of the liver as a primary diagnosis. This tumor had metastatic lesions, indicating that hepatic fibrosarcoma in Wistar rats has a poor prognosis.

References

1. Barros CSL. Fígado, vias biliares e pâncreas exócrino. In: Santos RL, Alessi AC, editors. Patologia veterinária. 2nd ed. Rio de Janeiro: Roca. 2017. p.181-265.
2. Bomhard E. Frequency of spontaneous tumors in Wistar rats in 30-months studies. Exp Toxicol Pathol. 1992;44(7):381-92.
3. Brito MVH, Koh IHJ, Lamarao LG, Damous SHB. Efeito do choque hipovolêmico na anastomose do intestino delgado de ratos. Arq Gastroenterol. 2001;38(2):116-24.
4. Burningham Z, Hashibe M, Spector L, Schiffman JD. The Epidemiology of Sarcoma. Clin Sarcoma Res. 2012;14(2):1-16.
5. Buzatto AB, Elias F, Franzoni MS, Fonseca-Alves CE. Long-Term Survival of a cat with Primary Leiomyosarcoma of the Urinary Bladder. Vet Sci. 2019;6(3):60.

6. Edward A, Levine MD. Prognostic factors in soft tissue sarcoma. Seminars in Surgical Oncology. 1999;17(1):23-32.
7. Ferguson PC, Griffin AM, Brian OS, Charles NC, Aileen MD, Ally M, Robert SB, Jay SW. Bone invasion in extremity soft-tissue sarcoma. American Cancer Society. 2006;106(12):2692-700.
8. Ferraz JRS, Roza MR, Caetano Júnior J, Costa AC. Hemangiossarcoma canino: revisão de literatura. J Bras Cien Anim. 2008;1(1):35-48.
9. GV RJ. Types of Cancer and Surgery in Rats (*Rattus norvegicus*). RRJVS. 2016;3(1):1-6.
10. Linton M, Tong L, Simon A, Buffa E, McGregor R, Labruyére J, Foster D. Hepatic fibrosarcoma incarcerated in a peritoneopericardial diaphragmatic hernia in a cat. JFMS Open Rep. 2016;2(1):2055116916638681.
11. Maekawa A, Onodera H, Tanigawa H, Furuta K, Kodama Y, Horiuchi S, Hayashi Y. Neoplastic and non-neoplastic lesions in aging Slc: Wistar rats. J Toxicol Sci. 1983;8(4):279-90.
12. Mahesh KJ, Reddy PL, Aparna V, Srinivas G, Nagarajan P, Venkatesan R, Sreekumar C, Sesikaran B. *Strobilocercus fasciolaris* infection with hepatic sarcoma and gastroenteropathy in a Wistar colony. Vet Parasitol. 2006;141(3-4):362-7.
13. Ogasawara H, Mitsumori K, Onodera H, Imazawa T, Shibutani M, Takahashi M, Ward Maekawa, JMA. Spontaneous histiocytic sarcoma with possible origin from the bone marrow and lymph node in Donryu and F-344 rats. Toxicol Pathol. 1993;21(1):63-70.
14. Poteracki J, Walsh M. Spontaneous neoplasms in control Wistar rats: a comparison of reviews. Toxicol Sci. 1998;45(1):1-8.
15. Ramu EM, Houdek MT, Isaac CE, Dickie CL, Ferguson PC, Wunder JS. Management of soft-tissue sarcomas; treatment strategies, staging, and outcomes. SICOT J. 2017;3(20):1-12.
16. Thoolen B, Maronpot RR, Harada T, Nyska A, Rousseaux C, Nolte T, Malarkey DE, Kaufmann W, Küttler K, Deschl U, Nakae D, Gregson R, Vinlove MP, Brix AE, Singh B, Belpoggi F, Ward JM. Proliferative and nonproliferative lesions of the rat and mouse hepatobiliary system. Toxicol Pathol. 2010;38(7 Suppl):5S-81S.
17. Trotte MNS, Menezes RC, Tortelly R. Neoplasias espontâneas em ratos Wistar de um centro de criação de animais de laboratório do Estado do Rio de Janeiro, Brasil. REV. CR. 2008;38(9):2545-51.
18. Walsh, KM, Poteracki, J. Spontaneous neoplasms in control Wistar Rats. Fundam Appl Toxicol. 1994;22(1):65-72.