



Case Report

Lipid rich carcinoma in canine mammary gland with metastasis in the abdominal cavity

Isabela F. S. Perossi^{1*}, Paulo E. B. Martinelli¹, Leticia Bonato¹, Gabriela P. Lima², Paulo Henrique L. Bertolo², Rafael R. M. E. Costa², Jorge L. A. Gómez³, Andriago B. De Nardi³, Rosemeri O. Vasconcelos²

¹Professional Health Program Resident Med. Vet. e Saúde (MEC/MS).

²Veterinary Pathology Departemnt - FCAV-UNESP, Jaboticabal, SP.

³Veterinary Clinic and Surgery Department, FCAV-UNESP, Jaboticabal, SP.

*Corresponding author: E-mail: isabelaperossi@gmail.com

Submitted June, 25th 2019, Accepted December, 10th 2019

Abstract

Lipid-rich carcinoma of the mammary gland is a rare variant of cancer and extremely uncommon in dogs. This case report describes the clinical and histopathological aspects of lipid-rich carcinoma in a female dog. A four-year-old spayed German Shepherd dog with enlarged volume adhered to the caudal and inguinal abdominal mammary region was examined. The impossibility of surgical resection led to euthanasia during the surgical procedure. At necropsy, analysis of the abdominal cavity revealed the presence of an irregularly shaped mass, whitish with red areas, in the intrapelvic region. Also, metastases in axillary and mediastinal lymph nodes and right lung were observed. Histopathological analysis of the tumor in the mammary glands and intrapelvic mass showed malignant neoplastic proliferation of epithelial cells. The cells had a distinct shape and boundary, a well-defined cytoplasm, and the presence of intracytoplasmic macro and micro vacuoles, which sometimes pushed the nuclei to the periphery. The lymph nodes had lost the histological architecture due to metastasis. Marked and diffuse immunostaining of tumor cells in the cytoplasm by pancytokeratin, GATA 3 and 35BH11 confirmed the epithelial origin of the tumor. This very aggressive and uncommon neoplasm should be considered as a possible metastasi in the differential diagnosis of tumors of the abdominal cavity.

Key words: cytokeratin, histology, immunohistochemistry, necropsy.

Introduction

Nowadays, mammary gland tumors are very common in dogs and cats (10), being the third most common in cats, and second in dogs. Tumor occurrence is directly related to patient age and reproductive status (10, 28).

Because lipid-rich carcinoma, a rare variant of infiltrating duct carcinoma of the woman breast (25), is an extremely uncommon neoplasm in dogs (7, 9, 21), the epidemiological, clinical, and pathological features have not been fully characterized yet (18, 19).

Histologically, the neoplasm is composed of sheets of cells with inconspicuous fibrovascular trabeculae

and necrosis foci, with round to oval cells, distinct borders and moderate to abundant cytoplasm containing numerous small vacuoles or a single large vacuole that occasionally peripheralizes the nucleus. Nuclei are round to oval and vesicular, with clumped chromatin and one or two nucleoli. Anisokaryosis and anisocytosis are moderate to severe, with variable numbers of mitoses. Some cases show lymphatic invasion and lymph node metastasis (10).

Although this tumor prevalence decreases when preventive ovariohysterectomy is performed, it remains an important disease in veterinary medicine (17). Currently, the veterinary treatment of choice is surgery, lumpectomy or nodulectomy, as well as simple, regional or radical mastectomy, except in cases of inflammatory carcinoma

(26, 28). The final diagnosis is only obtained after histopathological examination, usually following surgery (5).

Breast cancer diagnosis in women uses tumor histological classification, taking into account the molecular profile of neoplastic cells by immunohistochemistry. A panel of tumor markers is used, allowing a more appropriate therapy choice and accurate patient prognosis. For this, tumors are classified into subtypes according to biological behavior and gene expression. The luminal A and luminal B subtypes express estrogen receptor (ER) and progesterone receptor (PR). Furthermore, luminal A has a good prognosis and B, intermediate. A tumor negative for hormone receptors and positive for human basal epidermal growth factor 2 (HER2) receptor has an intermediate prognosis. Triple-negative tumors (ER-, PR-, HER2-) have poor prognosis and generally do not respond well to chemotherapy (11).

The comparison of tumor expression profiles in dogs and humans shows overlapping unregulated genes in human and canine mammary tumors. Global gene expression profiles comparing metastatic versus non-metastatic canine mammary carcinoma are not available, while several studies on human breast cancer have found significant expression profiles associated with metastasis (14).

Thus, this case report describes the clinical and histopathological aspects of the lipid-rich carcinoma in a female dog.

Case report

The veterinary oncology service of the Veterinary Hospital (FCAV-UNESP, Jaboticabal, São Paulo State,

Brazil) evaluated a four-year-old spayed German shepherd dog with increased volume adhered to the caudal abdominal and inguinal region of the mammary glands, warm, with an inflammatory aspect, showing bilateral and sub-lumbar inguinal lymphadenomegaly. Additionally, the animal had tenesmus and no milk secretion was observed in the mammary gland.

The ultrasonographic exam showed deep inguinal lymph nodes and medial iliac while irregular masses of hypoechoic echogenicity, with cavitory areas and evident vascularization, were observed compressing the colon.

The animal was referred for regional mastectomy and exploratory laparotomy. During surgery, the intra-abdominal mass adhered to the pelvis was verified, but the impossibility of surgical resection led to euthanasia during the surgical procedure. After euthanasia, upon necropsy, both, the animal and the tumor resected from the caudal abdominal (M4) and inguinal region of the mammary gland (M5) measuring 30 x 15 cm, were sent for histopathological analysis (Fig. 1A).

The *in situ* analysis of the abdominal cavity revealed a discrete amount of reddish liquid and the presence of an irregular shaped mass in the intrapelvic region, whitish with red areas, fibro-elastic, measuring 21x6 cm, homogeneous, whitish with blackened areas at the cut surface (Fig. 1B and 1C). Right axillary and mediastinal lymph nodes were enlarged, as well inguinal lymph node (Fig. 1E). Lung was diffusely reddish, with small blisters that shrunk to the touch and three nodules of 1cm diameter in the right cranial lobe (Fig. 1D).

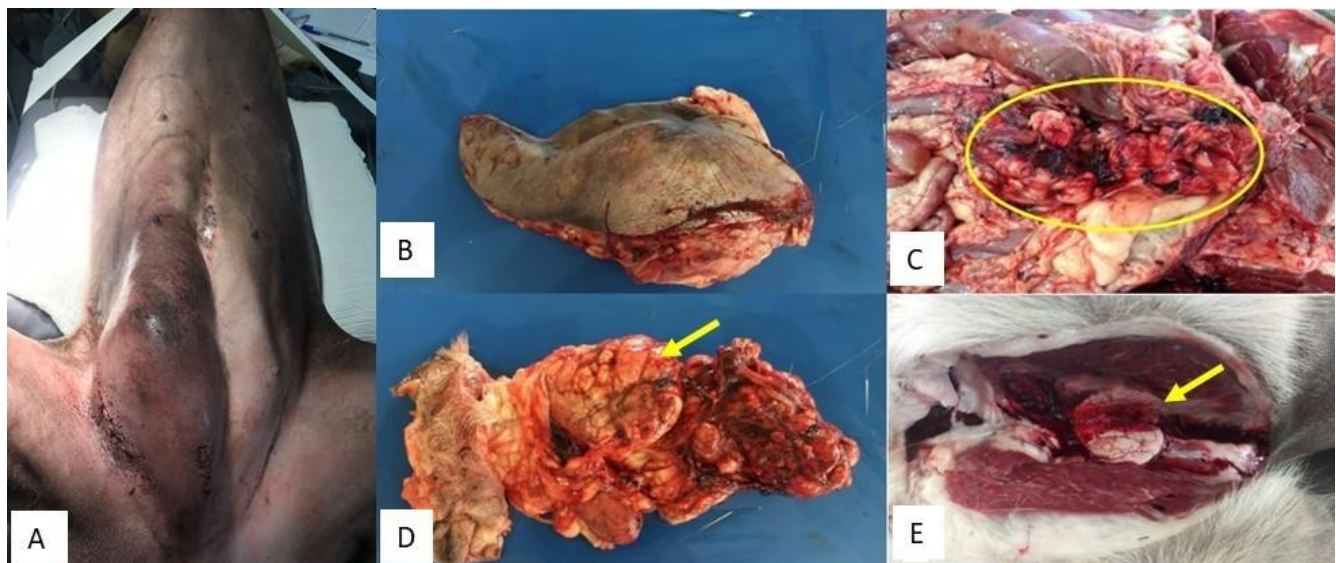


Figure 1. Gross morbid lipid-rich carcinoma canine mammary gland. **A and B.** Localized neoplasm in the caudal abdominal and inguinal mammary gland. **C.** Note a large intrabdominal mass with hemorrhagic areas (circle). **D.** Detail of the intrabdominal mass showing lobulated aspect in the cut surface (arrow). **E.** Lymph node enlarged due to metastasis (arrow).

The histopathological analysis of the tumor in the M4, M5 and intra-abdominal regions revealed a malignant neoplastic proliferation of epithelial cells, of infiltrative growth with great cellularity and indistinct limits. The cells were arranged in strands with thin collagenous stroma. Individually the cells had distinct shapes and boundaries, with well delimited and eosinophilic cytoplasm, intracytoplasmic vacuoles that sometimes pushed the nuclei to the periphery (Fig. 2A and 2B). These were oval, hypochromic, with finely clustered chromatin and evident

and multiple nucleoli. Moderate anisocytosis, discrete cardiomegaly, and moderate multinucleation were observed. Four mitotic figures were observed in 10 large magnified fields (Obj 40x). In addition, extensive areas of necrosis and yellowish intratumoral secretion, also discrete lymphocytic inflammatory infiltrate, were noted. Foci of pulmonary metastasis (Fig. 2C) caused atelectasis of adjacent alveoli and discrete congestion. Lymph nodes showed a loss of normal architecture due to metastasis.

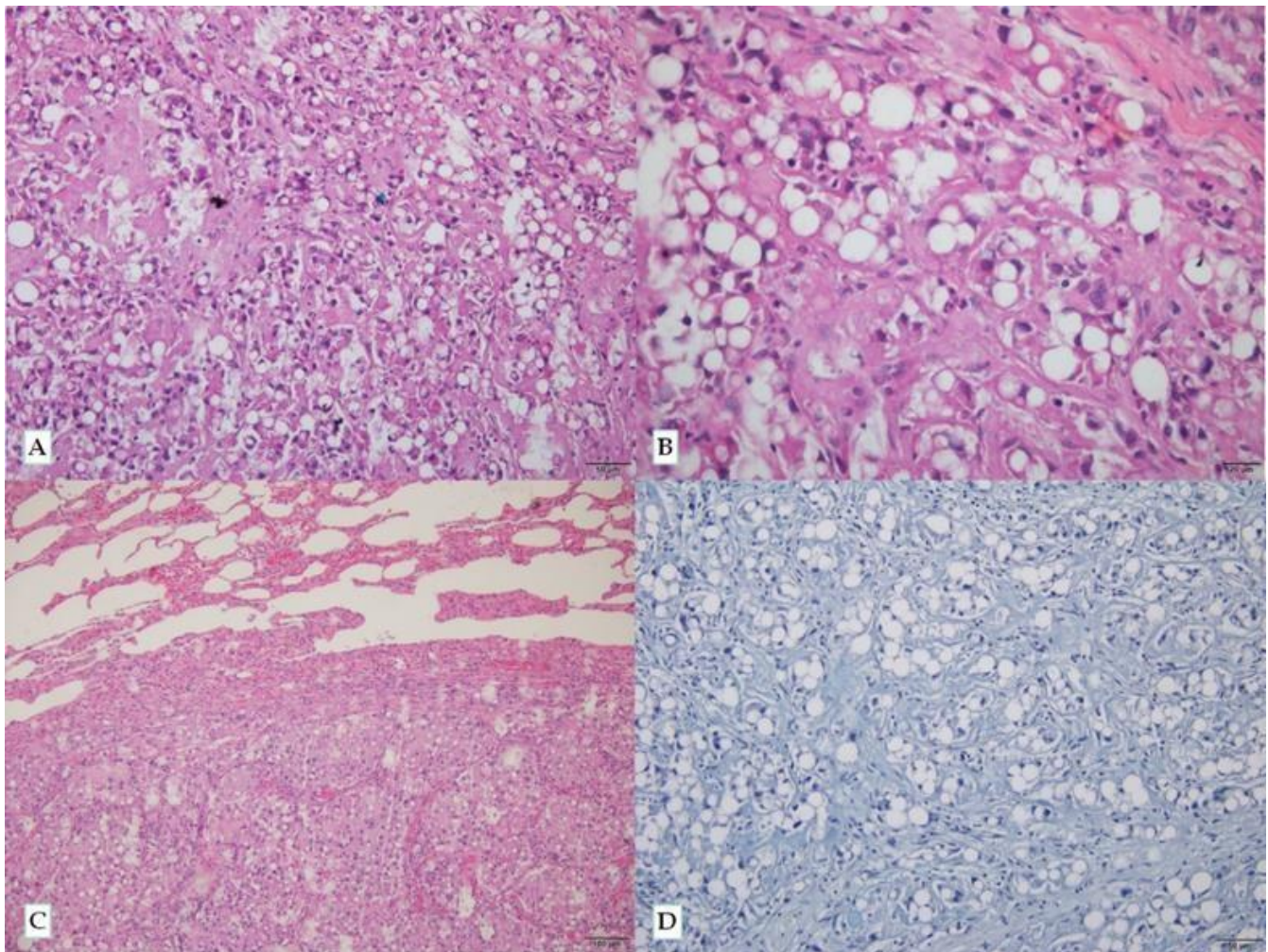


Figure 2. Lipid rich carcinoma in canine mammary tissue. **A and B.** Intracytoplasmic lipid vacuoles are observed in tumor cells (bar = 50 and 20 µm, respectively). **C.** Note lung metastasis with alveolar atelectasis (*, bar = 100 µm and 50 µm, respectively). Hematoxylin and Eosin. **D.** Negative tumor for secretory carcinoma (bar = 50 µm). PAS-Alcian blue histochemistry.

The histological classification of tumors followed the World Health Organization (18) and the guidelines of the second consensus for canine mammary tumor diagnosis (3). The differential diagnosis of a mammary secretory carcinoma was made using the histochemical method of Periodic Acid Schiff (PAS) plus Alcian Blue, which stained blue the intracytoplasmic vacuoles of the neoplastic cells. However, the neoplastic cells were negative (Fig. 2D).

The immunohistochemistry analysis was performed using the cytokeratin (clonal AE1/AE3, DakoCytomation, Code M3515, 1:200 dilution) and vimentin (clonal V9, DakoCytomation, Code M0725, 1:150 dilution) antibodies, and the streptavidin-biotin-peroxidase complex (LSAB + System HRP kit, DakoCytomation, Code K0690-1), at the immunohistochemistry laboratory of UNESP.

Marked and diffuse cytokeratin immunostaining was observed in the cytoplasm of tumor cells, while the neoplastic cells were negative for vimentin, suggesting the epithelial origin of the tumor (Fig. 3). The tumor samples were sent to another veterinary diagnostic laboratory to verify the glandular origin of the neoplasm, by immunohistochemical analysis. The sample was subjected to an antibody panel consisting of GATA3, 35BH11,

34BE12, GATA4, c-erbB2, p63, estrogen receptor, mammaglobin, CK7, and CK20. In the immunohistochemistry analysis, the tumor cells were positive only for the GATA3 and 35BH11 antibodies (Fig. 4). The result of the immunohistochemical analysis concluded that it was a poorly differentiated lipid-rich carcinoma that probably originated from the mammary gland.

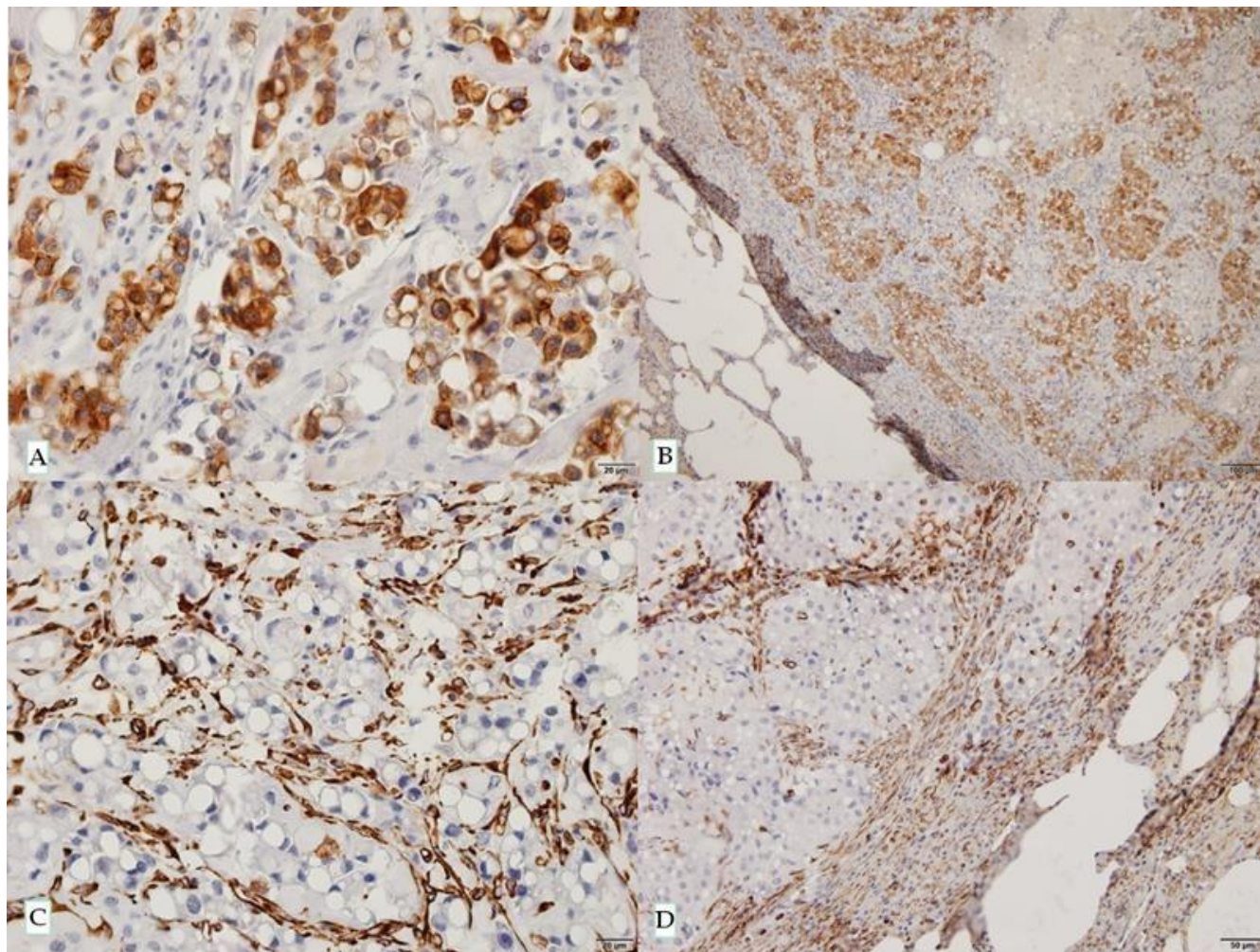


Figure 3. Photomicrographs of the immunohistochemistry analysis of the canine mammary tumor. **A.** Tumor cells positive for pancytkeratin antibody (bar = 20 µm). **B.** Note the same aspect in the pulmonary metastasis (bar = 100 µm). **C and D.** Negative immunostaining of the tumor and pulmonary metastasis for vimentin antibody. Note that it only the tumor stroma is positive (bar = 20 and 50 µm, respectively). Streptavidin-biotin-peroxidase complex.

Discussion

There is a high incidence of mammary cancer in female dogs in Brazil and 50% of these tumors are diagnosed as malignant (3). This tumor incidence is higher in non-castrated female dogs (6, 20), however, the female dog in this study was spayed. Dog age at castration is directly related to the efficiency of ovariectomy in preventing mammary tumors in dogs, but no information of the spayed age was available. Studies show that the incidence of canine mammary carcinomas is declining in

certain regions, such as the United States and some Western European countries, due to the common practice of performing ovariohysterectomy at an early age, ranging from 8 weeks to 7-12 months old. In contrast, in regions such as Scandinavia and Spain, the incidence of these neoplasms is much higher, since preventive sterilization is not routinely performed (6, 20, 22). In Brazil, annual incidence rates vary significantly according to geographic location. A study conducted by the Laboratory of Comparative Pathology of UFMG pointed out that about 1500 cases were diagnosed as breast cancer in 15 years,

but most of the female dogs were not castrated until the time of diagnosis (4). One study investigated dogs diagnosed with lipid-rich carcinoma, of which six were not castrated, five had previous gestation, two had

pseudopregnancies while none received oral contraceptives (7). The results revealed that most of the animals diagnosed with the mammary neoplasm were not castrated.

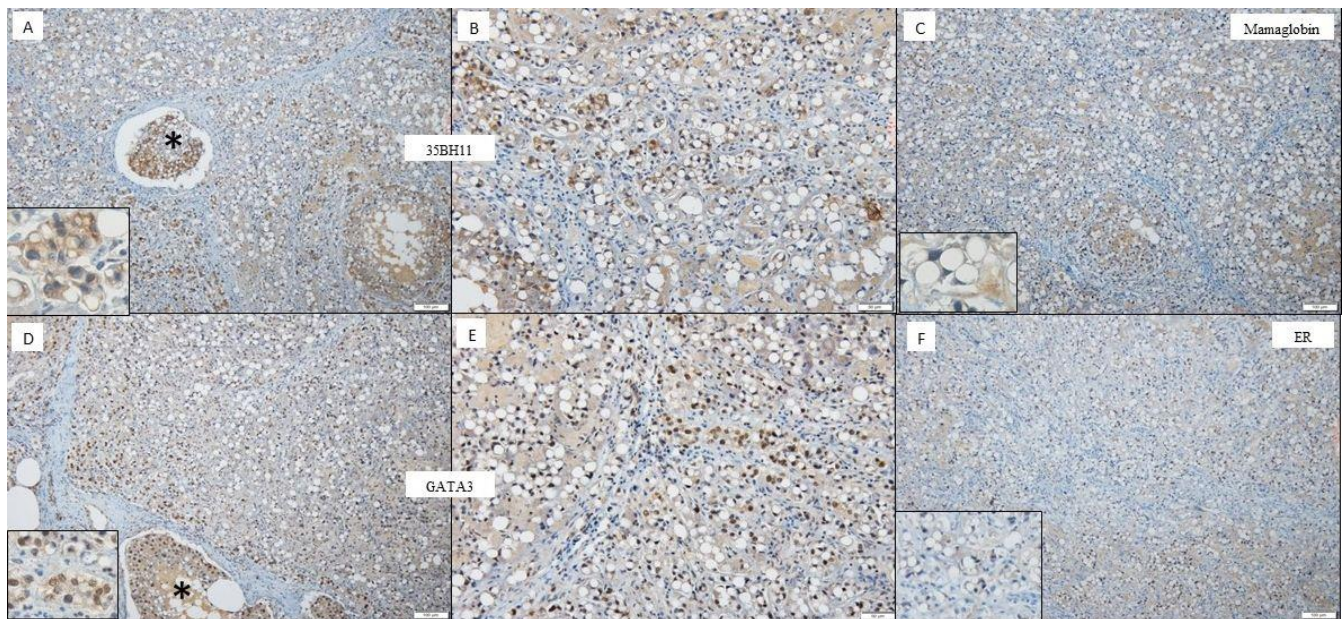


Figure 4. Photomicrographs of the immunohistochemistry analysis of the canine mammary tumor. **A and B.** Tumor cells, including intravascular emboli (*), positive for cytokeratin 35BH11 antibody (detail, bar = 100 and 50 μ m, respectively). **C.** The neoplastic cells were negative for mamaglobin antibody (detail, bar = 100 μ m). **D and E.** Note the mammary carcinoma positive for GATA3 antibody (detail). The neoplastic emboli (*) showed the same aspect (bar = 100 and 50 μ m, respectively). **F.** Negative immunostaining of the mammary tumor for estrogen receptor antibody (ER) antibody (detail, bar = 100 μ m). Streptavidin-biotin-peroxidase complex.

From 2013 to 2018, the Veterinary Pathology Service of the FCAV-UNESP diagnosed 426 mammary gland tumors and only one case was a lipid-rich carcinoma, showing the low incidence of this rare tumor. In the literature, this tumor incidence is rare, both in women (16, 27) and in female dogs (9, 18). A survey of 276 samples of mammary gland tumors in dogs was performed, and only two were diagnosed as lipid-rich carcinoma (0.7%) (23).

In this case report, the tumor had extremely aggressive behavior, with inflammatory signs upon clinical examination, metastases to the lungs and regional lymph nodes. Unlike the two cases of the dogs cited in the literature (23), in which the diagnosis indicated no vascular invasion nor clinical signs of lesions in the regional lymph nodes, and no recurrence nor metastases in the follow-up 15 and 9 months after surgery, respectively. However, in other works the postoperative follow-up detected recurrence or metastases (or both) in four of the seven cases in the regional lymph nodes and lungs, varying from 3 months to 16 months (7). Metastasis in the bones detected by pelvic radiographs revealed a mass that appeared as a ventral opacity between the sixth and seventh lumbar vertebra and was further diagnosed by cytology analysis (13).

Previous studies report that neoplasms appeared as solitary or multiple nodules, ranging in diameter from one to six centimeters (7) to more than 20 cm in length (17). In this case report, the mammary neoplasm had 30 x 13 cm and the intrapelvic mass had 21 x 6 cm, in agreement with the literature.

Other mammary carcinomas such as ductal, lobular, secretory (rich in glycogen and mucinous) and mesenchymal neoplasms, as liposarcoma also present vacuolated cytoplasm. However, while secretory mammary carcinomas tend to be positive for PAS-Alcian blue, the lipid-rich carcinoma is negative for this histochemical technique, after digestion by diastasis (2), as observed in this study.

The immunohistochemistry technique was used for a definitive diagnosis in this case. The lipid-rich carcinoma was positive for pancytokeratin (AE1/AE3) and negative for vimentin, discarding the differential diagnosis of liposarcoma. According to the literature, tumor cells have a glandular epithelial immunophenotype because they express high and low molecular weight cytokeratin exclusively (7, 9). A study in the literature tested various cytokeratin types in normal canine tissue and epithelial and mesenchymal tumors. Pancitokeratin antibody (AE1/AE3) showed strong labeling in epithelial tissues, including

single or mixed canine mammary tumors, with positivity of the neoplastic epithelium. These authors suggest that this antibody should be part of a general screening to differentiate epithelial from mesenchymal tumors (1).

Tumor samples from the present study were also positive for GATA3. Studies highlight that the *GATA3* gene is highly expressed in mammary tumors (8). This gene is crucial at various stages of mammary gland development and, for luminal cell differentiation, being part of a set of genes called "intrinsic" breast genes (8). Harbeck et al. (2019) point out that the *GATA3* gene may mutate or be amplified in 10% of early breast cancers (11). These authors report that this gene is activated in tumors of the luminal molecular subtype A. In the female dog of the present study, we observed an aggressive and metastatic neoplasm to the pelvic cavity. Even though the suggestive molecular pattern is the luminal pattern, there are few studies on dogs that correlate this marker with the disease prognosis (11).

In this study, the positivity of the tumor cells for low molecular weight cytokeratin (35BH11) was also observed. Cardona et al. (1989) obtained poor labeling in various types of normal and neoplastic epithelial tissue, including breast tumors (1). According to Cassali et al. (2014), immunohistochemical analysis with cytokeratins of different molecular weights may present variable results in canine lipid-rich carcinoma (3). However, cytokine 35BH11 has been considered a useful marker for identifying cells of epithelial origin and tumors of human origin (15).

The origin of the mammary gland tumor was evaluated by labeling the neoplastic cells with the mammaglobin antibody. According to the literature, this protein is overexpressed in 48 to 84% of breast carcinomas in women. This antibody is considered to have good sensitivity but low specificity (15). In the present study, the negative result of mammaglobin labeling is possibly due to poor differentiation of neoplastic cells, since the laboratory that performed the immunohistochemistry attests that the antibody used has cross-reactivity with the canine species.

A report of lipid-rich carcinoma in a dog breast highlights that c-erbB2 and p63 labeling was negative in neoplastic cells (24), similar to that described in the present report.

The neoplastic cells were also negative for the estrogen receptor in this study. In female breast cancer, tumors with the most aggressive molecular profile (triple negatives, overexpressed Her2) are usually negative for hormone receptors (11). In dogs, as in women, the expression of hormone receptors in mammary tumors is related to the best prognosis (12), unlike the dog of the present study that had a very aggressive tumor.

The immunohistochemistry technique is a widely used tool in human oncology, as it allows to determine the prognosis and the most appropriate therapeutic method for the patient. In veterinary medicine, this technique has been

successfully employed. However, studies to validate the best markers for canine tumors are still missing (12). In the present case report, this technique allowed to determine the epithelial origin of the canine tumor.

We can conclude that this is a rare and extremely aggressive neoplasm for dogs, with high rates of metastasis to the regional lymph nodes and poor prognosis. The immunohistochemistry technique was fundamental to determine the poorly differentiated tumor phenotype, which was associated with clinical and pathological findings.

References

1. Cardona A, Madewell BR, Naydan DK, Lund JK. A comparison of six monoclonal antibodies for detection of cytokeratins in normal and neoplastic canine tissue. *J Vet Diagn Invest.* 1989;1:316-23.
2. Cassali GD, Gobbi H, Gartner F, Schmitt FC. Secretory Carcinoma of the Canine Mammary Gland. *Vet Pathol.* 1999;36:601-3.
3. Cassali GD, Lavallo GE, Ferreira E, Estrela-Lima A, De Nardi AB, Ghever C, Sobral RA, Amorim RL, Oliveira LO, Sueiro FAR, Beserra HEO, Bertagnolli AC, Gamba CO, Damasceno KA, Campos CB, Araujo MR, Campos LC, Monteiro LN, Nunes FC, Horta RS, Reis DC, Luvizotto MCR, Magalhães GM, Raposo JB, Ferreira AMR, Tanaka NM, Grandi F, Ubukata R, Batschinski K, Terra EM, Salvador RCL, Jark PC, Delecrodi JER, Nascimento NA, Silva DN, Silva LP, Ferreira KCRS, Frehse MS, di Santis GW, Silva EO, Guim TN, Kerr B, Cintra PP, Silva FBF, Leite JS, Mello MFV, Ferreira MLG, Fukumasu H, Salgado BS, Torres R. Consensus for the Diagnosis, Prognosis and Treatment of Canine Mammary Tumors – 2013. *Braz J Vet Pathol.* 2014;7(2):38-69.
4. Cassali GD, editor. *Patologia mamária canina: do diagnóstico ao tratamento.* São Paulo: Medvet, 2017:27-30..
5. Silva HC, Oliveira AR, Horta RS, Merísio ACR, Sena BV, Souza MCC, Flecher MC. Epidemiology of Canine Mammary Gland Tumours in Espírito Santo, Brazil. *Acta Scientiae Veterinariae.* 2019;47: Art.1640.
6. Egenvall A, Bonnett BN, Ohagen P, Olson P, Hedhammar A, von Euler H. Incidence of and survival after mammary tumors in a population of over 80,000 insured female dogs in Sweden from 1995 to 2002. *Prev Vet Med.* 2005;69:109-27.
7. Espinosa de los Monteros A, Hellmén E, Ramírez GA, Herráez P, Rodríguez F, Ordás J, Millán Y, Lara A, Martín de las Mulas J. Lipid-rich carcinomas of the mammary gland in seven dogs: clinicopathologic and immunohistochemical features. *Vet Pathol.* 2003;40:718-23.
8. Eeckhoutte J, Keeton EK, Lupien M, Krum SA, Carroll JS, Brown, M. Positive cross-regulatory loop

- ties GATA-3 to estrogen receptor α expression in breast cancer. *Cancer Res.* 2007;67(13):6477-83.
9. Giudice C, Sironi G, Roccabianca P, Crippa L. Carcinoma mammario a cellule lipidiche nel cane: caratteristiche anatomopatologiche di due casi. In *Atti XXI Congresso Nazionale APIV*, 2003.
 10. Goldschmidt M, Penã L, Zappulli V. Tumours of the Mammary Gland. In: Meuten DJ, editor. *Tumours in Domestic Animals*. 5th ed. Ames: Wiley-Blackwell, p.723-65.
 11. Harbeck N, Penault-Llorca F, Cortes H, Gnant M, Houssami N, Poortmans F, Ruddy K, Tsang J, Cardoso F. Breast cancer. *Nature Reviews*. 2019;5:1-31.
 12. Horta RS, Costa MP, Lavallo GE, Araújo RB, Cassali GD. Fatores prognósticos e preditivos dos tumores caninos definidos com o auxílio da imunohistoquímica. *Cienc. Rural*. 2012;42(6):1033-9.
 13. Kim MC, Kim SY, Lee SH, Kim DY, Yoon JH, Kim WH, Lee JH, Kim Y. Metastatic lipid-rich mammary carcinoma in a dog. *Korean J. Vet. Res.* 2014;54:265-8.
 14. Klopffleisch, R., Lenze, D., Hummel, M., & Gruber, A. D. Metastatic canine mammary carcinomas can be identified by a gene expression profile that partly overlaps with human breast cancer profiles *BMC Cancer*. 2010;10:618.
 15. Krishna M. Diagnosis of metastatic neoplasms. An immunohistochemical approach. *Arch Pathol Lab Med*. 2010;134:207-15.
 16. Kurebayashi J, Izuo M, Ishida T, Kurosumi M, Kawai T. Two cases of lipid-secreting carcinoma of the breast: case reports with an electron microscopic study. *Japanese journal of clinical oncology*. 1988;18: 249-54.
 17. Magalhães GM, Gava FN, Voorwald FA, Silveira AC, Tinnuci-Costa M, Alessi AC. Carcinoma rico em lípidios em cadela. *PUBVET* 6, 2012: Art.1295.
 18. Misdorp W, Else RW, Hellme'n E, Lipscomb TP. Histological classification of mammary tumors of the dog and the cat. *In: WHO International Histological Classification of Tumors of Domestic Animals*, 2nd series, vol. VII. AFIP, Washington, DC, 1999.
 19. Misdorp W. Tumors of the mammary gland. In: Meuten DJ, editor. *Tumors in Domestic Animals*. 4th ed., pp. 575-606. Iowa State Press, Ames, IA, 2002.
 20. Moe L. Population-based incidence of mammary tumours in some dog breeds. *J Reprod Fertil Suppl*. 2001;57:439-43.
 21. Peña L, Perez-Alenza MD, Rodriguez-Bertos A, Nieto A. Canine inflammatory mammary carcinoma: histology, immunohistochemistry and clinical implications of 21 cases. *Breast Cancer Res. Treat.* 2003;78:141-8.
 22. Perez Alenza MD, Tabanera E, Pena L. Inflammatory mammary carcinoma in dogs: 33 cases (1995–1999). *J Am Vet Med Assoc*. 2001;219:1110-4.
 23. Pérez-Martínez C, García-Iglesias MJ, Durán-Navarrete, AJ, Espinosa-Alvarez J, García-Fernández RA, Lorenzana-Robles N, Fernández-Pérez S, García-Marín JF. Histopathological and Immunohistochemical Characteristics of Two Canine Lipid-Rich Mammary Carcinomas. *J. Vet. Med.* 2005;52:61-6.
 24. Rezaie A, Esmaeilzadeh S, Naddaf H. Lipid rich carcinoma and solid carcinoma in mammary gland of a dog: histopathological and immunohistochemical features. *Iranian J Vet Sci Technol*. 2011;3(1):57-64.
 25. Rosen PP, Oberman HA. *Atlas of Tumor Pathology*. AFIP, Washington, DC, 1993.
 26. Sleecx N, De Rooster H, Veldhuis Kroeze EJB, Van Ginneken C, Van Brantegem L. Canine mammary tumours, an overview. *Reproduction in Domestic Animals*. 2011;46:1112-31.
 27. Van Bogaert LJ, Maldague P. Histological variants of lipid secreting carcinoma of the breast. *Virchows Arch Path Anat*. 1977;375:345-53.
 28. Withrow SJ, MacEwen EG. *Small Animal Clinical Oncology*. 4th ed. Philadelphia: WB. Saunders Co., 2007.