BJVP
Brazilian Journal of Veterinary Pathology
ISSN 1983-0246

Case Report

Clinicopathological and immunohistochemical features of pleomorphic lobular mammary carcinoma in a female dog

Geórgia M. Magalhães[1,2], Juliana Santilli[2], Priscila P. Cintra[2*], Sabryna G. Calazans[2], Alfredo Ribeiro-Silva[3]

[1]South Minas Federal Institute- Muzambinho-MG.
[2]Veterinary Hospital of Unifran, University of Franca (UNIFRAN).
[3]Department of Pathology and Forensic Medicine, Ribeirão Preto Medical School, University of São Paulo (USP).
[*]**Corresponding author:** Priscila Pavini Cintra, PhD course in the Graduate Program in Sciences, University of Franca, Franca-SP, Brazil. Address: Av. Dr. Armando de Sáles Oliveira, 201, Veterinary Hospital of Unifran- Parque Universitario, Franca - SP, Brazil 14404-600, Phone +55 16 37118713/ +55 16 981181182. E-mail: ppcintra@yahoo.com.br

Submitted August, 20th 2019, Accepted October, 04th 2019

Abstract

This report describes a pleomorphic lobular carcinoma (PLC) case, in an eight-year-old, female Shih Tzu dog, which attended the Veterinary Hospital of the University of Franca, Brazil. A single irregular, non-ulcerated, non-hyperaemic soft nodule, 2 cm in diameter, was observed during the clinical examination. The nodule was adhered within the deep tissues in the right caudal thoracic mammary gland. After removal of the nodule, the histopathologic examination showed that the neoplastic epithelial cells were scattered throughout the stroma in linear patterns, had abundant eosinophilic cytoplasm, eccentric nuclei and cytoplasmatic vacuoles, features compatible with the diagnosis of pleomorphic lobular carcinoma. An immunohistochemical evaluation was performed in order to better characterise the tumour. Based on the negative immunoreactivity for hormone receptors and human epidermal growth factor receptor-2 and positive expression for one of the basal markers, the basal-like triple-negative phenotype was characterized. The treatment indicated was chemotherapy with carboplatin; however, the disease progressed, and the patient had an overall survival of 47 days after surgery, confirming the aggressiveness of the disease.

Key words: canine, immunohistochemistry, triple-negative, tumour.

Introduction

Mammary gland tumours are one of the most common neoplasms of female dogs, being the simple and complex carcinoma the most frequent type of malignant disease. (1, 2). Pleomorphic lobular carcinoma (PLC) is an uncommon and special type of malignant mammary neoplasia that corresponds to a variant of invasive lobular carcinomas (ILC) in women (3). It is characterised as an aggressive tumour with poor prognosis, with the first case described within a female dog published in 2002 (4). The study compared the cytomorphological and immunohistochemical findings of mammary neoplasm in female dogs and women, showing similarities between species (1, 2, 4).

The histological patterned of PLC is characterised by epithelial cells arranged in discohesive aggregates arranged in rows or loosely dispersed in the stroma. The cells show abundant eosinophilic cytoplasm and eccentric nuclei, similar to plasm cells. Pleomorphism is also present in nuclei, where often, bizarre and multinucleated cells can be noticed (2).

PLCs are known to be immunohistochemically positive for hormone receptors, in addition to having a high proliferation rate represented by the Ki-67 positive cells percentage, and positive expression of human epidermal growth factor receptor 2 (HER-2) (2, 5). The absence of E-cadherin (E-cad) and β-catenin membranous staining is characteristic of PLC for women and female dogs, and it has been suggested that loss of these markers

 All rights reserved 2007.

can help the diagnose PLC in both species (2-6). Strong immunostaining of cytoplasmic cells to cytokeratins can define the epithelial origin of PLC (2, 7).

Due to the high malignant grade of PLCs, along with few cases reported in literature, the present study aims to describe the clinicopathological and immunohistochemical findings of a PLC from a female dog.

Case report

An eight-year-old female Shih Tzu dog was referred to the Veterinary Hospital of the University of Franca (São Paulo, Brazil) due to a mammary tumour first observed approximately two months prior. During the clinical examination, a single irregular, non-ulcerated, non-hyperaemic soft nodule, measuring 2 cm in diameter, was observed. The nodule was adhered to the deep tissues in the right caudal thoracic mammary gland. Fine needle aspiration (FNA) cytology was performed and Diff-Quik staining results suggested a high grade epithelial malignant mammary tumour, characterized by the presence of mostly loose epithelial cells, broad eosinophilic cytoplasm with a round to oval nucleus, loose chromatin, and evident macronucleus, marked anisocytosis and anisokaryosis and presence of mitosis. Total right side mastectomy was scheduled for 18 days after diagnosis. Intraoperatively, the muscle immediately beneath and around the nodule was shaved, showing at histopathologicl exam the presence of neoplastic epithelial cells.

Samples of the tumor and right inguinal lymph node were fixed in 10% formalin, processed, and then embedded in paraffin. Tumor and lymph node sections of 3 mm thickness were obtained and stained with hematoxylin and eosin (HE). In the histopathological examination, the neoplastic epithelial cells were scattered throughout the stroma, in linear patterns (Fig. 1A) with abundant eosinophilic cytoplasm and eccentric nuclei containing cytoplasmic vacuoles (Fig. 1B) and neoplastic emboli in superficial dermis lymphatic vessels (Fig. 1C). The presence of a high mitotic index was observed, 15 mitosis figures in 10 fields of higher magnification, however the inguinal lymph node involvement was not observed (Fig. 1D). Using the data obtained from the histopathology, a diagnosis of pleomorphic lobular mammary carcinoma was established.

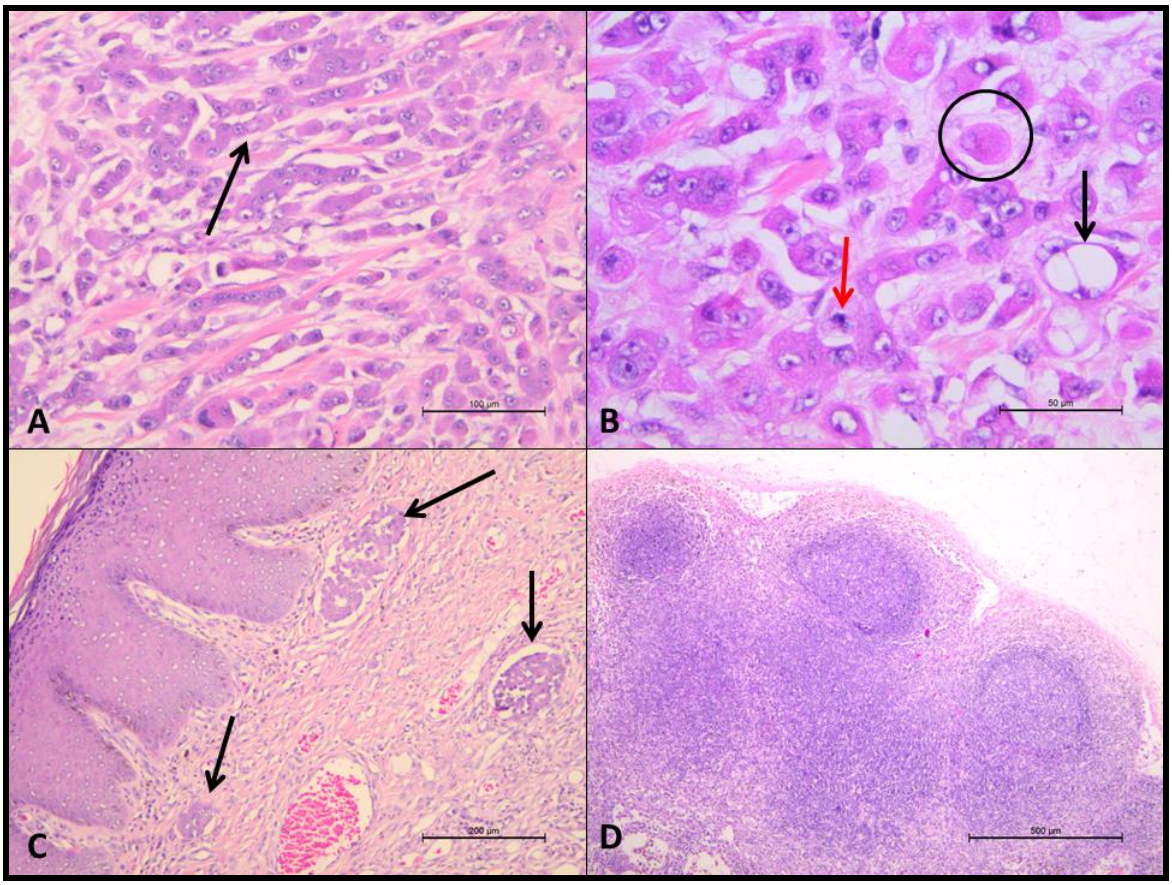

Figure 1. A photomicrograph image of the pleomorphic lobular carcinoma in the described female dog. **A.** Mammary gland. Neoplastic proliferation of linearly arranged epithelial cells. **B.** Neoplastic cells with abundant eosinophilic cytoplasm with eccentric nucleus (circle), sometimes containing cytoplasmic vacuoles (black arrow). Mitosis figure (red arrow). **C.** Neoplastic emboli in superficial dermis lymphatic vessels. **D.** Metastasis-free inguinal lymph node. (Hematoxylin and eosin).

The immunohistochemistry (IHC) reactions were developed using the Kit Easylink One (EasyPath). The paraffin sections were dewaxed in xylene and rehydrated through a series of graded alcohols. The sections were placed in buffer and were subjected to heat retrieval using a pressure cooker for 30 minutes. After antigen retrieval, the samples were allowed to cool for 15 minutes at room temperature. Endogenous peroxidase activity and proteins were blocked according to the manufacturer's protocol. The specimens were incubated for 60 minutes with the primary antibodies specified in Table 1. After the incubation with primary antibody, the slides were incubated with the visualization system and then with the chromogen substrate, liquid diaminobenzidine (DAB). The slides were then stained with hematoxylin, dehydrated in a series of alcohols and permanently mounted with Permount polymer (Fischer, Fairlawn, NJ). For negative controls, the primary antibodies were replaced by the antibody dilution buffer used in the reaction and the positive controls were cases of breast carcinoma known to be positive for the markers used.

Table 1. List of antibodies applied and their results.

Antibody	Clone	Brand	Dilution	Cell Localization	Result
β-Catenin	β-Catenin-1	Dako, Glostrup, Denmark	1:400	membrane, cytoplasmatic and/or nuclear	Focal positive (cytoplasm)
Cyclin D1	SP4	LabVision, CA, USA	1:200	nuclear	Positive
E-cad	NCH-38	Dako, Glostrup, Denmark	1:150	membrane, cytoplasm	Focal Positive (membranous)
CK LMW	35βH11	Dako, Glostrup, Denmark	1:100	cytoplasm	Negative
CK HMW	34βE12	Dako, Glostrup, Denmark	1:300	cytoplasm	Diffuse positive
HER-2*	SP3	Cell Marque, CA, USA	1:200	membrane	Negative
PR	16	Receptor Novocastra, Newcastle upon Tyne, UK	1:200	nuclear	Negative
ER	6F11	Novocastra, Newcastle upon Tyne, UK	1:400	nuclear	Negative
Ki-67	MIB-1	Dako, Glostrup, Denmark	1:300	nuclear	Positive 25%

CK LMW (Low molecular weight cytokeratin); CK HMW (High molecular weight cytokeratin); PR (progesterone receptor); ER (estrogen receptor)
HER-2*- score 0 according to ASCO/CAP 2013 (7).

Immunohistochemically, neoplastic cells revealed positive immunoexpression of β-catenin (Fig. 2A), CK HMW (Fig. 2B), cyclin D1(Fig. 2C), Ki-67 (25% of positive cells) (Fig. 2D) and E-cad (Fig. 3), and negative immunoreactivity for ER, PR, HER-2 receptor, and CK LMW. Since loss of hormone receptors and HER-2, as well as positive expression for one of the basal markers (CK HMW) were observed, the diagnosis of a pleomorphic lobular carcinoma with an immunophenotype of basal-like triple-negative was stablished. A chemotherapy protocol with 300 mg/m² carboplatin intravenously every 21 days, for a total of 6 cycles was established.

Recurrence was detected by the presence of two nodules in the right axillary thoracic region 7 days after the first chemotherapy session. The cranial nodule presented an irregular appearance of plaque measuring 4 cm in diameter; the caudal nodule was soft and regular in appearance, adhered to the deep tissues, and measured 2 cm in diameter. FNA cytology suggested a mammary carcinoma. Thorax radiographs showed no abnormalities.

The patient returned 19 days after the second chemotherapy session showing dyspnea, tiredness, apathy, and pain unresponsive to medication. During the clinical examination, it observed that the nodules had fused, forming an ulcerated plaque, measuring 8 cm in diameter (Fig. 4). Lung nodules were visualized by thoracic radiographs suggestive of PLC metastasis. Euthanasia was performed after 7 days due to the tumour progression. Necropsy was not authorized by the owner.

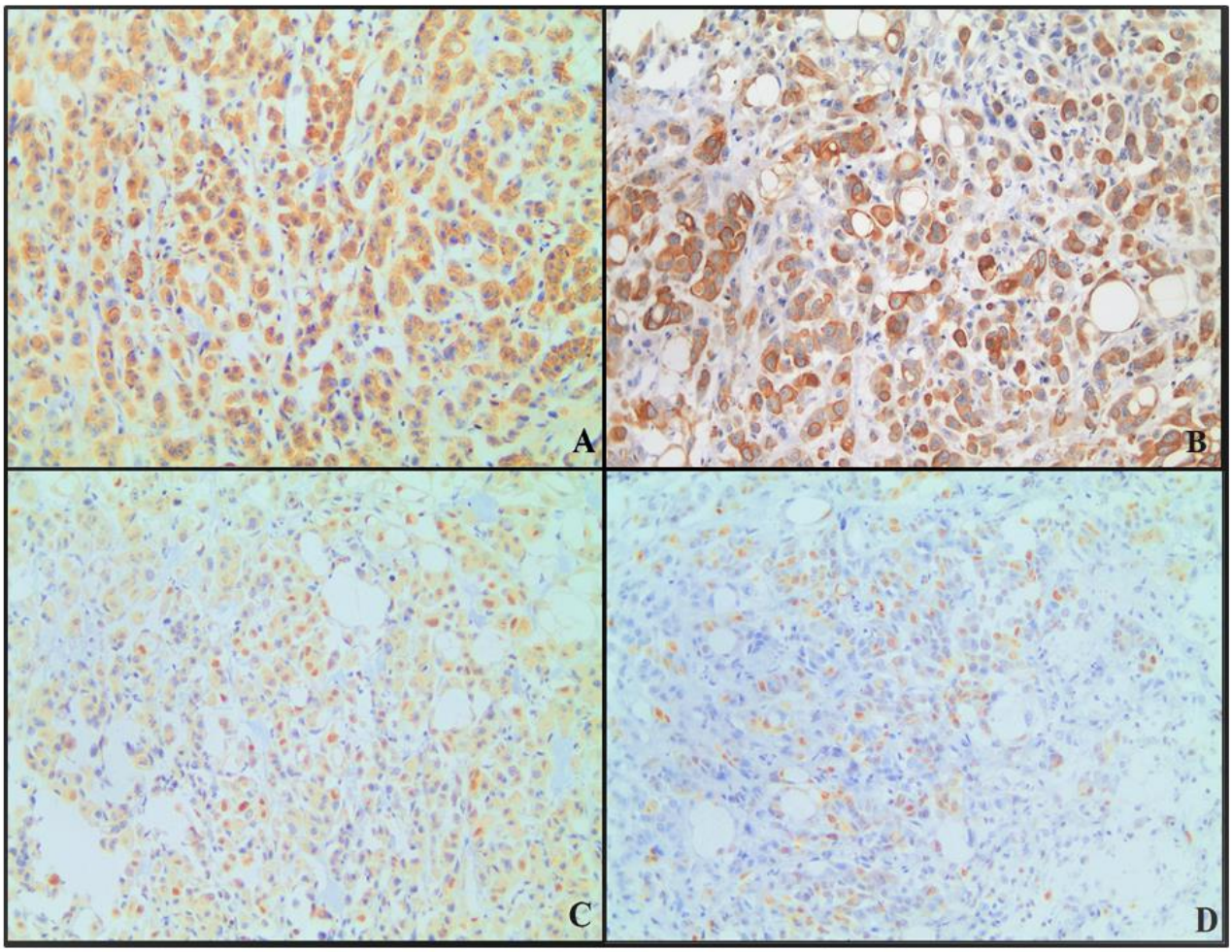

Figure 2. Immunochemistry. **A.** β Catenin – cytoplasm focal positive staining. **B.** Cytokeratin high molecular weight (34βE12) - Diffuse positive-membranous staining. **C.** Cyclin D1 – nuclear positive staining. **D.** Ki67 - nuclear positive staining (25%) (x200).

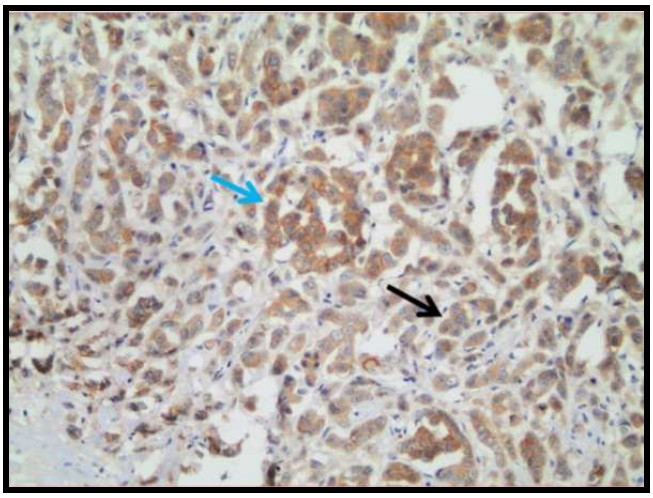

Figure 3. Immunochemistry. E-cad - positive-cytoplasmatic staining (black arrow) with loss of membranous staining (blue arrow) (×200).



Figure 4. Photo of the Shih Tzu female dog, 8 years. Image shows the ulcerated node fused and adhered to the subcutaneous space, measuring 8 cm, with a plaque appearance.

 All rights reserved 2007.

Discussion

PLC is an extremely rare mammary tumor in dogs with few cases described in the literature (1, 2, 7). The characteristics of the histopathological examination, in this study, were consistent with those reported in veterinary and human literature. Scattered epithelial cells arranged in rows, with eosinophilic cytoplasm and eccentric nuclei, and cytoplasmic vacuoles are consistent with the expected findings of PLC (1, 7, 8). Salgado and collaborators (2) state that PLC cells can appear like a plasm cell, or can also have a predominant signet ring cell, in which it presents the nucleus displaced to the periphery, being associated with a more aggressive clinical behaviour than classic invasive lobular carcinoma in humans. Metastases and mitoses are common in PLC (1, 9, 10). D'Assis and collaborators (7) suggested the presence of micrometastases in inguinal lymph nodes, in which they observed a slight reaction of hyperplasia in its parenchyma and unspecific circulatory changes. In our study, we did not observe inguinal lymph node metastasis, but lymphatic emboli in the superficial dermis of the mammary tissue were identified, characterizing metastasis in lymphatic vessels.

There are conflicting data in the literature regarding the expression of ER and PR within PLCs (5). In several studies, PLC is considered immunohistochemically positive for hormone receptors in human and canine females; it is also reported to have a high proliferation rate and expression of HER-2 (2, 5, 7). However, in this study, it was classified as triple-negative pleomorphic lobular carcinoma.

The same pleomorphic variant of triple-negative lobular carcinoma was reported in humans by Manucha and collaborators (11). The authors suggested if the apocrine morphology might have contributed to the triple-negative hormonal profile because most PLCs have apocrine features. Therefore, they suggested evaluating if cytogenetics in such cases are different from the hormone-positive variants of PLC. Based on this suggestion, the same approach could be applied to PLC in this study.

Triple-negative mammary tumours are a type of breast cancer that does not express ER, PR and HER-2 proteins. Patients usually have a predisposition to early recurrence and distant metastasis (12). This type of tumour causes a lower survival rate in women and female dogs because of the aggressiveness of the neoplastic entity (13, 14).

It was also observed in this study the positive immunoexpression of CK HMW, the negative immunoexpression of CK LMW, and classification of the PLC as basal-like triple-negative cancer (14). The term 'basal-like' is applied in tumours that have similar molecular profiles to the myoepithelial/basal cells of the normal mammary gland (15). Few cases of PLC in dogs are reported in the literature, all of them with epithelial origin (2, 7). According to Kim and collaborators (15), most of the triple-negative tumours are basal-like phenotype as 75.6% of them express basal markers and are associated with a high histological grade. A study conducted by Kim and collaborators (14) reports that 89.3% of 28 triple-negative carcinoma were identified as basal-like triple-negative and the majority of animals were of Shih Tzu breed with advanced-age, as observed in this study.

As described in the literature and supporting the clinical observation of its aggressive nature, PLC has a significantly higher proliferative index than classical ILC, as demonstrated by Ki-67 proliferative index, which reinforces its higher mitotic activity (5-7). Ki-67 expression increases with malignancy, and a nuclear staining of more than 24% is considered positive (16). The immunostaining of Ki-67 has important prognostic relevance in canine primary mammary carcinomas with lymph node metastasis and angiolymphatic invasion being related to poor prognosis and shorter overall survival of dogs with a high Ki-67 index (16).

The E-cad receptor is the major transmembrane component of the adherent junctions in epithelial cells of all organs, and cadherin-catenin complexes play an important role in tumour invasion and proliferation (17). These complexes are thought to influence metastasis and invasion by a process involving loss of cell adhesion (6). In humans, the absence of E-cad membranous staining is characteristic of lobular carcinomas, including PLC (5). In canine mammary lesions, absent or low E-cad expression was associated with loss of β-catenin expression (2, 6, 7), however, in our study, the analysis of E-cad expression showed cytoplasmic positivity with loss of membranous staining in neoplastic epithelial mammary cells and the positive β-catenin receptor.

The cytoplasmatic positivity of β-catenin is often associated with E-cadherin cytoplasmic positivity in some malignant less-differentiated tumors, being that, the β-catenin cytoplasmic accumulation may be linked to disruption of its catabolism controlled by APC protein, which complexes and degrades β-catenin (18). MATOS and collaborators (17) studied E-cad expression in 77 canine malignant mammary tumours and observed that tubulopapillary carcinomas show high E-cad expression. The formation of tubular and papillary structures requires some degree of morphological organization, which largely depends on adhesion molecules (cadherins and catenins). PLC shows neoplastic epithelial cells in linear patterns.

These authors also observed that non-ulcerated tumours with a diameter smaller than 3 cm had a significantly higher E-cad expression than the larger, ulcerated tumours (17). In this case report, the tumour was non-ulcerated 2 cm nodule, however, presented loss of membranous staining to E-cad. According to Cassali and collaborators (1), the cytoplasmatic positivity for E-cad is an abnormality in the expression pattern for this molecule, also a reduction in E-cad expression is significantly

associated with a higher infiltrative growth and vessel invasion (17).

The vast majority of invasive lobular carcinomas, in women have overexpression of the protein cyclin D1 (19). The cyclin D1 regulates progression through the G phase of the cell cycle and entry into the S phase, in both species (19, 20). It is essential in cellular adhesion, motility, and cellular migration in different cell types, including mammary epithelial cells (21). As cyclin D1 abundance regulates cellular adhesion dynamics, it has been suggested that cyclin D1 may also contribute to cellular growth properties through regulation of cellular substratum interactions, thus, contributing to the invasiveness and/or metastatic phenotype (22). In humans, it has been reported that high expression of cyclin D1 is associated with cell cycle activation and poor prognosis in oestrogen receptor-positive tumours (23).

Studies in dogs demonstrated that cyclin D1 is associated with metabolic, morphological, and protein expression patterns typical of proliferating cells, that, in malignant lesions shows a high percentage of cyclin D1-positive cells and high proliferative rates (20). Although a substantial proportion of ER-negative tumours also express high levels of cyclin D1, the biological role of cyclin D1 signalling in tumours lacking ER remains an area to be explored in both species (24). There are not data about the expression of cyclin D1 in PLC in dogs, however, the relationship between the high proliferative rates and super-expression of cyclin D1 is accordance as same in literature.

Surgery was performed as the treatment of choice, as recommended in the literature (1, 24). Due to the mammary carcinoma diagnosis, chemotherapy was instituted as an adjuvant therapy (1). However, the patient did not respond to therapy and its clinical condition did not improve, and developed metastatic disease. The animal was euthanised, and the overall survival was 47 days after surgery. As described in the literature, PLC had an aggressive, metastatic, poor prognosis and short survival time (1, 2, 7). Similar data reported by D'Assis and collaborators (7) shows a short survival time of 54 days in a PLC case. Although adjuvant chemotherapy was employed, there is a lack of information regarding the use of this approach and its efficacy in mammary canine tumours (1). It is likely that the histological subtype and the molecular phenotype influenced the difficult treatment and poor prognosis (14).

PLC is a rare form of ILC that has unique morphological characteristics and due to its pleomorphism, several immunohistochemical changes are described. In the present study, the basal-like triple-negative phenotype contributed to the progression of the disease and its poor prognosis.

References

1. Cassali GD, Lavalle GE, Ferreira E, Estrela-Lima A, De Nardi AB, Ghever C, Sobral RA, Amorim RL, Oliveira LO, Sueiro FAR, Beserra HEO, Bertagnolli AC, Gamba CO, Damasceno KA, Campos CB, Araujo MR, Campos LC, Monteiro LN, Nunes FC, Horta RS, Reis DC, Luvizotto MCR, Magalhães GM, Raposo JB, Ferreira AMR, Tanaka NM, Grandi F, Ubukata R, Batschinski K, Terra EM, Salvador RCL, Jark PC, Delecrodi JER, Nascimento NA, Silva DN, Silva LP, Ferreira KCRS, Frehse MS, di Santis GW, Silva EO, Guim TN, Kerr B, Cintra PP, Silva FBF, Leite JS, Mello MFV, Ferreira MLG, Fukumasu H, Salgado BS, Torres R. Consensus for the Diagnosis, Prognosis and Treatment of Canine Mammary Tumors – 2013. Braz J Vet Pathol. 2014;7(2):38-69.
2. Salgado BSL, Monteiro N, Colodel MM, Figueiroa FC, Nonogaki S, Rocha RM, Rocha NS. Cytohistological and immunohistochemical features of a mammary invasive pleomorphic lobular carcinoma in a dog. Comp Clin Pathol. 2012;21:495-9.
3. Narendra S, Jenkins SM, Nassar A. Clinical outcome in pleomorphic lobular carcinoma and pleomorphic lobular carcinoma in-situ. Ann Diagn Pathol. 2015;19:64-9.
4. Cassali GD, Gartner F, Schmitt FC. Pleomorphic lobular carcinoma of the canine mammary gland: histopathologic and immunohistochemical features. Arq Bras Med Vet Zoo. 2002;54:592-4.
5. Butler D, Rosa M. Pleomorphic lobular carcinoma of the breast a morphologically and clinically distinct variant of lobular carcinoma. Arch Pathol Lab Med. 2013;137:1688-92.
6. Brunetti B, Sarli G, Preziosi R, Monari C, Benazzi C. E-cadherin and b-catenin reduction influence invasion but not proliferation and survival in canine malignant mammary tumors. Vet Pathol. 2005;42:781-7.
7. D'Assis MJMH, Silva LP. Machado MCA, Nascimento NA, Damasceno KA, Cassali GD, Estrela-Lima A. Pleomorphic lobular carcinoma of the mammary gland in female dog subject to chemotherapy with carboplatin - Case report. Rev Bras Med Vet. 2016;38:139-46.
8. Rakha EA, Deurzen CHM, Paish EC, Macmillan RD, Ellis IO, Lee AH. Pleomorphic lobular carcinoma of the breast: is it a prognostically significant pathological subtype independent of histological grade? Modern Pathol. 2013;26:496-501.
9. Salgado BS, Monteiro LN, Cassali GD, Rocha NS, Gärtner F. Rare histotypes of canine mammary neoplasms. SJVS. 2014;1:1-6.
10. Flecher MC, Lima Silva DT, Dos Santos VC, Cassali GD, Salgado BS. *In situ* and invasive mammary pleomorphic lobular carcinomalike neoplasm in a dog. 5º CBPV – Congresso Brasileiro de Patologia Veterinária. 2019 Jul 15-18 Ribeirão-Preto (Brasil): ABPV – Associação Brasileira de Patologia Veterinária. p.1.

11. Manucha V, Khilko N, Reilly K, Zhang X. Invasive pleomorphic lobular carcinoma, negative for ER, PR and Her/2neu - a case report. Int J Clin Exp Patho. 2011;4:200-5.
12. Jasar D, Smichkoska S, Kubelka K, Filipovski V, Petrushevska G. Expression of p53 protein product in triple negative breast cancers and relation with clinical and histopathological parameters. Pril. 2015;36:69-79.
13. Im KS, Jang YG, Shin JI, Kim NH, Lim HY, Lee SM, Kim JH, Sur JH. CD44+/CD24–cancer stem cells are associated with higher grade of canine mammary carcinomas. Vet Pathol. 2015;52:1041-4.
14. Kim HW, Lim HY, Shin JI, Seung BJ, Ju JH, Sur JH. Breed- and age-related differences in canine mammary tumors. Can J Vet Res. 201;80:146-55.
15. Kim NH, Lim HYK, Im S, Kim JH, Sur JH. Identification of triple-negative and basal-like canine mammary carcinomas using four basal markers. J Comp Pathol. 2012;148:298-306.
16. Araújo MR, Campos LC, Damasceno KA, Gamba CO, Ferreira E, Cassali GD. HER-2, EGFR, Cox-2 and Ki67 expression in lymph node metastasis of canine mammary carcinomas: Association with clinical-pathological parameters and overall survival. Res Vet Sci. 2016;106:121-30.
17. Matos AJF, Lopes C, Carvalheira J, Santos M, Rutteman GR, Gärtner F. E-cadherin expression in canine malignant mammary tumours: Relationship to Other Clinico-Pathological Variables. J Comp Pathol. 2006;134:182-9.
18. Restucci B, Maiolino P, Martano M, Esposito G, Filippis D, Borzacchiello G, Muzio LL. Expression of, β -catenin, E-cadherin and APC in canine mammary tumors. Anticancer Res. 2007;27:3083-90.
19. Oyama T, Kashiwabara K, Yoshimoto K, Arnold A, Koerner F. Frequent overexpression of the cyclin DI oncogene in invasive lobular carcinoma of the breast. Cancer Res. 1998;58:2876-80.
20. Sfacteria AB, Cervasi C, Bertani M, Paiardini G, Costantino A, Piedimonte GV. [Update on animal models for testing innovative antineoplastic strategies: the mammary tumor in dogs]. Chir Ital. 2001;53:857-68.
21. Velasco-Velázquez MA, Li Z, Casimiro M, Loro E, Homsi N, Pestell RG. Examining the role of cyclin D1 in breast cancer. Future Oncol. 2011;7:753-65.
22. Fu MC, Wang Z, Li T, Sakamaki RG, Pestell. Minireview: Cyclin D1: Normal and Abnormal Functions. Endocrinology. 2004;145:5439-47.
23. Ahlin C, Lundgren C, Embretsen-Varro E, Jirstrom K, Blomqvist C, Fjällskog M. High expression of cyclin D1 is associated to high proliferation rate and increased risk of mortality in women with ER-positive but not in ER-negative breast cancers. Breast Cancer Res Tr. 2017;16:667-78.
24. Karayannopoulou M, Lafioniatis S. Recent advances on canine mammary cancer chemotherapy: A review of studies from 2000 to date. Revue Méd Vét. 2016;167:192-200.