



Original Full Paper

## Clinical features of indurative mastitis caused by caprine arthritis encephalitis virus

Lilian Gregory<sup>1\*</sup>, Eduardo H. Birgel Junior<sup>1</sup>, Maria C. C. S. H. Lara<sup>2</sup>, Marcelo Angelini<sup>1</sup>, Wanderley P. Araújo<sup>1</sup>, Huber Rizzo<sup>1</sup>, Paulo C. Maiorka<sup>1</sup>, Roberto S. Castro<sup>3</sup>, Ana C. M. Kiraly<sup>1</sup>, Fernando J. Benesi<sup>1</sup>, Eduardo H. Birgel<sup>1</sup>

<sup>1</sup>Faculdade de Medicina Veterinária e Zootecnia, Universidade de São Paulo

<sup>2</sup>Instituto Biológico – APTA – SAA

<sup>3</sup>Universidade Federal Rural de Pernambuco

\*Corresponding author: Lilian Gregory, <sup>1</sup>Faculdade de Medicina Veterinária, Universidade de São Paulo. Av. Prof. Orlando Marques Paiva, 87. CEP 05508-900. São Paulo, SP, Brazil. E-mail: [lgregory@usp.br](mailto:lgregory@usp.br)

Submitted June 19<sup>th</sup> 2009, Accepted August 10<sup>th</sup> 2009

### Abstract

Forty seven mammary glands affected by indurative mastitis were analyzed in order to study parenchyma alterations caused by caprine arthritis encephalitis virus. The study was based on physical examination of the animals and physical-chemical characteristics of the milk. Diagnosis was based on physical examination, serological results, PCR of the milk and histopathology from the mammary tissue. Physical examination showed that indurative process affected the parenchyma of all animals. In many cases, there were nodules of different sizes. PCR detected the virus in the parenchyma and milk of many animals showing that mastitis was caused by a virus. Only 2.35% (47/2000) of the glands evaluated showed consistency alterations related to the virus. PH, chloride content and electroconductivity, as well as somatic cells counts, were greater in animals infected by CAE virus. Alterations in the consistency of the mammary parenchyma were observed in the 25 animals infected. Diameter of the nodules in the parenchyma of eight glands ranged from 1 to 3 cm. Retromammary *lymphnodes* were enlarged in 4 of 47 glands (8.5%). No clumps were observed in milk samples, but secretion had an aqueous appearance. From the 34 milk samples analyzed, 18/34 (52.9%) showed normal physical-chemical parameters; 9 showed one or two abnormal parameters, and 7 showed 3 or more abnormal parameters.

**Key Words:** Goats, arthritis, encephalitis, mastitis, virus

### Introduction

Caprine arthritis encephalitis virus (CAE) is classified as a RNA-virus in the *Retroviridae* family, *Lentivirinae* subfamily, *Lentivirus* genus (Lara, 2005). This virus has been associated with syndromes that include arthritis and pneumonia in adult animals, leukoencephalomyelitis in young animals and indurative mastitis in dairy goats (Angelopoulou et al., 2008). The study of CAE virus prevalence has involved researchers from different parts of the world concerned with the actual situation of the disease in goat herds. In Brazil, serological surveys were carried out in Rio Grande do Sul,

Pernambuco, São Paulo, Piauí, Ceará, Minas Gerais, Rio de Janeiro and Bahia states (Fernades, 1997). Results have been alarming for both breeders and veterinarians, for an ever-growing number of animals were affected every year, and the number of virus-free herds decreased substantially. When indurative mastitis ensues, the mammary gland of goats show gradual and diffuse hardening, presence of several hard nodules, and asymmetry of the halves (Lerondelle et al. 1995, 1999). Histopathological changes showed perivascular and gland parenchyma infiltration by mononuclear cells, with *lymphoproliferation* and hyperplasia of lymphoid follicles, many times involving to

alveoli calcification and necrosis (Zwahlen et al., 1983; Gonzales et al., 1987; Cheevers e McGuire, 1988; Perk, 1988, Gregory et al. 2006). Decrease in milk yield in goats affected by CAE virus was demonstrated by Bohland (1998). Healthy goats produced from 25 to 31% more milk and lactations up to 17% longer than infected animals. Birgel Jr et al. (2005), on the occurrence of indurative mastitis, observed that from 97 glands evaluated by palpation, diffuse hardening was diagnosed in 19.68% of CAE virus infected animals. Lara et al. (2005), studying the clinical forms of caprine arthritis encephalitis, showed that indurative mastitis affected 6.6% of the seroreagent goats. According to Birgel Jr et al. (2005) infection by the virus significantly affects physical-chemical and cellular characteristics of goat milk. Electroconductivity, chloride content and somatic cell counts were greater in goats infected by the virus, with or without signs of diffuse hardening. Protein, fat and total solid contents were lower only in the group of goats infected by the virus and showing signs of diffuse hardening.

A review of the literature showed that there is a lack of Brazilian studies on clinical signs of indurative mastitis in goats. Studies that evaluate the importance of this clinical mastitis form in our country are extremely necessary. Therefore, the objective of the present study was to evaluate clinical aspects of mastitis caused by the infection by CAE virus.

## Material and methods

Forty seven mammary glands of Saanen, Brown Alpine and Toggenburg goats affected by indurative mastitis were analyzed. Animals were bred in the state of Sao Paulo. Diagnosis of indurative mastitis was based on physical examination, serology and PCR results and histopathological examination of biopsies from two glands affected. Physical examination was carried out by means of traditional methods in semiology as described by Birgel (1982). Milk pH was determined by means of a potentiometer Electroconductivity (Milku Mastitron) was determined in the milk parlor, just after samples were collected. Chloride content was determined by means of colorimetric titration in a chloride analyzer (Cornel Model 925). Milk samples were kept in a water bath at 38°C for 15 minutes before they were analyzed. They were then manually homogenized and lactose, fat, protein and total solid contents were determined by means of infrared radiation using a Bentley 2000 infrared instrument (Bentley Instruments Inc.). Somatic cell counts were carried out by two different techniques traditionally accepted in mammary gland semiology and in sanitary milk production; respectively, *California Mastitis Test* – CMT, according to Schalm et al. (1971) and flow cytometry using a Somacount 500 ( Bentley Instruments Inc.).

Serum samples collected were kept frozen at -20°C, until the moment they were used in the analysis.

Immunodiffusion in agar gel (IDAG) was used in the detection of serum antibodies against CAE according to Crawford and Adams (1981), using the Caprine Arthritis-Encephalitis Antibody Test Kit (Central Veterinary Laboratory, New Haw, UK). Collection of mammary gland tissue samples was performed by aspirative biopsy. Fragments were fixed in formalin 10 % and stained by Hematoxilin-eosin.

PCR was performed using proviral DNA extracted from milk by means of the phenol / chloroform / isoamyl alcohol method. Primers used were specifically generated for a conserved fragment of the *pol* gene, located between positions 2198 and 2650 (Leroux et al., 1995). Amplification was carried out at 94°C for 5 minutes and 35 denaturation cycles at 94°C for 1 minute; annealing at 60°C for 1 minute and extension at 72°C for 1 minute. Finally, 72°C for 8 minutes and 4°C until the moment of sample collection. Samples were analyzed by electrophoresis in 1.5% agarose gel in TBE buffer, stained with ethidium bromide and observed under ultraviolet light.

Graphpad Instat version 3 was used in order to calculate arithmetic means, standard deviation of the means and variation coefficient of the results obtained for physical-chemical and cellular characteristics of milk, as well as to compare means obtained in the different experimental groups. Firstly, results were submitted to variance analysis, and difference between means was evaluated by the t test in parametric samples, and Mann Whitney test in non-parametric samples. Significance level was set at 5% ( $p \leq 0.05$ ) (Berquó et al., 1981)

## Results

In the present study 2,000 halves were palpated and 47 of them (2.35%) showed changes in consistency related to the virus. Evaluation of these alterations is shown in Figures 1, 2, 3 and 4. The specific examination of the mammary gland of these 25 animals demonstrated that consistency alterations were bilateral in 22 animals (88%) and unilateral in 3 animals (12%) (Fig.1). From the 47 abnormal halves, 8 (17%) showed disperse nodules in the parenchyma, ranging from 1 to 3 cm in diameter; 33 of them (70.2%) showed diffuse hardening and 6 showed atrophy (12.8%) associated with hardening. Atrophy was considered to be the late evolutive phase of the mammary disease. The evaluation of retromammary lymphnodes showed that in 4 of the 47 halves (8.5%) lymphnodes were enlarged. Palpation of one of the 47 halves (2.1%) showed to be painful to the animal. No milk sample showed any clumps, but secretion was aqueous.

Table 1 shows mean values obtained for physical-chemical and cellular characteristics of 34 samples collected from 34 affected glands. From these samples, 18/34 (52.9%) showed normal parameters, 9 (26.47%) showed one or two abnormal parameters and 7 (20.59%) showed 3 or more abnormal physical-chemical parameters.

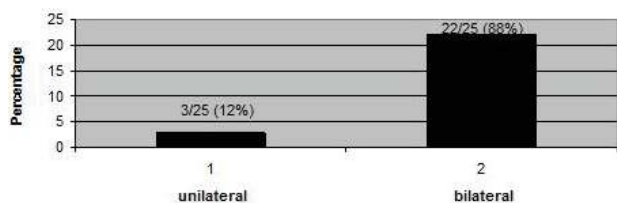


Figure 1 – hardening of the mammary gland caused by caprine arthritis encephalitis virus.

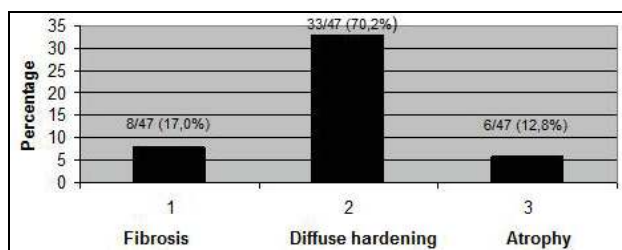


Figure 2 – Type of changes in the mammary parenchyma observed in animals affected by indurative mastitis.

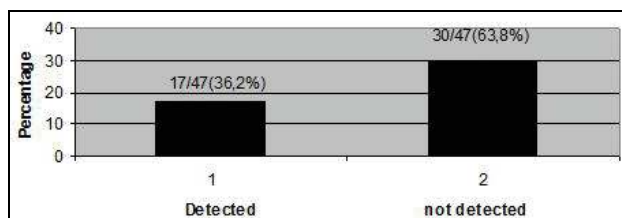


Figure 3 – Milk samples positive for caprine arthritis encephalitis virus by means of PCR

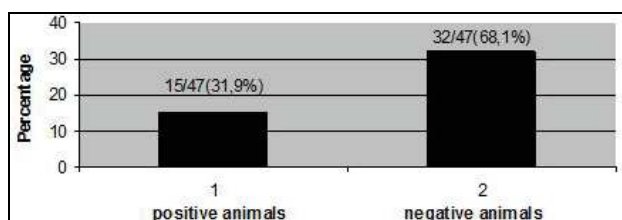


Figure 4 – Bacteriological examination of milk.

Table 1 – Means and standard deviation of physical-chemical and cellular parameters in the milk of goats affected by indurative mastitis caused by CAE virus infection.

Milk parameter	Mean values
Electroconductivity (mS/cm)	6.99 ± 1.01
pH	6.76 ± 0.29
Chloride (mg/dl)	178.6 ± 40.3
Lactose (g/dL)	4.25 ± 0.48
Fat (g/dL)	3.03 ± 1.22
Protein (g/dL)	2.85 ± 0.57
Total solids (g/dL)	10.65 ± 2.12
SCC x 1,000	1544.680 ± 1627.310

In the two animals that were submitted to histopathological examination (Figures 5 and 6), mastitis was characterized by *lymphocitary* infusion, and the main changes observed were: acini showing mononuclear fibrosing and atrophic mastitis; foci of mononuclear cells with calcification of some acini; mastitis with diffuse *lymphocitary* infusion; important interstitial mononuclear mastitis; mastitis lesions; mastitis foci with lympho-neutrophilic infusion and mastitis with mono-leukocytic infusion. Figures 5 e 6, which came from the biopsies of the mammary gland of goats, were classified according to the general histopathological description: moderate atrophy of the epithelium of the gland; fibrosis between lactiferous ducts; scaling of the epithelium inside the ducts, sometimes with the presence of inflammatory cells; some ducts showing internal calcification foci.

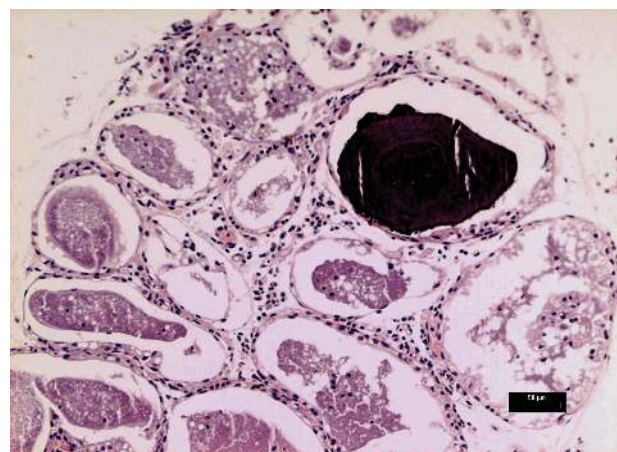


Figure 5 – Mammary tissue with a calcified focus inside a lactiferous duct and presence of mononuclear inflammatory infiltrate (HE, scale bar 50 µm).

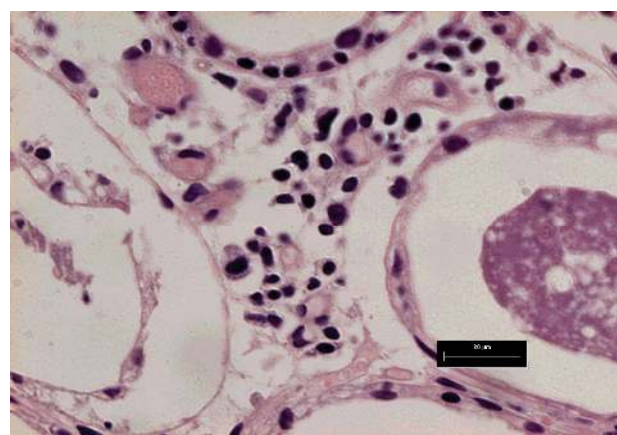
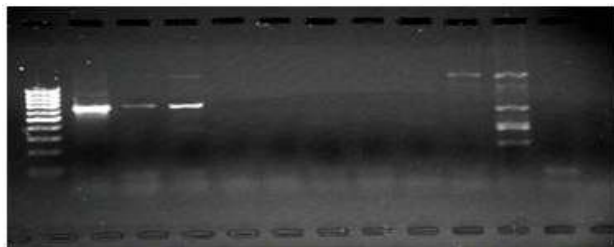


Figure 6 – Mammary tissue. Presence of inflammatory mononuclear cells in the interstice between lactiferous ducts (HE, scale bar 20 µm).

The amplification of proviral DNA showed a 600 bp fragment, corresponding to the result expected for the primers used, as seen in Figure 7. In 17 of the 47 hardened

halves (36.17%) CAE virus was detected by means of the technique, showing that the virus was being shed in the milk.



**Figure 7** – Electrophoresis in 1.5% agarose gel stained with ethidium bromide and observed under UV light. Slot 1: molecular weight standard 100bp DNA ladder. Slot 2: positive control, 600bp (standard strain CAEV Cork). Slots 3 and 4: positive milk samples. Slots 5 to 10: negative samples. Slot 11: positive milk sample. Slot 12: negative sample. Slot 13: negative control.

### Discussion and conclusions

Results of the physical examination of infected goats showed diffuse hardening of the parenchyma of the glands, with some cases of hypotrophy or atrophy of the infected halves, as observed by other authors (Lerondelle et al., 1995; Lerondelle et al., 1999; Lara et al., 2005). Substitution of gland parenchyma by connective tissue and fibrosis observed in the histopathological examination explains the decrease in milk yield described by Bohland (1998), and the quality of milk produced by animals infected by the virus (Birgel Jr et al. 2005). Clinical examination of some animals showed single or multiple nodules that were also reported by these authors, and a significant part of the animals showed diffuse hardening. The atrophy in 12.8% of the glands is suggestive of the late phase of the disease, when mammary volume decreases. Results of the histopathological examination mainly evidenced mononuclear infiltrations and fibrosis with calcification. Comparison between results obtained here and those found in the literature show that the infection by CAE virus was responsible for many significant changes in the glands, as reported by Zwahlen et. al. (1983), Gonzales et al. (1987), Cheevers e McGuire (1988) and Perk (1988).

Results for the physical-chemical characteristics of milk compared with literature data on normal animals showed greater pH, chloride content and electroconductivity. Results obtained on the influence of CAE virus infection on cell composition of goat milk was different from the reports by Smith e Cutlip (1988), who did not observe variation in somatic cell counts from the milk of infected and healthy goats. However, results of the present study are in agreement with those by Ryan et al. (1993), who showed that seropositive animals presented greater somatic cell counts.

Only 20% of the goats showing indurative mastitis presented significant changes in their udders, and

30% showed only partial changes. PCR detected the virus in only 50% of the samples. These data indicated that mammary gland is the target organ of CAE virus, indurative mastitis and clinical alteration was observed in animals infected by the virus.

### References

1. ANGELOPOULOU, K.; POUTAHIDIS, T.; BRELLOU, GD.; GREENLAND, T.; VLEMMAS, 2008. A deletion in the R region of long terminal repeats in small ruminant lentiviruses is associated with decreased pathology in the lung. *The Veterinary Journal* v. 175, p. 346-355
2. BERQUÓ, ES.; SOUZA, JMP.; GOTLIES, SLD, 1981: Bioestatística, Editora Pedagógica e Universitária, São Paulo.
3. BIRGEL, EH., 1982: Leucose linfática e enzoótica dos bovinos adultos, aspectos clínicos e diagnóstico. In: BIRGEL, E H.; BENESI, FJ., 1982: Patologia clínica veterinária. São Paulo: Sociedade Paulista de Medicina Veterinária.. 242-260.
4. BIRGEL JUNIOR, EH.; CESTARI, V.; SAMPAIO, RM.; BIRGEL, DB.; RAIMONDO, RF.; BRANDESPIN, FB.; BIRGEL, EH., 2005: Influência da infecção pelo vírus da artrite encefalite caprina nas características físico-químicas, celulares e microbiológicas do leite de caprinos. In: CONGRESSO BRASILEIRO DE BUIATRIA, 5., 2005, Búzios – RJ. Anais... Rio de Janeiro: Editora. (Resumo).
5. BOHLAND, E., 1998: Artrite Encefalite Caprina: avaliação dos aspectos produtivos e reprodutivos de animais infectados e não infectados. 95p. (Thesis) Faculdade de Medicina Veterinária e Zootecnia, Universidade de São Paulo, São Paulo.
6. CHEEVERS, WR.; MCGUIRE, TC., 1988: The Lentiviruses: MAEDI/VISNA, caprine arthritis-encephalitis and equine infectious anemia. *Adv. Virus Res.* 34, 189-215.
7. FERNANDES, MA., 1997: Artrite-encefalite caprina. Contribuição para o estudo epidemiológico em rebanhos criados no Estado de São Paulo. 83p. (Thesis) Faculdade de Medicina Veterinária e Zootecnia, Universidade de São Paulo, São Paulo.
8. GREGORY, L.; ANGELINI, M.; LARA, MCCSH.; BENESI, FJ.; RIZZO, H.; MAIORKA, PC.; ARAÚJO, W P.; FERNANDES, MA.; KIRALY, ACM.; BIRGEL JUNIOR, EH., 2006. Clinical evaluation of viral indurative mastitis caused by Caprine Arthritis Encephalitis In: XXIV World Buiatrics Congress. Nice, France. *Anais of XXIV World Buiatrics Congress*.
9. GONZALES, L.; GELABERT, J E.; MARLO, JC.; SAEZ de OKARIZ, C., 1987: Caprine arthritis-encephalitis in the Basque country, *Spain. Vet. Rec.* 120, 102-109.

10. LARA, MCCSH., BIRGEL JUNIOR, EH., GREGORY, L., BIRGEL, EH. , 2005: Aspectos clínicos da artrite-encefalite dos caprinos. *Arq. Bras. Med. Vet. Zootec.* 57, 736-740.
11. LERONDELLE, C.; GODET, M.; MORNEX, JF., 1999: Instilation of primary culture of mammary epithelial cells by small ruminant lentiviruses. *Vet. Res.*, 30, 467-74.
12. LERONDELLE, C.; GREENLAND, T.; JANE, M., 1995: Infection of lactating goats by mammary instillation of cell-borne caprine arthritis-encephalitis virus. *J. Dairy Sci.* 78, 850-855.
13. LEROUX, C., CORDIER, G., MERCIER, I., CHASTANG, J., LYON, M., QUERAT, G., GREENLAND, T., VIGNE, R., MORNEX, JF. , 1995: Ovine aortic smooth muscle cells allow the replication of visna-maedi virus in vitro. *Arch. Virol.* 140, 1-11.
14. PERK, K., 1988: Ungulate lentiviruses: Pathogenesis and relationship to AIDS. *Adv. Vet. Sci. Comp. Med.* 32, 97-127.
15. RYAN, DP.; GREENWOOD, PL.; NICHOLS, PJ., 1993: Effect of caprine arthritis-encephalitis virus infection on milk cell count and N-acetyl-beta-glucosaminidase activity in dairy goats. *J. Dairy Res.* 60, 299-306.
16. SCHALM, OW.; CARROL, EJ.; JAIN, NC., 1971: Bovine mastitis. Philadelphia, Lea & Febiger.
17. SMITH, MC.; CUTLIP, R., 1988: Effects on infection with caprine arthritis-encephalitis virus on milk production in goats. *J. Am. Vet. Med. Assoc.* 193, 63-67.
18. ZWAHLEN, M.; AESCHBACHER, M.; BALCER, Th.; STUCKI, M.; WYDER-WALTHER, M.; WEISS und STECK, F., 1983: Lentivirusinfektionen bei Ziegen mit Carpititis und interstitieller Mastitis. *Schweiz. Arch. Tierheilk.* 125, 281-299.