



Case Report

Ulcerative dermatitis due to feline infectious peritonitis virus infection in a cat

Vicente A. Avila¹, Daniel R. Rissi^{2*}

¹Department of Pathology, College of veterinary Medicina and Animal Science, Universidad Nacional Autónoma de México.

²Department of Pathology and Athens Veterinary Diagnostic Laboratory, University of Georgia College of veterinary Medicina and Animal Science GA, USA.

*Corresponding author: Dr. Daniel R. Rissi, Department of Pathology and Athens Veterinary Diagnostic Laboratory, University of Georgia College of Veterinary Medicine, Athens, GA 30602, phone 706 542 5916. E-mail: rissi@uga.edu

Submitted September, 17th 2019, Accepted November, 25th 2019

Abstract

Feline infectious peritonitis (FIP) is one of the most prevalent viral diseases of wild and domestic cats. Despite of its multisystemic character, cutaneous lesions of FIP have been rarely described. A skin biopsy from a 14-month-old male neutered domestic shorthaired cat with a slightly raised, 5 mm in diameter ulcer on the dorsal cervical area and a presumptive clinical diagnosis of FIP was submitted for histological examination. Histological changes consisted of ulcerative dermatitis with perivascular, periadnexal, and interstitial accumulations of neutrophils, macrophages, lymphocytes, and plasma cells with areas of vasculitis. Immunohistochemistry for feline coronavirus revealed intralesional clusters of antigen within macrophages. FIP should be considered in cases of papular to nodular or ulcerative skin lesions in cats when occurring in conjunction with clinical signs of systemic disease consistent with FIP.

Key words: feline infectious peritonitis, feline coronavirus, cat, dermatopathology.

Introduction

Feline infectious peritonitis (FIP) is one of the most prevalent viral diseases of wild and domestic cats (1, 4, 5, 8). Feline infectious peritonitis virus (FIPV) is a mutant strain that arose from feline enteric coronavirus (FECV), which is associated with subclinical or transient gastrointestinal disease in young cats (8). FIP is a multisystemic disease that leads to a wide variety of clinical signs and tissue changes consisting mainly of fibrinous, pyogranulomatous, or lymphoplasmacytic inflammation within affected organs (4, 8). Despite of its multisystemic character, cutaneous lesions of FIP have been rarely described (1, 2, 3, 7) and pose a diagnostic challenge to the pathologist, especially in a surgical pathology setting where a detailed clinical history may be incomplete. This article aims to characterize a case of ulcerative dermatitis due to FIPV infection in a cat.

Case report

A 14-month-old male neutered domestic shorthaired cat was examined because of a slightly raised, 5 mm in diameter area of ulceration on the dorsal cervical area. Physical examination revealed bilateral fibrinous uveitis, which allowed for a presumptive clinical diagnosis of FIP. An excisional biopsy of the cutaneous lesion was immersed in 10% buffered formalin and submitted for histopathology. Tissue sections were routinely processed for histology and stained with hematoxylin and eosin.

Histological changes included diffuse dermal edema and perivascular to interstitial accumulations of eosinophilic strands of fibrin that separated collagen bundles throughout. These changes were more evident around small blood capillaries and hair follicles (Fig. 1). Interstitial, perivascular, and periadnexal areas were also expanded by moderate numbers of neutrophils and macrophages with fewer lymphocytes and plasma cells.

The wall of affected venules or arterioles was partially expanded and disrupted by these inflammatory cells (vasculitis) (Fig. 2). There was a focal area of epidermal loss with mild neutrophilic inflammation of the denuded superficial dermis. Immunohistochemistry (IHC) for feline coronavirus was performed for diagnostic confirmation. IHC was performed on an automated stainer (Nemesis 3600, Biocare Medical, Concord, CA). A mouse polyclonal antibody for feline coronavirus (Custom Monoclonals International, West Sacramento, CA) at a dilution of 1:600 and biotinylated horse anti-mouse at a dilution of 1:100 were used. Antigen retrieval was conducted using Citrate Solution 10X (BioGenex, Fremont, CA) at a dilution of 1:10 for 15 minutes at 110°C. A biotinylated rabbit anti-goat antibody (Vector Laboratories, Burlingame, CA) at a dilution of 1:300 was used to detect the target, and the immunoreaction was visualized using 3,3-diaminobenzidine (DAB, Biocare Medical, Concord, CA) substrate for 12 minutes counterstained with hematoxylin. IHC revealed positive immunolabeling within round cells (most likely macrophages) around areas of vasculitis (Fig. 3). The cat died a few days later but no necropsy was performed.

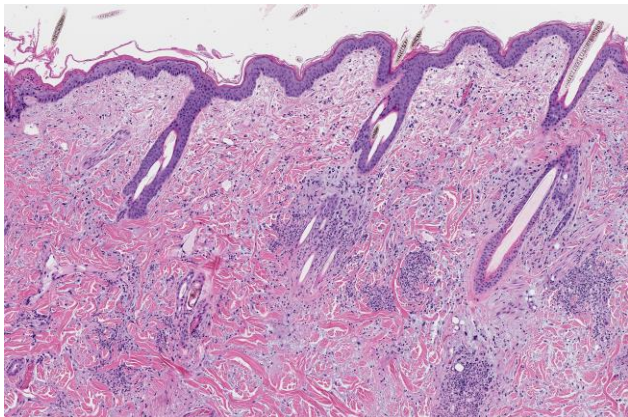


Figure 1. Feline infectious peritonitis virus infection, skin, cat. The dermis is edematous and perivascular, adnexal, and interstitial accumulations of inflammatory cells are distributed throughout (5X, H&E).

Discussion

A diagnosis of ulcerative dermatitis and vasculitis due to FIPV infection was considered after histological evaluation of the submitted sample in the current case because FIP had been presumptively diagnosed clinically and, more importantly, because that information was available in the clinical history. While the described cutaneous changes are consistent with FIPV infection (1, 2, 3, 7), FIP is typically systemic and fatal, and only rarely leads to cutaneous changes during the course of infection. The diagnosis was subsequently confirmed using IHC.

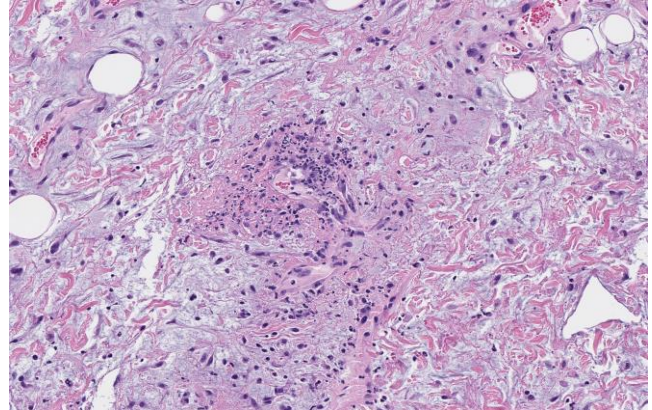


Figure 2. Feline infectious peritonitis virus infection, skin, cat. Clusters of neutrophils and fibrin expand the vascular wall (vasculitis) and the perivascular spaces of a dermal venule (20X, H&E).

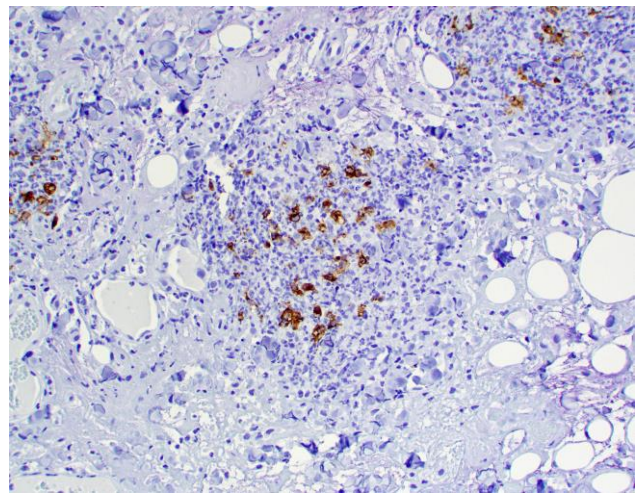


Figure 3. Feline infectious peritonitis virus infection, skin, cat. Clusters of viral antigen within round cells (most likely macrophages) are highlighted using immunohistochemistry (40X, immunohistochemistry for feline coronavirus).

Cutaneous changes associated with effusive or non-effusive FIP are exceedingly rare (1, 2, 3, 7). Based on these reports, cutaneous lesions are characterized by non-pruritic, partially alopecic erythematous papules or nodules that occur on the lateral or dorsal cervical area (2, 3), thoracic limbs (2), thorax (3), lip (7), or disseminated throughout the body (1). As evidenced by our case, lesions can eventually ulcerate (1, 7) and can be focal. Experimentally infected cats tend to develop ulcerative lesions that are predominantly located on the neck and head, similar to the lesion in the current report (6). However, too few cases have been published to determine whether there may be a predisposition for these lesions to affect specific anatomic locations.

Histological changes in the current case were similar to previous reports (1, 2, 3, 7), consisting of the classic changes associated with FIPV infection in other

organs, with mixed inflammatory infiltrates, vasculitis, and exudation of fibrin and edema fluid into the adjacent tissues (4, 5). Based on the anatomic location and the ulcerative nature of the lesion in our case, the main differential diagnosis was feline idiopathic ulcerative dermatosis (FIUD) (9). This is an idiopathic condition of cats that is characterized by ulcerative lesions on the dorsal cervical or interscapular area (9, 10). Although FIUD may clinically resemble our case and other reported cutaneous changes associated with FIPV (6), the main histological features of between these two diseases are distinct. FIUD is characterized by epidermal ulceration with subepidermal linear fibrosis, suppurative inflammation, and vascular thrombosis and lacks fibrin exudation and vasculitis seen in the FIPV-associated lesions (10). In addition, subepidermal linear fibrosis is not a feature of the cutaneous lesions associated with FIP (1, 2, 3, 7). A database search in our web-based archives revealed 4 cases of feline idiopathic ulcerative dermatosis from 2010 to 2019. Cutaneous lesions in all cases were restricted to the dorsal cervical area and exhibited the previously described histological changes. Replicate tissue sections of these cases were subsequently submitted to IHC for FIPV and were negative. No cases of cutaneous lesions associated with FIPV infection were reported in the same period. IHC is an important diagnostic tool to confirm or rule out FIPV infection (4, 5). In our case, IHC revealed clusters of viral antigen within the cytoplasm of macrophages throughout the tissue sections, similar to previous reports (1). A form of skin fragility syndrome characterized by extensive skin tears and exposure of the underlying subcutaneous tissue and skeletal muscle has been described in a cat with FIP and hepatic lipidosis (11). Histological changes in that cat were different from those reported in the current case, and consisted of epidermal and dermal atrophy and telogenic hair follicles (11). The cause of the skin fragility could not be determined, and the authors concluded that the FIP and hepatic lipidosis likely contributed to the development of the cutaneous lesions (11).

The cutaneous changes in this case and other similar cases (1, 2, 3, 7) highlight the need to consider FIP in cases of papular to nodular or ulcerative skin lesions in cats when occurring in conjunction with clinical signs of systemic disease consistent with FIP. Diagnostic confirmation can be achieved by histological examination and IHC.

References

1. Bauer BS, Kerr ME, Sandmeyer LS, Grahn BH. Positive immunostaining for feline infectious peritonitis (FIP) in a Sphinx cat with cutaneous lesions and bilateral panuveitis. *Vet Ophthalmol.* 2013;16:160-3.
2. Cannon MJ, Silkstone MA, Kipar AM. Cutaneous lesions associated with coronavirus-induced vasculitis in a cat with feline infectious peritonitis and concurrent feline immunodeficiency virus infection. *J Feline Med Surg.* 2005;7:233-6.
3. Declercq J, De Bosschere H, Schwarzkopf I, Declercq L. Papular cutaneous lesions in a cat associated with feline infectious peritonitis. *Vet Dermatol.* 2008;19:255-8.
4. Goodson T, Randell S, Moore L. Feline infectious peritonitis. *Compend Contin Educ Vet.* 2009;31:1-8.
5. Kipar A, Meli ML. Feline infectious peritonitis: still an enigma? *Vet Pathol.* 2014;51:505-26.
6. Miller WH, Griffin CE, Campbell KL. Viral, Rickettsial, and Protozoal Skin Diseases. In: Miller WH, Griffin CE, Campbell KL, editors. *Muller and Kirk's Small Animal Dermatology.* St. Louis: Elsevier. 2013. p.343-62.
7. Osumi T, Mitsui I, Leutenegger CM, Okabe R, Ide K, Nishifuji K. First identification of a single amino acid change in the spike protein region of feline coronavirus detected from a coronavirus-associated cutaneous nodule in a cat. *J Feline Med Surg Open Rep.* 2018;4:1-5.
8. Pedersen NC. A review of feline infectious peritonitis virus infection: 1963-2008. *J Feline Med Surg.* 2009;11:225-58.
9. Scott DW. An unusual ulcerative dermatitis associated with linear subepidermal fibrosis in 8 cats. *Feline Pract.* 1990;18:8-11.
10. Spaterna A, Mechelli L, Rueca F, Cerquetella M, Brachelente C, Antognoni MT, Tesei B. Feline idiopathic ulcerative dermatosis: Three cases. *Vet Res Comm.* 2003;27:795-8.
11. Trotman TK, Mauldin E, Hoffmann V, Del Piero F, Hess RS. Skin fragility syndrome in a cat with feline infectious peritonitis and hepatic lipidosis. *Vet Dermatol.* 2007;18:365-9.