BJVP
Brazilian Journal of Veterinary Pathology
ISSN 1983-0246

Case Report

Cholangiocarcinoma in an Australian goose

Thaynara P. Carvalho[1], Daniel O. Santos[1], Nayara F. Paula[1], Larissa G. A. Moreira[1], Ayisa R. Oliveira[1], Pâmela Aparecida Lima[1], Herlandes P. Tinoco[2], Maria Elvira L. T. Costa[2], Carlyle M. Coelho[2], Angela T. Pessanha[2], Renato L. Santos[1*]

[1]Escola de Veterinária, Universidade Federal de Minas Gerais, 31270-901, Belo Horizonte, Minas Gerais, Brazil.
[2]Fundação de Parques Municipais e Zoobotânica de Belo Horizonte, 31365-450, Belo Horizonte, Minas Gerais, Brazil.
[*]**Corresponding author:** RLS. Departamento de Clínica e Cirurgia Veterinária, Escola de Veterinária, Universidade Federal de Minas Gerais, Av. Presidente Antônio Carlos, 6627 – CEP 30161-970, Belo Horizonte, MG, Brazil. Phone: 55-31-3409-2239. Fax: 55-31-3409-2230. E-mail: rsantos@vet.ufmg.br

Submitted October, 11th 2019, Accepted January, 29th 2020

Abstract

Cholangiocarcinomas are neoplasms originating from the biliary epithelium. This report describes the gross, microscopic, and immunohistochemical findings in a case of cholangiocarcinoma in an Australian goose (*Cereopsis novaehollandiae*). The animal had cachexia and ascites. The liver and gallbladder had cystic masses that was diagnosed as a cholangiocarcinoma.

Key words: *Cereopsis novaehollandiae*, goose, neoplasm, hepatic tumor.

Introduction

Primary hepatic carcinomas include hepatocellular carcinomas or cholangiocarcinoma, derived from hepatocytes or biliary epithelium, respectively. Cholangiocarcinoma is a malignant neoplasm composed of epithelium resembling the biliary epithelium. This neoplasm usually has an invasive pattern of growth, and it may metastasize within the liver and to other organs (4). Cholangiocarcinoma is often diagnosed in domestic animal species particularly in the dog (4), but it has been previously reported in some species of birds, including ducks (3), ring-necked pheasant (8), Senegal firefinch (8), flamingo (12), penguin (9), peach-fronted conure (5), American rhea (10), and domestic chickens (7). Predisposing factors for this neoplasm in humans and some mammalian species include chronic inflammation and intraductal parasitism (4). *Platynosomus fastosus*, a trematode parasite of the biliary tract of cats has been associated with cholangiocarcinoma. Canine intestinal parasites, including *Ancylostoma* sp. and *Trichuris vulpis* has been associated with a increase risk of cholangiocarcinoma (4). This report describes a cholangiocarcinoma in an Australian goose diagnosed based on gross findings, histopathology, and immunohistochemistry.

Case report

An adult male Australian goose (*Cereopsis novaehollandiae*) was found apathetic in its enclosure at the Belo Horizonte Zoological Garden. The animal was admitted at the zoo veterinary hospital, but quickly progressed to death. Grossly, the animal was cachectic, and had pale white mucosae. There was a moderate amount of translucent transudate within the celomic cavity (Fig. 1A). The liver and gallbladder had an encapsulated mass with multiple cysts (Fig. 1B). Samples of the lung, heart, liver, spleen, kidney, brain, and intestines were fixed in 10% buffered formalin, submitted for routine histological processing, stained with hematoxylin and eosin (HE), and evaluated under light microscopy. Immunohistochemistry was performed using pan-cytokeratin (AE1/AE3) monoclonal antibody (Santa Cruz biotechnology, code sc-81714) at 1:2000 dilution incubated for one hour at room temperature.

 All rights reserved 2007.

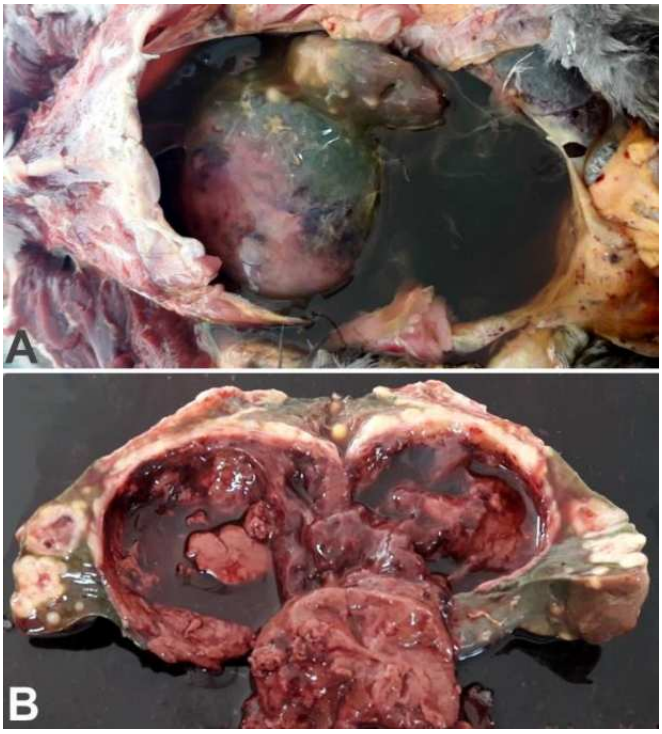

Figure 1. Gross findings in an Australian goose (*Cereopsis novaehollandiae*) with chollangiocellular carcinoma. **A.** Celomatic cavity with abundant accumulation of transudate (ascites). **B.** Liver with a cystic neoplasm.

Microscopically, the proliferative lesion involving the liver and gallbladder was characterized by an epithelial, non-encapsulated, poorly demarcated, and invasive neoplasm. Neoplastic cells were organized in cords or tubules lined mostly by a single cell layer, and some of these tubules contained an eosinophilic acellular material in the lumen (Fig. 2A). Neoplastic cells ranged from cuboidal to polyhedral, with well-defined cytoplasmic boundaries, and an eosinophilic homogenous cytoplasm (Fig. 2B). Nuclei were basal, round to oval, with loose chromatin and evident nucleolus. There was moderate anisocytosis and anisokaryosis. Among the neoplastic tubules there was severe desmoplastic reaction with abundant accumulation of collagen fibers as evidenced by Masson's trichrome (Fig. 2C and D). No mitoses were detected in 10 high power microscopic fields. The neoplastic tissue compressed the adjacent hepatic parenchyma, resulting in hepatocyte atrophy. No other gross changes were observed in any organ. Neoplastic cells consistently expressed cytokeratin (Fig. 3), whereas the adjacent non-neoplastic biliary epithelia stained positively for cytokeratin, thus serving as internal positive controls.

Discussion

In this case there were multiple neoplastic nodules in the liver compressing the adjacent parenchyma, although there were no detectable metastases to other organs. In the liver, metastatic foci are usually morphologically similar to the primary site (4).

Although the etiology of these tumors has not been fully elucidated, cholangiocarcinomas have been associated with chronic hepatic lesions, such as parasitic and toxic injuries (1, 11). In cats, *Platynosomus fastosus,* a trematode parasite of the biliary tract that usually causes asymptomic infections, has been associated with this neoplasm (1). The mechanism by with parasite induces tumor development is unknow. However, it has been demonstrated that metabolites generated by parasites can promote inflammation that results in cytotoxic and mutagenic damages to cellular DNA (11). In birds, chronic exposure to mycotoxins is considered carcinogenic, and commonly associated with hepatic neoplasms (6, 11). Mycotoxins are chemicals produced by a series of fungi that can grow in grains and seeds kept under inadequate storage conditions. A variety of mycotoxins produced by different fungi, particularly aflatoxins produced by *Aspergillus* spp. and *Penicilium* spp., are associated with hepatocellular adenoma and hepatocellular carcinoma. Carcinogenic potential in these cases depend on chronic and continuous ingestion of contaminated food, initially causing degeneration and hepatic fibrosis with ductal hyperplasia and steatosis that may progress to the development of a neoplasm. However, controlled studies on carcinogenesis are lacking in birds (6). Viral infections should also be considered as potential causes of hepatic neoplasms in birds, particularly the duck hepatitis virus or the leucosis virus (2, 4).

Clinical changes often associated with cholangiocarcinomas include lethargy, anorexia, vomiting, and weight loss, whereas ascites and hypoalbuminemia are less common (4). In this case, there was weight loss and ascites, which was likely due to hypoalbuminemia and hepatic fibrosis.

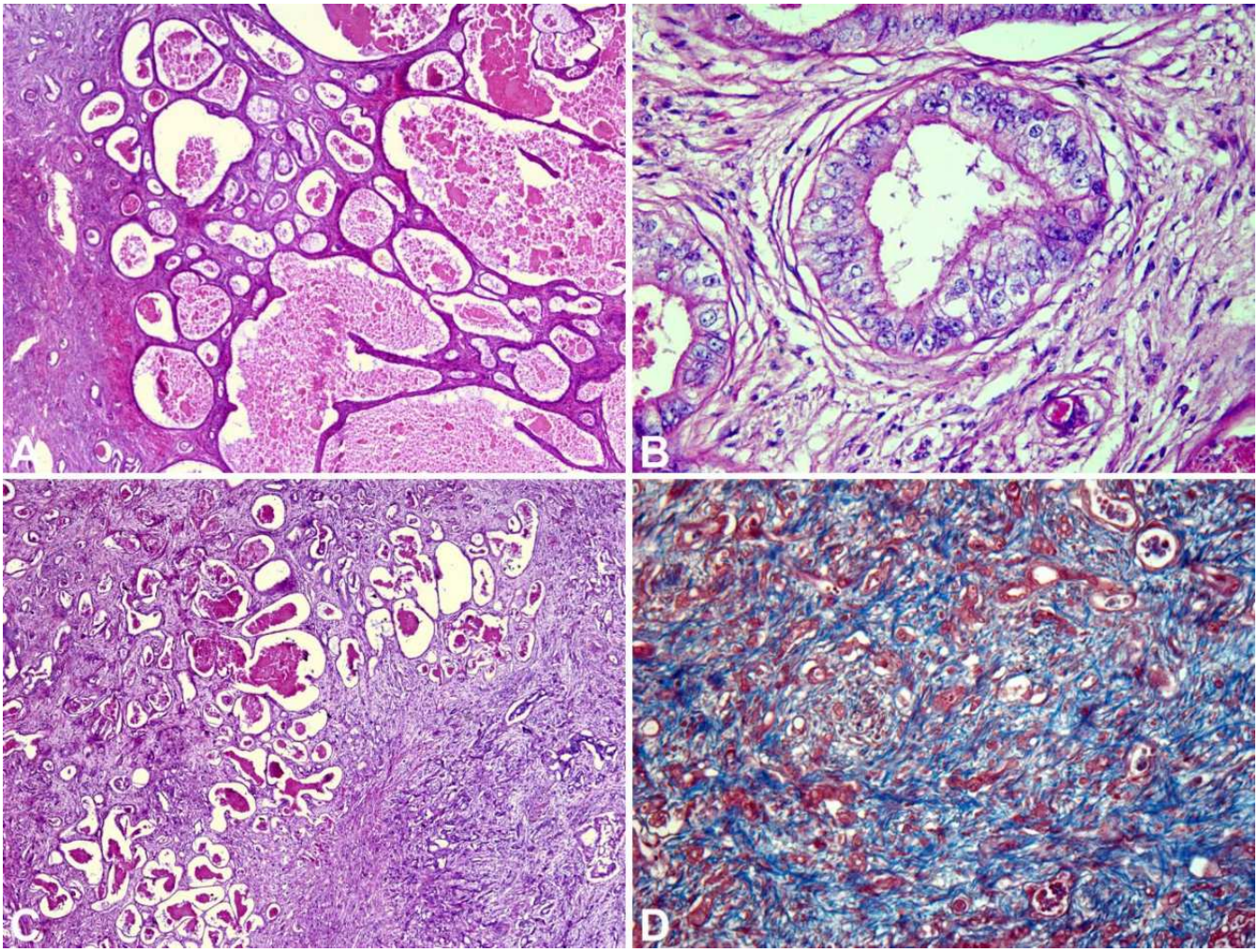

Figure 2. Liver of an Australian goose (*Cereopsis novaehollandiae*) with chollangiocellular carcinoma. **A.** Liver, chollangiocellular carcinoma composed of epithelial cells organized in tubules and cords, 50x, Hematoxylin and eosin. **B.** Neoplastic cells were predominantly cuboidal with well-defined cytoplasmic boundaries. Nuclei were basal and round to oval. Moderate anisocytosis and anisokaryosis. 400x, Hematoxylin and eosin. **C.** Intense desmoplastic reaction 50x, Hematoxylin and eosin, and **D.** Abundant collagen deposition in areas of desmoplasia. Masson's trichrome.

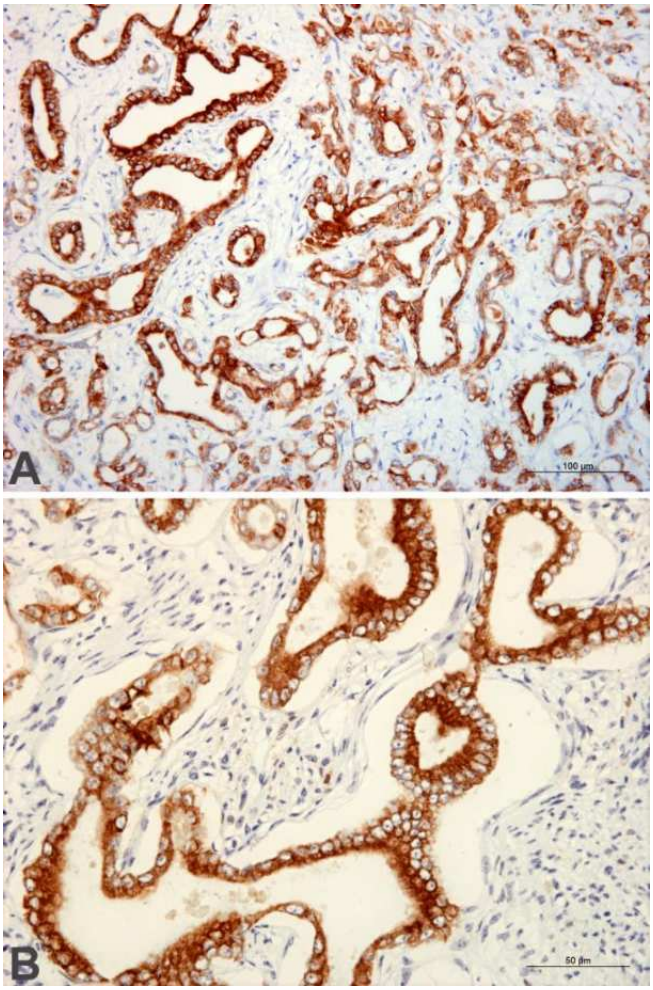

Figure 3. Immunohistochemistry for cytokeratin of chollangiocellular carcinoma in liver of an Australian goose (*Cereopsis novaehollandiae*). **A.** Neoplastic cells strongly and diffusely positive for pancytokeratin. Immunohistochemistry with diaminobenzidine as chromogen; counterstained with hematoxylin, 400x and **B.** 50x.

References

1. Andrade RLFS, Dantas AFM, Pimentel LA, Galiza JN, Carvalho FKL, Costa VMM, Riet-Correa F. *Platynosomum fastosum*-induced cholangiocarcinomas in cats. Vet Parasitol. 2012;190(23):277-80.
2. Beard JW, Hillman EA, Beard D, Lapis K, Heine U. Neoplastic response of the avian liver to host infection with strain Mc29 leukosis virus. Cancer Res. 1975;35:1603-27.
3. Campbell JG. Spontaneous hepatocellular and cholangiocellular carcinoma in the duck; an experimental study. Br J Cancer. 1949;3(2):198-210.
4. Cullen JM, Popp JA. Tumors of the liver and gall bladder. In: Meuten DJ. Tumors in domestic animals. 4th ed. Ames: Iowa State. 2017. p.483-508.
5. Gibbons PM, Bush MD, Tell LA, Graham JE, Lowensine LJ. Internal papillomatosis with intrahepatic cholangiocarcinoma and gastrointestinal adenocarcinoma in a peach-fronted conure (*Aratinga aurea*). Avian Dis. 2002;46:1062-9.
6. Godoy SN. Psittaciformes. In: Cubas ZS, Silva JR, Catão-Dias JL, editors. Tratado de Animais Selvagens - Medicina Veterinária. São Paulo: Editora Roca. 2017. p.222-51.
7. Goyl D, Singh A, Sood N, Gupta K, Sood NK. A rare case of cholangiohepatocellular carcinoma in poutry. Indian J Vet Pathol. 2005;29:52-3.
8. Lombard LS, Witte EJ. Frequency and types of tumors in mammals and birds of the Philadelphia Zoological Garden. Cancer Res. 1959;19:127-41.
9. Renner MS, Zaias J, Bossart GD. Cholangiocarcinoma with metastasis in a captive Adelie penguin (*Pygoscelis adeliae*). J Zoo and Wildl Med. 2001;32:384-6.
10. Rocha PRDA, Lopes LL, Arruda LP, Pescador CA, Cruz RAS, Colodel EM. Cholangiocarcinoma in an American Rhea (Rhea Americana araneipes). Cienc Rural. 2015;45(2):284-7.
11. Sripa B, Kaewkes S, Sithithaworn P, Mairiang E, Laha T, Smout M, Pairojkul C, Hudhisawasdi VB, Tesana S, Thinkamrop B, Bethony JM, Loukas A, Brindley PJ. Liver flukes induces cholangiocarcinoma. PLoS Med. 2007;4:1148-55.
12. Wadsworth PF, Majeed SK, Branker WM, Jones DM. Some hepatic neoplasms in non-domesticated birds. Avian Pathol. 1978;7:551-5.