Braz J Vet Pathol, 2020, 13(2), 519 – 523
DOI: 10.24070/bjvp.1983-0246.v13i2p519-523

BJVP
Brazilian Journal of Veterinary Pathology
ISSN 1983-0246

Case Report

Spongiform leukoencephalopathy in an adult mixed breed female dog

Juan A. García[1], Martí P. Batlle[2], Agustín Romero[3], Eduardo Alvarez[4], Fernando Dutra[3*]

[1]CONICET, Buenos Aires, Argentina.
[2]Unidad de Patología Murina y Comparada (UPMiC), Departamento de Medicina y Cirugía Animales, Universitat Autònoma de Barcelona, 08193 Bellaterra (Cerdanyola del Vallès), Barcelona, España.
[3]DILAVE Regional Este, Treinta y Tres, Uruguay.
[4]Facultad de Veterinaria, Universidad de la República, Montevideo, Uruguay.
[*]**Corresponding author:** DILAVE "Miguel C Rubino" Regional Este, Treinta y Tres, Avelino Miranda 2045, CP33000, Treinta y Tres, Uruguay. E-mail: fdutra@mgap.gub.uy.

Submitted February, 26th 2020, Accepted March, 25th 2020

Abstract

Leukoencephalomyelopathy is a nonspecific lesion characterized by widespread vacuolation of central nervous system white matter. It is mainly of genetic basis, occurring in young pure breed dogs. This report describes a neurodegenerative disease associated to demyelination in an adult mixed breed female dog. After 20 days in a kennel with 12 other dogs, the dog showed progressive nervous signs with ataxia and inability to maintain balance. No other dog was affected. After 15 days, the animal was euthanized *in extremis* and necropsied. No macroscopic lesions of diagnostic relevance were present. Microscopically, *status espongiosus* was observed in white matter throughout the length of the neuroaxis, from frontal brain lobe to lumbar spinal cord. Specific stains of Kluver Barrera and immunohistochemistry for the detection of phosphorylated and non-phosphorylated neurofilaments, microglia, astrocytosis, oligodendrocytosis and myelin proteins in brain and spinal cord sections showed demyelination, axonal fragmentation and degeneration, microgliosis and decrease of oligodendrocytes. The anatomopathological study and epidemiological data suggests a primary demyelination due to decrease in number and function of oligodendrocytes, which is probably of genetic basis with late onset.

Key words: neurodegenerative disease, domestic animals, neuropathology, genetic disease.

Introduction

Leukoencephalomyelopathy associated to *status spongiosus* is a nonspecific lesion characterized by widespread vacuolation of the central nervous system white matter (16, 26). It is a neurodegenerative disease due to several factors such as hereditary, nutritional, immunological or exposition to toxics (8, 9, 13, 19, 20). When the degenerative disorder affects myelin, demyelination occurs and it can be primary or secondary, being the first by direct damage of myelin sheaths, while the latter most commonly happens after axonal damage (29). The disorder can have early onset in life due to failure of myelin synthesis, or late onset due to loss of myelin (15). It is characterized by a progressive neurological deterioration that includes ataxia, hypermetria and paresis of all four limbs, mostly it has a genetic basis, affecting young (< 2 years) pure breed dogs (6, 25, 27). There are few reports of late onset spongiform leukoencephalopathy in adult dogs suggesting a genetic origin (17, 18, 25).

Case Report

The affected dog was a 5 year old mixed breed female. The dog stayed 20 days in a shelter, and after that

Braz J Vet Pathol, 2020, 13(2), 519 – 523
DOI: 10.24070/bjvp.1983-0246.v13i2p519-523

period it presented clinical signs of emaciation, inability to maintain balance, lethargy, anisocoria, horizontal nystagmus and ataxia. At clinical exam, it had normal temperature (39°C), moderately elevated heart rate (140 beats/min) and respiratory frequency (30 breaths/min). Swallowing reflex and laryngeal and digestive function were diminished. Blood samples were collected for hematological studies (blood and leucocytes count and glycemia). Immunochromatography for *Neospora caninum* and *Toxoplasma gondii* and canine distemper virus in serum from blood sample was carried out. After 15 days, clinical signs aggravated, so euthanasia was practiced *in extremis* under owner's approval.

At *post-mortem* examination, generalized muscular atrophy was the only significant macroscopic finding, without any other lesions of diagnostic relevance. Tissue samples, including serial coronal sections of the central nervous system, were fixed in 4% buffered formaldehyde, and 5-µm tissue sections were routinely processed for hematoxylin and eosin (HE) for histopathological examination. Tissue sections of brain and spinal cord, from cervical to lumbar regions, were processed for specific stains of Kluver Barrera (KB) (14). Selected sections of brain and spinal cord were also processed for immunohistochemistry (IHC) to detect phosphorylated and non-phosphorylated neurofilaments (NF), microglia (Iba1), astrocytes (GFAP), oligodendrocytes (Olig2), myelin basic protein (MBP). Control for tissue was performed on brain tissue sections of a dog that had same age but with no nervous signs or lesions. Same sections were prepared for IHC for detection of canine distemper virus.

Microscopically, a marked diffuse vacuolation of the white matter (*status espongiosus*), throughout the length of the neuroaxis was observed, from the frontal brain area to lumbar spinal cord (Fig. 1), being most severe in cerebral cortex (neocortex and paleocortex) and cerebellum. The lesions were bilateral and symmetrical. The vacuoles were rounded to oval, well demarcated, of variable size, many of them coalesce forming cavities with no apparent content. There was moderate glial cell proliferation, mostly microglia. The oligodendrocytes in white matter were disorderly distributed, without their typical fascicular disposition along myelinated nerve fibers. Areas of white matter, adjacent to gray matter in brain, presented spongiosis with mild alteration of neuropil and few neuronal chromatolysis. The remaining organs did not show lesions of diagnostic relevance.

In areas of spongiosis of white matter, KB staining demonstrated a moderate weak demyelination (Fig. 2). The IHC study, in these areas showed diminished NF immunolabeling, with axonal fragmentation and degeneration (Fig. 3A), along with marked Iba1 immunolabeling (Fig. 3B) in phagocytic cells infiltrating white matter and in perivascular cuffs. The latter also showed a laminar pattern of deep layers of cerebral cortex. Immunolabeling by GFAP was moderately expressed. Evaluation by Olig2 showed a decrease of oligodendrocytes. Also, MBP was diminished for myelin (Fig. 4). Canine distemper IHC was negative. Hematological studies resulted within normal values.

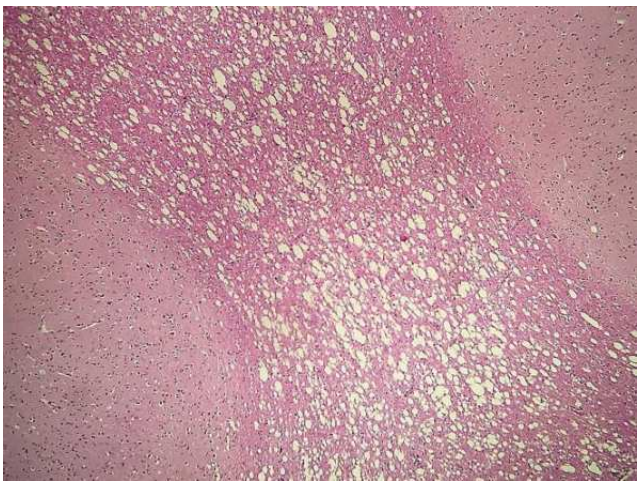

Figure 1. Adult mixed breed female dog, cerebral cortex. Diffuse severe white matter vacuolation (*status espongiosus*). H&E, x10.

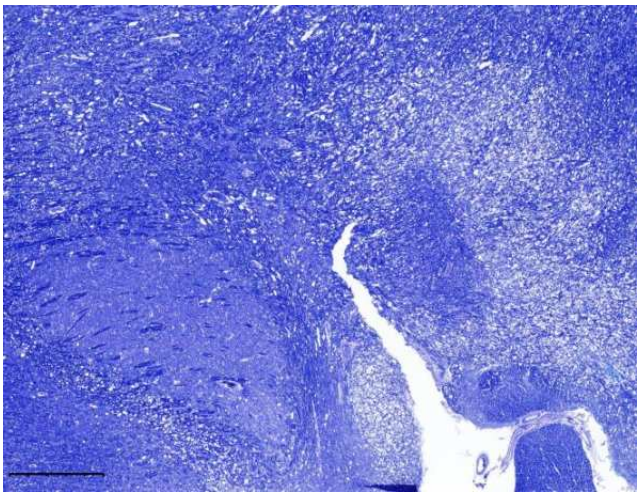

Figure 2. Adult mixed breed female dog, transverse section at the level of the thalamus. Areas of spongiosis in white matter showing moderate weak demyelination (right) by blue staining discoloration. KB, x2.

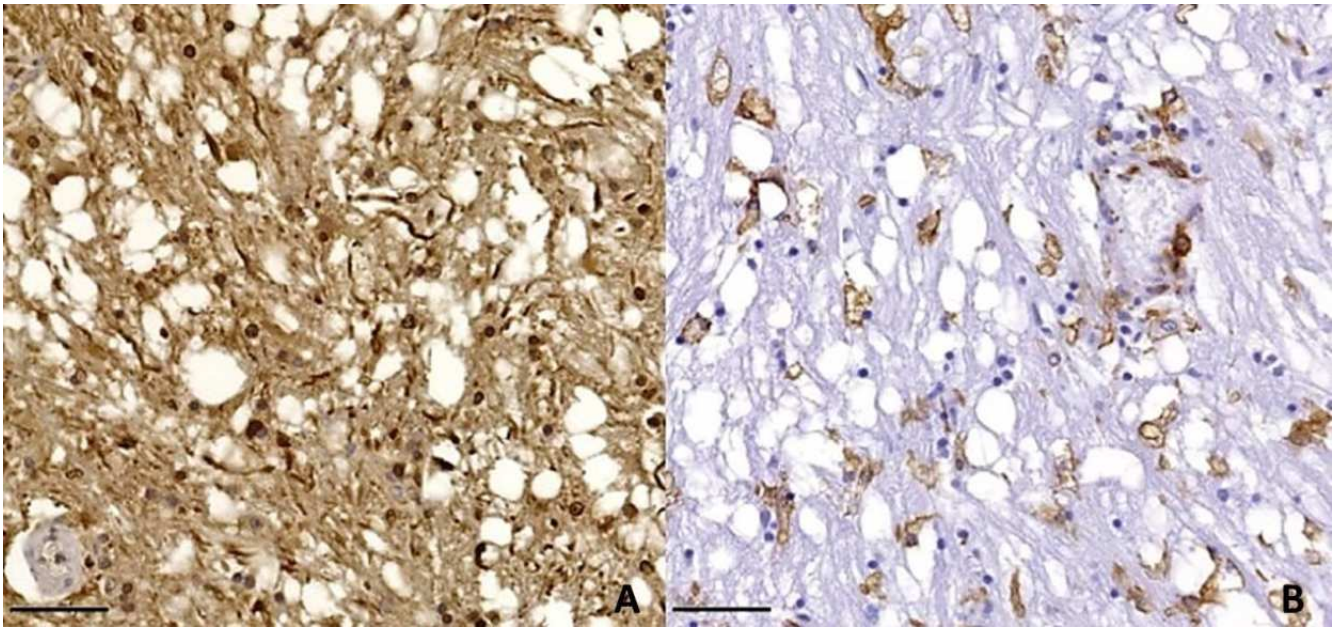

Figure 3. Adult mixed breed female dog, cerebral cortex. **A.** Note fragmented axons in areas of white matter vacuolation. IHC NFt, x40, bar=50um. **B.** Activated microglia between vacuoles. IHC Iba1 x40 bar=50um.

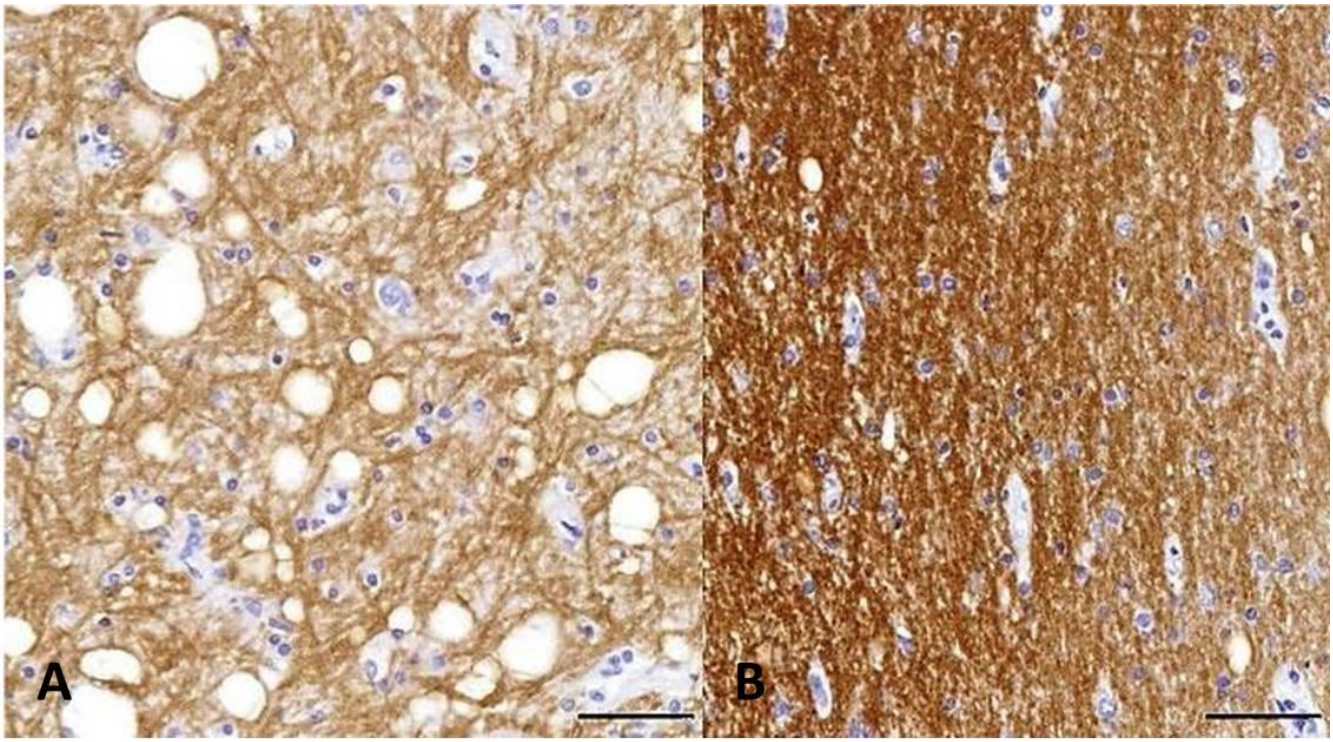

Figure 4. Adult mixed breed female dog, cerebral cortex. Diminished immunolabeling in spongiotic cortical areas **(A)** compared to no spongiotic areas **(B)**. IHC MBP, x40, bar=50um.

Discussion

In this case, the neuropathological findings together with the immunohistochemical results suggest a primary demyelination due to a decrease in number and function of oligodendrocytes, which is probably of genetic basis (26). Oligodendrocytes in white mater are arranged along the axonal processes in chains of 3 to 5 cells (5). In the present report, the disorderly distribution of oligodendrocytes in white matter and their scarce immunolabeling for Olig2 suggest a failure in the synthesis and maintenance of myelin (28), confirmed by a moderate expression of MBP, indispensable for the myelin sheath organization (11). This suggests a late onset of primary

demyelination. Moreover, the decreased NF immunolabeling observed in the spongiotic areas, confirmed that the loss of myelin was associated with secondary axon damage and loss (20, 26, 29). Marked activation of microglia is observed in chronic neurodegenerative disorders (22), as the present case. GFAP expression is common during demyelination in chronic neurodegenerative disorders (13) as well as a decrease of phosphorylated neurofilaments and consequent slow axonal transport (2).

Acquired leukoencephalopathy can have a toxic origin due to hexachlorophene or isoniazid application, or accidental consumption of phenelzine or bromethalin (3, 9, 23). In this case, the dog did not have access to these toxics, and shared his 20 days with 12 other dogs, which were not affected. Also, the association of bromethalin toxicosis with white matter spongiosis in dogs is not conclusive (21). Vitamin B12 deficiency and/or methionine leads also to leukoencephalopathy in the spinal cord white matter associated with a diet composed mainly of ruminant stomachs (24). However the diet had vitamin B12 in its composition. No drug treatment was reported before onset of signs.

Inherited leukoencephalopathy is common in young pure breed animals, such as in Golden Retriever, Weimaraner, Border Terriers, among others (8, 9, 16, 19, 25). Though the dog of this case was an adult mixed breed, the bilateral symmetric distribution in absence of inflammatory infiltrate, affecting the entire neuroaxis and selectively the white matter, suggests an inherited genetic base of late onset as possible cause of the neurological disease (6). A congenital error of oligodendrocyte progenitor cells might had occurred early in life, remaining clinically silent until a loss threshold of oligodendrocytes was reached and compensatory mechanisms were depleted, as reported in multiple sclerosis in humans or in aciduria in canines up to 7-years-old (1, 4, 7, 17,18). Demyelination process is observed in Canavan disease caused by myelin gene mutations in humans (15) and in pure breed dogs, as Azawakh, Rottweiler y Pembroke Welsh Corgi, suggesting an inherited base (10, 12, 17, 18).

Conclusion

To our knowledge, there is no report of neurodegenerative disorder described in an adult mixed breed dog characterized by a primary demyelination affecting conscious general proprioceptive pathways in the spinal cord. Probably, a genetic base failure with late onset led to late disruption of oligodendrocytes integrity, affecting formation and maintenance of myelin. Though it is described as a disorder occurring in young and pure breed, it should take in account in adult mixed breed dogs. Further case researches are necessary to confirm genetic defects as cause of myelination defect.

Acknowledgements

We want to thanks technicians Leticia Ferreira Chavez, Ester Blasco and Tamara Rivero for processing the samples for histology and immunohistochemistry studies.

References

1. Abramson CJ, Platt SR, Jakobs C, Verhoeven NM, Dennis R, Garosi L, Shelton GD. L-2-Hydroxyglutaric Aciduria in Staffordshire Bull Terriers. J Vet Intern Med. 2003;17:551-6.
2. Berciano J, Fernandez-Barreiro A, editors. Ponencia sobre polineuropatías. XIII Congreso Nacional de Neurología; Murcia, España. Barcelona: Viguera editores; 2005. 114p.
3. Blakemore WF, Palmer AC, Noel PRB. Ultrastructural changes in isoniazid-induced brain oedema in the dog. J Neurocytol. 1972;1(3):263-78.
4. Bohm M, Henderson H, Van der Zwan H, Basson S. L-2 hydroxyglutaric aciduria in a South African Staffordshire Bull Terrier. J S Afr Vet Assoc. 2014;85(1):1-5.
5. Brat DJ. Normal Brain Histopathology. In: Perry A, Brat D, editors. Practical Surgical Neuropathology: A Diagnostic Approach. Missouri: Elsevier; 2018. p.19-37.
6. Cantile C, Youssef S. Nervous system. In: Maxie MG, editor. Jubb, Kennedy and Palmer's Pathology of domestic animals. Missouri: Elsevier; 2016. p.317-47.
7. Correale J, Meli F, Ysrraelit C. Compromiso neuronal en esclerosis múltiple. Medicina (Buenos Aires). 2006;66:472-85.
8. da Costa RC, Parent JM, Poma R, de Lahunta A. Multisystem Axonopathy and Neuronopathy in Golden Retriever Dogs. J Vet Intern Med. 2009;23:935-9.
9. Dorman DC, Simon J, Harlin KA, Buck WB. Diagnosis of bromethalin toxicosis in the dog. J Vet Diagn Invest. 1990;2:123-8.
10. Eagleson JS, Kent M, Platt SR, Rech RR, Howerth EW. MRI Findings in a Rottweiler with Leukoencephalomyelopathy. J Am Anim Hosp Assoc. 2013;49:4.
11. Frid K, Einstein O, Friedman-Levi Y, Binyamin O, Ben-Hur T, Gabizon R. Aggregation of MBP in chronic demyelination. Ann Clin Transl Neur. 2015;2(7):711-21.
12. Gamble DA, Chrisman CL. A Leukoencephalomyelopathy of Rottweiler Dogs. Vet Pathol. 1984;21:274-80.
13. Hibbits N, Yoshino J, Le TQ, Armstrong RC. Astrogliosis during acute and chronic cuprizone demyelination and implications for remyelination. ASN Neuro. 2012;4(6):e00100.

14. Kluver H, Barrera E. A method for the combined staining of cells and fibers in the Nervous system. J Nueropath Exp Neurol. 1953;12:400-3.
15. Kumar S, Mattan NS, de Vellis J. Canavan disease: a white matter disorder. Ment Retard Dev Disabil Res Rev. 2006;12(2):157-65.
16. Li FY, Cuddon PA, Song J, Wood SL, Patterson JS, Shelton GD, Duncana ID. Canine spongiform leukoencephalomyelopathy is associated with a missense mutation in cytochrome b. Neurobiol Dis. 2006;21(1):35-42.
17. Mandara MT, Reginato A, Balducci F, Bernardin M. A leukomyeloencephalopathy of unknown origin in an Azawakh dog. Res Vet Sci. 2017;113:101-4.
18. March PA, Coates JR, Abyad RJ, Williams DA, O'brien DP, Olby NJ, Keating NH, Oglesbee M. Degenerative Myelopathy in 18 Pembroke Welsh Corgi Dogs. Vet Pathol. 2009;46(2):241-50.
19. Martin-Vaquero P, da Costa RC, Simmons JK, Beamer GL, Jaderlund KH, Oglesbee MJ. A Novel Spongiform Leukoencephalomyelopathy in Border Terrier Puppies. J Vet Intern Med. 2012;26(2):402-6.
20. Oevermann A, Bley T, Konar M, Lang J, Vandevelde M. A Novel leukoencephalomyelopathy of Leonberger Dogs. J Vet Intern Med. 2008;22(2):467-71.
21. Pérez-López M, Sobhakumari A, Filigenzi M, Poppenga RH. Presente y futuro de un nuevo rodenticida dentro de la unión europea: la brometalina. An Vet (Murcia). 2017;33:49-54.
22. Perry VH, Nicoll JA, Holmes C. Microglia in neurodegenerative disease. Nat Rev Neurol. 2010;6(4):193-201.
23. Poppenga RH, Trapp AL, Braselton WE, Louden CG, Gumbs JM, Dalley JB. Hexachlorophene toxicosis in a litter of Doberman Pinschers. J Vet Diagn Invest. 1990;2(2):129-31.
24. Sheahan BJ, Caffreyh JF, Gunna HM, Keating JN. Structural and biochemical changes in a spinal myelinopathy in twelve english foxhounds and two harriers. Vet Pathol. 1991;28(2):117-24.
25. Sisó S, Hanzlícek D, Fluehmann G, Kathmann I, Tomek A, Papa V, Vandevelde M. Neurodegenerative diseases in domestic animals: A comparative review. Vet J. 2006;171(1):20-38.
26. Vandevelde M, Higgins RJ, Oevermann A. Veterinary Neuropathology: Essentials of Theory and Practice. 1st ed. Iowa: Wiley-Blackwell. 2012. p.173-8.
27. Wouda W, Van Nes JJ. Progressive ataxia due to central demyelination in Rottweiler dogs. Vet Q. 1986;8(2):89-97.
28. Yokoo H, Nobusawa S, Takebayashi H, Ikenaka K, Isoda K, Kamiya M, Sasaki A, Hirato J, Nakazato Y. Anti-Human Olig2 Antibody as a Useful Immunohistochemical Marker of Normal Oligodendrocytes and Gliomas. Am J Pathol. 2004;164(5):1717-25.
29. Zachary JF. Nervous system. In: McGavin MD, Zachary JF, editors. Pathologic Basis of Veterinary Disease. St. Louis: Elsevier; 2007. p.853-933.