



## Case Report

# Tubular Adenoma Pyloric-Gland Type in a Cow

Raimundo A. Tostes<sup>1\*</sup>, Jessica Voitena<sup>2</sup>, Arthur C. Cheng<sup>3</sup>, Aline M. Viott<sup>1</sup>

<sup>1</sup>Post-Graduate Program in Animal Science, Department of Veterinary Medicine, Animal Pathology Laboratory, Universidade Federal do Paraná.

<sup>2</sup>Veterinary Medicine Graduate student, Universidade Federal do Paraná.

<sup>3</sup>Residency Program in Veterinary Pathology, Universidade Federal do Paraná.

\*Corresponding Author: Raimundo Tostes, Post-Graduate Program in Animal Science, Departamento de Medicina Veterinária, Universidade Federal do Paraná, Rua Pioneiro 2153, CEP 85950-000, Palotina, Paraná, Brazil. E-mail: [tostes@ufpr.br](mailto:tostes@ufpr.br)

Submitted March, 08<sup>th</sup> 2020, Accepted March, 12<sup>th</sup> 2020

## Abstract

The paper describes a typical Pyloric-Gland Type Tubular Adenoma founded in a 7 years old holstein cow. At necropsy, macroscopic examination showed a pedunculated polypoid formation measuring 4.0 cm in its largest diameter in the mucous membrane of the gallbladder's body region, with a delicate base in the form of a rod measuring 2.5 cm in length. Histologically analysis showed a tubular cell proliferation covered with cylindrical epithelium, which secreted mucus, with regular, vesicular nuclei with small and regular nucleoli. The stroma was represented by a delicate and loosened, vascularized connective tissue and edema. In the veterinary literature, there is no mention of the occurrence of Pyloric-Gland Type Tubular Adenoma in cattle as well a published description about it.

**Key words:** tumor, gallbladder, neoplasia, holstein.

## Introduction

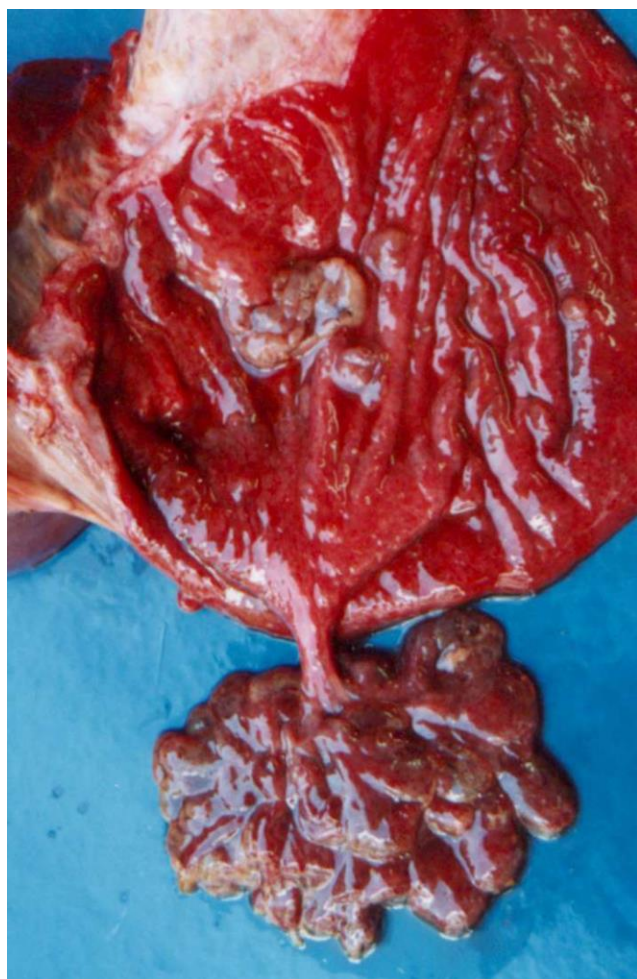Primary liver tumors in bovines is relatively common. However, gallbladder neoplasia diagnosis is rare (4). Rarely, bovine presents a clinical condition attributable to a specific liver neoplasm. Thus, the diagnosis of hepatic neoplasia in cattle is mainly carried out in slaughterhouses. Data obtained in bovine slaughterhouses indicate a variation of 1.5% (10) to 11.9% (2) in primary liver and gallbladder tumors occurrence. Gallbladder adenoma occurrence in specific is rare in cattle. There is no record about occurrence of a Tubular Adenoma Pyloric-Gland Type in cattle in medicine veterinary indexed literature. In medical literature, this tumor has been studied with more detail after accidental findings in cholecystectomy by cholelithiasis, resembling this case, where the finding occurred during the animal's necropsy with no clinical signs related to the disease. Adenomas are tumors of the glandular epithelium (intraepithelial tumor) typically polypoid, solitary and well-defined. They are divided into three groups according to their growth pattern: tubular, papillary and tubulopapillary; they are cytologically classified as

pyloric-gland type, intestinal type and biliary type. Adenomas pyloric-gland type are more common in the bladder, while other types are more common in extra-hepatic bile ducts (3, 6). The pyloric-gland adenoma is a benign tumor composed of short tubular glands in a compact manner, which are similar to the pyloric-gland. In early lesions, there are well demarcated nodules embedded in the slides and covered with normal biliary epithelium (6). Despite its simple histological structure, gallbladder is the origin of a wide variety of tumors (6). Most tumors are carcinomas, and a small proportion are lymphomas, adenomas, carcinoid and stromal tumors (1). Some authors propose that it is a predisposing condition for the progression to adenocarcinoma (3, 5, 7, 8). This case presents a typical Tubular Adenoma Pyloric-Gland Type founded in a holstein cow.

## Case report

A black and white Holstein (HPB), 7 years old cow was treated at the Veterinary Hospital of the Universidade Federal do Paraná, Palotina Sector. This animal was sent to care due to the development of an

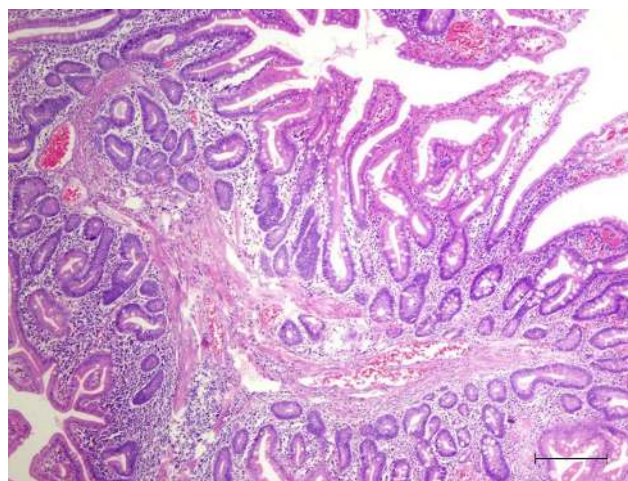
abomasal displacement to the left. Despite the attempt of surgical correction of such displacement, there was an unfavorable development culminating in its death 24 hours after the procedure. The animal was necropsied in the Laboratory of Animal Pathology of the Universidade Federal do Paraná. In the examination of the liver and gallbladder, a pedunculated polypoid formation measuring 4.0 cm in its largest diameter was observed in the gallbladder's mucosa, with a delicate base in the form of a rod measuring 2.5 cm in length (Fig. 1). The sample was collected and placed in 10% formalin for histopathological analysis. Microscopically, the lesion was characterized by a tubular configuration covered with a low cylindrical epithelium, which secreted mucus, with regular, vesicular nuclei with small and regular nucleoli. The stroma was represented by a delicate and loosened, vascularized connective tissue and edema (Fig. 2).



**Figure 1.** Gall Bladder, cow, HPB, female, seven years old. Pedunculated polypoid formation measuring 4.0 cm in its largest diameter was observed in the gallbladder's mucosa.

## Discussion

They are compounds that contain lobes of the compressed pyloric-glands type, some of which may be cistically dilated. The epithelial cells are cuboidal or columnar with vesicular or hyper chromatic nuclei and small nucleoli and with variable amounts of cytoplasmic mucin. Smaller lesions, such as the one observed, show low-grade epithelial neoplasia, but larger adenomas may have high-grade changes or foci of invasive carcinoma. As they increase, most adenomas develop a pedicle and lumen design (6).



**Figure 2.** Gall Bladder, cow, HPB, female, seven years old. Tubular configuration covered with a low cylindrical epithelium, which secreted mucus, with regular. The stroma was represented by a delicate and loosened, vascularized connective tissue and edema. HE. Bar 42  $\mu$ m.

According to Gallahan (5), adenomyomatosis of the gallbladder is a hyperplasia caused by excessive proliferation of the epithelium surface, which could cause a muscle capsule invagination, is a benign lesion and represents approximately 25% of gallbladder polyps and usually located in the background, as a solitary polyp.

Non-neoplastic polyps were classified as hyperplastic consisting of its own mucus, with the presence of dilated regular glandular structures surrounded by loosened stroma (10). Gallbladder polyps are generally considered not to cause any symptoms, although most studies do not assess symptoms prevalence (5).

## References

1. Albores-Saavedra J, Henson DE, Klimstra D. Tumors of the Gallbladder and Extrahepatic Bile Ducts. Atlas of Tumor Pathology. Washington: AFIP; 2000. 365p.
2. Anderson LJ, Sandison AT. Tumors of the liver in cattle, sheep and pigs. *Cancer*. 1968;21(2):289-301.
3. Burt AD, Portmann BC, Ferrell LD. MacSween's Pathology of the Liver. 6th ed. London: Churchill Livingstone Elsevier; 2012. 1032p.

4. Cullen JM. Tumors of the Liver and Gallbladder. In: Meuten DJ, editor, Tumors in Domestic Animals. 5th ed. New Jersey: Wiley-Blackwell; 2016. p.602-631.
5. Gallahan WC, Conway JD. Diagnosis and management of gallbladder polyps. Gastroenterol Clin N Am. 2010;39(2):359-67.
6. Hamilton SR, Aaltonen LA. Pathology and Genetics of Tumours of the Digestive System. International Agency for Research on Cancer – IARC Press; 2000. 417p.
7. Lee KF, Wong J, Li JCM, Lai PBS. Polypoid lesions of the gallbladder. Amer J Surg. 2004;188(2):186-90.
8. Myers RP, Shaffer EA, Beck PL. Gallbladder polyps: epidemiology, natural history and management. Can J Gastroenterol. 2002;16(3):187-94.
9. Roa I, Aretxabala UX, Morgan FR, Molina UR, Araya OJC, Roa SJ, Ibache SG. Pólipos y adenomas de La vesícula biliar: consideraciones clínico-patológicas. Rev Méd Chile. 2004;132(6):673-9.
10. Tessele B, Barros CSL. Tumors found in cattle from slaughterhouses [portuguese]. Pesq Vet Bras. 2016;36(3):145-60.