Braz J Vet Pathol, 2020, 13(2),549 – 554
DOI: 10.24070/bjvp.1983-0246.v13i2p549-554

BJVP
Brazilian Journal of Veterinary Pathology
ISSN 1983-0246

Case Report

First report of psittacine beak and feather disease in imported budgerigar (*Melopsittacus undulatus*) chicks in Mexico

Félix Sánchez-Godoy[1], Daniela Estrada-Arzate[2], Anhet A. Torres-Torres[1], Fernando Chávez-Maya[1], Araceli Lima-Melo[2], Gary García-Espinosa[1*]

[1]Departamento de Medicina y Zootecnia de Aves, Facultad de Medicina Veterinaria y Zootecnia, Universidad Nacional Autónoma de México. Av. Universidad 3000, CU, CdMx. 04510.
[2]Departamento de Patología, Área de Patología Clínica, Facultad de Medicina Veterinaria y Zootecnia, Universidad Nacional Autónoma de México. Av. Universidad 3000, CU, Cd.Mx. 04510.
[*]**Corresponding author:** E-mail: gary@unam.mx

Submitted January, 17th 2020, Accepted June, 15th 2020

Abstract

This case reports an outbreak of psittacine beak and feather disease in imported budgerigars (*Melopsittacus undulatus*) in a breeding site in Mexico. Feather abnormalities occurred in 3-month-old budgerigars and the percentage of affected birds was 40 of 100 birds (40%). The disease begins with varying degrees of bare skin on the back, the ventral region of the body, and the thoracic and pelvic regions without clinical signs or mortality offspring. Thirty-tree budgerigars were referred to the laboratory for diagnostics work-up. The hemogram showed different stages of inflammation in all studied birds, where 66% had relative erythrocytosis, leukocytosis due to heterophilia and monocytosis associated with chronic inflammation. The biochemical analysis showed mainly hypoproteinemia and hypouricemia in 5/8 and 4/9 birds, respectively. The absence of feathers with some tiny calamus of the pectoral region was the most significant feature and no other significant pathologic changes were observed. Histopathologic findings were apoptosis and a moderate amount of spherical intracytoplasmic basophilic inclusion bodies in clusters in some epithelial cells of feather follicles (12/14 sections examined) and bursa of Fabricius (8/10 sections examined). End-point PCR of bursa of Fabricius, genome sequencing and phylogenetic analysis, confirmed circovirus identification of the psittacine beak and feather disease virus species and belonging to the group 2 previously found in budgerigars. This is the first description of the psittacine beak and feather disease in budgerigars in Mexico showing the need of monitoring health status of companion and free-ranging endemic and endangered psittacine birds in Mexico in order to collaborate with the trade regulation of these bird species.

Key words: Circovirus, psittacine beak and feather disease, budgerigars, botryoid inclusion bodies.

Introduction

The psittacine beak and feather disease virus (PBFDV) in psittacine birds belongs to the family Circoviridae, genus *Circovirus*. It is 14 to 17 nm in diameter, not enveloped, icosahedral, and its genome is composed of a single circular DNA of 1.7 to 2 kb. The virus causes an acute infection in neonates and chronic infection in juveniles and adults, mainly affecting the skin and lymphoid tissue (15). The virus is transmitted between birds horizontally, and vertical transmission has also been suggested (18). The first case of this disease occurred in southern Australia in red-rumped parakeets (*Psephotus haematonotus*) in 1888 (1, 10). As of 2016, the disease had been reported in more than 60 species of psittacine birds around the world (8), and have also been reports of the virus in non-parrot species (2) such as the Gouldian finch (*Chloebia gouldiae*), powerful owl (*Ninox strenua*) and Australian rainbow bee-eater (*Merops ornatus*) (5, 22, 23). In 2016, the worldwide distribution of the disease from 1984 to 2015 was reported and showed the largest number of reported cases in captive birds in the United States and

 All rights reserved 2007.

Braz J Vet Pathol, 2020, 13(2),549 – 554
DOI: 10.24070/bjvp.1983-0246.v13i2p549-554

South Africa and wild birds in Australia and New Zealand (7). In Latin America, the presence of the virus and disease has been reported in captive psittacine of the genus *Amazona* spp., *Aratinga* spp. and *Agapornis* spp. in Costa Rica (6).

Mexico has 21 species of wild and captive psittacine birds with an endangered status (3) as well as exotic kept for ornamental and companion purposes. The objective of this work is to report for the first time case a psittacine beak and feather disease outbreak in captive budgerigars (*Melopsittacus undulatus*) in Mexico, and to highlight the importance of health surveillance of captive birds entered to Mexican territories, reducing the risk of potential infectious agents threatening survival conditions of resident bird species in Mexico.

Case Report

In the fall of 2015, a breeding site for budgerigars in Mexico City observed that 40% of offspring had varying degrees of bare skin on the back, the ventral region of the body, and the thoracic and pelvic regions. Some of the feathers were deformed, with an embedded calamus. The condition started few months after the imported budgerigars from Europe were housed near the rest of the birds. None of the birds imported showed clinical signs when they arrived.

Thirty-three 3-month-old budgerigars were referred to the laboratory for diagnostic work-up at the Facultad de Medicina Veterinaria y Zootecnia de la Universidad Nacional Autónoma de México. From 9 of the 33 birds, two samples of 0.5 mL of blood was taken from the occipital and jugular veins prior to euthanasia and necropsy. Necropsy was performed on all 33 birds, samples of skin, thymus, bursa of Fabricius, spleen, bone marrow, beak, esophagus, liver, heart, kidney, brain and lung, were collected and fixed in 10% formaldehyde, embedded in paraffin and stained with hematoxylin and eosin. The bursal of Fabricius were randomly selected, frozen for PCR and nucleotide sequencing and phylogenetic analysis.

Although most studied birds showed good body condition, most of the primary and secondary feathers, and coverts of the pectoral region were absent (bare areas), and some feather follicles had a calamus ranging from 0.1 to 0.5 cm in length (Fig. 1). The vane of some covert feathers was fused. No other significant macroscopic changes were observed.

On the other hand, microscopically, skin sections showed swollen and slightly eosinophilic epithelial cells of the feather follicle and epidermal collar, with apoptotic bodies in some areas; in certain epithelial cells and macrophages, there was a moderate amount of botryoid, spherical, intracytoplasmic basophilic inclusion bodies (IBIB) (Fig. 2). In some areas, the dermal papillae and the feather pulp exhibited IBIB and moderate aggregates of inflammatory cells composed of macrophages and heterophils. The thymus had a cortex with a moderate number of lymphocytes and multifocal areas of apoptosis. The bursa of Fabricius had lymphoid follicles severely atrophied, with a proliferation of cortico-medullary epithelial cells, and abundant amounts of botryoidal, spherical IBIB in the cytoplasm of some affected cells. Finally, the bone marrow had a moderate decrease in the erythrocyte and myeloid populations in several studied sections. No significant microscopic lesions were found in the rest of the organs examined.



Figure 1. Budgerigar (*Melopsittacus undulatus*) with psittacine beak and feather disease. Bilateral and severe dystrophy of the wing, breast and flank feathers is observed.

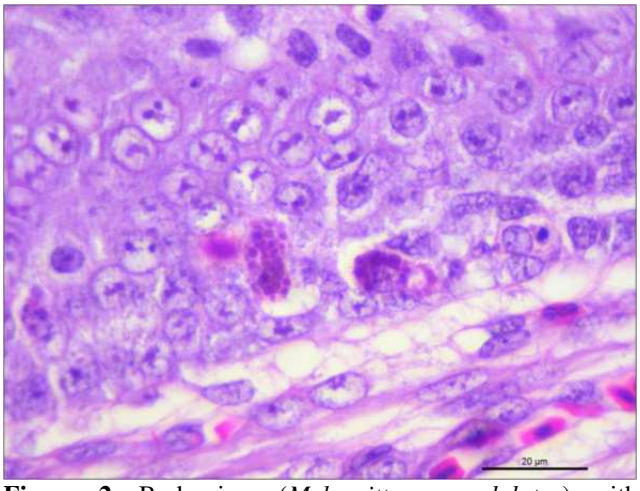

Figure 2. Budgerigar (*Melopsittacus undulatus*) with psittacine beak and feather disease. Some epithelial cells of the epidermis of the feather follicle contain botryoid, spherical basophilic intracytoplasmic inclusion bodies. Hematoxylin-eosin staining. Bar = 20µm.

Braz J Vet Pathol, 2020, 13(2),549 – 554
DOI: 10.24070/bjvp.1983-0246.v13i2p549-554

The hematocrit findings showed that 4/9 birds (44%) had values 3-7% above the maximum normal level, while 5/9 birds (56%) had normal values. Relative erythrocytosis associated with hemoconcentration was observed in 6/9 birds (66%), with an increase of 2.5-26%, while 3/9 (34%) birds had normal values. Leukocytosis was present in 3/9 birds (55%), with an increase of 41-50%; leukopenia was present in 2/9 birds (22%) with an increase of 26%; and 4/9 birds (22%) had normal values. Heterophilia was present in 3/9 birds (33%), with an increase of 50-60%; heteropenia was present in 1/9 birds (11%), with a 26% decrease; and 5/9 birds had normal values. Lymphopenia was observed in 1/9 birds, with a decrease of 55%, while 8/9 birds had normal values. Monocytosis was also observed in 6/9 birds (66%), with an increase of 72-94%, while 3/9 birds (34%) had normal values (Table 1).

The biochemical analysis findings showed changes in 7/9 birds (77%): hypoproteinemia in 5/9 birds (55%), hypouricemia in 4/9 birds (44%), elevated aspartate aminotransferase (AST) in 3/9 birds (33%) and hyperglycemia in 1/9 birds (11%) (Table 2).

Table 1. Hemogram values for 3-month-old budgerigars (*Melopsittacus undulatus*) with psittacine beak and feather disease.

Parameter	Reference value	1	2	3	4	5	6	7	8	9	Mean	± SD
Hematocrit (L/L)	0.44-0.58	0.57	0.56	0.58	0.55	0.62	0.52	0.65	0.60	0.61	0.58	0.039
Erythrocytes ($x10^{12}$/L)	2.3-3.9	2.3	4.1	3.9	4.4	4.8	4.0	5.3	4.6	3.3	↑4.07	0.88
VGM (fL)	90-190	248	137	149	125	129	130	123	130	189	151.1	41.65
Thrombocytes ($x10^9$/L)	-	14	13	15	Clusters	17	24	Clusters	12	13	↑15.4	4.11
Total proteins (g/L)	25-45	42	32	32	36	32	32	34	30	40	34.8	4.9
Leucocytes ($x10^9$/L)	3.0-8.0	2.2	7.3	13.6	16.0	2.2	15.2	4.8	3.7	3.5	7.6	5.72
Heterophils ($x10^9$/L)	1.2-5.2	0.88	4.45	10.47	13.12	1.65	12.31	2.88	2.34	2.55	↑5.6	4.8
Lymphocytes ($x10^9$/L)	0.6-3.6	1.03	1.17	1.63	1.60	0.33	1.98	1.15	0.81	0.77	1.1	0.5
Monocytes ($x10^9$/L)	0.0-0.08	0.11	1.24	1.36	0.96	0.02	0	0.24	0.07	0.18	↑0.46	0.55
Eosinophils ($x10^9$/L)	0.0-0.08	0	0	0	0	0	0	0	0	0	0	0
Basophils ($x10^9$/L)	0.0-0.08	0.18	0.44	0.14	0.32	0.20	0.91	0.53	0.48	0	↑0.35	0.27
H:L ratio	0.9-3.3	0.85	3.8	6.4	8.2	5.0	6.2	2.5	2.85	3.31	↑4.34	2.29

* B1 to B9 are the numbers assigned to each bird.

Table 2. Biochemical values of 3-month-old budgerigars (*Melopsittacus undulatus*) with psittacine beak and feather disease.

Parameter	Reference value	1	2	3	4	5	6	7	8	9	mean	± SD
Glucose (mmol/L)	11.1-22.2	20.5	19.5	15.3	15.0	18.3	16.5	18.1	18.2	23.3	18.3	2.6
Uric acid (mmol/L)	238-833	263	200	203	348	200	272	310	200	400	266.22	73.9
Total proteins (g/L)	20-30	20	18	21	21	19	19	20	17	15	↓18.8	1.96
Albumin (g/L)	-	7	6	8	6	6	7	8	7	6	6.7	0.83
AST (U/L)	150-350	274	293	336	802	410	247	328	399	330	↑379.8	166.95
GLH (U/L)	-	5	5	4	7	4	5	4	5	6	5	1

* B1 to B9 are the numbers assigned to each bird.

The bursa of Fabricius samples stored at -80 °C were used to perform DNA extraction and purification for the detection of this viral agent using a PureLink Viral RNA/DNA Mini Kit (Invitrogen, USA). Subsequently, different fragments of the PBFDV genome were amplified from an end-point PCR using previously reported primers and amplification conditions (14,17,26,27). The previously amplified fragments were purified with the QIAquick Gel Extraction Kit QIAGEN (Qiagen, Germany) for sequencing using the BigDye™ Terminator v3.1 Cycle Sequencing Kit (Applied Biosystems, USA). The sequences were read in an ABI PRISM 3130 xlt Genetic Analyzer (Applied Biosystems, USA), and electropherograms were obtained that were subsequently edited and aligned to obtain a consensus sequence of 2007 nt using MEGA version 7 (12). The 2007 nt fragment (029-16) was compared with the available public sequences on the GenBank using basic local alignment search tool (BLASTn) to identify similar sequences. The sequence obtained in this study had the greatest similarity (94%) to two sequences, AB277750 and KP677584, clustered with two isolates from budgerigars in Japan and

Braz J Vet Pathol, 2020, 13(2),549 – 554
DOI: 10.24070/bjvp.1983-0246.v13i2p549-554

Taiwan, respectively. A total of 42 and 31 sequences of complete genomes of different circovirus species affecting birds and are available in GenBank were collected (Tables 3 and 4 respectively). An alignment was made using 42 and 31 sequences and the 029-16 sequence in ClustalW; subsequently, a phylogenetic tree was constructed using Kimura's 2-parameter model to calculate the genetic distances. The phylogenetic tree was constructed using the neighbor-joining method, bootstrap values were calculated with 1000 replicates, using MEGA 7 software (12). From the phylogenetic tree (Fig. 3), it was identified that sequence 029-16 obtained in this work was most closely related to the circovirus belonging to the PBFDV species and specifically to sequences of circovirus strains of budgerigars within the group 2 of PBFDV (Fig. 4).

Discussion

The dystrophy of primaries and secondaries feathers, and coverts, as well as the detection of apoptosis in the epithelial cells of feather follicles and lymphoid organs with the presence of IBIB, were consistent with the macroscopic and microscopic lesions described in the literature related to psittacine beak and feather disease (10, 16, 24). The absence of subcutaneous hemorrhages and, in other organs, karyomegaly, with slightly basophilic intranuclear inclusion bodies in the spleen and liver, differentiate this disease from avian polyomavirus (11, 24). No lesions were found in the beak in this case, but it has been previously reported that beak lesions are less common than feather lesions representing a characteristic feature of psittacine beak and feather disease in yellow-crested cockatoos (*Cacatua sulphurea*), salmon-crested cockatoos (*Cacatua moluccensis*) and white cockatoos (*Cacatua alba*) (19). The absence of morbidity and mortality noted in this case suggests that viral infection developed in affected chicks after the primary lymphoid organs matured and before they reached the full feathered age (16, 20, 21).

Hematological changes as erythrocytosis is frequently associated with hemoconcentration and not necessarily related to this viral infection (4). Ninety percent of the studied birds presented basophilia, which has been associated with acute or chronic inflammation (13). The results showed that slightly more than half of the studied birds remitted to the laboratory had relative erythrocytosis due to hemoconcentration, leukocytosis due to heterophilia and monocytosis associated with chronic inflammation, while leukopenia due to heteropenia and normal values occurred in less than half of the birds. The hemogram results in this study showed different stages of inflammation in budgerigars with PBFDV, while a previous study of African gray parrot (*Psittacus erithacus*) chicks infected with psittacine circovirus showed leukopenia and severe anemia (25), and irregular leukocyte values were observed in cockatoos (9).

Table 3. Sequences obtained from GenBank and used to construct Figure 3. The host and accession numbers of each of the sequences used in the phylogenetic analysis from which Figure 3 was obtained are shown.

Host	GenBank Number
Sulphur-crested cockatoo (*Cacatua galerita*)	AF311301
Sulphur-crested cockatoo (*Cacatua galerita*)	KY189054
Sulphur-crested cockatoo (*Cacatua galerita*)	KY189055
Budgerigar (*Melopsittacus undulatus*)	AB277748
Budgerigar (*Melopsittacus undulatus*)	AB277749
Budgerigar (*Melopsittacus undulatus*)	AB277750
Budgerigar (*Melopsittacus undulatus*)	AB277751
Budgerigar (*Melopsittacus undulatus*)	GQ386944
Budgerigar (*Melopsittacus undulatus*)	KP677584
Cockatiel (*Nymphicus hollandicus*)	AB514568
Cockatiel (*Nymphicus hollandicus*)	EF457974
Cockatiel (*Nymphicus hollandicus*)	EF457975
Coconut lorikeet (*Trichoglossus haematodus*)	AF311299
Coconut lorikeet (*Trichoglossus haematodus*)	KP795105
Coconut lorikeet (*Trichoglossus haematodus*)	KP795106
Canary (*Serinus canaria*)	AJ301633
Canary (*Serinus canaria*)	NC_003410
Duck (undetermined species)	GQ423747
Duck (undetermined species)	MF627687
Duck (undetermined species)	MF627690
Finch (undetermined species)	DQ845075
Finch (undetermined species)	NC_008522
Goose (undetermined species)	AF536940
Goose (undetermined species)	AF536941
Goose (*Anser sp.*)	AJ304456
Gull (undetermined species)	DQ845074
Lesser black-backed gull (*Larus fuscus*)	KT454925
Lesser black-backed gull (*Larus fuscus*)	KT454927
Pigeon (undetermined species)	KX108827
Pigeon (*Columba livia*)	LC035390
Pigeon (undetermined species)	MG518478
Australian raven (*Corvus coronoides*)	DQ146997
Australian raven (*Corvus coronoides*)	NC_008375
Starling (undetermined species)	KC846095
Starling (undetermined species)	KC846096
Starling (*Sturnus vulgaris*)	NC_008033
Mute swan (*Cygnus olor*)	EU056309
Mute swan (*Cygnus olor*)	EU056310
Mute swan (*Cygnus olor*)	NC_025247
Zebra finch (*Taeniopygia guttata*)	KU641384
Zebra finch (*Taeniopygia guttata*)	KU641385
Zebra finch (*Taeniopygia guttata*)	NC_026945

 All rights reserved 2007.

Braz J Vet Pathol, 2020, 13(2),549 – 554
DOI: 10.24070/bjvp.1983-0246.v13i2p549-554

Table 4. BFDV sequences affecting budgerigars from the GenBank and used to construct Figure 4. The country and accession number of each of the sequences used in the phylogenetic analysis from which Figure 4 was obtained are indicated.

Country	GenBank Number
Australia	KM887947
Australia	KM887948
Australia	KM887949
Australia	KM887950
Australia	KM887951
China	GQ386944
Japan	AB277746
Japan	AB277747
Japan	AB277748
Japan	AB277749
Japan	AB277750
Japan	AB277751
Poland	JX221004
Poland	JX221005
Poland	JX221009
Poland	JX221012
Poland	JX221014
Poland	JX221026
Poland	JX221027
Poland	JX221028
Poland	JX221034
South Africa	GQ165756
South Africa	GQ165757
South Africa	GQ165758
Taiwan	KP677578
Taiwan	KP677579
Taiwan	KP677581
Taiwan	KP677584
Taiwan	KP677585
Taiwan	KP677592
Taiwan	KP677593

Also, hypoproteinemia has been observed in cockatoos infected with this viral agent (9), so we concluded this could be a characteristic of the pathogenesis of psittacine beak and feather disease in this case.

The nucleotide sequence and phylogenetic analysis of PBFDV in this case could not allow identifying the geographic origin, but it was clear that it is closely related to group 2 of the PBFDV that affects budgerigars.

This is the first description of the psittacine beak and feather disease in budgerigars in Mexico and highlighted the need to monitor health status of resident psittacine species in Mexico and to regulate trade bird species.

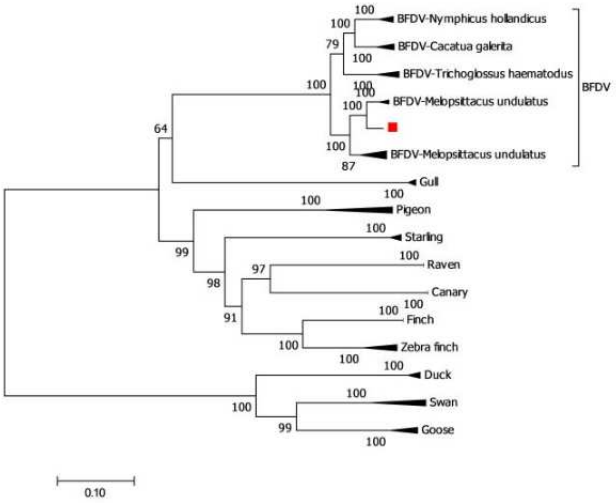

Figure 3. Phylogenetic relationships of 029-16 sequence. The common name and scientific name of the birds indicate the origin of each PBFDV used in the tree. The bootstrap values are indicated in each branch. Each triangle represents groups of closely related sequences.

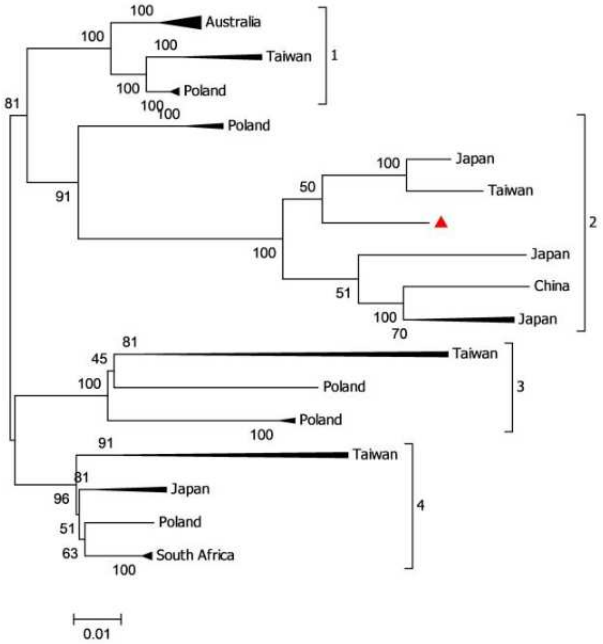

Figure 4. Phylogenetic relationships of 029-16 sequence and PBFDV genomes affecting budgerigars. The country name indicates the origin of each circovirus used in the tree. The bootstrap values are indicated in each branch. Each triangle represents groups of closely related sequences.

Acknowledgments

We thank the QBP Delia Arlette Castillo Mata for the processing of biochemical profile samples.

Braz J Vet Pathol, 2020, 13(2),549 – 554
DOI: 10.24070/bjvp.1983-0246.v13i2p549-554

References

1. Albertyn J, Tajbhai KM, Bragg RR. Psittacine beak and feather disease virus in budgerigars and ring-neck parakeets in South Africa. Onderstepoort J Vet Res. 2004;71:29-34.
2. Amery-Gale J, Marenda MS, Owens J, Eden PA, Browning GF, Devlin JM. A high prevalence of beak and feather disease virus in non-psittacine Australian birds. J Med Microbiol. 2017;66:1005-13.
3. Berlanga H, Gómez de Silva H, Vargas-Canales VM, Rodríguez-Contreras V, Sánchez-González LA, Ortega-Álvarez R, Calderón-Parra R. Aves de México: Lista actualizada de especies y nombres comunes. DF, México: CONABIO; 2017. 117p.
4. Campbell TW, Ellis CK. Avian and exotic animal hematology and cytology. 4th ed. Iowa: Wiley Blackwell; 2015. 424p.
5. Circella E, Legretto M, Pugliese N, Caroli A, Bozzo G, Lavazza A, Camarda A. Psittacine Beak and Feather Disease – like Illness in Gouldian Finches (*Chloebia gouldiae*). Avian Dis. 2014;58:482-87.
6. Dolz G, Sheleby-Elías J, Romero-Zuñiga JJ, Vargas-Leitón B, Gutiérrez-Espeleta G, Madriz-Ordeñana K. Prevalence of Psittacine Beak and Feather Disease Virus and Avian Polyomavirus in Captivity Psittacines from Costa Rica. Open J Vet Med. 2013;3:240-5.
7. Fogell DJ, Martin RO, Groombridge JJ. Beak and feather disease virus in wild and captive parrots: an analysis of geographic and taxonomic distribution and methodological trends. Arch Virol. 2016;161:2059-64.
8. Hakimuddin F, Abidi F, Jafer O, Li C, Wernery U, Hebel Ch, Khazanehdari K. Incidence and detection of beak and feather disease virus in psittacine birds in the UAE. Biomol Detect Quantif. 2015;6:27-32.
9. Jacobson E R, Clubb S, Simpson C, Walsh M, Lothrop Jr CD, Gaskin J, Harrison G. Feather and beak dystrophy and necrosis in cockatoos: clinicopathologic evaluations. J Am Vet Med Assoc. 1985;189:999-1005.
10. Katoh H, Ogawa H, Ohya K, Fukushi H. A Review of DNA Viral Infections in Psittacine Birds. J Vet Med Sci. 2010;72:1099-106.
11. Krautwald ME, Muller H, Kaleta EF. Polyomavirus infection in budgerigars (*Melopsittacus undulatus*): clinical and aetiological studies. Arch Virol. 1998;143:1501-2.
12. Kumar S, Stecher G, Tamura K. MEGA7: Molecular Evolutionary Genetics Analysis version 7 for bigger datasets. Mol Biol Evol. 2016;33:1870-4.
13. Maxwell MH, Robertson GW. The avian basophilic leukocyte: a review. World's Poult Sci J. 1995;51:307-25.
14. Ogawa H, Yamaguchi T, Fukushi H. Duplex shuttle PCR for differential diagnosis of budgerigar fledgling disease and psittacine beak and feather disease. Microbiol Immunol. 2005;49:227-37.
15. Pass DA, Perry RA. The pathology of beak and feather disease. Aust Vet J. 1984;61:69-74.
16. Pass D. The pathology of the avian integument: A review. Avian Pathol. 1989;18:1-72.
17. Patrick L. Shearer, Nicolai Bonne, Phillip Clark, Margaret Sharp and Shane R. Raidal. Beak and feather disease virus infection in cockatiels (*Nymphicus hollandicus*). Avian Pathol. 2008;37:75-81.
18. Rahaus M, Desloges N, Probst S, Loebbert B, Lantermann W, Wolf MH. Detection of beak and feather disease virus DNA in embryonated eggs of psittacine birds. Veterinarni Medicina. 2008;53:(1):53-8.
19. Raidal SR, Sarker S, Peters A. Review of psittacine beak and feather disease and its effect on Australian endangered species. Aust Vet J. 2015;93:466-70.
20. Ritchie BW, Niagro FD, Lukert PD, Steffens WL, Latimer KS. Characterization of a new virus from cockatoos with psittacine beak and feather disease. Virology. 1989;171:83-8.
21. Ritchie BW, Gregory CR, Latimer KS, Pesti D, Campagnoli R, Lukert PD. A review of the most common viruses affecting Psittaciformes. International Zoo Yearbook. 2000;37:257-73.
22. Sarker S, Lloyd C, Forwood J, Raidal SR. Forensic genetic evidence of beak and feather disease virus infection in a Powerful Owl, *Ninox strenua*. Emu. 2016;116:71-4.
23. Sarker S, Das S, Helbig K, Raidal SR. Identification of beak and feather disease virus in an unusual novel host (*Merops ornatus*) using Nested PCR. Genome Announc. 2016;4:e01376-16.
24. Schmidt ER, Reavill RD, Phalen ND, editors. Pathology of pet and aviary Birds. 2nd ed. Iowa: Wiley Blackwell; 2015. 312p.
25. Schoemaker NJ, Dorrestein GM, Latimer KS, Lumeij JT, Kik MJ L, Van Der Hage MH, Campagnoli RP. Severe leukopenia and liver necrosis in young African grey parrots (*Psittacus erithacus erithacus*) infected with psittacine circovirus. Avian Dis. 2000;44:470-8.
26. Ypelaar I, Bassami MR, Wilcox GE, Raidal SR. A universal polymerase chain reaction for the detection of psittacine beak and feather disease virus. Vet Microbiol. 1999;68:141-8.
27. Zhuang Q, Chen J, Mushtaq MH, Chen J, Liu S, Hou G, Li J, Huang B, Jiang W. Prevalence and genetic characterization of avian polyomavirus and psittacine beak and feather disease virus isolated from budgerigars in Mainland China. Arch Virol. 2012;57:53-61.