



Review Article

Consensus Regarding the Diagnosis, Prognosis and Treatment of Canine and Feline Mammary Tumors - 2019

Geovanni D. Cassali^{1*}, Paulo C. Jark², Conrado Gamba³, Karine A. Damasceno⁴, Alessandra Estrela-Lima⁵, Andriago B. De Nardi⁶, Enio Ferreira¹, Rodrigo S. Horta⁷, Bruna F. Firmo⁶, Felipe A. R. Sueiro⁸, Lucas C. S. Rodrigues⁹, Karen Y. R. Nakagaki¹⁰

¹Departamento de Patologia Geral, ICB/UFMG, Belo Horizonte – MG, Brazil.

²Médico Veterinário autônomo - Oncologista, Ribeirão Preto - SP, Brazil.

³Laboratório Vertã de Diagnóstico Veterinário, Passo Fundo - RS, Brazil.

⁴Fundação Oswaldo Cruz, Centro de Pesquisas Gonçalo Moniz, Salvador – BA, Brazil.

⁵Departamento de Patologia e Clínicas, Escola de Medicina Veterinária, UFBA - Salvador – BA, Brazil.

⁶Departamento de Clínica e Cirurgia, FCAV, UNESP, Jaboticabal - SP, Brazil.

⁷Departamento de Clínica e Cirurgia Veterinária, EV/UFMG, Belo Horizonte - MG, Brazil.

⁸Vetpat – Laboratório Veterinário, Campinas - SP, Brazil.

⁹Estima – Hospital Veterinário, Taubaté – SP, Brazil.

¹⁰Celulavet – Laboratório Veterinário, Belo Horizonte- MG, Brazil.

*Corresponding author: Laboratório de Patologia Comparada, Departamento de Patologia Geral, ICB, Universidade Federal de Minas Gerais, Avenida Antônio Carlos, 6627, 31270-901, Belo Horizonte, Minas Gerais, Brazil. E-mail: cassalig@icb.ufmg.br

Submitted September, 29th 2020, Accepted October, 13th 2020

Abstract

The aim of this paper is to discuss and update criteria that can guide the diagnosis, prognosis and treatment of canine and feline mammary neoplasms. It was elaborated during the IV Mammary Pathology Meeting: Diagnosis, Prognosis and Treatment of the Canine and Feline Mammary Neoplasia, held on April 29th and 30th, 2019 in Belo Horizonte – MG, Brazil, sponsored by the Laboratory of Comparative Pathology of the Federal University of Minas Gerais (UFMG), with the support of the Brazilian Association of Veterinary Pathology (ABPV) and Brazilian Association of Veterinary Oncology (ABROVET). Academics from several regions of Brazil were present and contributed to this work.

Key words: mammary neoplasias, dogs, cats, mammary gland, veterinary oncology.

Introduction

The mammary neoplasms have been frequently diagnosed in canine and feline species representing the most common tumor in canine females (69) and the third most common in the queen (57, 61, 70, 75). Most of these neoplasms are malignant and may be associated with mortality (69, 76), which justifies the current concern of the veterinary oncologists regarding the diagnostic accuracy and therapeutical strategies for these diseases.

Since 2010, the Laboratory of Comparative Pathology, located at the Biological Sciences Institute of Federal University of Minas Gerais, Brazil, supported by the Brazilian Association of Veterinary Pathology (ABPV)

and Brazilian Association of Veterinary Oncology (ABROVET), has organized the Brazilian Consensus Regarding the Diagnosis, Prognosis and Treatment of Canine Mammary Tumors and Consensus for the Diagnosis, Prognosis and Treatment of Feline Mammary Tumors (14, 15, 16, 17). In 2019, the 4th Brazilian consensus took place at Federal University of Minas Gerais and celebrated 20 years of the Laboratory of Comparative Pathology.

That event assembled Brazilian university professors, researchers, liberal professionals and postgraduation students from the programs of veterinary clinics, surgery and pathology focused on mammary oncology, and aimed to discuss, standardize and improve

the criteria related to diagnosis, immunohistochemical and therapeutical proceedings in canine and feline mammary neoplasms.

Diagnosis

Clinical approach and staging

Canine

Clinical evaluation of dogs with mammary tumor involves a complete clinical history and physical examination. Mammary tumors manifest as single or multiple nodules within the mammary gland and may be detected during palpation of all 5 pairs of mammary glands. Tumors can be associated with glandular tissue or with the nipple. Inguinal superficial and axillary lymph nodes should also be palpated. The mammary tumors can develop as firm circumscribed nodules but plaque-like lesions may also be observed. Clinical characteristics as fixation to the skin and surrounding tissues, local temperature, edema, inflammation and ulceration are relevant signs related to malignant growth (4, 36). The absence of one or more of these signs does not exclude aggressive behavior.

M4 and M5 glands are involved in approximately 65-70% of the cases and usually over 50% of female dogs develop multiple lesions. Each lesion has to be individually evaluated since there are different histological types and tumor behavior among canine tumors. The tumor prognosis is determined based on molecular, histological, and clinical characteristics of the most aggressive tumor (19). Clinical staging of females affected by mammary tumors is an important step before treatment planning. Distant metastasis can be detected at the diagnosis and may change surgical decision for example. The staging requirements consist of (1) primary tumor evaluation, (2) regional lymph node involvement (axillary and superficial inguinal), and (3) identification of distant metastasis. Clinical staging is performed according to the World Health Organization staging system proposed in 1980 for dogs (79). This system defined 5 clinical stages reflecting tumor progression in dogs (Table 1). Local lymph node involvement and distant metastasis reflect stages IV and V respectively and have a great impact on tumor prognosis.

The size of each primary tumor needs to be evaluated, once the highest diameter of the largest tumor will be considered for dog's clinical staging. Clinical features as period of tumor growth, clinical evidence of invasiveness and inflammatory conditions should also be evaluated. Tumor size is considered an intended prognostic feature. Dogs with mammary tumors larger than 5 cm (T3) have a shorter survival time compared to those on stage T1 and T2. There is a relation between tumor size, expression of hormone receptors and proliferation markers in canine mammary tumors which corroborates with aggressiveness (33, 76). The tumor measurement is an easy clinical

assessment that represents an important primary evaluation for prognosis. Besides that, it is a relevant feature for treatment decisions and surgical approach.

Table 1. Clinical staging for canine mammary tumors according to TNM system (14, 79).

T - Primary Tumor	
T ₁	< 3 cm maximum diameter
T ₂	3-5 cm maximum diameter
T ₃	> 5 cm maximum diameter
N - Regional lymph nodes	
N ₀	No metastasis (histology or cytology)
N ₁	Metastasis present (histology or cytology)
M - Distant metastasis	
M ₀	No distant metastasis detected
M ₁	Distant metastasis detected
Stages	
I	T ₁ N ₀ M ₀
II	T ₂ N ₀ M ₀
III	T ₃ N ₀ M ₀
IV	Any T N ₁ M ₀
V	Any T Any N M ₁

The axillary and inguinal superficial lymph nodes must be palpated during the physical examination. Lymph node enlargement, fixation and inflammation are characteristics of tumor cell infiltration, but the absence of those features does not exclude lymph node involvement. Definitive clinical staging is commonly determined after surgery and histological lymph node evaluation. The presence of tumor cells infiltrating a regional lymph node is considered an important prognostic factor with a great impact on dogs' survival time. Dogs in clinical stage IV have a median survival time of 331 days compared to 1149 days for dogs in stage I (76). Lymph node involvement impact on survival time was also demonstrated in another study where the survival rates of 1 and 2 years were 19% and 0% for dogs with lymph node metastasis compared to 84% and 69% for dogs with no lymphatic dissemination. The median survival time was 7.1 and 30.2 months of dogs with and without lymph node infiltration (80).

The investigation of distant metastasis is critical to determine the clinical staging and the therapeutic plan. Dogs with distant organs infiltrated by tumor cells may not benefit from surgery. The most common site of distant metastasis is the lungs. Other investigation sites for metastasis include sublumbar, sternal, and prescapular lymph nodes, liver, brain, and bone. Three views radiographs and abdominal ultrasound are always recommended for dogs with mammary tumors. The detection of distant metastasis has an important impact on dogs' survival time. Overall survival time can reduce from 331 to 236 days for dogs with primary tumors larger than 5 cm without or with the detection of distant metastasis respectively (76).

Although clinical staging is considered an important tool to determine the patient's prognosis, it cannot be evaluated as a single feature. Microscopic tumor characteristics are relevant especially for early stage tumors with no lymphatic or other tissue involvement. The biological behavior of tumors can be early determined by histological type, grade and molecular tumor expression can be determined by immunohistochemistry and other methods (94). The set of each of these characteristics allows the veterinarian to better design a therapeutic strategy and achieve more efficient tumor control.

The histopathologic evaluation is always recommended and crucial for all cases. In general, it is performed after the surgery and does not just evaluate the primary tumor, but all the mammary glands including regional lymph nodes. The canine mammary tumors are very heterogeneous and should be evaluated in deep detail. The transition area between tumor and adjacent tissues should also be included. For trimming procedures, the recommendations of Estrela-Lima et al. (32) should be followed. For tumors between 3-5 cm and specimens larger than 5 cm, three and five fragments of the tumor mass should be collected, respectively, and each fragment must measure no more than 1.5x1.5x0.5 cm. The margins should be assigned and the central necrotic areas must be excluded. A standard recommendation for how every tumor biopsy specimen should be trimmed is impossible because each specimen is unique. Specimen size, overall margin area, tumor type, and potential financial restrictions should be considered. The cross-sectioning (radial method, "halves and quarters") is the most commonly used method for small or moderately sized masses. The tumor is bisected along its shortest axis. Subsequently, each half of the tissue is bisected through its longest axis, creating quarter sections that demonstrate the mass in different planes. Alternatively, parallel slicing at regular intervals (complete bread loafing, serial sectioning) increases the percentage of marginal tissue examined. All mammary glands of the submitted chain must be sampled, even if they do not contain tumors. The margin evaluation is mandatory and can be identified using India ink staining.

The mammary gland without macroscopic evidence of tumors should also be included in the microscopic analysis. Local tumor invasion can be noticed in some cases and are relevant to define the pathologic behavior. Besides that, adjacent inflammatory conditions, hyperplasia and dysplasia lesions can also be identified. The analysis of surgical margins is always relevant to adjuvant therapy planning. Whenever there are neoplastic cells in the area stained with Indian ink, the sample should be considered as having "compromised margins". Lateral, deep and superficial margins should be evaluated for the presence of neoplastic cells. If the margins are free, it is recommended to assign a distance in millimeters from the tumor to the smallest margin. If there are compromised margins, these must be identified, and the type of

imperfection must be assigned (presence of isolated cells or lesion continuity) (15).

During the clinical evaluation, a fine needle aspiration can be performed before surgery to differentiate other tumor types, inflammation, and hyperplasia. This is an important step to rule out cutaneous tumors developed at the mammary gland region. Fine needle aspiration is considered a preliminary assessment and cannot be used for a complete diagnosis of mammary tumors (13, 91).

Feline

At least 80% of feline mammary tumors are malignant (6, 68). Many of these, mainly large and invasive tumors, adhere to the skin and are ulcerated. In addition, invasion of lymphatic vessels and lymph nodes is common. Regional or distant metastasis can be found in more than 80% of cats with mammary cancer (54) and occur mainly in the lungs, and may also be seen in the pleura, liver, diaphragm, adrenal glands, spleen, kidneys, uterus and ovaries (47, 93, 100). Often, there is multiple glandular involvement, and just like in female dogs, abdominal mammary glands are the most affected (5, 24, 93). The prognosis is considered to be unfavorable and the mean survival time is less than one year (57, 75).

The clinical staging of mammary tumors in cats aims to assess the size of the primary tumor, the involvement of regional lymph nodes (axillary and inguinal), and the presence of distant metastasis, allowing the establishment of prognosis and a treatment planning, similar to what happens in female dogs. Clinical staging should be performed according to a modified staging system from the World Health Organization (79) for mammary tumors in felines (Table 2) (5, 61). A Brazilian study with 37 cats with mammary cancer (25) found that stage III is the most frequent tumor in the clinical routine, being responsible for 68% of the cases, followed by stage I and II, both with 16%.

Weijer et al. (99) observed survival differences according to tumor size, and cats with mammary tumors smaller than 2 cm had a mean survival of 12 months, compared to a 6.8 months survival for cats with tumors between 2-3 cm and 4 months for cats with tumors larger than 3 cm. Ito et al. (51) also found a survival difference according to tumor size, and cats with neoplasms greater than 3cm had a mean survival of 5 months compared to 9 months of animals with tumors smaller than 3cm.

As well as in female dogs, the presence of lymph node metastasis diagnosed by histopathological examination seems to be an independent prognostic factor in cats with mammary cancer. Lymph node metastasis was associated with shorter survival in 83 cats with mammary cancer and was one of the variables that influenced the prognosis in both univariate and multivariate analysis in that study, along with the histological grading (68).

Borrego et al. (5) did not show a prognostic value of clinical staging, with no difference between medians of

disease-free survival and overall survival, although 23 animals were evaluated and there was no inclusion of animals in stage IV. In contrast, Novosad et al. (74) demonstrated significantly longer disease-free survival for animals classified as stage I. In an univariate analysis with 53 cats, the median survival of stages I, II, III and IV was 29, 12.5, 5.9 and 1 month respectively (51), corroborating the importance of staging in the prognosis of cats with mammary neoplasms.

Table 2. World Health Organization modified clinical staging for feline mammary tumors, according to the TNM system (5, 17, 61).

T - Primary Tumor	
T ₁	< 2 cm maximum diameter
T ₂	2-3 cm maximum diameter
T ₃	> 3 cm maximum diameter
N - Regional lymph nodes	
N ₀	No metastasis (histology or cytology)
N ₁	Metastasis present (histology or cytology)
M - Distant metastasis	
M ₀	No distant metastasis detected
M ₁	Distant metastasis detected
Stages	
I	T ₁ N ₀ M ₀
II	T ₂ N ₀ M ₀
III	T ₁₋₂ N ₁ M ₀
	T ₃ N ₀₋₁ M ₀
IV	Any T N ₀₋₁ M ₁

Histopathological evaluation

The frequency of benign and malignant mammary tumors in female dogs and cats varies considerably due to the existence of different tumor classification methods and the absence of uniform criteria to differentiate tumor types. There is a good agreement in the inclusion of categories such as: adenoma, invasive carcinomas, benign mixed tumors, and carcinomas in mixed tumors. However, the variation is considerable in other categories and several classifications have been proposed; the best known is that of Misdorp et al. published in 1999 by WHO (69) and Goldschmidt et al. (42). In Brazil, this was updated by Cassali et al. (15, 17) with the consensus for diagnosis, prognosis, and treatment of canine and feline mammary neoplasms (Tables 3 and 4).

Histological Grading

The grading of invasive carcinomas of female dogs and cats is performed according to the same criteria proposed for women, described by Elston and Ellis (31). The classification is based on tissue architecture (tubular formation), cell pleomorphism and mitosis count, always considering invasive areas for evaluation (Table 5). In both

species, histological grading has shown prognostic value (25).

Table 3. Canine Mammary Tumors Histological Classification. Modified from Cassali et al. (15).

Histological classification of canine mammary tumors

1. Non-neoplastic epithelial lesion

- 1.1 Ductal hyperplasia
- 1.2 Lobular Hyperplasia
- 1.3 Adenosis
- 1.4 Duct ectasia
- 1.5 Columnar cell lesions
 - 1.5.1 Columnar cell alteration
 - 1.5.2 Columnar cell hyperplasia
 - 1.5.3 Atypical columnar cell lesions

2. Benign tumors

- 2.1 Adenoma
- 2.2 Adenomyoepithelioma
- 2.3 Myoepithelioma
- 2.4 Basaloid adenoma
- 2.5 Fibroadenoma
- 2.6 Benign mixed tumor
- 2.7 Ductal papiloma
- 2.8 Phyllodes tumor

3. Malignant tumors

3.1 Carcinomas

- 3.1.1 *In situ* Carcinoma
 - 3.1.1.1 Ductal in situ Carcinoma
 - 3.1.1.2 Lobular in situ Carcinoma
- 3.1.2 Carcinoma in a mixed tumor
- 3.1.3 Papillar carcinoma (invasive and noninvasive)
- 3.1.4 Tubular carcinoma
- 3.1.5 Solid carcinoma
- 3.1.6 Basaloid carcinoma
- 3.1.7 Cribriform carcinoma
- 3.1.8 **Special type carcinomas**
 - 3.1.8.1 Micropapillary carcinoma
 - 3.1.8.2 Pleomorphic lobular carcinoma
 - 3.1.8.3 Secretory carcinoma
 - 3.1.8.4 Mucinous carcinoma
 - 3.1.8.5 Lipid-rich carcinoma
 - 3.1.8.6 Glycogen-rich carcinoma
 - 3.1.8.7 Squamous cell carcinoma
 - 3.1.8.8 Spindle-cell carcinoma
 - 3.1.8.9 Carcinoma with sebaceous differentiation

3.2 Myoepithelial neoplasias

- 3.2.1 Malignant adenomyoepithelioma
- 3.2.2 Malignant myoepithelioma

3.3 Sarcomas

- 3.3.1 Fibrosarcoma
- 3.3.2 Osteosarcoma
- 3.3.3 Carcinosarcoma
- 3.3.4 Sarcoma in a mixed tumor

3.3.5 Other sarcomas

- 3.3.5.1 Condrosarcoma
- 3.3.5.2 Liposarcoma
- 3.3.5.3 Hemangiosarcoma
- 3.3.5.4 Phyllodes sarcoma

Table 4. Feline Mammary Tumors Histological Classification. Modified from Cassali et al.(17).

Histological classification of feline mammary tumors			
1. Non-neoplastic benign lesions			
1.1	Ductal hyperplasia		
1.2	Lobular Hyperplasia		
1.3	Adenosis		
1.4	Fibroadenomatous hyperplasia)	change	(fibroepithelial)
1.5	Duct ectasia		
1.6 Columnar cell lesions			
1.6.1	Columnar cell alteration		
1.6.2	Columnar cell hyperplasia		
2. Benign tumors			
2.1	Adenoma		
2.2	Adenomyoepithelioma		
2.3	Myoepithelioma		
2.4	Basaloid adenoma		
2.5	Fibroadenoma		
2.6	Benign mixed tumor		
2.7	Ductal papiloma		
2.8	Phyllodes tumor		
3. Malignant tumors			
3.1 Carcinomas			
3.1.1	<i>in situ</i> Carcinomas		
3.1.1.1	Ductal <i>in situ</i> Carcinoma		
3.1.1.2	Lobular <i>in situ</i> Carcinoma		
3.1.2	Tubulopapillary carcinoma		
3.1.3	Cribriform carcinoma		
3.1.4	Solid carcinoma		
3.1.5	Carcinoma in a mixed tumor		
3.1.6	Papillary carcinoma		
3.1.7	Tubular carcinoma		
3.1.8 Special type carcinomas			
3.1.8.1	Micropapillary carcinoma		
3.1.8.2	Pleomorphic lobular carcinoma		
3.1.8.3	Secretory carcinoma		
3.1.8.4	Mucinous carcinoma		
3.1.8.5	Lipid-rich carcinoma		
3.1.8.6	Glycogen-rich carcinoma		
3.1.8.7	Squamous cell carcinoma		
3.1.8.8	Spindle-cell carcinoma		
3.1.8.9	Carcinoma with sebaceous differentiation		
3.2 Myoepithelial neoplasias			
3.2.1	Malignant adenomyoepithelioma		
3.2.2	Malignant myoepithelioma		
3.3 Sarcomas			
3.3.1	Fibrosarcoma		
3.3.2	Osteosarcoma		
3.3.3	Carcinosarcoma		
3.3.4	Sarcoma in mixed tumor		
3.3.5 Other sarcomas			
3.3.5.1	Condrosarcoma		
3.3.5.2	Liposarcoma		
3.3.5.3	Hemangiosarcoma		

Table 6. Immunohistochemical panel for canine and feline mammary carcinomas. ER, Estrogen receptor; PR, Progesterone receptor.**Table 5.** Summary of the semiquantitative method for assessing histological grade in canine and feline mammary Carcinomas*.

Feature	Score
Tubule formation	
Most tumors (>75%)	1
Moderate degree (10-75%)	2
Little or none (<10%)	3
Nuclear pleomorphism	
Small, regular uniform cells	1
Moderate increase in size and variability	2
Marked variation	3
Mitotic counts**	
0-7	1
8-16	2
>17	3
Olympus BX-40 microscope	
Objective	X40
Field diameter (mm)	0.55
Field area (mm ²)	0.239

Source: Dutra et al. (29).

*According to Elston and Ellis (30, 31)

**Assessed as number of mitoses per 10 fields at the tumor periphery.

Immunohistochemistry

The immunohistochemistry technique has been used in veterinary medicine as a valuable tool to determine prognostic and predictive factors for neoplasms (83). However, the standardization of antibodies, methodologies, and evaluation methods is necessary. Based on the literature data and discussion among professionals during the IV Brazilian consensus, the immunohistochemical panel for canine and feline mammary carcinomas should be composed by Estrogen receptor (ER), Progesterone receptor (PR), Ki-67 and COX-2 expressions. The specifications regarding antibodies, previously standardized in canine and feline mammary gland samples and immunohistochemical evaluation, are presented below (Tables 6 and 7) (Figs. 1 and 2).

It is important to use negative and positive controls in order to confirm the unspecific stain and reaction positivity, respectively. We suggest as positive controls samples from canine and feline species positive for the markers; for the negative control, it is necessary to substitute the antibody for normal serum or even, normal serum (or immunoglobulin) from the same species as the primary antibody was made.

Target antigen (clone)	Manufacturer	Dilution	Antigen retrieval method	Incubation time (h)/ temperature
Ki-67 (MIB-1)	Dakocytomation	1:25	Pressurized heat (125°C/2 mins) with citrate buffer pH 6.0*	1/room temperature
ER (1D5)	Dakocytomation	1:20	Pressurized heat (125°C/2 mins) with EDTA buffer pH 9.0*	1/room temperature
PR (HPRA2)	Neomarkers	1:20	Pressurized heat (125°C/2 mins) with EDTA buffer pH 9.0*	1/room temperature
COX-2 (SP21)	Neomarkers	1:80	Water bath (98°C/20 mins) with citrate buffer pH 6.0*	1/room temperature

Source: De Campos et al. (25).

Recommended immunohistochemical criteria for canine mammary tumors

Proliferation index

Ki-67 is a cell cycle-related marker largely used in canine neoplasms (53). This marker has been evaluated in order to determine the proliferation index of canine mammary neoplasms and is related to the prognosis of these tumors (60, 75). The cut-offs of 14% (51), 27%, 20% (59), 22% (11), 24% (2) and 33% (76) have been determined for this marker in canine mammary neoplasms. According to the Brazilian consensus, the proliferation index should be determined by Ki-67 nuclear staining evaluated in at least 1000 neoplastic cells in high-power-fields (400X), also considering the size of the microscopic field (29) and the cut-off suggested is $\geq 20\%$ (Fig. 1E).

Cyclooxygenase-2

In canine mammary neoplasms, the inducible enzyme COX-2 has been associated with prognosis and tumorigenesis (12, 61, 67). Based on the possibility to provide complementary treatment with COX-2-selective nonsteroidal drugs, the veterinarians of the Brazilian consensus suggested to perform immunohistochemistry in mammary samples using the semiquantitative system proposed by Lavalle et al. (58). In this system, the COX-2 cytoplasmic staining distribution is taken into consideration (score 0 = staining in 0% of the neoplastic cells; score 1 = <10% of the cells; score 2 = 10% to 30% of the cells; score 3 = 31% to 60% of the cells; > 60% of the neoplastic cells) and intensity (score 0 = absence of therefore are scored for estrogen receptor (ER) and progesterone receptor (PR) status to predict response to hormone therapy (96).

staining; score 1 = weak staining; score 2 = moderate staining; and score 3 = strong staining). The obtained scores are multiplied to obtain a total score that ranges from 0 to 12. The neoplasms showing ≥ 6 total score are considered positive (Fig. 1F).

Recommended immunohistochemical criteria for feline mammary tumors

Hormonal receptors

ER and PR expression have been immunohistochemically demonstrated in feline mammary tumors (10, 26, 65, 71), however ER and PR expression in invasive carcinomas does not correlate with other histological parameters or overall survival (50, 65). In some studies, no association was found between ER and PR expression and OS in feline mammary neoplasms, which means that these receptors cannot currently be considered definitively prognostic in cases of feline mammary neoplasia (50, 65).

Morris et al. (71) evaluated ER expression and lesions with > 5% staining were considered positive. They observed statistically significant differences in the number of ER positive cells in lesions of different histological type. Non-neoplastic lesions and adenoma had more ER positive cells than carcinomas and low-grade carcinomas had more ER positive cells than intermediate and high-grade samples combined. Millanta et al. (66) found a similar result using a cut-off point above 5% for positivity to hormonal receptors. Invasive mammary carcinomas frequently exhibit steroid hormone receptor expression and

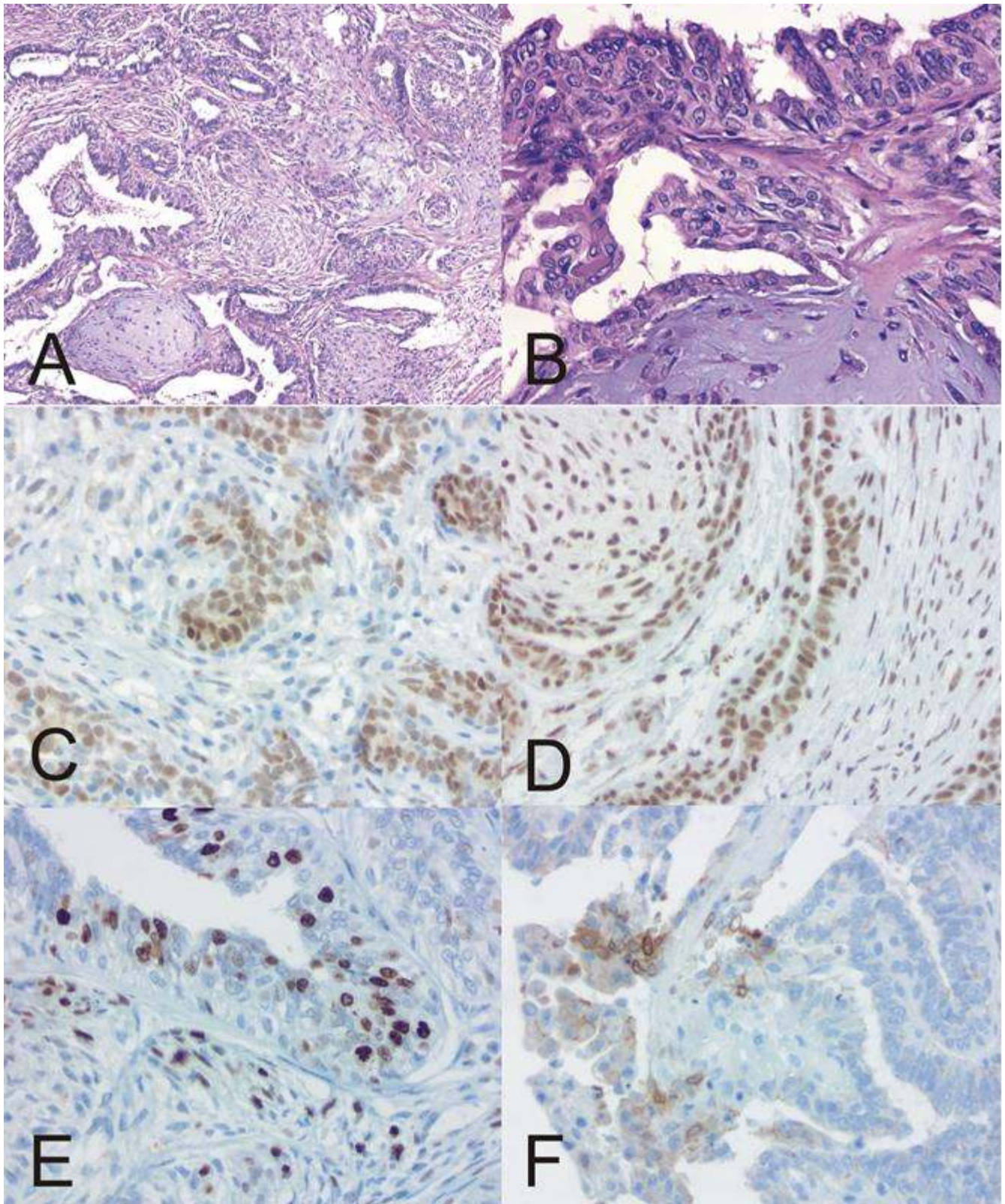


Figure 1. Canine. Carcinoma in a mixed tumor. . (A). H&E 10x (B). H&E 40x. Immunohistochemistry: . (C) ER (D) PR (E)Ki-67 (F)COX-2. DAB Chromogen. 40x.

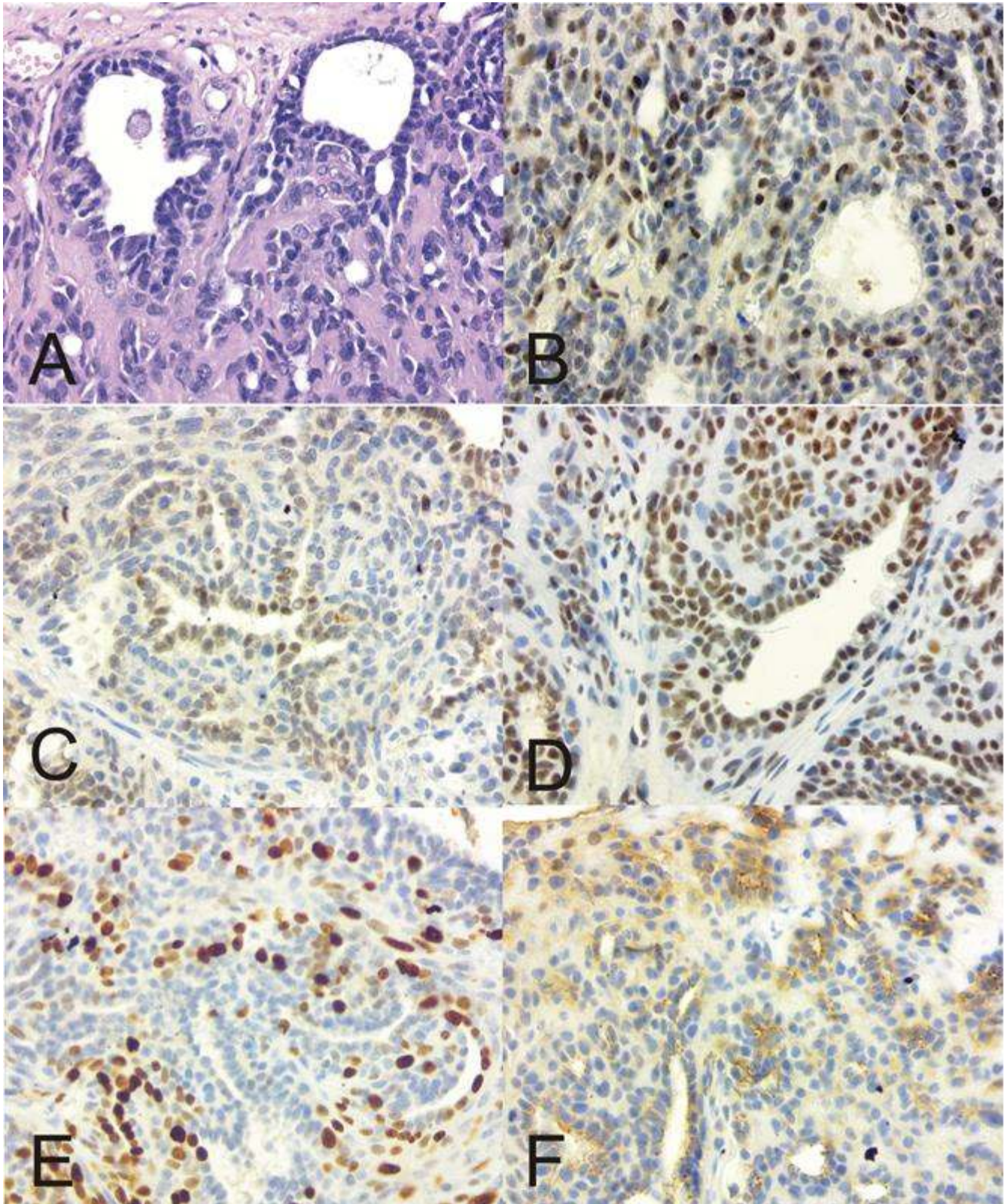


Figure 2. Feline. Adenomyoepithelioma. (A). H&E 40x. Immunohistochemistry: (B). p63 (C). ER. (D). PR. (E) Ki-67 (F). COX-2. DAB Chromogen. 40x.

The prevalence of positive tumors for ER and PR using the recommendations of the American Society of Clinical Oncology and the American College of Pathologists for hormone receptor positivity was described recently (25). Those authors considered tumors as ER/PR positive when more than 1% of tumors cells showed nuclear staining and observed that most primary tumors as well as regional metastasis showed positivity for ER and PR.

Given the divergences in the literature regarding the ideal cut off for hormone receptors, further studies are necessary to establish more significant data. Before this, the present consensus recommends a cut-off above 10% (Figs. 2C and D).

Proliferation index

The immunohistochemical evaluation of cell proliferation index by immunostaining with Ki-67 is excellent to determine the growth fraction in feline mammary tumors (25, 64). Studies on mammary lesions in cats showed a progressive increase in proliferative index from normal mammary glands, non-neoplastic lesions, benign tumors, carcinomas in situ, invasive and metastatic carcinomas (25, 67). In neoplastic cells, when Ki67 value in positive cells was less than 25.2 (median value of all cases, calculated as positive nuclei in 1000 neoplastic cells), a significant association with increased survival in a 1-year post surgery follow-up study was observed (18). Morris et al. (71) also showed that the number of samples with more than 20% of cells staining for Ki67 was significantly greater in carcinomas than in benign lesions (non-neoplastic lesions or adenomas).

According to Soares et al. (92), Ki-67 index may be used as a prognostic biomarker in feline mammary carcinomas with values greater than 14%. Other studies have shown indexes less than 50% and indicated thresholds of 18.7–25% to discriminate feline mammary carcinomas with a worse prognosis (18, 64, 71). Apparently, the literature is variable regarding the cut-off values of Ki-67, so further studies are necessary to determine more accurate values. Considering that the means are around 20%, this cut off is recommended, since cases above this mean usually have higher chances of metastasis and worse prognoses (25) (Fig. 2E).

Cyclooxygenase-2

COX-2 expression has also been demonstrated in feline mammary carcinomas (25, 67, 89, 100). Millanta et al. (67) observed elevated expression of COX-2 protein in 80.9% of feline mammary carcinomas and almost half of them (49%) presented high expression. Elevated COX-2 expression was associated with negative ER and positive PR status, increased VEGF expression and correlated to a poor prognosis. These results reinforced that COX-2 is overexpressed in tumors with an aggressive phenotype.

Higher levels of COX-2 expression in invasive mammary carcinomas were also linked to a poorer prognosis according to Zappulli et al (101).

Sayasith et al. (89) found a lower percentage of cases (37%) with intermediate to high COX-2 expression. The authors suggested that the possible explanation for this difference in the proportion of tumors with high COX-2 staining intensity and distribution includes differences in the antibodies and the scoring system that were used.

The literature shows that the levels of COX-2 expression in feline mammary carcinomas vary between studies (25, 67, 89, 101). While it seems likely that COX-2 expression could have prognostic potential in feline mammary tumors, discrepancies between studies due to different antibody usage need careful data interpretation, as evaluation of distribution and/or intensity (101).

Recently, De Campos and contributors (25) evaluated some molecular markers in feline mammary tumors including COX-2. The criterion of evaluation was the multiplication of intensity x distribution. This allows the identification of 12 scores, being the neoplasm considered positive when the results are ≥ 6 score. These criteria have been adopted by other study performed on canine mammary tumors and has been shown to be suitable for predictive and prognostic classification of these neoplasms in cats (58). therefore being indicated in this consensus (Fig. 2F).

Prognostic and Predictive Markers in Canines and Felines

The prognostic factor is defined as one or more specific clinical, pathological and biological characteristics of the individuals and their tumors, which allows the prediction of the patient's clinical evolution and survival, without the patient being submitted to additional therapies after the initial surgery. Predictive markers allow patients to be selected for more specific and individualized treatments (34). Tumor size, histological type, histological grade, lymph node metastasis and proliferative index are well-established prognostic factors for canine and feline species (Table 8). Among the most aggressive types of tumors are high-grade tubular carcinoma, solid carcinoma, lobular pleomorphic carcinoma, micropapillary carcinoma and carcinosarcoma. For example, an invasive micropapillary carcinoma can be highly positive for hormone receptors, however the histological type in this case is an independent prognostic factor (38). Carcinomas in mixed tumors, in general, show a good prognosis, however when they present combined micropapillary or solid areas, they provide a shorter survival time (77), emphasizing the importance of a more careful histological description. Within lymph node metastasis, we could also consider the number of compromised lymph nodes and the extracapsular extension as markers of worse prognosis, which are already described in dogs (2). Among the predictive markers evaluated by immunohistochemistry,

we have COX-2, Ki-67, estrogen and progesterone receptors (Figs. 1 and 2). There is a lack of strong evidence

for inclusion of E-cadherin and HER-2, and both, were, therefore, removed from the panel in the consensus.

Table 7. Immunohistochemical evaluation for Ki-67, estrogen receptor (ER), progesterone receptor (PR) and cyclooxygenase-2 (COX-2) in canine and feline mammary carcinomas.

Antibody	Evaluation
Ki-67	Number of positive nuclei in a total of 1000 neoplastic cells (× 400 magnification).
ER	Positive: nuclear staining was present in ≥10% of the tumor cells.
PR	Positive: nuclear staining was present in ≥10% of the tumor cells. - Distribution score*: 0 = absent; 1 = <10%; 2 = 10–30%; 3 = 31–60%; 4 >61%. - Intensity score: 0 = absent; 1 = weak; 2 = moderate; 3 = strong.
COX-2	- Multiplication: distribution and intensity scores. Total score: 0–12 Low scores: 0–5 High scores: 6–12

*Five microscope fields/×400 magnification).

Table 8. Prognostic and Predictive Markers related to mammary neoplasia in cat and dogs.

Prognostic Factors	Predictive Factors
1. Tumor size	1. COX-2
2. Histological type	2. Ki67
3. Histological grade	3. Estrogen receptor
4. Lymph node metastasis	4. Progesterone receptor
5. Proliferative index	
6. Hormonal receptor*	
7. COX-2	

*Prognostic factor considered in dogs

Treatment

Surgery

Canine

Surgical excision of the tumor is still the treatment of choice for almost all dogs with mammary tumors. This technique can cure dogs with no lymphatic and distant metastasis involvement or less aggressive histological types (8, 28). Nevertheless, tumor removal is not recommended for dogs with inflammatory carcinoma. Surgery for dogs with distant metastasis detected prior to the surgery will not extend dog's survival time but may increase the life quality for patients with ulcerated and/or painful lesions.

Surgical techniques as lumpectomy (nodulectomy), mamectomy (simple mastectomy), regional mastectomy, unilateral or bilateral mastectomy, associated or not to lymph node removal and ovariectomy are describe (35). The type of surgery will primarily rely on clinical stage, but conditions beyond tumor size, like ulceration and inflammation may also impact this therapeutic decision. Dog breed, size, weight, age or time of tumor development are not relevant for

tumor excision or for surgical technique recommendation. Surgical technique advices to the treatment of mammary tumors have been extensively discussed in literature and should promote an efficient local tumor control (1, 20, 27, 93). Advantages and disadvantages of local and radical surgery are always discussed in veterinary community. Some studies have pursued to identify the benefits of each surgical technique. Despite those studies, surgery recommendation is still under discussion and evaluation. Until now, there is no consent among specialists of what approach could offer a better local control, decrease the risk of tumor recurrence and distant metastasis development, and more studies are needed. The published data of several prognostic factors and studies design are controversial. Some oncologists advocate aggressive procedures, considering the possibility of developing new tumors in the remaining mammary glands. In addition, small lesions could also be associated with aggressive biologic behavior. Unilateral or bilateral mastectomy have a higher chance of local tumor control, however they are considered aggressive techniques, associated to increased surgical complications and surgical response to trauma, and may not improve survival time in dogs (28, 35, 49). These techniques can be considered over treatment for some dogs and careful must be taken, choosing the surgical approach. Although there is no consensus among professionals on the best surgical approach to mammary tumors in dogs, it is unanimous the need for further studies on the subject. One of the points discussed in the consensus was the adoption of a proposal on the extension of mastectomy based on stage, tumor size, number and location of lesions in addition to lymphatic drainage, in order to develop prospective studies on the subject. It is important to emphasize that this proposal is not something consolidated in the literature, but rather an attempt to unify conducts and generate data on a large scale to be discussed among specialists.

An easy decision-making process for mastectomy might be performed as follow: dogs with clinical stage from II to V may be submitted to unilateral or bilateral surgery; and dogs in stage I can benefit from a regional mastectomy. Whenever reasonable, lymphatic drainage of the mammary chain should be considered, and lumpectomy and mamnectomy are therefore, usually not recommended.

The mammary gland selected to be removed during regional mastectomy might be defined based on lesion localization and lymphatic drainage (28, 35).

Total unilateral mastectomy involves the removal of all glands from a mammary chain along with their ipsilateral superficial regional lymph nodes (axillary and inguinal). It is indicated for multiple tumors (regardless of size), lesions located in M3 and tumors with poor clinical prognostic factors, such as lesions with rapid growth and/or larger than 3 cm (T2 and T3). Thus, tumor removal promotes a single surgical wound through a single incision for the resection of mammary tissue. When multiple lesions are found in both mammary chains of a patient, their removal is performed in two surgical procedures, with an interval of 4 to 6 weeks between them.

Regional mastectomy is based on the concept that certain mammary glands share the same lymphatic and venous drainage network with each other and must be removed simultaneously in block along with their respective superficial regional lymph nodes. Besides, we defined that this technique is only suitable for single lesions with clinical prognostic factors that are associated with less tumor aggressiveness, such as a maximum size of 3 cm (T1), not adhering to adjacent tissues, without ulceration and without signs of inflammation, in addition to slow growth. Therefore, lesions that meet the afore mentioned criteria can be addressed according to their location. Another easy decision-making process can be applied for regional mastectomy (Table 9) as follow: when lesions are in M1: M1 and M2 glands and the axillary lymph node should be removed; when lesions are in M2: M1, M2 and M3 glands should be removed in addition to the axillary lymph node; when lesions are in M4: M3, M4 and M5 glands are removed in addition to the inguinal lymph node and when lesions are in M5: M4, M5 glands

and the inguinal lymph node must be removed. Lesions located in M3 cannot be removed by this technique, as they share both lymphatic communications (1, 81).

Total bilateral mastectomy consists of the removal of the two mammary chains simultaneously along with their bilateral superficial lymph nodes (axillary and inguinal). Dogs with flat thorax and excessive elastic skin can be submitted to this technique with less impairment of surgical synthesis, however, dogs with deep thorax require associated reconstructive surgery techniques for their surgical synthesis, if simultaneous removal of the two chains of mammary glands is inevitable, such as a tumor of excessive size affecting both mammary chains (3). In this consensus we defined that this technique should be avoided due to great tissue damage unless the nodule is invading the contralateral mammary chain.

For mammary tumors, a 1-2 cm surgical margin of healthy tissue is recommended, which may involve the adjacent muscle tissue in the deep plane (pectoral, abdominal oblique or rectus abdominis muscles), in case of tumor adherence. In the case of performing extensive surgical techniques (total unilateral or total bilateral mastectomy), the surgical wound must be carefully closed to avoid the occurrence of suture dehiscence, which can occur due to the presence of excessive tension at its edges. In simpler cases, it is recommended to use subcutaneous tissue divulsion to advance the adjacent lateral tissue, followed by the use of walking suture pattern to cover the muscle layer through the fascia and the subcutaneous tissue through the dermis for dead space reduction and advancement of skin. Afterwards, the end of dead space reduction must be done with the zigzag pattern and the skin suture with separate simple stitches. In more extensive cases, in which the presence of large tumors requires the creation of large skin defects for their removal, it is recommended to combine reconstructive surgery techniques, using a donor tissue to occlude the recipient area, which can be subdermal pattern (such as the flap of the axillary or inguinal folds) or axial pattern (such as the flap of the thoracolateral or thoracodorsal artery) (80).

Table 9. Guidelines to determine the surgery technique and extension for single canine mammary tumors, depending on location, as defined in Consensus 2019.

Single tumor localization	Tumor Size	Surgery Type
M1*	< 3 cm (T1)	Regional mastectomy (M1-M2 + axillary lymph node)
	>3cm (T2 ou T3)	Unilateral mastectomy
M2*	< 3 cm (T1)	Regional mastectomy (M1, M2, M3 + axillary lymph node)
	>3cm (T2 ou T3)	Unilateral mastectomy
M3*	Any size (T1, T2 or T3)	Unilateral mastectomy
M4*	< 3 cm (T1)	Regional mastectomy (M3, M4, M5 + inguinal lymph node)
	>3cm (T2 ou T3)	Unilateral mastectomy
M5*	< 3 cm (T1)	Regional mastectomy (M4-M5 + inguinal lymph node)
	>3cm (T2 ou T3)	Unilateral mastectomy

*Tumors associated with other negative prognosis factors should be submitted to unilateral mastectomy.

Because of the possibility of metastasis in the lymph nodes that preferentially drain the mammary parenchyma, the removal of these structures is recommended during mastectomy. The superficial inguinal lymph node accompanies the inguinal mammary gland when this structure is removed, primarily because of its proximity to the mammary gland. The axillary lymph node should be removed, preferentially immediately before mastectomy, especially when the tumors are located in the thoracic (cranial and caudal) mammary glands and cranial abdominal mammary gland. A significant obstacle is finding the axillary lymph node, especially when it is not enlarged. To facilitate its localization, the use of 0.1% - 2.5% patent blue is recommended at a dosage of 2 mg / kg. Complications due to dye application are rare, with reports of hypersensitivity reactions occurring in only 0.1% - 1.1% of the patients. When applied in a large volume or even at the recommended dose, patent blue can temporarily stain the patient's skin, mucous membranes, and urine.

The lymph node staining technique consists of the inoculation of patent blue subpapillary or in the peritumoral and intradermal regions of the skin covering the neoplasia. For this technique, the neoplasia should be divided into four equal quadrants. During the preoperative period, one-fourth of the total volume of the vital marker is inoculated in the superficial intradermal region of each quadrant. Patent blue should be applied between 5 to 10 minutes before the surgical procedure starts, massaging the area of application for better drainage. The "draining" anatomical site is identified by observing the stained lymphatic pathway that corresponds to the location of the lymph node (s). The area incision is followed by the separation of the adjacent tissues and the visual identification of the stained lymph nodes. After lymphadenectomy, a second inspection is recommended to check the presence of other stained lymph nodes.

Most studies do not show benefit of ovariectomy on survival time or disease recurrence in dogs with mammary tumors. Nevertheless, it may benefit selected individuals, as in the presence of grade-2 ER-positive tumors, increased peri-surgical serum estrogen (56) or reproductive reasons unrelated to the mammary tumor. This procedure can be performed during primary tumor removal or planned couple weeks after that. Decision for ovariectomy should consider its possible benefits and risks, which includes increased surgical trauma, when performed along with mastectomy, especially in dogs with advanced stage disease or comorbidities.

Dogs diagnosed with distant metastatic or inflammatory carcinoma are not candidates for surgery. Except for inflammatory carcinoma, palliative surgery can be considered for stage V patients with ulcerative tumors or in pain and discomfort in an attempt to improve the dog's life quality and pain control. In these cases, it is important to have a discussion with the pet owner explaining the palliative purpose of the surgery, since the

procedure will promote a tumor spread control and probably will not increase the dog's overall survival (7).

Feline

Surgery is the main treatment recommended for feline mammary tumors (70) and can be associated with other types of therapies, such as chemotherapy (57). Unilateral or two-step bilateral radical mastectomy, regardless of tumor size and lesion location, consists of the surgical technique of choice and is related to a reduction in tumor recurrences (57, 61, 62).

A previous study described significant differences in OS associated with different surgical procedures, with higher OS in cats submitted to bilateral radical mastectomy (78). Gemignani et al. (39) evaluated the influence of the mastectomy extension in 107 cats with mammary cancer. The animals were initially divided into two groups: unilateral x bilateral mastectomy. The recurrence rate was higher in the group that was submitted to unilateral mastectomy (46.7%) compared to the bilateral mastectomy group (20%). The rates of lymph node and distant metastasis were also higher in the unilateral group (55%) compared to the bilateral group (35.6%). Animals submitted to unilateral mastectomy had disease free time progression and specific disease survival (only animals that died due to mammary tumor complications) of 289 and 473 days, while in the bilateral group these variables were 542 and 1140 days respectively, suggesting the interference of the mastectomy extension in the patients' survival. To analyze the complication rates of the surgical procedure, the animals were divided into three groups: unilateral mastectomy (n = 61); bilateral mastectomy performed in two stages (n = 14) and bilateral mastectomy in a single stage (n = 32), with complication rates of 21.3, 35.7 and 40.6% respectively, suggesting that complications were higher in bilateral mastectomy groups. Despite several limitations of retrospective multi-institutional studies, this study represents a significant number of evaluated animals and suggests that the best approach for cats with mammary cancer is bilateral mastectomy, which can be performed in two moments to decrease the complication rate, although each case must be assessed individually.

Regional, axillary, and inguinal lymph nodes, even if not clinically altered, should be excised by the time of the mastectomy due to the high incidence of regional metastasis (23). For axillary lymph node lymphadenectomy, intradermal application of patent blue (2.5%) is indicated, at a dose of 2mg/kg, not exceeding the volume of 1ml per patient to facilitate its identification and removal.

Chemotherapy

Canine

Adjuvant chemotherapy is not recommended for all dogs with mammary tumor. In fact, the real benefit of systemic treatment should be evaluated and dogs with higher risk of distant metastasis development should be identified. This evaluation is based on histology type, grade, clinical stage and molecular prognostic factors identified by immunohistochemistry analysis. An important advantage in the histopathological classification of mammary tumor proposed during 2011 consensus that correlates with the prognosis and disease's clinical behavior has been successfully used by veterinarians. Aggressive histologic types of mammary tumors in dogs as micropapillary carcinoma, solid carcinoma, carcinosarcoma, and pleomorphic lobular carcinoma present a higher risk for distant metastasis development. For these histologic types, adjuvant chemotherapy is always recommended regardless of histological grade, clinical stage, or molecular expression profile. Dogs with less aggressive histologic types can also have a systemic treatment recommendation based on tumor grade or clinical staging. Chemotherapy is always advised for any grade III carcinoma and dogs with clinical stage IV and V with detected metastasis in lymph nodes or lungs.

Women diagnosed with aggressive breast cancer are commonly treated with adjuvant chemotherapy in attempt to prevent or delay the development of metastasis in more aggressive cases. Research from Universidade Federal de Minas Gerais showed a significant benefit of adjuvant chemotherapy and antiangiogenic therapy in female dogs with advanced stage of mammary cancer. Lavallo et al. (59) demonstrated that animals treated with carboplatin, with or without COX-2 inhibitors, had a statistically significant longer overall survival when compared to animals submitted exclusively to surgical treatment, indicating that this chemotherapeutic agent is beneficial for the treatment of malignant mammary gland neoplasms.

Although the benefits of adjuvant chemotherapy for dogs with high risk of metastasis have been established, the determination of the most appropriate chemotherapy agent or protocol to control neoplastic cells dissemination and growth is not available yet. The lack of clinical studies comparing two or more chemotherapy protocols in a multicentric platform could identify more efficient antineoplastic agents and the benefits of the therapeutic association of COX-2 inhibitors. Platin-based agents as carboplatin, but also doxorubicin and gemcitabine are the most commonly used drugs to control canine mammary tumors. These agents can be used as a single treatment or combined with cyclophosphamide and COX-2 inhibitors. Clinical trials comparing dogs' outcomes after surgery receiving different treatments are necessary.

Increased COX-2 expression in canine mammary tumors has been associated with more aggressive tumors and a worse prognosis. Heller et al. (48) observed a 50% immunostaining for COX-2 in the analyzed tumors and higher staining in anaplastic carcinomas (poorly differentiated) compared to well differentiated carcinomas. Lavallo et al. (58) observed that the increased expression of COX-2 was associated with a worse prognosis and shorter survival time, suggesting that the use of COX-2 inhibitors may be an alternative in the treatment and control of advanced neoplastic mammary gland disease in female dogs.

Souza et al. (95) demonstrated a strong COX-2 expression in inflammatory carcinomas and submitted these patients to treatment with piroxicam. An improvement in clinical conditions and increased survival of the treated animals was observed. The rational use of COX-2 inhibitors depends on the positive immunolabeling for COX-2 with high score (≥ 6), reinforcing the use of immunohistochemistry for COX-2 as a predictive factor for mammary cancer in dogs.

Dogs with malignant mammary tumor should be followed after surgery regardless of histological type, grade, clinical staging and chemotherapy regimen. Dogs follow-up consist on 3-views chest x-rays, abdominal ultrasound and clinical evaluation every 2 months in the first six months of diagnosis and every 3 months up to 2 years.

Feline

Several clinical, histopathological and immunohistochemical parameters are evaluated to indicate the treatment of antineoplastic chemotherapy. Clinically, the adjuvant chemotherapy is indicated in patients with aggressive histological types, malignant tumors larger than 3 centimeters in diameter, as well as in patients with evidence of metastasis in regional or distant lymph nodes. After histopathological evaluation, invasion of neoplastic cells in lymphatic or blood vessels, histological grade III and aggressive histological types such as micropapillary carcinoma, solid carcinoma, cribriform carcinoma and carcinosarcoma are criteria for complementing antineoplastic therapy. In immunohistochemical test, if the Ki-67 is greater than 14%, the use of antineoplastic chemotherapy in the postoperative period is also indicated (92).

The response to chemotherapy in animals diagnosed with metastasis may not be satisfactory (41). The chemotherapy protocols proposed by the literature consist of the use of doxorubicin as a single drug or in combination with cyclophosphamide; carboplatin as a single drug or in combination with doxorubicin; and mitoxantrone as the only drug or in association with cyclophosphamide (22, 55, 57). Additional clinical studies should be conducted to assess which doses and

chemotherapy combinations are most effective in increasing survival time (41).

Previous studies have evaluated the use of doxorubicin as an adjuvant chemotherapy in feline malignant mammary neoplasms (62, 74) and the association of this chemotherapy with COX-2 inhibitors (5). Novosad et al. (74) observed a survival increase in cats when surgery was associated with a doxorubicin treatment (median of 641 days after five cycles of chemotherapy), however, the study did not include a control population. Borrego et al. (5) also found a high median survival rate (median of 460 days) when treating cats with malignant mammary cancer with surgery, doxorubicin and a non-selective COX-2 inhibitor (meloxicam), at a dose of 0.2mg/kg/SC/SID, on the day of the surgical procedure, followed by 0.1mg/kg/VO/SID for 5 days, followed by 0.025mg/kg/VO/SID, during the antineoplastic chemotherapy treatment); however, this study also did not include a control population. McNeill et al. (62) did not observe a beneficial effect with the association of chemotherapy with doxorubicin and surgery (median 848 days) when compared to cats treated only with surgery (median 1406 days). In addition, doxorubicin may be nephrotoxic in felines requiring careful assessment of renal function (57). Another drug that can be used as a non-selective COX-2 inhibitor is piroxicam at a dose of 0.3mg/kg, every 48 hours (9).

Carboplatin has been proposed as a rescue therapy agent as a single drug or in association with other antineoplastic drugs (mitoxantrone and doxorubicin) for feline malignant mammary neoplasms with recurrences or metastasis (74). De Campos et al. (24) found no significant difference between cats diagnosed with mammary gland malignant neoplasms treated only with surgery (median SG of 387 days) and treated with surgery and chemotherapy with carboplatin (median SG of 428 days). However, the overall survival described in the study is superior to the overall survival described in the literature (less than one year), demonstrating the efficiency of surgical treatment. Recently, Gemignani et al. (39) found, in a study with 107 cats with mammary cancer, that the use of chemotherapy was beneficial in both univariate and multivariate analysis, but several different protocols were used, making it impossible to draw conclusions about the most suitable drugs.

The real effectiveness of chemotherapy in cats with mammary cancer shows conflicting results, due to studies with variable methodology, without a control group, with variable criteria in the choice of chemotherapy candidates and types of protocols used. However, due to the high aggressiveness of tumors in cats, the consensus authors recommend the use of chemotherapy in cases of neoplasms with aggressive histological types and grades and/or advanced clinical staging, similar to what happens in women and dogs. The choice of the best protocol still needs studies, so the options mentioned above should be

considered according to the patient's comorbidities, cost, and treatment logistics.

Neoadjuvant chemotherapy in dogs and cats with mammary cancer

The concept of neoadjuvant systemic therapy in breast cancer treatment in women was initially used in order to treat patients with inoperable tumors (97). It is worth mentioning that, in human medicine, the control therapeutic approaches of breast cancer involve a systemic therapy with chemotherapy, in addition to loco-regional stages such as surgery and radiotherapy. In veterinary medicine, the information reported in the literature on the effectiveness of adjuvant chemotherapy in mammary cancer control in female dogs and cats is still discussed and there are practically no reports on the effects of neoadjuvant chemotherapy or even radiotherapy as a complementary treatment to surgery.

Follow-up of dogs and cats with mammary tumors

After the diagnosis of a malignant mammary tumor, it is essential to establish a schedule of the patient's reevaluations, in order to earlier detect the disease manifestation.

This reassessment includes hematological exams (complete blood count and biochemical tests), to assess the patient's general condition and possible paraneoplastic syndromes, and imaging exams (abdominal ultrasound and chest radiography in the right lateral-lateral, left lateral-lateral and ventrodorsal projections), to assess signs of asymptomatic metastasis.

The protocol indicated by the group is to carry out reassessments every 2 months for the first 6 months after diagnosis, and every 3 months between 6 and 24 months.

Mammary tumor prevention

Canine

For many years, it was argued that the best way to prevent the development of mammary cancer in female dogs is early spay or castration. This practice is recommended by a majority of veterinarians in the United States to be performed before the first estrus based on the benefits of mammary tumor reduction and pet population control (90). Clearly, the advantage of spaying a female dog is to avoid the development of hormonal dependent diseases. However, recent scientific findings suggest some adverse effects including urinary incontinence, higher risk of neoplasia development as osteosarcoma, lymphoma and mast cell tumor, and musculoskeletal disorders (86).

Females spayed before the first estrus show a higher risk of developing other tumor types. A 2-fold increase in osteosarcoma occurrence was observed in several breed neutered dogs compared to intact animals

(87). In Rottweilers, the occurrence of osteosarcoma was 3-4 times increased in dogs neutered prior to 1 year old compared to intact dogs (21). The risk of tumor development is not identified for all histologic types. To evaluate the impact of early neutering (<12 months) versus late neutering (> 12 months), another study was conducted in 759 Golden Retrievers. Interestingly, the percentage of hemangiosarcoma cases in late neutered females was 4 times higher than intact and early neutered females. In the same study, no cases of mast cell tumor were observed in intact females compared to a 6% occurrence in late-neutered females (86).

In addition to the incidence increase of some neoplasms, early castration is also related to an increase in orthopedic problems such as hip dysplasia and cruciate ligament rupture (45, 46).

A recent study with more than three thousand mixed-breed dogs evaluated the risk of orthopedic problems and the development of cancer including osteosarcoma, lymphoma, mast cell tumor and hemangiosarcomas according to the animals' weight and reproductive status. In this research, there was no increase in the incidence of cancer related to early neutering, but dogs over 20 kg neutered before one year of age had a significantly higher incidence of orthopedic problems, suggesting the need for personalized approaches according to the size of the dogs (46). Nevertheless, among 35 pure-breed dogs there was an increased risk of cancer for two small breeds: Shih-tzu, for females spayed between 6-11 months, and Boston Terrier, for males spayed before 1-year. For medium or large breeds, an increased risk of cancer was demonstrated for Border Collie (both male and female neutered between 6-11 months old), Cocker Spaniel (males neutered before 6 months and females spayed before 24 months), Beagle (males neutered between 6-11 months), Collie (females spayed before 6 months), Golden Retriever (males neutered before 11 months and females at any age), Australian Shepherd (females spayed before 6 months), Boxer (males and females neutered before 2 years old), Standard Poodle (males neutered before 11 months) and Irish Wolfhound (males neutered before 24 months) (45).

Published data may have bias results including nutritional condition, dogs' metabolism, age and/or housing that were not addressed in most studies. Thus, this subject must be better studied to accurately determine the benefits and risks of early sterilization and determine the best time to spay the dog. Although these questions remain unanswered, the authors of this consensus suggest that sterilization before the first oestrous cycle should be avoided and that it should be performed between the first and second oestrus when the primary goal is the prevention of mammary neoplasia rather than population control. Nevertheless, specific features of each breed and disease epidemiology should be considered for the decision-making process.

6.2. Feline

Intact queens are seven times more at risk of developing the disease compared to spayed cats (78, 93, 98). As in women and dogs, hormonal factor also has a strong influence on the development of mammary tumors in cats. Early castration, from six to 12 months, reduces the risk of mammary tumors in cats (78, 88). There is a 91% reduction in the risk of developing mammary cancer in castrated cats up to six months old, a 86% reduction in cats ovariectomized up to one year old and a reduction of only 11% when castration is performed between 13 and 24 months old (57, 79).

In addition, another form of prevention is the non-administration of contraceptive drugs, which unfortunately is still a common practice in Brazil.

Conclusion

The standardization of the criteria for histopathological classification is a great challenge, only surpassed in a degree of difficulty by the recommendation of therapeutic protocols. Lesions of the mammary gland have great morphological complexity and distinct tumor progressions. The knowledge and standardization of conducts and diagnostic criteria since the first clinical approach, the performance of TNM, surgical excision, diagnosis, histopathological graduation and choice of appropriate immunohistochemical markers for therapeutic guidance are essential for the establishment of more effective and individualized therapeutic protocols, which are guided by the patients' time and life quality. We have progressed in recent years with multidisciplinary meetings in the mammary cancer research field and the possibility of carrying out multicentric work in the country and sharing the experience of various services is already a reality in mammary oncology in Brazil.

Acknowledgments

This work was supported in part by Conselho Nacional de Desenvolvimento Científico e Tecnológico (CNPq).

References

1. Allen SW, Mahaffey EA. Canine mammary neoplasia: prognostic indicators and response to surgical therapy. *J Am Anim Hosp Assoc.* 1989; 25:540-6.
2. Araújo MR, Campos LC, Ferreira E, Cassali GD. Quantitation of the Regional Lymph Node Metastatic Burden and Prognosis in Malignant Mammary Tumors of Dogs. *J Vet Intern Med.* 2015; 29(5):1360-7.

3. Bartels KE, Ferguson HR, Gillette EL, Ferguson HL. Simultaneous bilateral mastectomy in the dog. *Vet Surg.* 1978;7:97-102.
4. Benjamin SA, Lee AC, Saunders WJ. Classification and Behavior of Canine Epithelial Neoplasms Based on Life-Span Observations in Beagles. *Vet Pathol.* 1999;36:423-36.
5. Borrego JF, Cartagena JC, Engel J. Treatment of feline mammary tumors using chemotherapy, surgery and a COX-2 inhibitor drug (meloxicam): a retrospective study of 23 cases (2002–2007). *Vet Comp Oncol.* 2009;7:213-21.
6. Bostock DE. Canine and feline mammary neoplasms. *Br Vet J.* 1986;142(6):506-15.
7. Boston S, Henderson RA. Role of surgery in multimodal cancer therapy for small animals. *Vet Clin Small Anim Pract.* 2014;44(5):855-70.
8. Brodey RS, Goldschmidt MH, Roszel JR. Canine Mammary Gland Neoplasms. *J Am Anim Hospital Assoc.* 1983;19:61-90.
9. Bulman-Fleming JC, Turner TR, Rosenberg MP. Evaluation of adverse events in cats receiving long-term piroxicam therapy for various neoplasms. *J Feline Med Surg.* 2010;12:262-8.
10. Cardazzo B, Zappulli V, Frassinetti F, Patarnello T, Castagnaro M, Bargelloni L. Full-length sequence and expression analysis of estrogen receptor alpha mRNA in feline mammary tumors. *J Steroid Biochem Mol Biol.* 2005;96:109-18.
11. Carvalho MI, Pires I, Prada J, Lobo L, Queiroga FL. Ki-67 and PCNA expression in canine mammary tumors and adjacent nonneoplastic mammary glands: prognostic impact by a multivariate survival analysis. *Vet Pathol.* 2016;53(6):1138-46.
12. Carvalho MI, Pires I, Prada J, Raposo TP, Gregório H, Lobo L, Queiroga FL. High COX - 2 expression is associated with increased angiogenesis, proliferation and tumoral inflammatory infiltrate in canine malignant mammary tumors: a multivariate survival study. *Vet Comp Oncol.* 2017;15(2):619-31.
13. Cassali GD, Gobbi H, Malm C, Schmitt F. Evaluation of accuracy of fine needle aspiration cytology for diagnosis of canine mammary tumors: comparative features with human tumors. *Cytopathol.* 2007;18:191-6.
14. Cassali GD, Lavallo GE, De Nardi AB, Ferreira E, Bertagnolli AC, Estrela-Lima A, Alessi AC, Daleck CR, Salgado BS, Fernandes CG, Sobral RA, Amorim RL, Gamba CO, Damasceno KA, Auler PA, Magalhães GM, Silva JO, Raposo JB, Ferreira AMR, Oliveira LO, Malm C, Zuccari, DAP, Tanaka NM, Ribeiro LR, Campos LC, Souza CM, Leite JS, Soares JMC, Cavalcanti MF, Fonteneles ZGC, Schuch ID, Paniago J, Oliveira TS, Terra EM, Castanheira TLL, Felix AOC, Carvalho GD, Guim TN, Guim TN, Garrido E, Fernandes SC, Maia FCL, Dagli MLZ, Rocha NS, Fukumasu H, Grandi F, Machado JP, Silva SMMS, Bezerril JE, Frehse MS, Almeida ECP, Campos CB. Consensus regarding the diagnosis, prognosis and treatment of canine mammary tumors. *Braz J Vet Pathol.* 2011;4:153-80.
15. Cassali GD, Lavallo GE, Ferreira E, Estrela-Lima A, De Nardi AB, Ghever C, Sobral RA, Amorim RL, Oliveira LO, Sueiro FAR, Beserra HEO, Bertagnolli AC, Gamba CO, Damasceno KA, Campos CB, Araujo MR, Campos LC, Monteiro LN, Nunes FC, Horta RS, Reis DC, Luvizotto MCR, Magalhães GM, Raposo JB, Ferreira AMR, Tanaka NM, Grandi F, Ubukata R, Batschinski K, Terra EM, Salvador RCL, Jark PC, Delecordi JER, Nascimento NA, Silva DN, Silva LP, Ferreira KCRS, Frehse MS, Santis GW, Silva EO, Guim TN, Kerr B, Cintra PP, Silva FBF, Leite JS, Mello MFV, Ferreira MLG, Fukumasu H, Salgado BS, Torres R. Consensus for the diagnosis, prognosis and treatment of canine mammary tumors - 2013. *Braz J Vet Pathol.* 2014;7(2):38-69.
16. Cassali GD, Damasceno KA, Bertagnolli AC, Estrela-Lima A, Lavallo GE, Di Santis GW, De Nardi AB, Fernandes CG, Cogliati B, Sobral R, Costa FVA, Ferreira E, Salgado BE, Campos CB, D'Assis MJMH, Silva LP, Machado MCA, Firmo BF, Nunes FC, Nakagaki KYR. Consensus regarding the diagnosis, prognosis and treatment of canine mammary tumors: benign mixed tumors, carcinomas in mixed tumors and carcinosarcomas. *Braz J Vet Pathol.* 2017;10(3):87-99.
17. Cassali GD, Campos CB, Angélica CB, Alessandra EA, Gleidice EL, Karine AD, Andriago BD, Bruno C, Fernanda VAC, Renata S, Giovana WD, Cristina GF, Enio F, Breno SS, Carlos HC, Danielle NS, Emanuel FM, Stéfane VT, Fernanda CN, Karen YRN. Consensus for the Diagnosis, Prognosis and Treatment of Feline Mammary Tumors. *Braz J Vet Res Anim Sci.* 2018; 55(2):1-17.
18. Castagnaro M, Casalone C, Bozzetta E, De Maria R, Biolatti B, Caramelli M. Tumor grading and the oneyear post-surgical prognosis in feline mammary carcinomas. *J Comp Pathol.* 1998;119:263-75.
19. Cavalcanti MF, Cassali GD. Prognostic factors in the clinical and histopathological diagnosis of breast tumors in bitches - review. *Rev Clin Vet.* 2006;11:56-64.
20. Chang SC, Chang CC, Chang TJ, Wong ML. Prognostic factors associated with survival two years after surgery in dogs with malignant mammary tumors: 79 cases (1998-2002). *J Am Vet Med Assoc.* 2005;227:1625-9.
21. Cooley DM, Beranek BC, Schlittler DL, Glickman NW, Glickman LT, Waters DJ. Endogenous gonadal hormone exposure and bone sarcoma risk. *Cancer Epidemiol Biomarkers Prev.* 2002;11(11):1434-40.
22. Cunha SC, Corgozinho KB, Souza HJ, Silva KV, Ferreira AMR. Adjuvant chemotherapy with mitoxantrone for cats with mammary carcinomas

- treated with radical mastectomy. *J Feline Med Surg*. 2015;17(12):1000-4.
23. Cunha SC, Corgozinho K, Justen H, Silva K, Leite J, Ferreira AM. Survival and Disease-free Interval of Cats with Mammary Carcinoma Treated with Chain Mastectomy. *Acta Sci Vet*. 2016;44:1-7.
 24. De Campos CB, Nunes FC, Lavalle GE, Cassali GD. Use of surgery and carboplatin in feline malignant mammary gland neoplasms with advanced clinical staging. *in vivo*. 2014;28(5):863-6.
 25. De Campos CB, Damasceno KA, Gamba CO, Ribeiro AM, Machado CJ, Lavalle GE, Cassali GD. Evaluation of prognostic factors and survival rates in malignant feline mammary gland neoplasms. *J Feline Med Surg*. 2016;18(12):1003-12.
 26. De las Mulas M, Niel MV, Millán Y, Ordás J, Blankenstein MA, Mil FV, Misdorp W. Progesterone receptors in normal, dysplastic and tumorous feline mammary glands. Comparison with estrogen receptors status. *Res Vet Sci*. 2002;72:153-6.
 27. Dias MLDM, Andrade JML, Castro MBD, Galera PD. Survival analysis of female dogs with mammary tumors after mastectomy: epidemiological, clinical and morphological aspects. *Pesq Vet Bras*. 2016;36(3):181-6.
 28. Dos Santos Horta R, Lavalle GE, de Castro Cunha RM, de Moura LL, de Araújo RB, Cassali GD. Influence of surgical technique on overall survival, disease free interval and new lesion development interval in dogs with mammary tumors. *Adv Breast Cancer Res*. 2014;3:38-46.
 29. Dutra AP, Azevedo Junior GM, Schmitt FC, Cassali GD. Assessment of cell proliferation and prognostic factors in canine mammary gland tumors. *Arq Bras Med Vet Zootec*. 2008;60:1403-12.
 30. Elston CW, Ellis IO. Pathological prognostic factors in breast cancer. I. The value of histological grade in breast cancer: experience from a large study with long-term follow-up. *Histopathol*. 1991;19:403-10.
 31. Elston CW, Ellis IO. Assessment of histological grade. *Systemic Pathology*. In: Elston CW, Ellis IO (eds) *The Breast*. Edinburgh: Churchill Livingstone; 1998. p. 365-84.
 32. Estrela-Lima A, Araújo MS, Costa-Neto JM, Teixeira-Carvalho A, Barrouin-Melo SM, Cardoso SV, Martins-Filho OA, Serakides R and Cassali GD. Immunophenotypic features of tumor infiltrating lymphocytes from mammary carcinomas in female dogs associated with prognostic factors and survival rates. *BMC Cancer*. 2010;10:1-14.
 33. Ferreira E, Bertagnolli AC, Cavalcanti MF, Schmitt FC, Cassali, GD. The relationship between tumor size and expression of prognostic markers in benign and malignant canine mammary tumors. *Vet Comp Oncol*. 2009;193:1-6.
 34. Ferreira E, Campos MRA, Nakagaki KYR, Cassali GD. Prognostic and Predictive Markers in Breast Cancer. *Canine Mammary Pathology: From diagnosis to treatment*. São Paulo: MedVet; 2017. p. 141-49.
 35. Fossum TW, Duprey LP, Huff TG. Surgery of reproductive and genital systems. In: *Small Animal Surgery*, St. Louis:Elsevier; 2013. p. 788-855.
 36. Fowler EH, Wilson GP, Koester A. Biologic Behavior of Canine Mammary Neoplasms Based on a Histogenic Classification. *Vet Pathol*. 1974;11:212-29.
 37. Gamba CO, Dias EJ, Ribeiro LGR, Campos LC, Estrela-Lima A, Ferreira E, Cassali GD. Histopathological and immunohistochemical assessment of invasive micropapillary mammary carcinoma in dogs: A retrospective study. *Vet J*. 2013;196:241-6.
 38. Gamba CO, Scaratti D, de Andrade VP, Estrela-Lima A, Ferreira E, Cassali GD. Invasive micropapillary carcinoma of the mammary gland in humans and canines: Clinicopathological, immunophenotypical and survival approaches. *J Vet Res Anim Sci*. 2017;115:189-94.
 39. Gemignani F, Mayhew PD, Giuffrida MA, Palaigos J, Runge JJ, Holt DE, Liptak JM. Association of surgical approach with complication rate, progression-free survival time, and disease-specific survival time in cats with mammary adenocarcinoma: 107 cases (1991–2014). *J Am Vet Med Assoc*. 2018;252(11):1393-402.
 40. Genelhu MC, Cardoso SV, Gobbi H, Cassali GD. A comparative study between mixed-type tumors from human salivary and canine mammary glands. *BMC cancer*. 2007;7(1):218.
 41. Giménez F, Hecht S, Craig LE, Legendre AM. Early detection, aggressive therapy: optimizing the management of feline mammary masses. *J Feline Med Surg*. 2010;12(3):214-24.
 42. Goldschmidt M., Peña L., Rasotto R., Zappulli V. Classification and grading of canine mammary tumors. *Vet Pathol*. 2011;88(1):117-31.
 43. Guil-Luna S, Sanchez-Cespedes R, Millan Y. Aglepristone decreases proliferation in progesterone receptor-positive canine mammary carcinomas. *J Vet Int Med*. 2011;25:518-23.
 44. Hammond MEH, Hayes DF, Dowsett MD, Allred C, Hagerty KL, Badve S, Fitzgibbons PL, Francis G, Goldstein NS, Hayes M, Hicks DG, Lester S, Love R, Mangu PB, Mcshane L, Miller K, Osborne CK, Paik S, Perlmutter J, Rhodes A, Sasano H, Schwartz JN, Sweep FCG, Taube S, Torlakovic EE, Valenstein P, Viale G, Visscher D, Wheeler T, Williams RB, Wittliff JL, Wolff AC. American society of clinical oncology / college of american pathologists guideline recommendations for immunohistochemical testing of estrogen and progesterone receptors in breast cancer. *J Clin Oncol*. 2010;28:2784-95.
 45. Hart BL, Hart LA, Thigpen AP, Willits NH. Assisting Decision-Making on Age of Neutering for 35 Breeds

- of Dogs: Associated Joint Disorders, Cancers and Urinary Incontinence. *Front Vet Sci.* 2020;7:14.
46. Hart BL, Hart LA, Thigpen AP, Willits NH. Assisting Decision-Making on Age of Neutering for Mixed Breed Dogs of Five Weight Categories: Associated Joint Disorders and Cancers. *Front Vet Sci.* 2020;7:472.
 47. Hayes JH, Milne KL, Mandell CP. Epidemiological features of feline mammary carcinoma. *Vet Record.* 1981;108(22):476-9.
 48. Heller DA, Clifford CA, Goldschmidt MH, Holt DE, Shofer FS, Smith A, Sorenmo KU. Cyclooxygenase-2 expression is associated with histologic tumor type in canine mammary carcinoma. *Vet Pathol.* 2005;42(6):776-80.
 49. Horta RS, Figueiredo MS, Lavallo GE, Costa MP, Cunha RMC, Araújo RB. Surgical stress and postoperative complications related to regional and radical mastectomy in dogs. *Acta Vet Scand.* 2015;57(1):34.
 50. Hughes K, Dobson JM. Prognostic histopathological and molecular markers in feline mammary neoplasia. *Vet J.* 2012;194:19-26.
 51. Ito T, Kadosawa T, Mochizuki M, Matsunaga S, Nishimura R, Sasaki N. Prognosis of malignant mammary tumor in 53 cats. *J Vet Med Sci.* 1996; 58:723-6.
 52. Kadthur JC, Rao S, Sonnahallipura BM, Thimmanahalli DS, Laxmikanth SM. Prognostic value of Ki67 proliferation antigen in canine malignant mammary gland tumours. *Braz J Vet Pathol.* 2011;41(1):36-40.
 53. Kaszak I, Ruszczak A, Kanafa S, Kacprzak K, Król M, Jurka P. Current biomarkers of canine mammary tumors. *Acta Vet Scand.* 2018;60(1):66.
 54. Kim NH, Lim HY, Im KS, Shin JI, Kim HW, Sur JH. Evaluation of clinicopathological characteristics and oestrogen receptor gene expression in oestrogen receptor-negative, progesterone receptor-positive canine mammary carcinomas. *J Comp Pathol.* 2014;151(1):42-50.
 55. Kitchell B, Larue SM, Rooks RL. Mammary tumors (dogs and cats). In: *Veterinary cancer therapy handbook: chemotherapy, radiation therapy, and surgical oncology for the practicing veterinarian.* Lakewood: AAHA; 1999. p.61-64.
 56. Kristiansen VM, Pena L, Diez Cordova L, Illera JC, Skjerve E, Breen AM, Cofone MA, Langeland M, Teige J, Goldschmidt M, Sorenmo KU. Effect of ovariohysterectomy at the time of tumor removal in dogs with mammary carcinomas: a randomized controlled trial. *J Vet Intern Med.* 2016;30(1):230-41.
 57. Lana SE, Rutteman GR, Withrow SJ. Tumors of the mammary gland. In: *Withrow SJ, VAIL, DM Withrow & MacEwen's small animal clinical oncology.* Philadelphia: WB Saunders; 2007. p. 619-636.
 58. Lavallo GE, Bertagnolli AC, Tavares WLF, Cassali GD. COX-2 expression in canine mammary carcinomas: correlation with angiogenesis and overall survival. *Vet Pathol.* 2009;46:1275-80.
 59. Lavallo GE, Campos CB, Bertagnolli AC, Cassali GD. Canine malignant mammary gland neoplasias with advanced clinical staging treated with carboplatin and cyclooxygenase inhibitors. *In Vivo.* 2012;26:375-9.
 60. Löhr CV, Teifke JP, Failing K, Keiss E. Characterization of the proliferation state in canine mammary tumors by the standardized AgNOR method with postfixation and immunohistologic detection of Ki-67 and PCNA. *Vet Pathol.* 1997;34(3):212-21.
 61. MacEwen EG, Hayes AA, Harvey HJ, Patnaik AK, Mooney S, Passe S. Prognostic factors for feline mammary tumors. *J Am Vet Med Assoc.* 1984;185:201-4.
 62. McNeill CJ, Sorenmo KU, Shofer FS, Gibeon L, Durham AC, Barber LG, Baez JL, Overlay B. Evaluation of adjuvant doxorubicinbased chemotherapy for the treatment of feline mammary carcinoma. *J Vet Intern Med.* 2009;23(1):123-9.
 63. Merglen A, Verkooijen HM, Fioretta G, Neyroud-Caspar I, Vinh-Hung V, Vlastos G, Bouchardy C. Hormonal therapy for oestrogen receptor-negative breast cancer is associated with higher disease-specific mortality. *Ann Oncol.* 2009;20(5):857-61.
 64. Millanta F, Lazzeri G, Mazzei M, Vannozzi I, Poli A. MIB-1 labeling index in feline dysplastic and neoplastic mammary lesions and its relationship with postsurgical prognosis. *Vet Pathol.* 2002;39:120-6.
 65. Millanta F, Calandrella M, Bari G, Niccolini M, Vannozzi I, Poli A. Comparison of steroid receptor expression in normal, dysplastic, and neoplastic canine and feline mammary tissues. *Res Vet Sci.* 2005;79:225-32.
 66. Millanta F, Calandrella M, Vannozzi I, Poli A. Steroid hormone receptors in normal, dysplastic and neoplastic feline mammary tissues and their prognostic significance. *Vet Rec.* 2006a;158:821-24.
 67. Millanta F, Citi S, Della Santa D, Porciani M, Poli A. COX-2 expression in canine and feline invasive mammary carcinomas: correlation with clinicopathological features and prognostic molecular markers. *Breast Cancer Res. Treat.* 2006b;98(1):115-20.
 68. Mills SW, Musil KM, Davies JL, Hendrick S, Duncan C, Jackson ML, Kidney B, Philibert H, Wobeser BK, Simko E. Prognostic value of histologic grading for feline mammary carcinoma: a retrospective survival analysis. *Vet Pathol.* 2015;52(2):238-49.
 69. Misdorp W, Else RW, Hellmén E. Histological classification of mammary tumors of the dog and the cat. 2nd Series. Vol VII. Washington DC: Armed

- Forces Institute of Pathology, American Registry of Pathology and the World Health Organization Collaborating Center for Worldwide Reference on Comparative Oncology. 1999. p.1-59.
70. Misdorp W. Tumors of the mammary gland. In: Tumors in domestic animals. Ames: Blackwell. 2002. p. 575-606.
 71. Morris JS, Nixó C, Bruck A, Nasir L, Morgan IM, Philbey AW. Immunohistochemical expression of TopBP1 in feline mammary neoplasia in relation to histological grade, Ki67, ERa and p53. *Vet J*. 2008;175:218-26.
 72. Nguyen F, Peña L, Ibsch C, Loussouarn D, Gama A, Rieder N, Belousov A, Campone M, Abadie J. Canine invasive mammary carcinomas as models of human breast cancer. Part 1: natural history and prognostic factors. *Breast Cancer Res Treat*. 2018;167:635-48.
 73. Nieto A, Pena L, Pérez-Alenza MD, Sanchez MA, Flores JM, Castano M. Immunohistologic detection of estrogen receptor alpha in canine mammary tumors: clinical and pathologic associations and prognostic significance. *Vet Pathol*. 2000;37(3):239-47.
 74. Novosad CA, Bergman PJ, O'Brien MG, McKnight JA, Charney SC, Selting KA, Graham JC, Correa SS, Rosenberg MP, Gieger TL. Retrospective evaluation of adjunctive doxorubicin for the treatment of feline mammary gland adenocarcinoma: 67 cases. *J Am Anim Hosp Assoc*. 2006;42(2):110-20.
 75. Nowak M, Madei JA, Pula B, Dziegiel P, Ciaputa R. Expression of matrix metalloproteinase 2 (MMP-2), E-cadherin and Ki-67 in metastatic and non-metastatic canine mammary carcinomas. *Ir Vet J*. 2015;69(1):9.
 76. Nunes FC, Campos CB, Teixeira SV, Bertagnolli AC, Lavallo GE, Cassali GD. Epidemiological, clinical and pathological evaluation of overall survival in canines with mammary neoplasms. *Arq Bras Med Vet Zool*. 2018;70(6):1714-22.
 77. Nunes FC, Damasceno KA, de Campos CB, Bertagnolli AC, Lavallo GE, Cassali GD. Mixed tumors of the canine mammary glands: Evaluation of prognostic factors, treatment, and overall survival. *Vet Anim Sci*. 2019;7:100039.
 78. Overley B, Shofer FS, Goldschmidt MH, Sherer D, Sorenmo KU. Association between ovariohysterectomy and feline mammary carcinoma. *J Vet Intern Me*. 2005;19(4):560-3.
 79. Owen LN. TNM Classification of tumors in domestic animals. Geneva: World Health Organization. 1980.
 80. Papazoglou LG, Basdani E, Rabidi S, Patsikas MN, Karayiannopoulou M. Current Surgical Options for Mammary Tumor Removal in Dogs. *J Vet Sci Med*. 2014;2(1):6.
 81. Patsikas MN, Karayiannopoulou M, Kaldrymidou E, Papazoglou LG, Papadopoulou PL, Tzegas SI, Tziris NE, Kaitzis DG, Dimitriadis AS, Dessiris AK. The lymph drainage of the neoplastic mammary glands in the bitch: a lymphographic study. *Anat Histol Embryol*. 2006;35:228-34.
 82. Queiroga FL, Raposo T, Carvalho M.I, Prada J, Pires I. Canine mammary tumours as a model to study human breast cancer: most recent findings. *in vivo*. 2011;25(3):455-65.
 83. Ramos-Vara JA, Kiupel M, Baszler T, Bliven L, Brodersen B, Chelack B, Stefanie KW, Del Piero FC, Dial S, Ehrhart EJ, Graham T, Manning L, Paulsen D, Valli VE. Suggested guidelines for immunohistochemical techniques in veterinary diagnostic laboratories. *J Vet Diagn Invest*. 2008;20(4):393-413.
 84. Rassotto, R. Prognostic Significance of Canine Mammary Tumor Histologic Subtypes: An Observational Cohort Study of 229 Cases. *Vet Pathol*. 2017;54(4):571-8.
 85. Ribeiro GM, Rocha RM, Bertagnolli AC, Cassali GD. Morphological aspects and immunophenotypic profiles of mammary carcinomas in benign-mixed tumors of female dogs. *Vet Med Int*. 2012;2012:7.
 86. Riva GT, Hart BL, Farver TB, Oberbauer AM, Messam LLM. Neutering dogs: effects on joint disorders and cancers in Golden Retrievers. *Plos One*. 2013;8(2):e55937.
 87. Ru G, Terracini B, Glickman LT. Host related risk factors for canine osteosarcoma. *Vet J*. 1998;156(1):31-9.
 88. Rutteman GR, Withrow SJ, Macewen EG. Tumors of the mammary gland. In: Withrow SJ; Macewen EG. (Eds.). *Small Animal Clinical Oncology*. Philadelphia: WB Saunders. 2001. p. 455-477.
 89. Sayasith K, Sirois J, Dore M. Molecular Characterization of Feline COX-2 and Expression in Feline Mammary Carcinomas. *Vet Pathol*. 2009;46:423-9.
 90. Schneider R, Dorn CR, Taylor DON. Factors influencing canine mammary cancer development and postsurgical survival. *J Natl Cancer Inst*. 1969;43:1249-61.
 91. Simon D, Schoenrock D, Nolte I, Baumgärtner W, Barron R, Mischke R. Cytologic examination of fine-needle aspirates from mammary gland tumors in the dog: diagnostic accuracy with comparison to histopathology and association with postoperative outcome. *Vet Clin Pathol*. 2009;38(4):521-8.
 92. Soares M, Ribeiro R, Carvalho S, Peleteiro M, Correia J, Ferreira F. Ki-67 as a Prognostic Factor in Feline Mammary Carcinoma: What Is the Optimal Cutoff Value?. *Vet Pathol*. 2016;53(1):37-43.
 93. Sorenmo KU, Deanna RW, Goldsmit RH. Tumors of the mammary gland. In: Withrow SJ, Vail DM. *Withrow & MacEwen's small animal clinical oncology*. Philadelphia: WB Saunders Company. 2013. p. 553-571.

94. Sorenmo KU, Durham AC, Kristiansen V, Pena L, Goldschmidt MH, Stefanovski, D. Developing and testing prognostic bio-scoring systems for canine mammary gland carcinomas. *Vet Comp Oncol*. 2019;17(4):479-88.
95. Souza CHDM, Toledo-Piza E, Amorin R, Barboza A, Tobias KM. Inflammatory mammary carcinoma in 12 dogs: clinical features, cyclooxygenase-2 expression, and response to piroxicam treatment. *Can Vet J*. 2009;50(5):506.
96. Tadrous PJ. Breast. In: *Diagnostic Criteria Handbook in Histopathology: A Surgical Pathology Vade Mecum*. John Wiley, Chichester; 2007. p. 258–266.
97. Teshome M, Hunt KK. Neoadjuvant therapy in the treatment of breast cancer. *Surg Oncol Clin N Am*. 2014;23(3):505-23.
98. Waldrow DR. Diagnosis and surgical management of mammary neoplasia in dogs and cats. *Vet Med*. 2001;96(12):943-948.
99. Weijer K, Hart AA. Prognostic factors in feline mammary carcinoma. *J Natl Cancer Inst*. 1983;70:709-16.
100. Weijer K, Head KL, Misdorp W, Hampe F. Feline malignant mammary tumors: morphology and biology: some comparisons with human and canine mammary carcinomas. *J Natl Cancer I*. 1972;49(6):1697-1704.
101. Zappulli V, Rasotto R, Caliarì D, Mainenti M, Peña L, Goldschmidt MH, Kiupel M. Prognostic evaluation of feline mammary carcinomas a review of the literature. *Vet Pathol*. 2015;52(1):46-60.