BJVP
Brazilian Journal of Veterinary Pathology
ISSN 1983-0246

Case Report

Weissellosis in rainbow trout in Colombia

Gersson Vásquez-Machado[1*], Miguel Rubiano-Garzón[2], Jonny Yepes-Blandón[3], Daniel Gordillo-González[4], Jersson Avila-Coy[1]

[1]Department of Diagnostic Service. HISTOLAB Veterinary Laboratory.
[2]Private Practice of Aquaculture.
[3]GIPEN Research Group on native fish - Piscícola San Silvestre SA. Barrancabermeja, Colombia.
[4]Universidad Nacional de Colombia.
[*]**Corresponding author:** Gersson Vasquez-Machado, Department of Diagnostic Service. HISTOLAB Veterinary Laboratory. Bogotá DC. K. 63 # 9sur – 13. E-mail: gerssonmv@hotmail.com

Submitted June, 1st 2020, Accepted August, 7th 2020

Abstract

Weissellosis is an emergent disease caused by *Weissella*, a Gram-positive bacteria correlated with hemorrhagic illness and mortality in farm-raised trout in several countries. The current study reports the first outbreaks of weissellosis by *Weissella ceti* in rainbow trout (*Oncorhynchus mykiss*), which caused severe mortalities in trout farms in Colombia between May 2016 to June 2019. The disease occurred in several farms irrigated by the same river where temperatures were above 17 °C. Symptoms of the disease were limited almost exclusively to trout above 250 g. The clinical signs consisted of lethargic and anorexic fish, swimming in circles at the surface or against the walls. Pathological findings were mainly ocular lesions like bilateral exophthalmia, periocular and intraocular hemorrhage, lenticular opacity and corneal rupture usually leading to blindness, muscular hemorrhages and necrosis. Microbial isolating from eye, brain, kidney, liver and muscle was performed and *W. ceti* was confirmed by amplification and sequencing of the 16S rRNA. The aim of this work was to characterize the Weisellosis by *Weissella ceti* in trouts in Colombia, including microbiological isolating, molecular analysis, gross and microscopic characterization.

Key words: *Weisella ceti*, *Oncorhynchus mykiss*, pathological lesions, characterization.

Introduction

Weissella is a Gram-positive, catalase-negative, non-endospore-forming bacteria with coccoid or rod-shaped morphology (5, 9, 17), belonging to the phylum Firmicutes, class Bacilli, order Lactobacillales, and family Leuconostocacea (5, 17). Micro-organisms of the genus *Weissella* have been isolated from a wide variety of habitats such as soil, silages, fresh vegetables, fermented foods, meat and meat products (2, 6, 7, 14, 16). In addition, some species have been isolated from human or animal tissues or blood (10, 11, 15). A novel specie of the genus *Weissella* named *Weissella ceti* sp. nov. first isolated from the spleen of beaked whales (*Mesoplon bidens*) (17), has been reported recently as an emerging pathogen producing high mortalities in farmed rainbow trout (*Oncorhynchus mykiss*, Walbaum) in China in 2009 (12), Brazil (8), The United States (18), Japan (14) and Mexico (4). *W. ceti* predominantly affected adult fish (0.5–1.0 kg), and the mortality of affected fish tends to be higher with increasing body weight (3, 8, 18, 19). Affected fish exhibit similar signs and gross lesions, including exophthalmia, hemorrhages in the eyes, mouth, vent, intestinal tract and peritoneal wall as well as petechiae in the liver (8, 12, 19).

The current study reports the clinical sings, gross and histopathological lesions on several outbreaks of Weisellosis by *Weissella ceti* in rainbow trout in Colombia South America.

Material and Methods

Outbreaks

High mortalities up to 50-70% were reported mainly in the summer season in rainbow trout farms raised in concrete ponds, in Colombia from 2016 to 2019, the farms are located in the center of the country (Latitude: 4.37917, Longitude: -74.3233). The seed and the larvae from each farm have the same origin. The disease occurred in four farms with the same water source (the same river). The outbreaks of mortality were higher in farms where temperatures were between 17-22°C. The symptoms of the disease were limited almost exclusively to rainbow trout above 250 g mainly animals ready to harvest 400-500 g, although some smaller animals also showed symptoms but to a lesser degree and severity. Infected fish became lethargic and anorexic, swimming at the surface in circles or against the walls, or congregating at the end of raceways.

Gross and histological Findings

10 clinically diseased fish (300-500g) were collected per farm and transported live in plastic bags with oxygen supplementation to HISTOLAB veterinary diagnostic laboratory for complete pathological and bacteriological analysis. All fish were euthanized via overdose with tricaine methanesulphonate-MS 222, Sigma (400 mg/L) and immediately subjected to postmortem examination. Tissue samples were taken and fixed in neutral buffered 10% formalin, embedded in paraffin wax, sectioned at 4 mm, and stained with hematoxylin. Slides were observed by light microscopy Nikon eclipse E200.

Bacteriological analysis

Samples for bacterial isolation were aseptically taken from the eye, liver, kidney and muscle of each specimen and streaked onto Tryptic Soy Agar and brain heart infusion agar (TSA and BHI, Oxoid) supplemented with 5% sheep blood and all plates were aerobically incubated at 18 hours at 30 °C. A representative isolate colony was selected from each plate, streaked onto a new TSA plate to obtain pure cultures for PCR and 16S rRNA sequencing. The susceptibility of bacteria isolates to 20 antimicrobial agents (Oxoid, UK), including amoxicillin (10 mg), ampicillin (10 mg), cephalothin V (30 mg), chloramphenicol (30 mg), clarithromycin (15 mg), doxycycline (30 mg), enrofloxacin (10 mg), erythromycin (15 mg), florfenicol (10 mg), gentamicin (10 mg), kanamycin (30 mg), neomycin (30 mg), norfloxacin (10 mg), penicillin (10 mg), rifampicin (5 mg), streptomycin (10 mg), sulfamethoxazole (23.75 mg)/trimethoprim (1.25 mg), oxytetracycline (30 mg), tobramycin (10 mg), vancomycin (30 mg) was tested and determined by using the standard method of Kirby and Bauer on Mueller Hinton agar (Becton, Dickinson and Company, USA).

Molecular analysis

The genomic DNA of the host bacterial strain (one isolate from each farm) was extracted using invitrogen purelink genomic DNA extraction kit (Thermo Fisher Scientific) according to the manufacturer's protocol. Amplification and sequencing of the 16S ribosomal RNA gene was performed using ribosomal gene 16S's initiators (27F 5'-AGAGTTTGATCCTGGCTCAG3'; 1492R 5'-GGTTACCTTGTTACGACTT-3'). Taxonomic analysis of unknown sequence was made using NCBI's tool BLAST (Basic Local Alignment Search Tool) and the tool Classifier of the Ribosomal Data Project (RDP). Similarity with the RDP sequences was identified using the tool SeqMatch of the RDP. Multiple sequence alignment was made using the algorithm MUSCLE (Multiple Sequence Comparison by Log-Expectation) of the problem sequence with the thirty sequences of higher similarity reported by BLAST. A phylogenetic tree was generated using the genetic distance model of Tamura-Nei (TN93), with the method of "Neighbor Joining" and the method "Bootstrap" with 100 replicas.

Results

Gross and histological Findings

Gross pathological findings were mainly ocular lesions like bilateral exophthalmia (Fig. 1), periocular and intraocular hemorrhage, lenticular opacity and corneal rupture (Fig. 2), usually leading to blindness. Externally, petechial and ecchymotic hemorrhages were also observed on the base of fins and skin accompanied by dark skin coloration (Fig. 3). At necropsy it was possible to observe several randomly distributed petechiae on the liver (Fig. 4) and swim bladder and diffuse hemorrhages in the gastrointestinal tract including the anus. Occasionally, severe diffuse redness and hemorrhages in skeletal muscle were also observed (Fig. 5). Histopathological changes in the eye include severe multifocal lymphocytic infiltrate affecting the choroid, retina, and adipose tissue, accompanied by corneal ulceration, hemorrhages, and cataracts in some animals (Fig. 6). Sometimes large amounts of coccobacilli were observed in the lesion foci. Ocular muscles showed moderate multifocal necrotic myositis with detachment, retraction, and fiber rupture, as well as moderate edema between the muscle fibers (Fig. 7). Multiple internal organs presented injuries. In the heart the microscopic findings consisted of mixed pericarditis with predominance of lymphocytic cells, accompanied by mild foci of necrosis as well as moderate foci of vasculitis and mild multifocal lymphocytic myocarditis (Fig. 8). The liver contained mild multifocal mixed cholangitis, which was predominantly lymphocytic. Moderate multifocal lymphocytic meningitis was discovered in the brain. In the rectum and anus, we found severe multifocal lymphocytic and hemorrhagic proctitis. Moderate multifocal mixed cystitis mainly lymphocytic with mild presence of coccobacilli and severe multifocal mixed and hemorrhagic

serositis with moderate presence of microthrombi and coccobacilli were found in the swim bladder. There was also peritonitis, mixed with multifocal hemorrhagic and moderate pancreatitis predominantly lymphocytic, with scarce intralesional small rods.



Figure 1. Adult rainbow trout displaying severe bilateral exophthalmia.



Figure 2. Rainbow trout showing severe lenticular opacity and a focally extensive corneal ulcer.

The skin and peripheral muscles contained lymphocytic epidermitis and severe multifocal hemorrhagic and lymphocytic dermatitis with focally extensive moderate ulceration as well as severe multifocal lymphocytic inflammation of the subcutaneous tissue (hypodermis). Retraction and severe multifocal atrophy of fibers, accompanied by moderate foci of necrosis, moderate multifocal lymphocytic and hemorrhagic myositis were discovered in the skeletal muscles (Fig. 9).



Figure 3. Multifocal hemorrhages in skin of the pectoral area and in the base of fins.

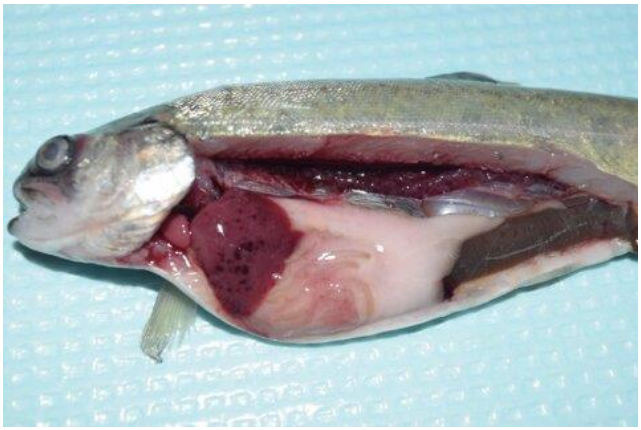

Figure 4. Moderate exophthalmia and moderate focal hemorrhage caudal to the eye, punctate petechial and purpuric hemorrhages in liver.



Figure 5. Rainbow trout with diffuse hemorrhages in muscle.

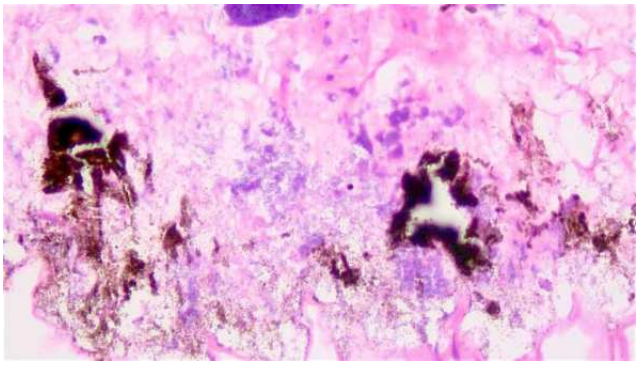

Figure 6. Histological view of a retina from a rainbow trout showing loss of tissue's structure whit severe pigment disintegration of the retinal pigment epithelium; foci of necrosis and mild inflammatory infiltrates, mainly lymphocytes and plasma cells. Abundant bacteria with a basophilic color of cocobacillary morphology can be seen in the image, HE 400x.

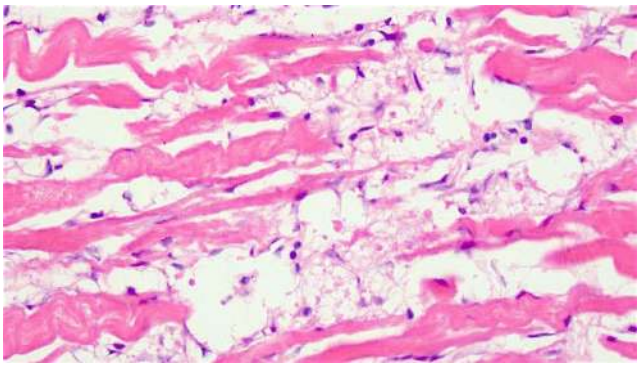

Figure 7. Ocular muscles with moderate multifocal necrotic myositis with detachment, retraction, and fiber rupture, also moderate edema between the muscle fibers, HE 200x.

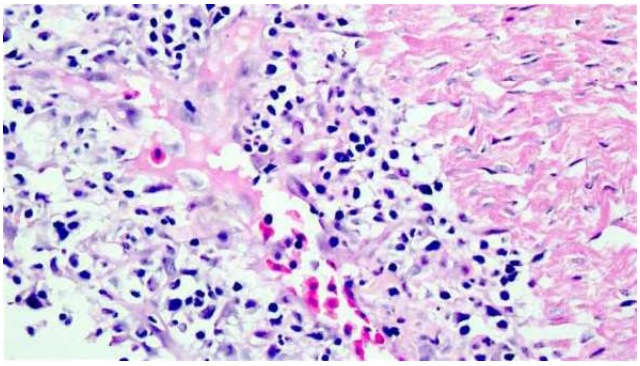

Figure 8. Section of hearth with mixed pericarditis with predominance of lymphocytic infiltrate, accompanied by mild foci of necrosis; moderate foci of vasculitis and mild multifocal lymphocytic myocarditis, HE 200x.

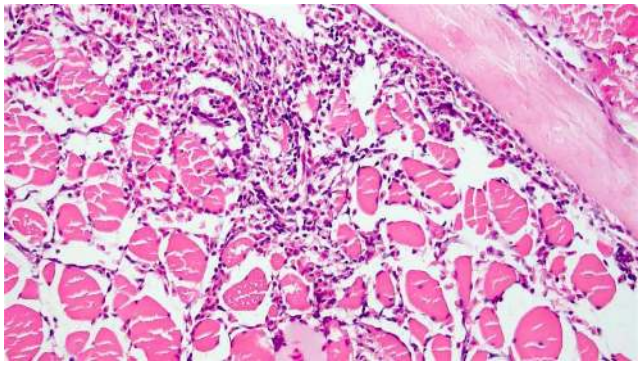

Figure 9. Skeletal muscle: Severe multifocal lymphocytic and hemorrhagic myositis accompanied by moderate foci of retraction, atrophy and necrosis of muscular fibers, HE 200x.

Bacteriological analysis

The pathogen was isolated from multiple tissues including eye, brain, kidney, liver and skeletal muscle. The main bacteriological media used was TSA agar supplemented with 5% sheep blood. However, the bacteria also grew up in bacteriological media (e.g., BHI supplemented with 5% sheep blood). The growth of the colonies took approximately 18 hours at 30 °C. White colonies displaying α- hemolytic activity were observed. Catalase-negative, Gram-positive small rods were observed by Gram stain and non-motile. All obtained cultures were pure.

The antibiogram resulted in resistance to most commercial antibiotics and sensitivity was found only to ampicillin, norfloxacin and intermediate sensitivity to oxytetracycline and florfenicol.

Molecular analysis

Weisella ceti was confirmed (GenBank accession numbers: MK968273, MK968274, MK968275, MK968276). RDP Classifier determined that it was a sequence of a microorganism belonging to the genus *Weissella*. Comparison with the database of sequences of 16S of RDP, using the SeqMatch tool against cultivated isolates, showed that the assembled problem sequence had higher similarity with sequences of the species *W. ceti*. Results of the taxonomic analysis of the assembled problem sequence of 1384 bp against the NCBI ref_seq database indicated it had 99% identity at 100% of its length, with 16S ribosomal gene sequences belonging to the *Weissella ceti* species. Phylogenetic tree showed sequence analyzed was grouped with sequences of the *Weissella ceti* species (Fig. 10).

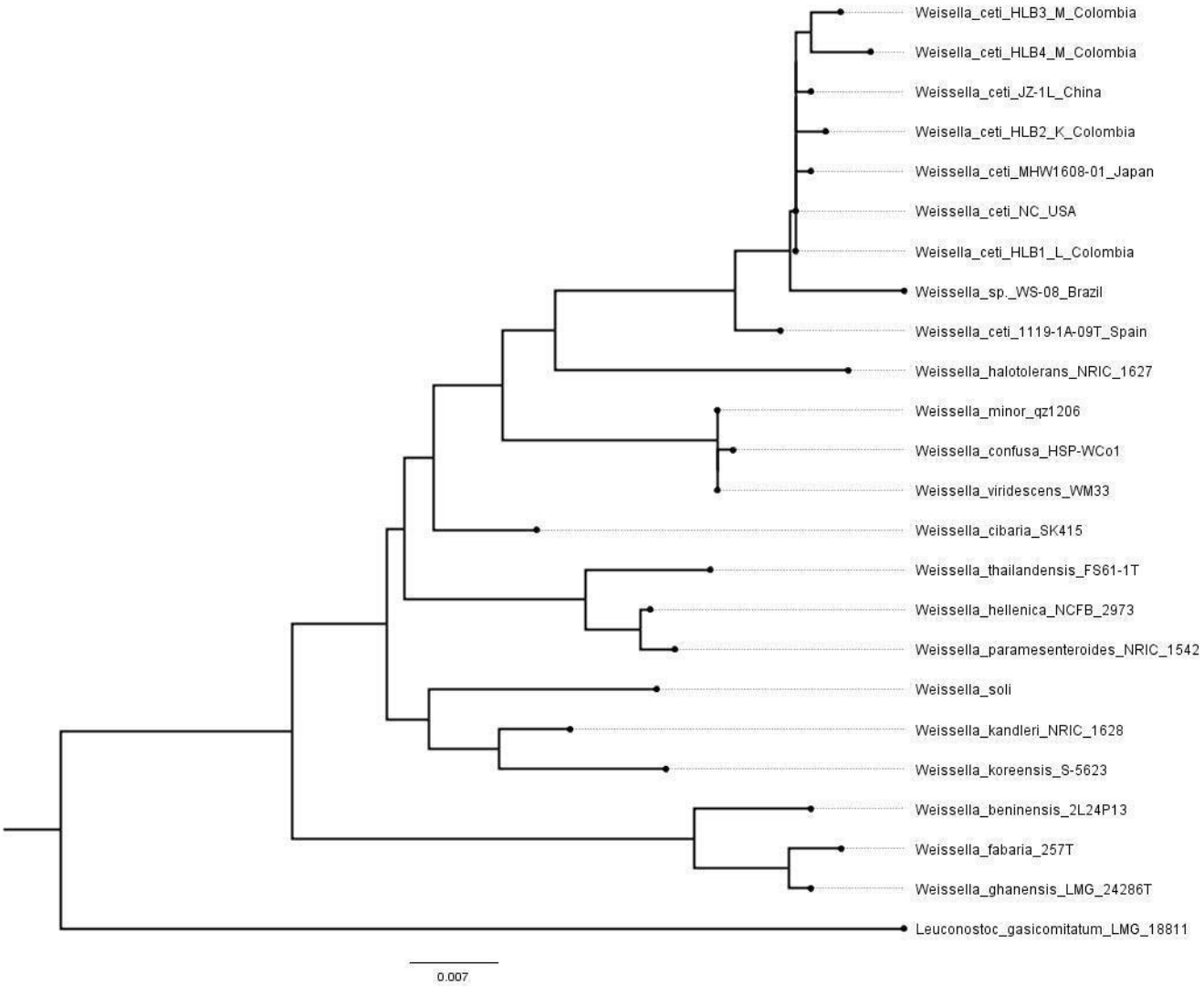

Figure 10. Phylogenetic tree inferred from the 16S rRNA gene sequence comparison using the neighbour-joining method, showing the relationships of the new Colombia *W. ceti* isolates with all recognized species of the genus *Weissella* and *W. ceti* rainbow trout isolates from different countries.

Discussion

Here, we present the evidence of a Weissellosis outbreak in rainbow trout farms in Colombia. Confirmation that the *W. ceti* bacterium was the causative agent in this outbreak was derived from amplification and sequencing of the 16S ribosomal RNA gene, gross, and histopathological findings. The Colombian outbreaks were associated with high water temperatures reaching 17–22 °C range. High temperatures were also indicated as a predisposing factor in the USA and Brazilian *Weissella* outbreaks (8, 18). The more important clinical symptoms and pathologic lesions included dark skin discoloration, lethargic swimming, bilateral exophthalmia, corneal opacity, ocular hemorrhages, corneal rupture, skin and fin hemorrhages, and petechiae in the liver and cavity coelomic, similar to those reported in USA, Brazil, China and Japan (8, 12, 14, 18). Furthermore, in this case we were able to isolate the bacteria from hemorrhagic lesions in the muscle and we reported histopathological lesions not previously described like diffuse muscular myonecrosis in some animals with diffuse hemorrhages. To our knowledge this is the first time that myonecrosis and bacterial isolation from muscle are reported in Weissellosis outbreaks. Clinical symptoms were observed mainly in adult animals (250-600 g) similar to what was reported in China (12), and the United States (18) where clinical signs were observed only in adult rainbow trout. However, in our case we also found a lower proportion of some juvenile animals (10-60 g) including fingerlings showing symptoms of Weissellosis, similar to what was reported in Brazil which found injuries in both adults and young (fry and fingerlings) (8).

The infection has been temporally controlled with the use of some antibiotics such as ampicillin, florfenicol, but the bacteria quickly acquired resistance to these drugs,

which has been proved by subsequent isolates and antibiograms (1). We conclude that Weissellosis by *W. ceti* in Colombia occurs mainly in rainbow trout more than 250 g in weight and sporadic in fry and juveniles. The disease is mainly associated with high water temperature. *W. ceti* could be isolated from several organs including muscle where causes necrotic and hemorrhagic lesions as we reported here for first time. *W. ceti* showed multidrug resistance which has been a problem for its control. Further investigation should be addressed to deep in the epidemiology of the disease. The presence of the bacteria in water has been proposed. Therefore, some authors suggest that *Weissella* strain may normally exist in the environment of the rainbow trout and become pathogenic under unknown conditions (13). In other words, it seems to be an opportunistic pathogen to fish.

References

1. Bauer AW, Kirby WM, Sherris JC, Turck M. Antibiotic susceptibility testing by a standardized single disk method. Am J Clin Pathol. 1966;45:493-6.
2. Björkroth KJ, Schillinger U, Geisen R, Weiss N, Hoste B, Holzapfel WH, Korkeala HJ, Vandamme P. Taxonomic study of *Weissella confusa* and description of *Weissella cibaria* sp. nov., detected in food and clinical samples. Int J Syst Evol Microbiol. 2002;52(1):141-8.
3. Cai Y, Benno Y, Nakase T, Oh TK. Specific probiotic characterization of *Weissella hellenica* DS-12 isolated from flounder intestine. J Gen Appl Microbiol. 1998;44(5):311-6.
4. Castrejón-Nájera, J, Ortega C, Fajardo R, Irgang R, Tapia-Cammas D, Poblete-Morales M, Avendaño-Herrera R. Isolation characterization, virulence potential of *Weissella ceti* responsible for weissellosis outbreak in rainbow trout (*Oncorhynchus mykiss*) cultured in Mexico. Transbound Emerg Dis. 2018;65(6):1401-7.
5. Collins MD, Samelis J, Metaxopoulos J, Wallbanks S. Taxonomic studies on some Leuconostoc-like organisms from fermented sausages: description of a new genus *Weissella* for the *Leuconostoc paramesenteroides* group of species. J Appl Bacteriol. 1993;75(6):595-603.
6. de Bruyne K, Camu N, de Vuyst L, Vandamme P. *Weissella fabaria* sp. nov., from a *Ghanaian cocoa* fermentation. Int J Syst Evol Microbiol. 2010;60(9):1999-2005.
7. Dellaglio F, Torriani S. DNA-DNA homology, physiological characteristics and distribution of lactic acid bacteria isolated from maize silage. J Appl Microbiol. 1986;60(2):83-92.
8. Figueiredo HC, Costa FA, Leal CA, Carvalho-Castro GA, Leite RC. *Weissella* sp. outbreaks in commercial rainbow trout (*Oncorhynchus mykiss*) farms in Brazil. Vet Microbiol. 2012;156(3-4):359-66.
9. Fusco V, Quero GM, Cho GS, Kabisch J, Meske D, Neve H, Bockelmann W, Franz CM. The genus *Weissella*: taxonomy, ecology and biotechnological potential. Front Microbiol. 2015;6:155.
10. Green M, Barbadora K, Michaels M. Recovery of vancomycin-resistant gram-positive cocci from pediatric liver transplant recipients. J Clin Microbiol.1991;29(11):2503-6.
11. Green M, Wadowsky RM, Barbadora K. Recovery of vancomycin-resistant gram-positive cocci from children. J Clin Microbiol. 1990;28(3):484-8.
12. Liu JY, Li AH, Ji C, Yang WM. First description of a novel *Weissella* species as an opportunistic pathogen for rainbow trout *Oncorhynchus mykiss* (Walbaum) in China. Vet Microbiol. 2009;136(3-4):314-20.
13. Magnusson J, Jonsson H, Schnürer J, Roos S. *Weissella soli* sp. nov., a lactic acid bacterium isolated from soil. Int J Syst Evol Microbiol. 2002;52(3):831-4.
14. Mitomi K, Hoai TD, Nishiki I, Yoshida T. First isolation of *Weissella ceti* responsible for outbreaks of weissellosis in farmed rainbow trout in Japan. J Fish Dis. 2018;41(5):847-50.
15. Olano A, Chua J, Schroeder S, Minari A, Salvia ML, Hall G. *Weissella confusa* (Basonym: *Lactobacillus confusus*) bacteremia: a case report. J Clin Micriobiol. 2001;39(4):1604-7.
16. Padonou SW, Schillinger U, Nielsen DS, Franz CM, Hansen M, Hounhouigan JD, Nago MC, Jakobsen M. *Weissella beninensis* sp. nov., a motile lactic acid bacterium from submerged cassava fermentations, and emended description of the genus *Weissella*. Int J Syst Evol Microbiol. 2010;60(9):2193-8.
17. Vela AI, Fernández A, de Quirós YB, Herráez P, Domínguez L, Fernández-Garayzábal JF. *Weissella ceti* sp. nov., isolated from beaked whales (*Mesoplodon bidens*). Int J Syst Evol Microbiol. 2011;61(11):2758-62.
18. Welch TJ, Good CM. Mortality associated with Weissellosis (*Weissella* sp.) in USA farmed rainbow trout: potential for control by vaccination. Aquaculture. 2013;388:122-7.
19. Welch TJ, Marancik DP, Good CM. *Weissella ceti*. Fish viruses and bacteria: Pathobiology and protection, 2017, p. 334-338.