BJVP
Brazilian Journal of Veterinary Pathology
ISSN 1983-0246

Original Full Article

Epidemiology of Canine Mast Cell Tumors in Uruguay

Alex Denis, Kanji Yamasaki, Juan Carlos Cruz, José Manuel Verdes*

Unidad Patología, Departamento de Patobiología, Facultad de Veterinaria Universidad de la República (Udelar), Montevideo, Uruguay.

***Corresponding author:** José Manuel Verdes DMV, MSc, PhD., Facultad de Veterinaria, Universidad de la República, Av. Alberto Lasplaces 1620, CP 11600, Montevideo, Uruguay.

Submitted July, 08th 2018, Accepted October, 10th 2018

Abstract

We examined in the present study main epidemiological features of canine mast cell tumors in Uruguay, principal breeds of occurrence, age, gender, anatomical distributions, and associated differences of pathological grading. During a three-year period, eighty four out of 405 skin specimens of dogs mainly received at the Veterinary Faculty of Montevideo from private clinics were mast cell tumors. Mix-breed dogs were mostly affected, followed by Labrador Retrievers, Boxers, Pit bulls and Golden Retrievers. Age of patients ranged from 3 to 15 years (median 7.9), and the incidence in females was slightly higher than in males. Tumors were more frequent in the trunk, followed by extremities, scrotum and neck. The majority of specimens were of high malignancy.

Key words: canine, epidemiology, mast cell tumor, Uruguay.

Introduction

Canine Mast cell Tumor (MCT) is a relevant skin malignant neoplasia in canine veterinary practice, with a variable incidence of 7-21% according to different reports worldwide (1, 4, 5, 7, 9, 14, 18, 21). Some MCTs show a slow growth rate and patients can be cured by surgical excision alone, whereas others present rapid growth and early lymph node and distant metastatic behavior. The incidence of this tumor in dogs was reported from the United States, Europe and Asia, with some age and sex predisposition of occurrence (1, 3, 8, 16, 18, 20, 21). However, epidemiological information from South America is scarce. In Brazil, it was reported that the most frequently affected breed was Boxers, followed by Schnauzers and mix-breed dogs (5). The histopathological classification of MCTs is said to be useful for an assessment of clinical outcome, and consequently qualitative malignancy grading systems were proposed (2, 11, 15). Among them, the Patnaik's classification (15) has been the most widely used. This system classifies MCTs into 3 grades based on histologic characteristics that include cellularity, cellular morphology, invasiveness, mitotic activity, and stromal reaction. According to different authors grades 1 and 3 are consistent in terms of clinical signs, but not grade 2 (10, 11, 16, 19). To improve concordance among pathologists and reduce prognosis uncertainty of the Patnaik's system, a two-tier classification scheme was proposed by Kiupel et al. (11) based on the mitotic activity and the degree of anisokaryosis of the tumor cells. Several recent reports found this classification useful (1, 8, 9, 16, 17). In the present study we characterize the incidence of canine MCTs in Uruguay considering breed, age, gender and anatomical distributions, and make an assessment of pathological grading according to Kiupel et al. (11).

Material and Methods

We analyzed 84 biopsies with positive histological diagnoses of MCTs, over a total of 405 skin tumor samples accessioned in our laboratory during a three-year period, from 2017 to 2019. Clinical information (e.g., gender, age, breed or anatomical locations) of each dog was obtained. Samples were submitted by clinicians fixed in 10% buffered formalin solution, and were routinely processed for histological analysis, sectioned at 4 µm, stained with hematoxylin-eosin. Special staining (e.g.,

 All rights reserved 2007.

toluidine blue) were performed as deemed necessary to confirm the diagnosis. Histopathological examination was performed under light microscopy by multiple veterinary pathologists, and tumors were graded according to Kiupel's 2-tier grading system (11). The assignment of high-grade MCTs was based on the presence of one of the following features: at least 7 mitotic figures in 10 high-power fields (hpf, 40x); at least 3 multinucleated (3 or more nuclei) cells in 10 hpf; at least 3 bizarre nuclei in 10 hpf; karyomegaly (i.e. nuclear diameters of at least 10% of neoplastic cells vary by at least two-fold).

Results

Data about gender, age, breed, tumor locations and histological grading are shown in Table1. A high percentage of skin tumor biopsies corresponded to MCTs, as 84 of our 405 samples had a positive diagnosis (20.7%). Mix-breed dogs were most commonly affected (n=22, 26.2%), followed by Labrador Retrievers (n=13, 15.5%), Boxers (n=12, 14.3%), Pit bulls (n=11, 13.1%), Golden Retrievers (n=7, 8.3%) and others (n=17, 20.2 %). Ages for patients with positive diagnoses ranged from 3 to 15 years (median 7.9 years), and 49 were females (58.3%) and 35 males (41.7%). All samples were obtained from dogs that were not neutered.

Table 1. Clinical and histological data of canine mast cell tumors from Uruguay.

Variable	n (%)
Breed (n = 84)	
Mixed	22 (26.2)
Labrador Retrievers	13 (15.5)
Boxer	12 (14.3)
Pit bull	11 (13.1)
Golden Retriever	7 (8.3)
Others	17 (20.2)
Sex (n = 84)	
Male	35 (41.7)
Female	49 (58.3)
Anatomic site(n = 84)	
Trunk	28 (33.3)
Extremities	25 (29.8)
Scrotum	8 (9.5)
Neck	6 (7.1)
Others	14 (16.7)
No information	3 (3.6)
Histological grading (n = 84)	
Low	35 (41.7)
High	49 (58.3)

Tumor location included the trunk area (n=28, 33.3 %), extremities (n=25, 29.8 %), the scrotum (n=8, 9.5 %), neck (n=6, 7.1%), other locations (n=14, 16.7 %), and just for a few there was no information available (n=3, 3.6 %). According to the Kiupel's grading system, low malignancy grade was observed in 35 cases (41.7%), and high grade in the remaining 49 (58.3%) (Figs. 1 and 2).

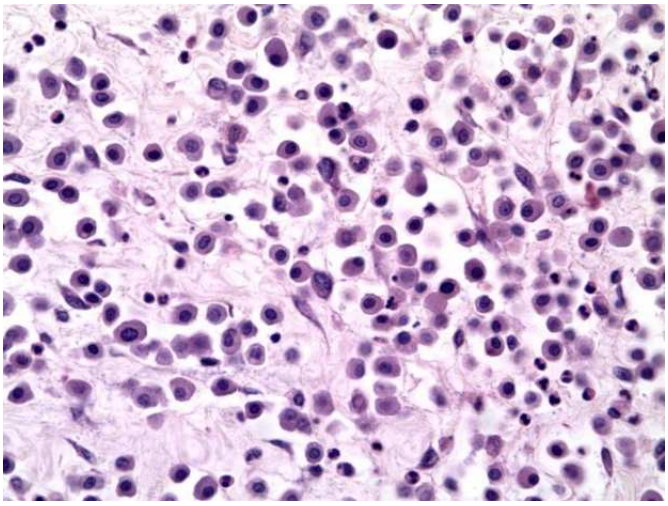

Figure 1. Low grade mast cell tumor. Well-differentiated tumor cells, mast cells with evident cell granulation and round nuclei (HE stain, hpf, 40x).

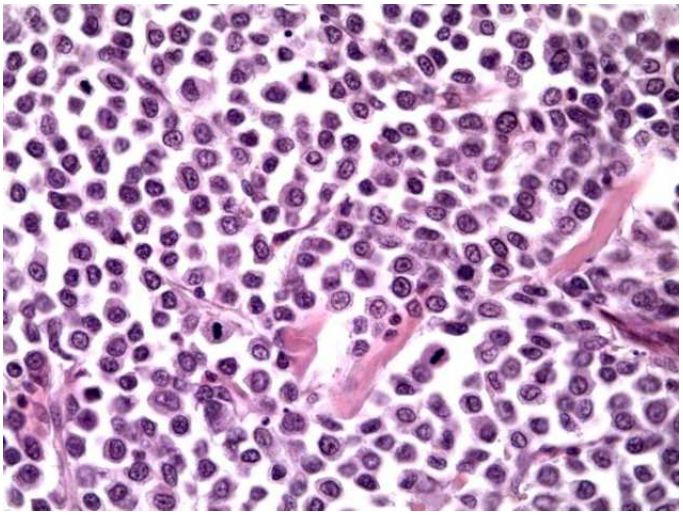

Figure 2. High grade mast cell tumor. Tumor cells bear less differentiated granules, and frequently exhibit mitosis and karyomegaly (HE stain, hpf, 40x).

Discussion

MCTs are considered the most common canine cutaneous tumors, accounting for 7% to 21% of all canine skin tumors, and its incidence varies by region (1, 4, 5, 7, 9, 13, 14, 18, 21). There are a few epidemiological reports from South America, of which a study held in our region reported that MCT was about 20.9% of all skin tumors in a sample of 761 from Brazil (5), a similar frequency than that in our study. On the other hand, the incidence of this tumor in Central America was reported to be quite low, around 6.8% (4). These differences may be influenced by breeds involved and even environmental factors.

Boxers, American Pit Bull Terriers, Schnauzer, French Bulldogs and Labrador Retrievers are said to be at high risk of developing MCT (1, 16, 18). In our study, most cases were in Labrador Retrievers, Boxer and Pit bull, breeds in which MCT are known to be highly prevalent. Miller reported that poorly differentiated MCTs were common in Shar-Pei dogs below 2 years of age (12). The development of these tumors in young dogs was not detected herein.

There are no previous reports of gender differences in the occurrence of MCT (18, 20, 21). We observed more often in females than in males, but it is necessary to examine a larger number of specimens to test for gender differences. Although Pierini et al. (16) reported that a significantly higher frequency of MCTs was found in neutered dogs, their results may be skewed by the fact that most of the dog population in Italy is likely spayed. We are not able to certainly indicate whether the occurrence of this tumor was affected by castration, neutering, or contraception, because there were no neutered dogs in our sample. A large portion of the dog population in Uruguay is intact. In regard to body distribution of MCTs, it is usually assumed that it mostly occurs in the trunk, limbs, scrotum, vulva, perineum, face, head, neck, prepuce, oral mucosa, and pinna (8, 21). Similarly, our most common location was the trunk, and other sites of occurrence are not incongruent with reports about location preferences.

A recent work reported that the incidence of low grade MCT using the binary Kiupel'grading system was 67% (9), which is somewhat contrasting to our incidence of 42%. The difference may be related to environmental factors and/or dog breeds, age, and also come other not yet identified causative effects. The predominance of high grade MCTs in our study is probably characteristic of its presentation in Uruguay. For future studies, it will be necessary to examine the presence or absence of tumor cells at the stump of the excised materials with high histological grading, and to investigate the relationship between these results with local recurrence and clinical signs of disseminated disease.

In summary, Uruguayan dogs seems to present a high incidence of skin MCT, and prevalence of high malignancy grade compared to other countries. Other features already reported for MCT showed no relevant differences.

Acknowledgements

The authors thank Victoria Yozzi for technical assistance, and Dr. Claudio Borteiro for critically reviewing and English editing. Alex Denis is fellowship recipient of Comisión de Investigación y Desarrollo Científico (CIDEC-Udelar, Uruguay). Kanji Yamasaki is supported by Japan International Cooperation Agency (JICA) and Programa de Contratación de Investigadores Provenientes del Exterior (CSIC-Udelar, Uruguay), José Manuel Verdes acknowledge to CSIC-Udelar, PEDECIBA, and ANII (Uruguay).

References

1. Blackwood L, Murphy S, Buracco P, de Vos JP, de Fornel-Thibaud P, Hirschberger J, Kessler M, Pastor J, Ponce F, Savary-Bataille K, Argyle DJ. European consensus document on mast cell tumours in dogs and cats. Vet Comp Oncol. 2012;10:e1-e29.
2. Bostock DE. The prognosis following surgical removal of mastocytomas in dogs. J Small Anim Pract. 1973;14:27-41.
3. Brønden LB, Eriksen T, Kristensen AT. Mast cell tumours and other skin neoplasia in Danish dogs - data from the Danish Veterinary Cancer Registry. Acta Vet Scand. 2010;52:6.
4. Chikweto A, McNeil P, Bhaiyat MI, Stone D, Sharma RN. Neoplastic and nonneoplastic cutaneous tumors of dogs in Grenada, West Indies. ISRN Vet Sci. 2011; 416435.
5. de Souza TM, Fighera RA, Irigoyen LF, de Barros CSL. Retrospective study on 761 canine skin tumors. Cienc Rural. 2006;36:555-60.
6. Dobson JM, Scase TJ. Advances in the diagnosis and management of cutaneous mast cell tumours in dogs. J Small Anim Pract. 2007;48:424-31.
7. Graf R, Pospischil A, Guscetti F, Meier D, Welle M, Dettwiler M. Cutaneous tumors in Swiss dogs: retrospective data from the Swiss Canine Cancer Registry, 2008–2013. Vet Pathol. 2018;55:809-20.
8. Horta RS, Lavalle GE, Monteiro LN, Souza MCC, Cassali GD, Araújo RB. Assessment of canine mast cell tumor mortality risk based on clinical, histologic, immunohistochemical, and molecular features. Vet Pathol. 2018;55:212-23.
9. Kok MK, Chambers JK, Tsuboi M, Nishimura R, Tsujimoto H, Uchida K, Nakayama H. Retrospective study of canine cutaneous tumors in Japan, 2008–2017. J Vet Med Sci. 2019;81:1133-43.
10. Kiupel M. Mast cell tumors. In: Meuten DJ, editor. Tumors in Domestic Animals. 5th ed. Iowa: Wiley Blackwell; 2017. p.176-202.
11. Kiupel M, Webster JD, Bailey KL, Best S, DeLay J, Detrisac CJ, Fitzgerald SD, Gamble D, Ginn PE, Goldschmidt MH, Hendrick MJ, Howerth EW, Janovitz EB, Langohr I, Lenz SD, Lipscomb TP, Miller MA, Misdorp W, Moroff S, Mullaney TP, Neyens I, O'Toole D, Ramos-Vara J, Scase TJ, Schulman FY, Sledge D, Smedley RC, Smith K, W Snyder P, Southorn E, Stedman NL, Steficek BA, Stromberg PC, Valli VE, Weisbrode SE, Yager J, Heller J, Miller R. Proposal of a 2-Tier Histologic Grading System for Canine Cutaneous Mast Cell Tumors to More Accurately Predict Biological Behavior. Vet Pathol. 2011;48:147-55.

12. Miller DM. The occurrence of mast cell tumors in young Shar-Peis. J Vet Diagn Invest. 1995;7:360-3.
13. Murphy S, Sparkes AH, Blunden AS, Brearley MJ, Smith KC. Effects of stage and number of tumours on prognosis of dogs with cutaneous mast cell Tumours. Vet Rec. 2006;158:287-91.
14. Pakhrin B, Kang MS, Bae IH, Park MS, Jee H, You MH, Kim JH, Yoon BI, Choi YK, Kim DY. Retrospective study of canine cutaneous tumors in Korea. J Vet Sci. 2007;8:229-36.
15. Patnaik AK, Ehler WJ, MacEwen EG. Canine Cutaneous Mast Cell Tumor: Morphologic Grading and Survival Time in 83 Dogs. Vet Pathol. 1984;21: 469-74.
16. Pierini A, Lubas G, Gori E, Binanti D, Millanta F, Marchetti V. Epidemiology of breed-related mast cell tumour occurrence and prognostic significance of clinical features in a defined population of dogs in west-central Italy. Vet Sci. 2019;6:53.
17. Sabattini S, Scarpa F, Berlato D, Bettini G. Histologic grading of canine mast cell tumor: is 2 better than 3?. Vet Pathol. 2015;52:70-3.
18. Shoop SJ, Marlow S, Church DB, English K, McGreevy PD, Stell AJ, Thomson PC, O'Neill DG, Brodbelt DC. Prevalence and risk factors for mast cell tumours in dogs in England. Canine Gen Epidemiol. 2015;2:1.
19. Thompson JJ, Pearl DL, Yager JA, Best SJ, Coomber BL, Foster RA. Canine subcutaneous mast cell tumor: characterization and prognostic indices. Vet Pathol. 2011;48:156-68.
20. Strefezzi RF, Xavier JG, Catão-Dias JL. Morphometry of Canine Cutaneous Mast Cell Tumors. Vet Pathol. 2003;40:268-75.
21. Welle MM, Bley CR, Howard J, Rüfenacht S. Canine mast cell tumours: a review of the pathogenesis, clinical features, pathology and treatment. Vet Dermatol. 2008;19:321-39.