Melo, et al.; **Structural description of sea turtle fibropapilloma.**
Braz J Vet Pathol, 2020, 13(3), 585 – 591
DOI: 10.24070/bjvp.1983-0246.v13i3p585-591

BJVP
Brazilian Journal of Veterinary Pathology
ISSN 1983-0246

Original Full Paper

Structural description of sea turtle fibropapilloma

Luana F. Melo[1,2*], Isabel G. Velasco[2], Julia B. Aquino[1], Rosangela Rodrigues[1], Edris Q. Lopes[1,2], Rose E. G. Rici[1]

[1]Department of Anatomy of Domestic and Wild Animals. Faculty of Veterinary Medicine and Zootechnics, University of São Paulo - FMVZ USP. São Paulo - SP, Brazil.
[2]Institute of Marine Biology and Environment - IBIMM. Santa Cruz das Palmeiras - SP, Brazil.
[*]**Corresponding author:** Luana Félix de Melo, Master in Science. Department of Anatomy of Domestic and Wild Animals. Faculty of Veterinary Medicine and Zootechnics, University of São Paulo - FMVZ USP. Avenida Professor Orlando Marques de Paiva, 87 - Butantã, São Paulo - SP, 05508-010 Brazil. E-mail: luanafelix@usp.br.

Submitted June, 16th 2020, Accepted August, 24th 2020

Abstract

Fibropapillomatosis is a neoplastic disease that affects sea turtles. It is characterized by multiple papillomas, fibropapillomas and cutaneous and/or visceral fibromas. Although its etiology has not been fully elucidated, it is known that there is a strong involvement of an alpha - herpesvirus, but the influence of other factors such as parasites, genetics, chemical carcinogens, contaminants, immunosuppression and ultraviolet radiation may be important in the disease, being pointed out as one of the main causes of a reduction in the green turtle population. Thus, the objective of this article was to describe the morphology of cutaneous fibropapillomas found in specimens of the green turtle (*Chelonia mydas*), using light and scanning electron microscopy in order to contribute to the mechanism of tumor formation. Microscopically, it presented hyperplastic stromal proliferation and epidermal proliferation with hyperkeratosis. The bulky mass was coated with keratin, with some keratinocyte invaginations, that allowed the keratin to infiltrate from the epidermis into the dermis, forming large keratinized circular spirals. Another fact that we observed was the influence of the inflammation of the tumors caused by ectoparasites.

Key words: fibropapillomatosis, *Chelonia mydas*, marine diseases, ectoparasites.

Introduction

Popularly known as the green turtle or arowana, the species *Chelonia mydas*, is widely distributed across the seas from the tropics to the temperate zones (11), being the species of sea turtle that has more coastal habits (23).

The diseases that affect sea turtles are not fully understood, and like other vertebrate, they are also susceptible to bacterial, fungal, viral and parasitic pathogens that can cause disease and even lead to death (9). Fibropapillomatosis is a debilitating disease, causing morbidity and mortality in marine turtles, which can cause fibromas, papillomas and cutaneous and visceral fibropapillomas (1). Despite being a disease considered benign, as they can regress spontaneously (18), it is debilitating and potentially fatal for turtles, as they hamper survival, causing emaciation, difficulty in swimming, locomotion, breathing and feeding (5). Being pointed out as one of the main causes of a reduction in the green turtle population, as they hardly reach adulthood, therefore, they do not contribute to the continuity of the species (28).

The fact that fibropapillomatosis is fatal in many cases, the interest in the impact of this disease on the long-life span of green turtle populations has increased (15). Knowledge of the health status of populations is considered imperative for the development of conservation programs (8).

Although its etiology has not been fully elucidated, it is known that there is a strong involvement of an alpha - herpesvirus, but the influence of other factors such as parasites, genetics, chemical carcinogens, contaminants, immunosuppression and ultraviolet radiation may be important in the disease (6, 10, 12, 17, 19, 20, 25, 26).

 All rights reserved 2007.

Melo, et al.; **Structural description of sea turtle fibropapilloma.**
Braz J Vet Pathol, 2020, 13(3), 585 – 591
DOI: 10.24070/bjvp.1983-0246.v13i3p585-591

Thus, the objective of this paper was to characterize morphologically cutaneous fibropapilloma found in green turtles (*C. mydas*) in order to support new studies on tumor formation development, to confirm the diagnosis of fibropapillomatosis due to the need for a differential diagnosis with several pathologies that can affect the skin.

Material and Methods

Samples of fibropapillomas and ectoparasites from three specimens of green turtle were collected from dead stranded on Guaraú beach, Peruíbe - SP and obtained with authorization and licenses approved by ICMBio / SISBio: 50132-1 and CEUA-IBIMM: 005/18.

The tumors were grouped according to Work and Balazs (31) so that it was possible to classify the severity of fibropapillomatosis, relating the size and quantity of tumors through the association between A to D, with A tumors smaller than 1 cm, B of 1 to 4 cm, C greater than 4 to 10 cm and D greater than 10 cm. The score obtained varying from unaffected (score 0) to severely affected (score 3). For histological analysis, the samples were fixed in 10% formaldehyde for 48 hours, in the sequence dehydrated in increasing series of ethanol (70 to 100%) and diaphanized in xylol, with later inclusion in paraffin. 5µm thick cuts were made in the microtome (Leica German) and stained with hematoxylin-eosin, and Mallory stain. The images were obtained through the Nikon Eclipse E-800 light microscope (22).

Part of the samples presenting fibropapilloma and ectoparasites were prepared for scanning electron microscopy. After fixing with 10% formaldehyde, they were dehydrated in increasing series of alcohols in concentrations of 70%, 80%, 90% and 100%, dried in a critical point apparatus LEICA EM CPD 300, glued with carbon glue on aluminum metallic bases (stub) and metallized (sputting) with gold in the EMITECH K550 metallizer device, and analyzed and photocumented in a LEO 435VP scanning electron microscope (SEM).

All images were obtained at the Advanced Center for Diagnostic Imaging - CADI-FMVZ-USP.

Results and Discussion

In the three green turtle specimens, there wasn´t a pattern in tumor appearance, being random arranged around the neck, base of the tail, cervical, inguinal, axillary and base of the shell (Fig. 1), as described by Cubas and collaborators (5), where they affirm the predominance in the soft tissue of the turtle's skin, which can also appear close to the eye and oral region. According to Matushima and collaborators (21), tumors can also be visceral, reaching internal organs such as liver, lungs and kidneys, but they were not observed in our specimens, since only 25% to 30% of turtles that present external tumors have internal tumors (1), tending to appear in the final stage of the disease and detected at necropsy (16).

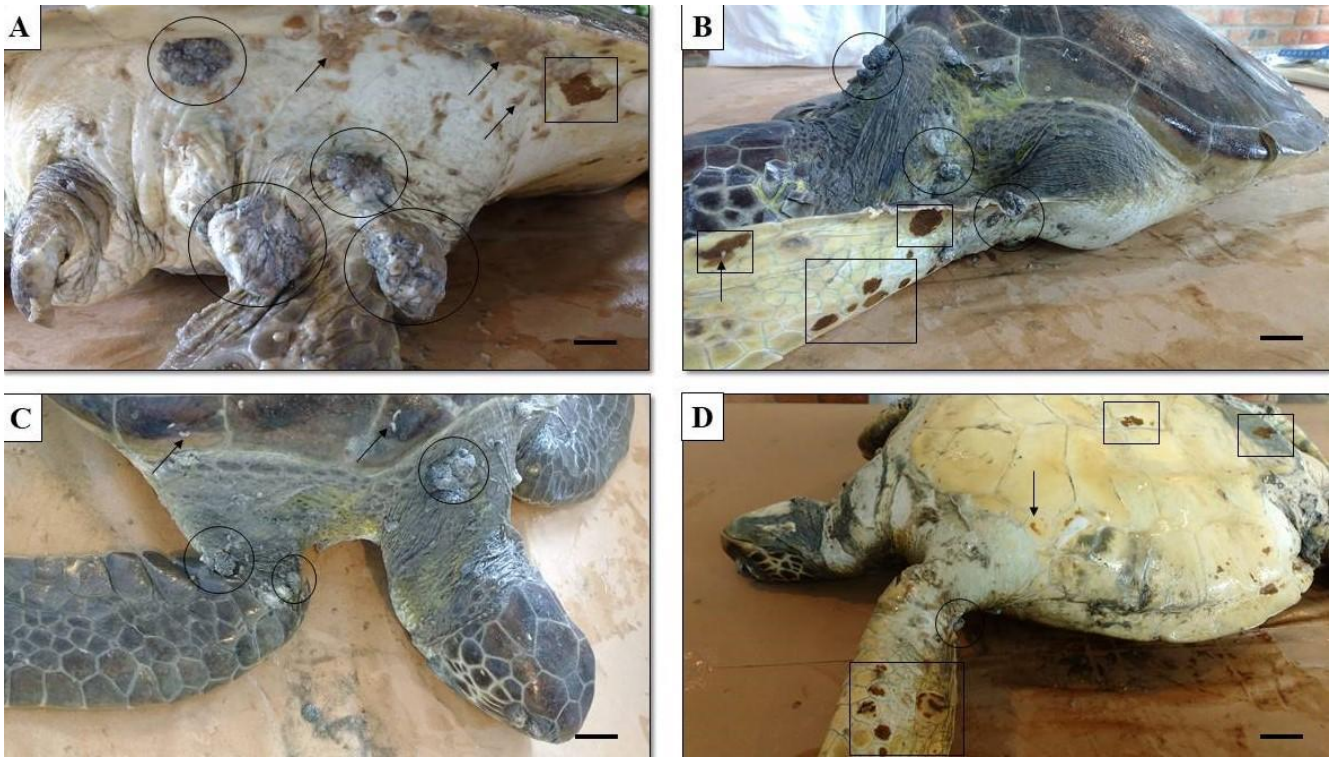

Melo, et al.; **Structural description of sea turtle fibropapilloma.**
Braz J Vet Pathol, 2020, 13(3), 585 – 591
DOI: 10.24070/bjvp.1983-0246.v13i3p585-591

Figure 1. Photomacrography of individuals from Chelonia mydas, showing cutaneous fibropapillomas in circles, ectoparasist egg colonies in squares and ectoparasites in arrows.

The tumors presented as a solid protrusion of the epidermis, having a narrow insertion base, giving pedunculated and quite firm shape, in gray color with some white dots, various sizes and in different aspects as to their external appearance, ranging from smooth to rough, resembling a cauliflower, with some small pointed projections (Figs. 1 and 2). According to Rhodes (27), fibropapillomatosis tumors can be intensely pigmented, becoming white, pink, red, gray, purple or black, they can vary in size and the largest may be ulcerated or necrotic.

It was also noted the presence of ectoparasites and their eggs scattered in small populations over the entire length of the individuals (Fig. 1). It is common for individuals affected by this disease to be infested with ectoparasites (21).

Work and Balazs (31) established a tumor score by associating the size, measuring from one end to the other, and the number of tumors, classifying the severity of fibropapillomatosis. We observed that two specimens studied were classified in score 3, severely affected and one score 2, moderately affected (Fig. 2).

Ectoparasites were leeches identified as the genus *Ozobranchus* that presented themselves in different sizes, close to the populations of their eggs (Fig. 2). This family includes two main species, which are permanent and exclusive ectoparasites of sea turtles: *O. branchiatus* and *O. margoi* (4). Although *O. branchiatus* and *O. margoi* can parasitize several species of sea turtles, these organisms show host preference, where in general, *O. branchiatus* is commonly found parasitizing the green turtle (*Chelonia mydas*), on the other hand, *O. margoi* is more often associated with parasitism in the loggerhead turtle (*Caretta caretta*) (3), thus supporting the identification of *Ozobranchus branchiatus*.

During the necropsy, it was possible to collect approximately 50 ectoparasites from each of the green turtle individuals, but some were lost during the necropsy, considering that a single turtle can carry more than one hundred leeches. Parasitism by *Ozobranchus* spp. can cause severe skin lesions, and risk of viral transmission that may be associated with the development of fibropapillomatosis (3, 7, 13, 30).

The marine leech, *O. branchiatus* is characterized by the segmented body, with the gills positioned laterally, with the presence of 2 suction cups at its ends, a large one positioned posteriorly, which it uses to adhere to the host, and a smaller one with the presence of a the orifice, the mouth, from where a proboscis is projected to pierce the turtle's skin to access the blood (Fig. 3). The colonies of eggs were dispersed throughout the turtle's body, where it was possible to see eggs with ectoparasites still in development and others that had already hatched with the larvae hatching from the eggs and others around (Fig. 3). Parasites were found on tumor masses frequently, causing inflammation with an aggressive hyperplastic response, which contributes to tumor growth (14, 24).

A

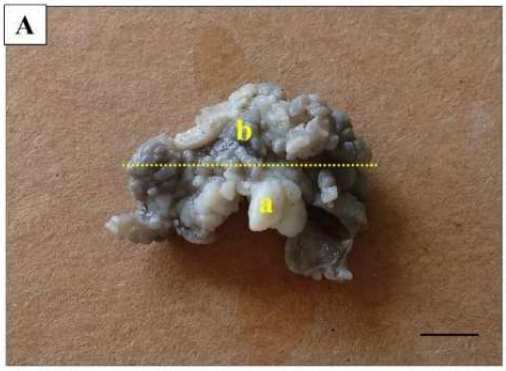

B

Size of Tumor		Score of Tumors			
		0	1	2	3
A	< 1cm	0	1 - 5	> 5	> 5
B	1 - 4cm	0	1 - 5	> 5	> 5
C	> 4 - 10cm	0	0	1 - 3	> 4
D	> 10cm	0	0	0	> 1

Work & Balazs, 1999

C

ID Turtles		
N°	CCC	Total Number of Tumors
1	47,5cm	27
2	38cm	34
3	35cm	29

D

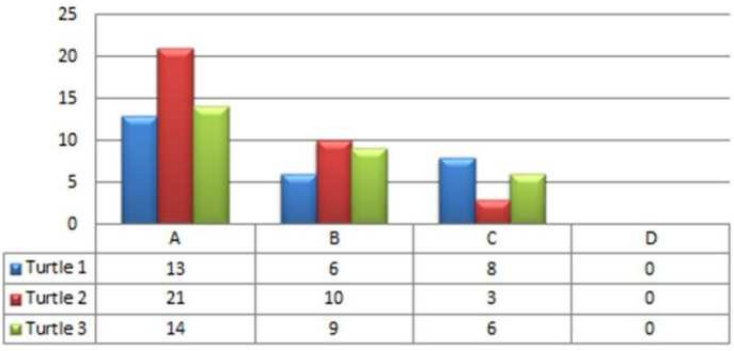

Figure 2. A. Scheme of a 4 cm fibropapilloma with a rough appearance with whitish color (a) and grayish color (b). **B.** Table obtained by Work &Balazs (1999) with the parameters to categorize fibropapillomas. **C.** Identification of 3 turtle specimens

Melo, et al.; **Structural description of sea turtle fibropapilloma.**
Braz J Vet Pathol, 2020, 13(3), 585 – 591
DOI: 10.24070/bjvp.1983-0246.v13i3p585-591

with their respective curved carapace length (CCC) and total number of tumors. **D.** Correlation of tumors according to quantity and size to classify the severity of fibropapillomatosis.

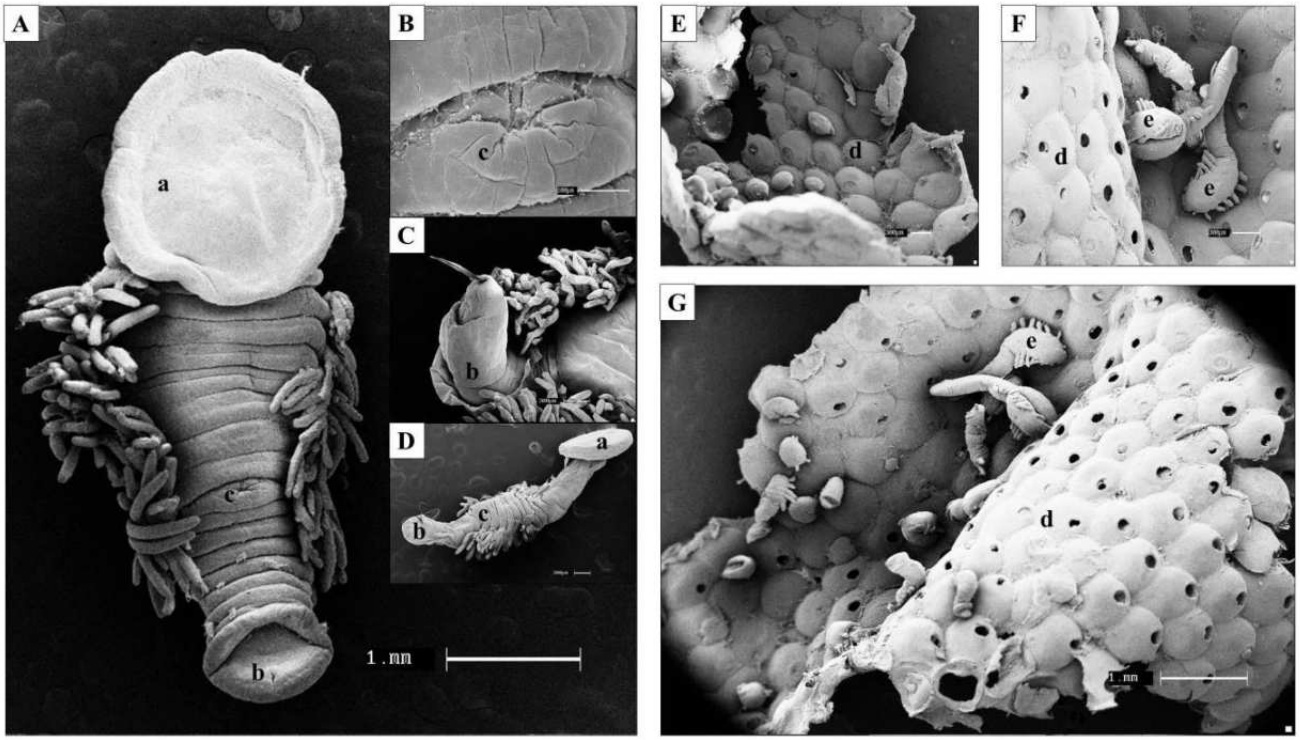

Figure 3. Photomicrography using scanning electron microscopy of the Ozobranchus in **A, B, C and D -** showing the segmented body of the ectoparasite, where at one end it has a large posterior suction cup (a), and at the other end a smaller anterior cup from which a proboscis (b) is projected in its region measured in the ventral view the anus (c) and laterally to its body the exposed gills. In **E, F and G -** images showing the egg colonies (d), where you can see the eggs hatching with new ectoparasites being born (e).

Microscopically, tumors associated with fibropapillomatosis are divided into three categories based on the predominant characteristics: papilloma, fibropapilloma and fibroma. Papillomas represent the initial stage of tumor development and consist mainly of proliferation of the epidermis. Fibroids are characterized by proliferation of the dermal matrix, often involving relatively mature collagenous tissue and represent the chronic phase of the three categories. Fibropapillomas show both changes, suggesting that it is an intermediate phase (16). According to this classification, together with microscopic analyzes, the tumors found were fibropapillomas (Fig. 4).

The tumors presented a hyperplastic stromal proliferation and epidermal proliferation, corroborating the findings of Cubas and collaborators (5), however in our results we observed hyperkeratosis, where in addition to the lining of the tumor mass due to keratin, it presented some invasions of the keratinocytes, thus allowing the keratin to grow inside the tumor forming large circular spirals, increasing the size of the fibropapillomas (Fig. 4), the stroma was highly vascularized, however keratin, being a dead and scaly protein, suggests a greater difficulty in tissue vascularization over time, due to the growth of keratin spirals, leading to tumor necrosis. Rhodes (27) describes the existence of necrotic tumors, thus inferring the possibility of tumor regression or tumor fall, as already evidenced by other authors.

The tumor cells had severe nuclear pleomorphism (Fig. 4), suggestive of virus infection, Cubas and collaborators (5) described these same nuclear changes in epithelial cells. It was possible to observe vacuolization of the cytoplasm and proliferation of fibrous tissue in the dense connective tissue around the keratin spirals (Fig. 4A), highly vascularized tissue (Fig. 4B), which contributes to metastasis, and the appearance of new tumors, corroborating with the findings of Schumacher (29) and Matushima (20). Greenblatt and collaborators (12) and Schumacher (29) described the presence of intracellular eosinophilic inclusions in epidermal cells, where in our findings it was possible to visualize degenerations with eosinophilic intranuclear inclusion bodies in the germinal epithelial tissue. Brito and collaborators (2) reported the

Melo, et al.; **Structural description of sea turtle fibropapilloma.**
Braz J Vet Pathol, 2020, 13(3), 585 – 591
DOI: 10.24070/bjvp.1983-0246.v13i3p585-591

occurrence of epithelial metaplasia, with a purulent inflammatory process associated with multiple fibropapillomas, which cannot be observed in our findings.

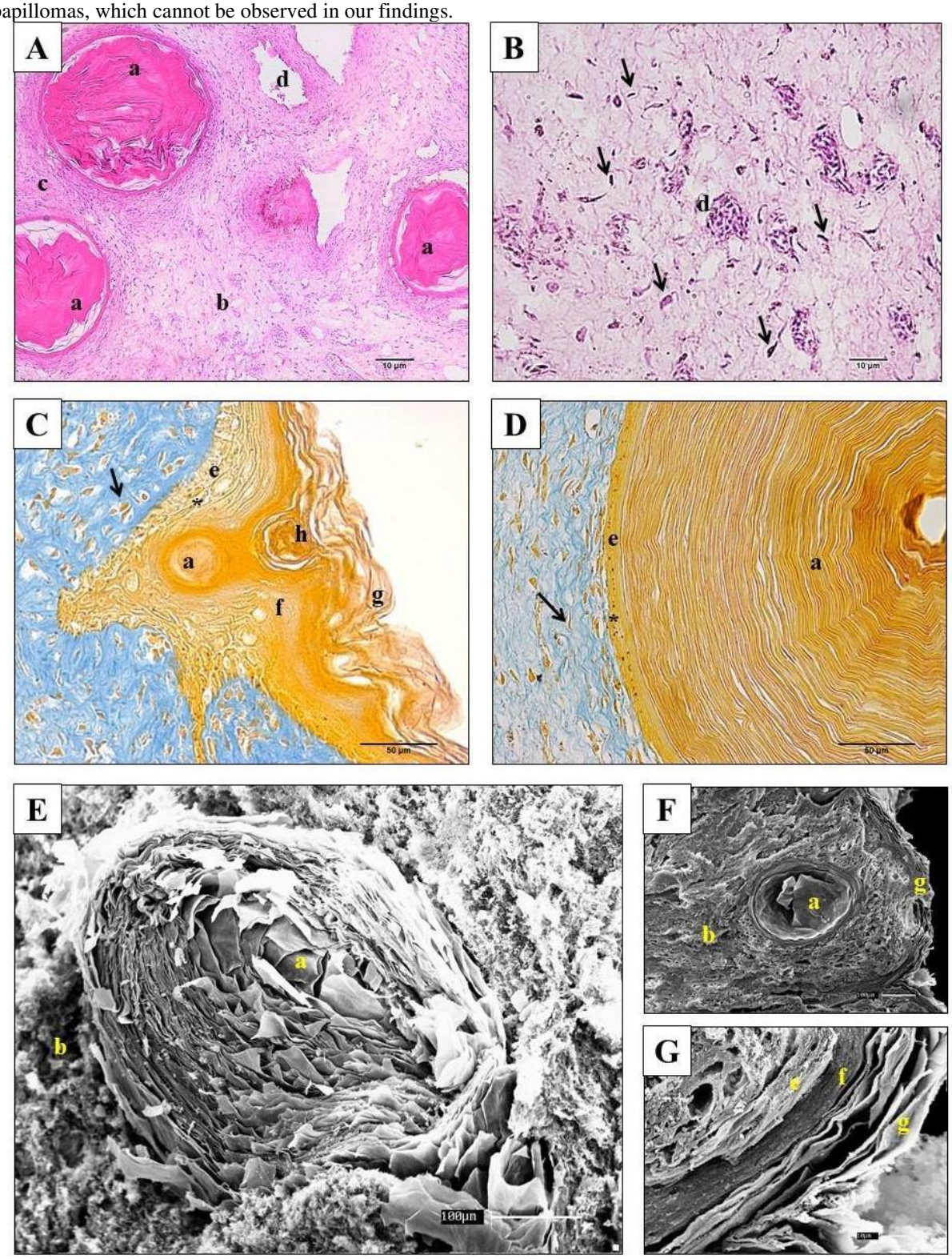

Figure 4. Photomicrograph of fibropapillomas showing stromal hyperplasia **B.** with the presence of fibroblasts **C.** that supports the pedunculated tumor with keratin spirals **A.** The stroma is highly vascularized **D.** the cells have severe nuclear pleomorphism (arrows), the tumor is coated with keratin **G.** and internally the germinal **E.** and spinous **F.** strata, where

keratinocytes are formed and mature, respectively. In the germinative stratum, it is possible to see eosinophilic intranuclear inclusion bodies (*). Images A and B were stained with HE and analyzed using a 10x and 40x objective, respectively. Images C and D were stained with mallory trichromatic and both were analyzed using a 20x objective. The images E, F and G were analyzed using scanning electron microscopy.

Conclusion

In this study we suggest that the formation of fibropapillomas was worsened with the presence of ectoparasites. We found in the studied samples fibropapillomatosis with hyperplastic stromal proliferation and epidermal proliferation with hyperkeratosis, coated with keratin, with some keratinocyte invaginations, thus allowing the keratin to grow inside the tumor forming large circular spirals, increasing the size of the fibropapilloma. This amount of dead tissue (keratin) within the fibropapilloma suggests the death of the tumor and its detachment, suggesting natural defense of the body.

Acknowledgments

We thank CAPES for the financial support.

Conflict of Interest

The authors declare that there is no conflict of interest.

References

1. Aguirre AA, Lutz PL. Marine turtles as sentinels of ecosystem health: is fibropapillomatosis an indicator? EcoHealth. 2004;1(3):275-83.
2. Brito FLC, Maia FCL, de França LMO, Albuquerque AR, Santos RAM, Cavalcanti MAM, Guimarães ESG. Fibropapillomatosis and multiple fribromas in a Green turtle from the South Cost of Pernambuco State, Brazil. Marine Turtle Newsletter. 2004;106:12.
3. Bunkley-Williams L, Williams Jr EH, Horrocks JA, Horta HC, Mignucci-Giannoni AA, Poponi AC. New leeches and diseases for the hawksbill sea turtle and the West Indies. Comp Parasitol. 2008;75(2):263-70.
4. Christoffersen ML. A catalogue of the Piscicolidae, Ozobranchidae, and Arhynchobdellida (Annelida, Clitellata, Hirudinea) from South America. Neotrop Biol Conserv. 2008;3(1):39-48.
5. Cubas PH, Baptistotte C. *Chelonia* (tartaruga, cágado, jabuti). In: Cubas ZS, Silva JCR, Catão-Dias JL, editors. Tratado de animais selvagens. São Paulo: Roca; 2007. p.108-10.
6. Curry SS, Brown DR, Gaskin JM, Jacobson ER, Ehrart LM, Blahak S, Hernbst LH, Kelin PA. Persistent Infectivity of a Disease-Associated Herpesvirus in Green Turtle after Exposure to Seawater. J Wildl Dis. 2000;36(4):792-7.
7. Davies RW, Chapman CG. First record from North America of the piscicolid leech, *Ozobranchus margoi*, a parasite of marine turtles. J Fish Res Board Can 1974;31(1):104-6.
8. Deem SL, Karesh WB, Weisman W. Putting theory into practice: wildlife health in conservation. Conservation Biology. 2001;15(5):1224-33.
9. Eckert LK, Bjorndal AK, Grobois FA, Donnelly M. Técnicas de investigación y manejo para la conservación de las tortugas marinas, grupo especialista en tortugas marinas. Pennsylvania: UICN/CSE, v.4; 2000. 270p.
10. Ene M, Su S, Lemaire C, Rose S, Schaff R, Moretti J, Lenz L, Herbst H. Distribution of chelonid fibropapillomatosis associated herpesvirus variants in Florida: molecular genetic evidence for infection of turtles following recruitment to neritic developmental habitats. J Wildl Dis. 2005;41(3):489-97.
11. Ernst CH, Barbour RW. Turtles of the World. Washington, D.C./London: Smithsonian Institution Press; 1989. [i]-xii, 1-313.
12. Greenblatt RJ, Quackenbush SL, Casey RN, Rovnak J, Balazs GH, Work TM, Casey JW, Suton CA. Genomic variation of the fibropapilloma-associated marine turtle herpesvirus across seven geographic areas and three host species. J Virol. 2005;79:1125-32.
13. Greenblatt RJ, Work TM, Balazs GH, Sutton CA, Casey RN, Casey JW. The *Ozobranchus leech* is a candidate mechanical vector for the fibropapilloma-associated turtle herpesvirus found latently infecting skin tumors on Hawaiian green turtles (*Chelonia mydas*). Virology. 2004;321:101-10.
14. Herbst LH, Jacobson ER, Klein PA, Balazs GH, Moretti R, Brown T, Sundberg JP. Comparative pathology and pathogenesis of spontaneous and experimentally induced fibropapillomas of green turtles (*Chelonia mydas*). Vet Pathol. 1998;36:551-64.
15. Herbst LH, Jacobson ER, Moretti R, Brown T, Sundberg JP, Klein JP. Experimental transmition of green turtle fibropapillomatosis using cells tumor extracts. Dis Aquat Organ. 1995;22(1):1-12.
16. Kang KI, Torres-Velez FJ, Zhang J, Moore PA, Morre PD, Rivera S, Brown CC. Localization of fibropapilloma-associated turtle herpesvirus in green turtle (*Chelonia mydas*) by in-situ hybridization. J Comp Pathol. 2008;139:218-25.
17. Lackovich JK, Brown DR, Homer BL, Garber RL, Mader DR, Moretti RH, Patterson AD, Herbst LH, Oros J, Jacobson ER, Curry SS, Klein PA. Association of herpesvirus with fibropapillomatosis of the green turtle *Chelonia mydas* and the loggerhead turtle *Caretta caretta* in Florida. Dis Aquat Organ. 1999;37(2):89-97.
18. Limpus CJ, Limpus DJ, Arthur KE, Parmenter CJ. Monitoring of green turtle population dynamics in Shoalwater Bay: 2000–2004. Research Publication n. 83,

Great Barrier Reef Marine Park Authority Research Publication Series, Townsville. 2005.

19. Lu YA, Wang Y, Aguirre AA, Zhao ZS, Liu CY, Nerurkar VR, Yanagihara R. RT-PCR detection of the expression of the polymerase gene of a novel reptilian herpesvirus in tumor tissues of green turtles with fibropapilloma. Arch Virol. 2003;148:1155-63.

20. Matushima ER. Fibropapillomas in sea turtles: histological, immunohistochemical and ultrastructural aspects. Sao Paulo-SP [thesis]. [São Paulo]: University of São Paulo; 2003. 113p.

21. Matushima ER, Longatto Filho A, Loretto CD, Kanamura CT, Sinhorini IL, Gallo B, Baptistolle C. Cutaneous papillomas of green turtles: a morphological, ultrastructural and immunohistochemical study in Brazilian specimens. Braz J Vet Res Anim Sci. 2001;38(2):51-4.

22. Melo LF, Rodrigues ACB, Cabrera ML, Turquetti AOM, Ruivo LP, Azarias GR, Lopes EQ, Rici REG. Analysis Of The Green Turtle Esophagus *Chelonia mydas* (Linnaeus, 1758), Testudines, Cheloniidae. Int J Morphol. 2019; 37(4):1391-6.

23. Moreira LMP, Baptistotte C, Scalfoni J, Thomé JC, Almeida APLS. Occurrence of *Chelonia mydas* on the island of Trindade, Brazil. Marine Turtle Newsletter. 1995;70:2.

24. Norton TM, Jacobson ER, Sundberg JP. Cutaneous fibropapillomas and renal myxofibroma in a green turtle, Chelonia mydas. J Wild Dis. 1990;26:265–70.

25. Quackenbush SL, Work TM, Balazs GH, Casey RN, Rovnak J, Chaves A, Dutoit L, Baines JD, Parrish CR, Bowser PR, Casey JW. Three closely related herpesviruses are associated with fibropapillomatosis in marine turtles. Virology. 1998;246(2):392-9.

26. Quackenbush SL, Casey RN, Murcek RJ, Paul TA, Work TM, Limpus CJ, Chaves A, duToit L, Perez JV, Aguirre AA, Spraker TR, Horrocks JA, Vermeer LA, Balazs GH, Casey JW. Quantitative analysis of herpesvirus sequences from normal tissue and fibropapillomas of marine turtles with real-time PCR. Virology. 2001;287(1):105-11.

27. Rhodes KH. Dermatologia de Pequenos Animais Consulta em 5 minutos. Rio de Janeiro: Revinter; 2005. 722p.

28. Rossi S. Study of the impact of fibropapillomatosis on Chelonia mydas Linnaeus, 1758 (Testudines, Cheloniidae) [dissertation]. [São Paulo]: University of São Paulo; 2007. 104p.

29. Schumacher J. Viral diseases. In: Mader DR, editor. Reptile Medicine and Surgery. 2nd ed. London: Saunders Company; 1996. p.224-34.

30. Schwartz FJ. The marine leech *Ozobranchus margoi* (Hirudinea: Pisciocolidae) epizootic on Chelonia and Caretta sea turtles from North Carolina. J Parasitol. 1974;60(5):889-90.

31. Work TM, Balazs GH. Relating Tumor Score to Hematology in Green Turtle with Fibropapillomatosis in Hawaii. J Wild Dis. 1999;35(4):804-7.