Braz J Vet Pathol, 2020, 13(3), 597 – 601
DOI: 10.24070/bjvp.1983-0246.v13i3p597-601

BJVP
Brazilian Journal of Veterinary Pathology
ISSN 1983-0246

Case Report

Cutaneous myofibroblastic fibrosarcoma in a margay (*Leopardus wiedii*): a case report

Raúl Bermúdez-Salas[1], Natalia Campos[1], Daniel Barrantes[1], Randall Arguedas[2], Alejandro Alfaro-Alarcón[1*]

[1]Department of Veterinary Pathology, School of Veterinary Medicine, National University of Costa Rica. Lagunilla, Ulloa, Heredia, 40104, Costa Rica.
[2]Simón Bolívar Zoo. 11 Avenue, San José, San José, 10101, Costa Rica.
[*]**Corresponding author:** E-mail: alejandro.alfaro.alarcón@ac.una.cr

Submitted October, 12th 2019, Accepted August, 24th 2020

Abstract

A routine check-up was performed on a captive 14-year-old female margay (*Leopardus wiedii*), a cutaneous mass was detected on the ventral thorax. The mass was surgically removed and sent for histopathological analysis. Histologically, the mass was a poorly-demarcated, highly cellular, infiltrative and unencapsulated mesenchymal neoplasm. Immunohistochemical labeling for smooth muscle actin and vimentin were positive, while desmin and cytokeratin were negative which is consistent with a myofibroblastic fibrosarcoma. This type of tumor has been diagnosed in wild felines, however this seems to be the first report of its occurrence in this *L. wiedii*. Wildlife oncology studies should be performed to promote our understanding of cancer in a species.

Key words: *Leopardus wiedii*, Margay, myofibroblastic fibrosarcoma, vimentin, smooth muscle actin, neoplasia.

Introduction

The margay (*Leopardus weidii*) is one of the six wild feline species found in Costa Rica (2). This felid has a wide geographical distribution and is found from southern Texas (United States) to northern Argentina and Uruguay. It can be more strongly associated with forest habitats (both evergreen and deciduous) than any other tropical American wild cat (1, 4, 10).

L. weidii is mostly nocturnal and its diet consists mainly of small mammals. Although other felids can prey on arboreal mammals, like the ocelot or big cats, only the margay has anatomical adaptations that allow it to move about in trees. For instance, its proportionally longer tail, large claws, and the ability of the hind feet to rotate 180° allows it to descend trees head first (1, 4).

Margays are listed in Appendix I of the Convention on International Trade of Endangered Species of Wild Fauna and Flora (CITES) since 1990. This species is protected across most of its range, with hunting and trade prohibited in many countries including Costa Rica. *L. weidii* has been listed as Near Threatened on the IUCN Red List since 2008 (2, 5, 10).

L. Wiedii has been known to live up to 24 years in captivity (10). An increasing number of elderly non-domestic felines in Zoos has resulted in the documentation of several diseases, including neoplastic processes (15). Cancer is an important cause of morbidity and mortality in several wildlife species (13). Wildlife oncologic studies may improve the understanding of cancer biology and comparative pathology (13, 16).

Domestic cats and wild felids are susceptible to many of the same neoplasm types, such as squamous cell carcinomas and mammary carcinomas. Tumors have been described mainly in captive animals (12, 16, 17). In margays specifically, there have been only two neoplasm case reports: a cholangiocellular carcinoma and a vaginal leiomyoma (9, 14).

 All rights reserved 2007.

Braz J Vet Pathol, 2020, 13(3), 597 – 601
DOI: 10.24070/bjvp.1983-0246.v13i3p597-601

Case Report

A check-up was performed on a 14-year-old female margay (4.65 kg) kept in captivity at the Simón Bolívar Zoo in San José, Costa Rica as it presented hyporexia and depression. A 5 x 5 cm cutaneous mass was detected on the ventral thorax. Blood samples for hematological studies were taken and a fine needle aspirate of the mass was performed. The ~~hematogy~~hematology revealed transitory ~~erythocytosis~~erythrocytosis, mild inflammation with associated neutropenia, and mild hypocalcemia. A mesenchymal neoplasia of fibroblastic origin was diagnosed. After surgical excision, the mass was fixated in 10% buffered formalin and sent for routine histopathological analysis at the Pathology Laboratory of National University in Heredia, Costa Rica.

On gross examination the mass was 9 x 5 x 4.5 cm, alopecic, non-pedunculated and diffusely ulcerated. At the cut surface it was well-circumscribed, white, non-encapsulated with an infiltrative growth pattern which extended to the subcutis and muscular layer.

Histologically, the mass was poorly-demarcated, densely cellular, infiltrative and unencapsulated mesenchymal neoplasm extending from the dermis and involving the subcutaneous tissue and muscular layer. Neoplastic tissue was closely packed in bundles and interlacing bands with scant amount of fine fibrous stroma. The neoplastic cells were spindle-shaped with indistinct cell borders. Cytoplasm was moderate, eosinophilic, and finely fibrillar. The nuclei were oval, paracentraly located with finely stippled chromatin and single-to-multiple basophilic nucleoli (Fig. 1). Mitotic count was 1-3 per 400X field. Multifocally, multinucleated giant cells were observed.

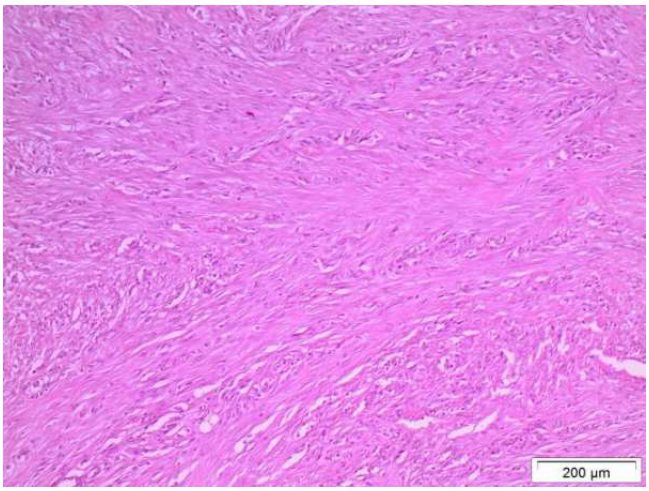

Figure 1. Histological appearance of the myofibroblastic fibrosarcoma. The mass is composed of spindle-shaped cells proliferating in highly cohesive sheets and interlacing bands with sparce amount of fine fibrovascular stroma (H&E).

The neoplastic tissue under Masson's trichrome stain showed moderate amounts of collagen fibers (Fig. 2). Immunohistochemical (IHC) assays of the mass were done for desmin (Mouse anti-human monoclonal desmin, 1:200, Dako), cytokeratin (Mouse anti-human monoclonal multi-cytokeratin, 1:200, Leica) smooth-muscle actin (Mouse anti-human monoclonal smooth muscle actin, 1:200, Dako) and vimentin (Mouse anti-human monoclonal Anti-Vimentin, 1:200, Dako). Strong positive cytoplasmatic immunostaining was observed for vimentin (Fig. 4) and smooth muscle actin (Fig. 5), and no immunoreactivity was detected for cytokeratin (CKs) (Fig. 3) and desmin (Fig. 6). On the bases of its morphological features, and immunostaining assays results, a diagnosis of myofibroblastic fibrosarcoma was made.

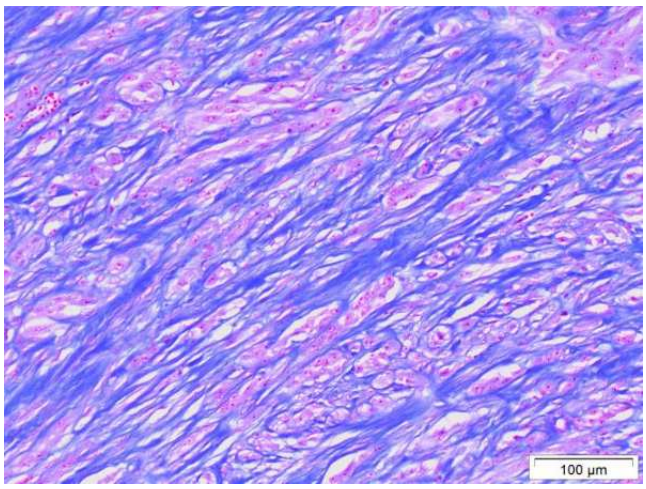

Figure 2. Myofibroblastic fibrosarcoma. Neoplastic tissue shows a positive Masson's trichome stain for collagen stroma.

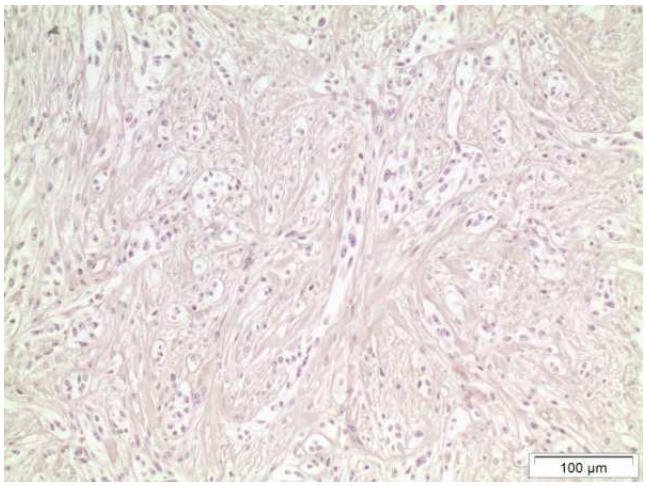

Figure 3. Myofibroblastic fibrosarcoma. Neoplastic fibroblasts immunonegative reaction for cytokeratin. Murine monoclonal anti-cytokeratin antibody.

Braz J Vet Pathol, 2020, 13(3), 597 – 601
DOI: 10.24070/bjvp.1983-0246.v13i3p597-601

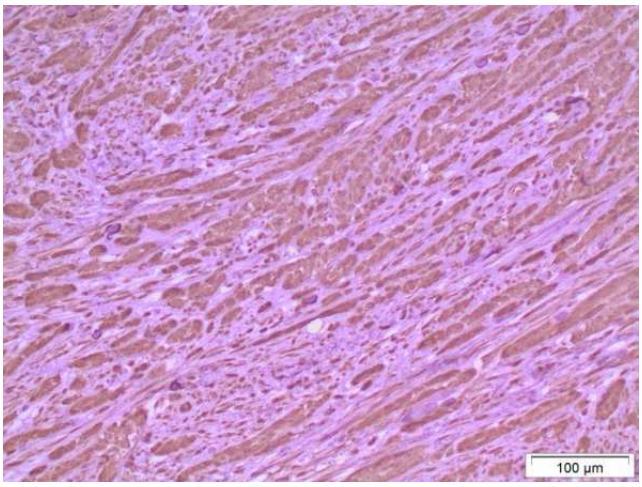

Figura 4. Histologic section of myofibrosarcoma from a female intact Margay. Spindle cells exhibit strong diffuse intracytoplasmic expression of vimentin. Murine monoclonal anti-vimentin antibody.

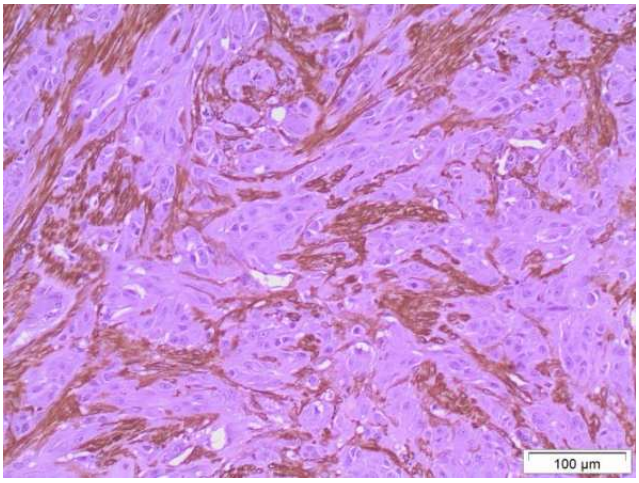

Figure 5. Myofibrosarcoma, immunohistochemistry for smooth muscle actin. Some malignant cells exhibit a strong multifocal intracytoplasmic precipitate. Murine monoclonal anti-smooth muscle actin antibody.

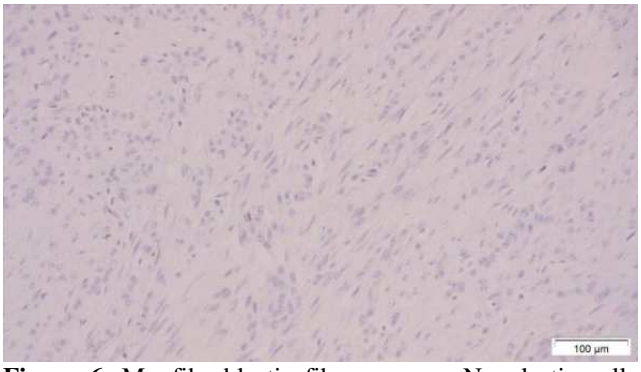

Figure 6. Myofibroblastic fibrosarcoma. Neoplastic cells immunohistological negativity for desmin. Murine monoclonal anti-desmin antibody.

Discussion

Fibrosarcomas are soft tissues sarcomas originated from fibroblasts, with no evidence of other cellular differentiation. This malignant mesenchymal tumor is well described in dogs and ~~cats, and~~cats and is the most common tumor in domestic felines (7, 11, 12). Three forms of fibrosarcoma have been described in domestic cats: virus-induced, solitary in older cats, and post-vaccinal fibrosarcomas (12). Variants recognized include fibrosarcoma of follicular papillary origin, keloidal fibrosarcoma, and myofibroblastic sarcoma (11).

In this case, neoplastic tissue had presence of marked cellular dysplasia, a collagen matrix, and multinucleate giant cells in some areas. Collagen presence was confirmed by Masson trichrome stain (7, 11). This type of tumor is over-diagnosed because any highly anaplastic sarcoma containing collagen is diagnosed as a fibrosarcoma when more specific histogenesis is not apparent (12).

IHC has become an important and routine diagnostic technique. It´s use allows differentiating fibrosarcomas from other fusiform cell tumors like peripheral nervous band cell tumors, leiomyosarcoma, rhabdomyosarcoma, amelanotic melanoma, among others (3, 7, 11, 12). In this case labeling for cytokeratin, desmin, smooth-muscle actin and vimentin was done.

Different cell types possess different types of cytoskeletal intermediate filaments (IF) proteins, which are one of the main cytoskeletal systems found in virtually all vertebrate cells. Those IF markers are employed to differentiate neoplasms of epithelial and mesenchymal origin (6, 7, 15).

Cytokeratins (CKs) are IF cytoskeleton proteins expressed, mainly, by epithelial cells (6). In this case no immunoreactivity was observed for CKs. Moreover, positive immunolabeling for vimentin and smooth-muscle actin was noted.

Vimentin is another IF protein which is detected in mesenchymal cells, including early developing muscle (6, 12). As mesenchymal cells, the neoplastic fibroblasts and myocytes retain their expression of vimentin (3, 10, 12). Most of the cells showed strong vimentin immunoreactivity, which was diffusely distributed within the cytoplasm.

Actins are one of the more characteristic cytoplasmic markers of myogenic differentiation (7). Smooth-muscle actin immunohistological positivity reveals myogenic components in this tumor. In this tumor actin was observed as a strong multifocal intracytoplasmic precipitate.

Due to the positive immunostaining for smooth-muscle actin and vimentin, two different sarcomas were considered, leiomyosarcoma and myofibroblastic fibrosarcoma (7, 12).

Desmin IHC analysis was done to clarify the neoplasms ~~origen~~origin. This marker is an IF protein

strongly expressed by muscle cells (7, 12). In this case no immunoreactivity was negative. The diagnosis of myofibroblastic fibrosarcoma was confirmed based on this immunohistochemistry panel results.

The smooth-muscle actin expression indicates myofibroblastic differentiation. Myofibroblasts are mesenchymal spindle cells that produce collagen and have capacity for contraction. These cells are important in wound healing, usually associated with granulation tissue secondary to trauma. However, no correlation has been proven in most cases of canine and feline myofibroblastic fibrosarcoma (3, 11).

Tumors of myofibroblasts have been referred to as: myofibroblastic sarcoma, myofibrosarcoma, or myofibroblastic fibrosarcoma. Myofibrosarcomas cells may be larger, more pleomorphic, and haphazardly arranged. The mitotic rate varies markedly (11).

There is not many specific information regarding the behavior of canine and feline myofibroblastic fibrosarcoma. Nevertheless, most soft tissue sarcomas exhibit similar behavior and prognosis. The fibrosarcomas are typically locally invasive and commonly recur within a period of weeks to months after surgical excision, but metastasis is uncommon. Surgery remains the treatment of choice. Nevertheless, the apparent tumor circumscription commonly results in incomplete excision. Wide surgical excision is recommended because adequacy of excision is prognostic (7, 11, 12).

Although fibrosarcomas have been diagnosed in wild felines (8, 16), this seems to be the first report in *Leopardus weidii*.

Conclusions

The use of special histological stains and immunohistochemical characterization is necessary in order to accurately differentiate between certain types of neoplasia.

Disease monitoring of captive animals reveals a wide range of spontaneous neoplasia across vertebrates. Neoplasia reports on *L. weidii* are scarce. This study reveals this type of tumor in this species for the first time. Wildlife oncologic studies, primarily those in zoos, should be made to better understand cancer in those species and establish epidemiological links.

Acknowledgements

The authors thank Dr. Luis Enrique Carazo Arias, DMV, IMMResearch, for the technical contributions in the development of this study.

References

1. Bianchi R, Rosa AF, Gatti A, Mendes SL. Diet of margay, *Leopardus wiedii*, and jaguarundi, *Puma yagouaroundi*, (Carnivora: Felidae) in Atlantic Rainforest, Brazil. Zoologia (Curitiba). 2011;28(1):127-32.
2. Blanco K, Peña R, Hernández C, Jiménez M, Araya LN, Romero JJ, Dolz G. Serological detection of viral infections in captive wild cats from Costa Rica. Vet Med Int. 2011;
3. Couto SS, Griffey SM, Duarte PC, Madewell BR. Feline Vaccine-associated fibrosarcoma: Morphologic Distinctions. Vet Path. 2002;39(1):33-41.
4. de Oliveira TG. Mammalian Species: *Leopardus wiedii.* Am Soc Mamm. 1998;579:1-6.
5. de Oliveira T, Paviolo A, Schipper J, Bianchi R, Payan E, Carvajal SV. *Leopardus wiedii*, Margay. The IUCN Red List of Threatened Species. 2015:e.T11511A50654216.
6. Eriksson JE, Dechat T, Grin B, Helfand B, Mendez M, Pallari H-M, Goldman RD. Introducing intermediate filaments: from discovery to disease. J Clin Invest. 2009;119(7):1763-71.
7. Hendrick MJ. Mesenchymal Tumors of the Skin and Soft Tissues. In: Meuten, D, editor. Tumors in Domestic Animals. 5th ed. California: Wiley-Blackwell, USA; 2017. p.142-75.
8. Kloft HM, Ramsay EC, Sula MM. Neoplasia in Captive Panthera Species. J Comp Pathol. 2019;166:35-44.
9. Kollias GV, Goring RL, Hager DA, Stampley A, Heard D. Urethral incarceration and colonic obstruction caused by vaginal leiomyoma in a margay. J Am Vet Med Assoc. 1986;189(9):1207-8.
10. Lamberski, N. Felidae in: Miller, ER, Fowler, ME, editors. Fowler`s Zoo and Wild Animal Medicine. Vol. 8. St. Louis: Elsevier-Saunders; 2014. p.467-75.
11. Lee-Gross T, Ihrke PJ, Walder EJ, Affolter VK. Fibrous tumors. In: Lee-Gross T, Ihrke PJ, Walder EJ, Affolter VK, editors. Skin Diseases of The Dog and Cat: Clinical and Histopathologic Diagnosis. 2nd ed. Oxford: Blackwell Science. 2005. p.710-34.
12. Mauldin EA, Peters-Kennedy J. Integumentary System. In: Maxie MG, editor. Jubb, Kennedy and Palmer's Pathology of Domestic Animals. Vol 1. 6th ed. Philadelphia: Saunders; 2016. p.511-736.
13. McAloose D, Newton AL. Wildlife cancer: a conservation perspective. Nat Rev Cancer. 2009;9(7):517-26.
14. McClure HM, Chang J, Golarz MN. Cholangiocarcinoma in a margay (*Felis wiedii*). Vet Path. 1977;14(5):510-2.
15. Nakagaki KYR, Lima P, Utiumi K, Pires MAM, Zanatta R, Boabaid FM, Colodel EM, Raymundo DL. Transitional cell carcinoma of urinary bladder with metastasis in lumbar vertebrae and spinal cord compression in an ocelot (*Leopardus pardalis*). Pesq Vet Bras. 2015;35(1):75-9.
16. Norton B, Tunseth D, Holder K, Briggs M, C. Hayek LA, Murray S. Causes of morbidity in captive African

Braz J Vet Pathol, 2020, 13(3), 597 – 601
DOI: 10.24070/bjvp.1983-0246.v13i3p597-601

lions (*Panthera leo*) in North America, 2001-2016. Zoo Biol. 2018;37(5):354-9.

17. Terio. KA, McAloose D, Mitchell E. Felidae in: Terio. KA, McAloose D, St Leger, J, editors. Pathology of Wildlife and Zoo Animals. London: Academic Press-Elsevier; 2018. p.263-86.

Brazilian Journal of Veterinary Pathology. www.bjvp.org.br . All rights reserved 2007.