Braz J Vet Pathol, 2020, 13(3), 615 – 618
DOI: 10.24070/bjvp.1983-0246.v13i3p615-618

BJVP
Brazilian Journal of Veterinary Pathology
ISSN 1983-0246

Case Report

Uterine leiomyosarcoma with secondary acute hemoabdomen in a goat

Daniel R. Rissi[1*]& Nicole M. Nemeth[2]

[1]Athens Veterinary Diagnostic Laboratory, Department of Pathology, University of Georgia College of Veterinary Medicine, Athens, GA, USA;
[2]Southeastern Cooperative Wildlife Disease Study, Departments of Pathology and Population Health, University of Georgia College of Veterinary Medicine, Athens, GA, USA.
[*]**Corresponding author:** Dr. Daniel R. Rissi, Athens Veterinary Diagnostic Laboratory, Department of Pathology, University of Georgia College of Veterinary Medicine, Athens, GA 30602, phone 706 542 5916. E-mail: rissi@uga.edu.

Submitted June, 15th 2020, Accepted August, 11th 2020

Abstract

Neoplasms of the reproductive tract are uncommonly reported in goats. Here we describe a case of sudden death caused by acute hemoabdomen due to a ruptured uterine leiomyosarcoma in a 7-year-old female mixed breed goat. Gross changes included oral and ocular pallor, as well as 3 liters of blood and blood clots in the abdominal cavity. The uterine body wall was irregularly thickened and firm, and had a 2 cm in diameter, transmural perforation. The uterine lumen was filled with dark red to brown blood clots admixed with friable necrotic material. Histologically, a poorly-demarcated neoplasm expanded and effaced the uterine wall. The neoplasm consisted of densely packed bundles and streams of elongate neoplastic cells with moderate pleomorphism and abundant eosinophilic cytoplasm and elongate nuclei with coarsely stippled chromatin. The mitotic count was 4 per 2.37 mm^2. Multiple areas of necrosis and clusters of lymphocytes and plasma cells were present throughout the neoplasm. Neoplastic cells exhibited diffuse immunolabeling for smooth muscle actin and patchy immunolabeling for desmin, consistent with a uterine leiomyosarcoma.

Key words: uterus, leiomyosarcoma, goat, reproductive pathology.

Introduction

Neoplasms of the reproductive tract are uncommonly reported in goats, with most of these affecting the uterus and less often the cervix, ovaries, vagina, and vulva of adult to aged individuals (4). Uterine neoplasms arising from the myometrium consist mainly of leiomyomas and leiomyosarcomas (3, 6, 7, 8, 10). Adenocarcinomas arising from the endometrial glands are less frequently reported (3, 5, 6). Goats affected by uterine neoplasms exhibit clinical signs that can be directly associated with the tumors, such as vaginal discharge or bleeding, or more insidious clinical signs, such as hydrometra, infertility, and decrease in production (4). Ultimately, advanced neoplasms can lead to death. Here we describe a case of sudden death caused by acute hemoabdomen resulting from a ruptured uterine leiomyosarcoma in a goat.

Case Report

A 7-year-old female mixed breed goat died suddenly while eating and was submitted for autopsy. Grossly, the oral and ocular mucosae were markedly pale white. Approximately 3 liters of blood and blood clots filled and distended the abdominal cavity (Fig. 1). The uterine body wall was diffusely and irregularly thickened and firm. The blood clot was attached to a focal, 2 cm in diameter transmural rupture in the uterine wall (Fig. 2). The uterine lumen was filled with dark red to brown blood clots admixed with friable necrotic material (Fig. 3). The two uterine horns and ovaries were intact and had no pathological changes. No significant changes were

 All rights reserved 2007.

Braz J Vet Pathol, 2020, 13(3), 615 – 618
DOI: 10.24070/bjvp.1983-0246.v13i3p615-618

observed in other organs. Routine tissue samples, including uterus, ovary, regional lymph node, lung, heart, thyroid and parathyroid gland, liver, spleen, gastrointestinal tract, kidney, urinary bladder, adrenal gland, and brain were collected, immersed in 10% buffered formalin, routinely processed for histology, and stained with hematoxylin and eosin.



Figure 1. Leiomyosarcoma, uterus, goat. Multiple blood clots cover the omental surface.

Histological changes were restricted to the uterus. A poorly-demarcated neoplasm expanded and effaced most of the uterine wall. The neoplasm consisted of densely packed bundles and streams of elongate cells supported by a scant fibrous connective tissue stroma (Fig. 4). Neoplastic cells had moderate pleomorphism and abundant, eosinophilic, homogeneous to fibrillar cytoplasm with indistinct cell borders. Nuclei were oval to elongate and had coarsely stippled chromatin and indistinct nucleoli. There was moderate anisokaryosis with areas of karyomegaly. The mitotic count was 4 per 2.37 mm^2. Multiple areas of necrosis, as well as clusters of lymphocytes and plasma cells were present throughout the neoplasm. The ruptured area in the uterine wall was surrounded by fibrin, hemorrhage, and a few neutrophils.

Immunohistochemistry (IHC) for smooth muscle actin (SMA; mouse monoclonal antibody, 1:5000 dilution for 60 minutes; Dako, Santa Clara, CA), desmin (mouse monoclonal antibody, 1:10 dilution for 90 minutes; Biocare, Pacheco, CA), and S-100 (mouse monoclonal antibody, ready to use dilution for 30 minutes; Cell Marque, Rocklin, CA) was performed for diagnostic confirmation. Neoplastic cells had widespread, robust cytoplasmic immunolabeling for SMA (Fig. 5) and patchy immunolabeling for desmin (Fig. 6). No immunolabeling for S-100 was observed.

Discussion

The pathological changes and IHC features in the current case were consistent with sudden death caused by acute hemoabdomen secondary to a ruptured uterine wall leiomyosarcoma. No evidence of metastasis was found in the multiple tissues examined.

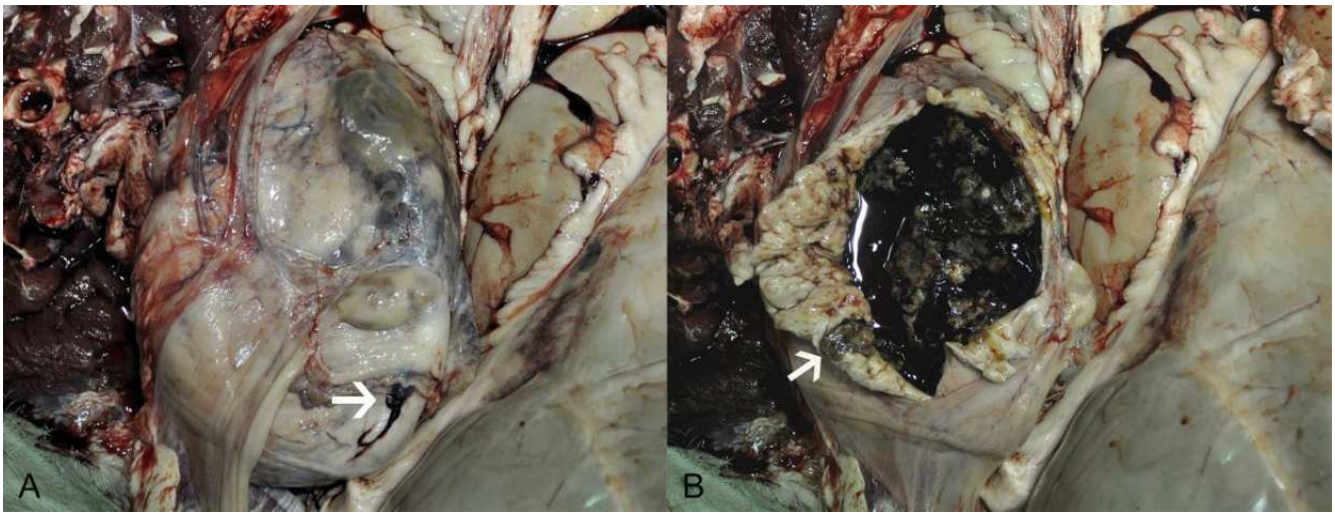

Figure 2. Leiomyosarcoma, uterus, goat. A. The uterine body is enlarged and irregular. **A.** blood clot (arrow) is attached to a focal ruptured area in the myometrium. **B.** The uterine lumen is filled with dark red to brown blood clots admixed with friable necrotic material. The site of uterine wall rupture is shown by the arrow.

Braz J Vet Pathol, 2020, 13(3), 615 – 618
DOI: 10.24070/bjvp.1983-0246.v13i3p615-618

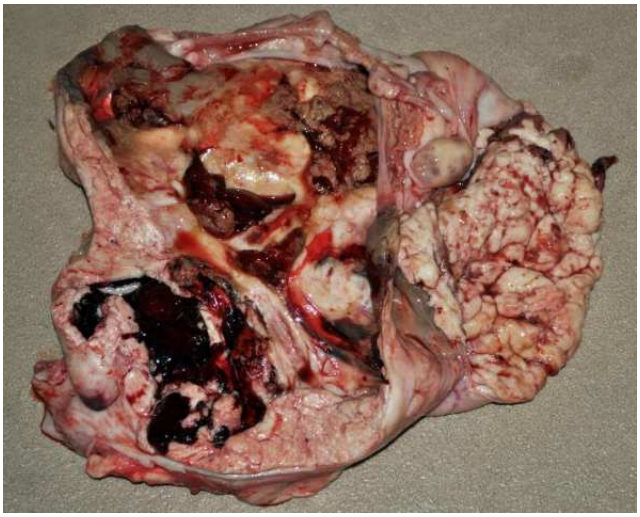

Figure 3. Leiomyosarcoma, uterus, goat. The uterine wall is diffusely thickened due to infiltration by the neoplasm.

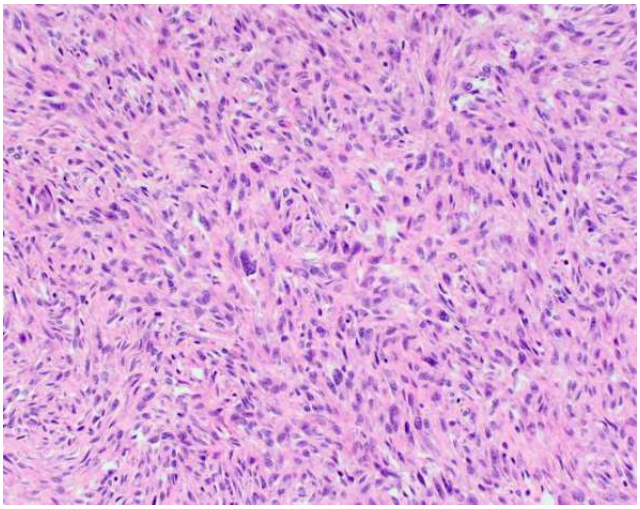

Figure 4. Leiomyosarcoma, uterus, goat. Densely packed bundles and streams of elongate neoplastic cells with eosinophilic cytoplasm and round to oval nuclei (20x, H&E).

Uterine leiomyomas and leiomyosarcomas of the reproductive tract of goats are uncommon (3, 6, 7, 10). Leiomyomas are more frequently reported than leiomyosarcomas and typically consist of well demarcated and well differentiated neoplasms (1, 4). In contrast, leiomyosarcomas are locally invasive tumors. Metastases can occur but have not been reported for uterine leiomyosarcomas in goats (2, 4). The tumor in the current report diffusely expanded the myometrium of the uterine body, but metastases were absent. Histological differentiation between leiomyoma and leiomyosarcoma should be made based on increased cell and nuclear pleomorphism and mitotic activity, as well as the presence of necrosis, which are features typically seen in leiomyosarcoma (1). In this case, IHC for SMA and desmin was useful to confirm a diagnosis of a smooth muscle neoplasm, as well as to differentiate it from a uterine fibrosarcoma (1).

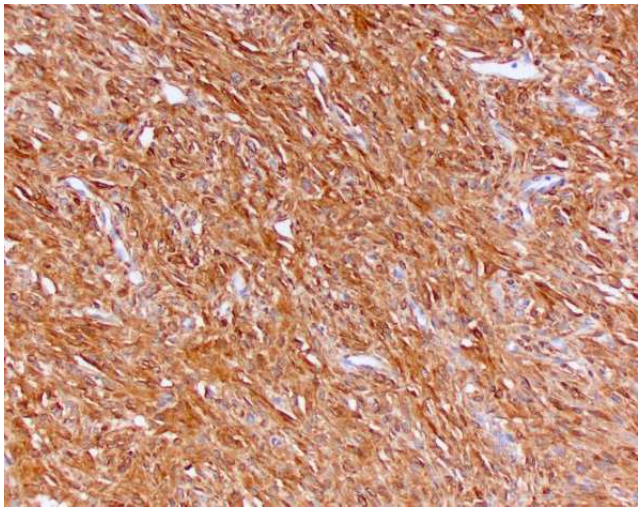

Figure 5. Leiomyosarcoma, uterus, goat. Neoplastic cells have widespread, robust cytoplasmic immunolabeling for smooth muscle actin (20x, immunohistochemistry for smooth muscle actin).

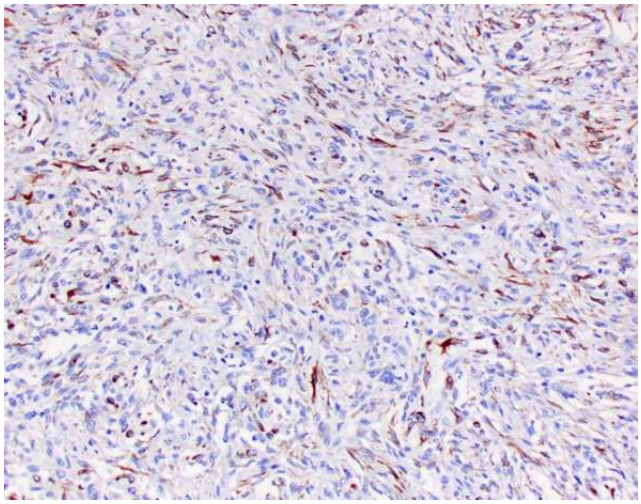

Figure 6. Leiomyosarcoma, uterus, goat. There is patchy cytoplasmic immunolabeling for desmin (20x, immunohistochemistry for desmin).

It is likely that the extensive areas of necrosis led to the transmural perforation, resulting in acute hemoabdomen and sudden death in this goat. Interestingly, a similar outcome has been described for a cervical leiomyoma in an aged goat that died following massive vaginal bleeding from a hemorrhaging artery adjacent to the neoplasm (9). While no damaged artery was evident near the bleeding area in our case that should also remain as a possibility.

 All rights reserved 2007.

Braz J Vet Pathol, 2020, 13(3), 615 – 618
DOI: 10.24070/bjvp.1983-0246.v13i3p615-618

References

1. Agnew DW, MacLachlan NJ. Tumors of the genital system. In: Meuten DJ, editor. Tumors in Domestic Animals. Ames: Wiley Blackwell; 2017. p. 689-722.
2. Cooper BJ, Valentine BA. Tumors of muscle. In: Meuten DJ, editor. Tumors in Domestic Animals. Ames: Wiley Blackwell; 2017. p. 425-466.
3. Dockweiler JC, Cossic B, McDonough SP, Fubini SL, Le KM, Donnelly CG, Gilbert RO, Cheong SH. Tumor collision of uterine adenocarcinoma and leiomyosarcoma in a goat. J Vet Diagn Invest. 2017;29:696-9.
4. Hananeh WM, Ismail ZB, Daradka H. Tumors of the reproductive tract of sheep and goats: A review of the current literature and a report of vaginal fibroma in an Awassi ewe. Vet World. 2019;12:778-82.
5. Kawashima M, Segawa R, Yoshida T, Murayma H, Nagahara R, Kimura M, Endo M, Tanaka T, Shibutani M. Endometrial adenocarcinoma with choriocarcinomatous differentiation in the uterus of a goat. J Vet Med Sci. 2017;79:1091-5.
6. Lohr CV. One hundred two tumors in 100 goats (1987-2011). Vet Pathol. 2012;50:668-75.
7. Pfisterl P, Geissbuehler U, Wiener D, Hirsbrunnerl G, Kaufmann C. Pollakisuria in a dwarf goat due to pathologic enlargement of the uterus. Vet Q. 2007;29:112-6.
8. Ryan MJ. Leiomyosarcoma of the uterus in a goat. Vet Pathol. 1990;17:389-90.
9. Uzal F, Puschner B. Cervical leiomyoma in an aged goat leading to massive hemorrhage and death. Can Vet J. 2008;49:177-9.
10. Whitney KM, Valentine BA, Schlaffer DH. Caprine genital leiomyosarcoma. Vet Pathol. 2000;37:89-94.

Brazilian Journal of Veterinary Pathology. www.bjvp.org.br . All rights reserved 2007.