



Case Report

Mammary carcinoma in a mixed tumor with myeloid metaplasia component presenting *Leishmania* spp. in a dog

Alexandre Arenales^{1*}, Jefferson Ferreira², Ana Carolina O. Almeida³, Daniella B. Rozza⁴, Maria Cecília R. Luvizotto⁴

¹Clínica de Bovinos de Garanhuns, Universidade Federal Rural de Pernambuco (UFRPE), Campus Garanhuns, Pernambuco, Brazil.

²Universidade Federal de Campina Grande (UFCG), Campus Patos, Paraíba, Brazil.

³Universidade José do Rosário Vellano (UNIFENAS), Alfenas, Minas Gerais, Brazil.

⁴Univ. Estadual Paulista (Unesp), Faculdade de Medicina Veterinária de Araçatuba, Departamento de Clínica, Cirurgia e Reprodução Animal, São Paulo, Brazil.

*Corresponding author: e-mail: alexandre.arenales88@gmail.com

Submitted August, 24th 2020, Accepted October, 13th 2020

Abstract

Here is described a 9-years-old, intact female dog with cytopathological analysis from mammary tumors containing *Leishmania* spp. amastigotes in macrophages. The animal was submitted to euthanasia and necropsy was performed. Histopathological diagnosis was a mammary carcinoma in a mixed tumor, grade I, with myeloid metaplasia component containing macrophages laden with a large amount of amastigotes. For confirmation, immunohistochemistry was used in neoplastic tissue and resulted in strong positivity for *Leishmania* antibody. Myeloid metaplasia portion of mammary carcinoma in a mixed tumor may be, rarely, a site for diagnosis of Canine Visceral Leishmaniasis.

Key words: canine visceral leishmaniasis, cytopathology, immunohistochemistry, mammary gland tumor.

Introduction

Leishmania spp. is the etiologic agent of leishmaniasis, which in affected dogs, 90% are a visceral form, called Canine Visceral Leishmaniasis (CVL). In dogs this disease may be an extensive parasitism, affecting mainly the spleen, lymph nodes, liver, bone marrow and skin. Microscopically, parasites are found usually in the cytoplasm of macrophages (1). There is a possible association between malignant disorders and Leishmaniasis, where those authors divide four different types of this association: leishmaniasis mimicking a malignant disorder; simultaneous diagnosis of leishmaniasis and tumors in immunocompromised individuals; direct involvement of *Leishmania* spp. in tumors pathogenesis; leishmaniasis as a difficult diagnosis and treatment in individuals under anti-neoplastic chemotherapy (6). Concomitant cases of leishmaniasis and tumors in dogs were reported, as a fibrosarcoma, small cell lymphoma and an adrenocortical adenoma (5), primary

extragenital transmissible venereal tumor (2), and in a cytopathological diagnosis of a mammary carcinoma (8).

Case report

Was referred to the *Veterinary Pathology Service* of Univ. Estadual Paulista (Unesp) – Araçatuba, cytopathology slides from a 9-years-old, female dog, with history of mammary tumors in the thoracic caudal and abdominal caudal mammary glands of left mammary chain and on thoracic caudal mammary gland right mammary chain. Cytopathological exam by fine needle capillary technique was performed by the clinician and slides were routinely processed using Romanowsky stain (Diff-Quick). At cytopathological slides, a complex mammary carcinoma was diagnosed, characterized by moderate cell population composed of clusters of large, well delimited and cuboidal cells, which showed large and slight basophilic cytoplasm; basal, round and large nucleus, with fine coarse chromatin and conspicuous basophilic nucleoli.

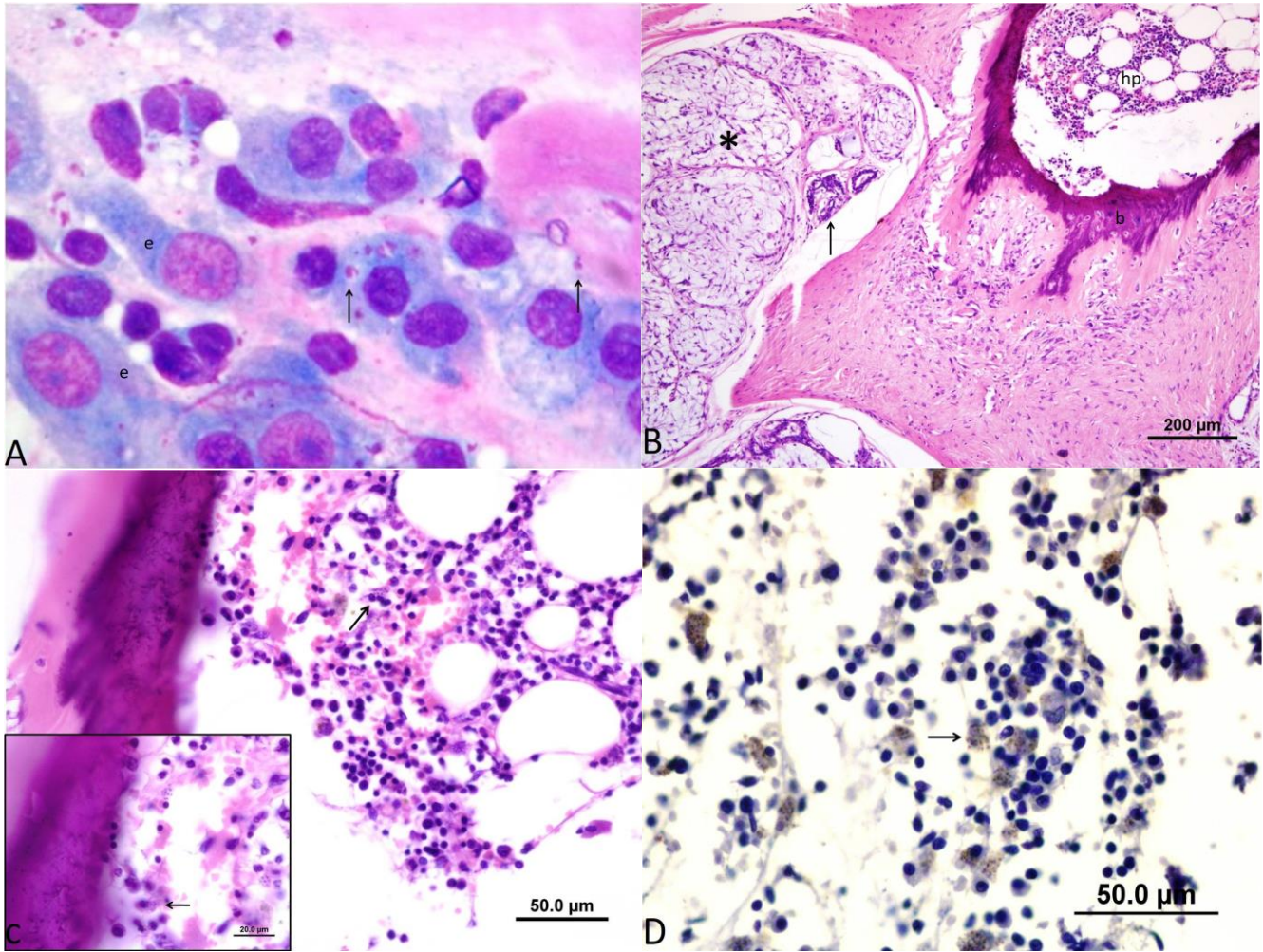


Figure 1. Microscopic findings in a dog in *Leishmania* spp. amastigotes in myeloid metaplasia component of a mammary carcinoma in a mixed tumor. **A.** Cytopathology of mammary carcinoma composed of malignant epithelial cells (e) and *Leishmania* spp. in amastigote (arrows) macrophages. 100x - Diff-Quick. **B.** Histopathology of mammary carcinoma in a mixed tumor. Notice the myxoid matrix (*), scant epithelial tubules (arrow), bone tissue (b) and myeloid metaplasia component (mm). Scale bar = 200µm, H&E. **C.** Histopathology of mammary carcinoma in a mixed tumor, myeloid metaplasia component. Notice macrophages filled with *Leishmania* spp. amastigotes (arrows). Scale bar = 50µm, H&E. **D.** Positive reaction to *Leishmania* spp. antigen in immunohistochemistry (arrow). Diaminobenzidine stain, Harris hematoxylin counterstain.

Criteria of malignancy were mild to moderate anisokaryosis and anisocytosis, binucleated cells and cells with multiple nucleoli. Additionally, inside macrophages, a large number of protozoa, approximately 2 x 3 µm with a well-defined nucleus and kinetoplast, compatible with *Leishmania* spp. amastigotes (Fig. 1A).

Due to leishmaniosis diagnostic, the dog was submitted to euthanasia. At necropsy, were observed severe emaciation and two mammary tumors, one along thoracic caudal and abdominal caudal mammary glands of left mammary chain and on thoracic caudal mammary gland of right mammary chain, measuring 10 x 8 x 6 cm and 5 x 4 x 3 cm respectively, both firm on palpation, with irregular and alopecic surface, attached to adjacent tissues

and ulcerated; cut surface revealed a multilobular arrange white to yellow, with central necrosis. Spleen showed a severe and diffuse splenomegaly due to severe white pulp hyperplasia. All superficial and deep lymph nodes showed severe swelling. Tissues fragments were fixed in 10% formalin and processed as routine for Hematoxylin and Eosin stain. Microscopically, in both mammary glands, was observed on deep dermis an expanding, multilobular, poor delimited and nonencapsulated neoplasm, composed of scant and poor delimited tubules of one layer of columnar epithelial cells, showing moderate, homogeneous and slight eosinophilic cytoplasm; nucleus was basal, round with hypochromic chromatin. Tubules were surrounded by abundant and multilobular to coalescent

areas composed of myoepithelial cells, embedded in a large amount of amorphous and eosinophilic myxoid matrix. Additionally, multifocal islands of cartilage and mineralized bone tissue, which surrounded central areas of myeloid metaplasia (Fig. 1B), containing adipocytes, few capillaries and all myeloid cell lineages: erythroid, granulocytic and megakaryocytic; also a large number of macrophages cytoplasm laden with *Leishmania* spp. (Fig. 1C). Diagnosis was a mammary carcinoma in a mixed tumor, grade I (4). Furthermore, adjacent tumoral skin was severely ulcerated with a diffuse and severe neutrophilic inflammation; and at deep dermis, a large number of fibroblasts containing *Leishmania* spp. In popliteal lymph nodes and spleen, were also visualized macrophages with *Leishmania* spp. Immunohistochemistry in neoplastic sections was performed using positive dog serum for Leishmaniasis, second Moreira et al., 2016 (7). Immunohistochemistry was positive for *Leishmania* antibody (Fig. 1D).

Discussion

In the present case, we were able to find *Leishmania* spp. amastigotes in macrophages within myeloid metaplasia component formed inside a mammary carcinoma in a mixed tumor; and make a diagnosis of leishmaniasis in citopathology and histopathology. Myeloid metaplasia is frequently observed in mammary mixed tumors and was described in detail by Aulera et al., (2011) (3).

In our case, the age of the dog is favorable to both neoplastic and infectious diseases; additionally to ulcerative lesions that resulted from tumoral growth are prone to attract vectors (1). This fact is supported by presence of amastigotes in dermal fibroblast along ulcerated epidermis of the tumor. For the best of our knowledge, there is only one report of a concomitant diagnosis of mammary tumor and Leishmaniasis in the tumor in a dog, which describes a cytopathological evaluation of a carcinoma in a mixed tumor; (8) in addition to epithelial malignant cells the authors found macrophages with cytoplasm filled by *Leishmania* spp. Nevertheless, in that case (8) there was no histopathological evaluation and a consequent lack of localization of the macrophages with *Leishmania* spp. amastigotes. *Leishmania* spp. amastigotes was described inside 3 different origins of neoplastic cells (5) (mesenchymal, lymphoid, and adrenocortical), with a suggestion of nonspecific cellular tropism for this protozoan, while another study (2) suggested a histiocytic origin of transmissible venereal tumor due the presence of amastigotes inside that neoplastic cells. In conclusion, diagnosis of Canine Visceral Leishmaniasis may be, rarely, made in myeloid metaplasia component of mammary carcinoma in a mixed tumor.

References

1. Alvar J, Cañavante C, Molina R, Moreno J, Nieto J. Canine Leishmaniasis. *Adv Parasit.* 2004;57:1-88.
2. Albanese F, Poli A, Millanta F, Abramo F. Primary cutaneous extragenital canine transmissible venereal tumour with *Leishmania*-laden neoplastic cells: a further suggestion of histiocytic origin? *Vet Dermatol.* 2002;13:243-6.
3. Aulera P, Bertagnolli A, Ferreira E, Campos G, Dias AP, Campos C, Campos L and Cassali G. Myeloid metaplasia in canine mixed mammary tumors: occurrence and characterization. *Vet Q.* 2011;31(4):173-7.
4. Cassali GD, Lavalle GE, Ferreira E, Estrela-Lima A, De Nardi AB, Ghever C, Sobral RA, Amorim RL, Oliveira LO, Sueiro FAR, Beserra HEO, Bertagnolli AC, Gamba CO, Damasceno KA, Campos CB, Araujo MR, Campos LC, Monteiro LN, Nunes FC, Horta RS, Reis DC, Luvizotto MCR, Magalhães GM, Raposo JB, Ferreira AMR, Tanaka NM, Grandi F, Ubukata R, Batschinski K, Terra EM, Salvador RCL, Jark PC, Delecordi JER, Nascimento NA, Silva DN, Silva LP, Ferreira KCRS, Frehse MS, Santis GW, Silva EO, Guim TN, Kerr B, Cintra PP, Silva FBF, Leite JS, Mello MFV, Ferreira MLG, Fukumasu H, Salgado BS, Torres R. Consensus for the diagnosis, prognosis and treatment of canine mammary tumors - 2013. *Braz J Vet Pathol.* 2014;7(2):38-69.
5. Ferro S, Palmieri C, Cavicchioli L, De Zan G, Aresu L, Benali SL. *Leishmania* amastigotes in neoplastic cells of 3 non histiocytic canine tumors. *Vet Pathol.* 2013;50:749-52.
6. Kopterides P, Mourtzoukou EG, Skopelitis E, Tsavaris N, Falagas ME. Aspects of the association between leishmaniasis and malignant disorders. *T R Soc Trop M H.* 2007;101:1181-9.
7. Moreira PRR, Franciscato DA, Rossit SM, Munari PD, Vasconcelos RO. Influence of apoptosis on liver and spleen resistance in dogs with visceral leishmaniasis. *Rev Bras Parasitol Vet.* 2016;25(3):341-7.
8. Pinho FA, Mello GWS, Barbosa SRV, Gonçalves LM, Silva SMMS, Costa FAL. Citologia de tumor de mama associada à *Leishmania* (*L.*) *chagasi*. In: anais do 35º Congresso Brasileiro de Medicina Veterinária; 2008, Gramado. [cited 2014 Fev 6]. Available from:<http://www.sovergs.com.br/conbravet2008/anais/cd/resumos/R0602-2.pdf>.