Braz J Vet Pathol, 2020, 13(3), 622 – 627
DOI: 10.24070/bjvp.1983-0246.v13i3p622-627

BJVP
Brazilian Journal of Veterinary Pathology
ISSN 1983-0246

Case Report

Cutaneous non-epitheliotropic large T-cell lymphoma in an English Bulldog

Halana do C. Silva[1], Rodrigo dos S. Horta[2], Bruna V. de Sena[3], Ana Carolina de J. Pinto[1], Isabella de O. Almeida[3], Júlia da P. P Rangel[4], Tayse D. de Souza[1], Mayra C. Flecher[1*]

[1]Hospital Veterinário, Laboratório de Patologia Animal, UVV, Vila Velha – ES, Brasil.
[2]Departamento de Clínica e Cirurgia Veterinárias, EV/UFMG, Belo Horizonte – MG, Brasil.
[3]Hospital Veterinário, Clínica de Pequenos Animais, UVV, Vila Velha – ES, Brasil.
[4]Hospital Veterinário, Cirurgia e Anestesiologia de Pequenos Animais, UVV, Vila Velha – ES, Brasil.
[*]**Corresponding author:** Universidade Vila Velha, campus Nossa Senhora da Penha. Rua Mercúrio, s/n, Boa Vista, Vila Velha, ES, 29102-623, Brazil. E-mail: mayra.flecher@uvv.br

Submitted June, 03rd 2020, Accepted September, 29th 2020

Abstract

Cutaneous lymphoma is histologically classified in epitheliotropic and non-epitheliotropic, the first showing higher incidence in dogs, and the second, in cats. Non-epitheliotropic lymphoma presents lymphocyte aggregates in the dermis and subcutaneous tissue, however cutaneous annexes are not infiltrated. It is usually more aggressive than epitheliotropic lymphomas. The aim of this study was to report a case of non-epitheliotropic lymphoma in a 9-year-old, female, English Bulldog presented with non-ulcerated skin nodules adhered to deep tissues. Microscopic and immunophenotypic features supported the diagnosis of non-epitheliotropic large T-cell lymphoma. Treatment was initiated with modification of the LOPP protocol, replacing procarbazine by dacarbazine (600 mg/m²) for up to six cycles, with a three-month survival. In the 11th week of treatment, after recurrent episodes of vomiting and diarrhea, abdominal ultrasound was performed and revealed an infiltrative mass in the stomach's greater curvature topography, showing an expansive and accentuated increase in one week, when euthanasia was elected.

Key words: neoplasm, canine, round-cell tumor, lymphocytes, skin.

Introduction

Cutaneous lymphoma represents 1% and 2.8% of all skin tumors in dogs and cats, respectively (5). They are histologically divided into epitheliotropic and non-epitheliotropic. The non-epitheliotropic group is the most common form of cutaneous lymphoma in cats, being less common in dogs (5, 11), and can be of a primary dermal origin or secondary to multicentric lymphoma (3, 5).

The average age of dogs and cats affected with cutaneous lymphoma is 10 years old (6). Weimaraners, Boxers, Saint Bernard, Basset Hounds, Irish Setters, Cocker Spaniels, German Shepherds, Golden Retrievers and Scottish Terriers are predisposed, and sex predilection is not reported (5). Non-epitheliotropic lymphoma can originate from B or T-cells (6), but frequently exhibit T-cell immunophenotype (2, 14).

Macroscopically, they appear as masses, nodules, or plaques, with focal or multifocal distribution throughout the body, usually located in the trunk region (6). They may be presented at variable sizes, which can be pruritic, therefore can cause ulceration, and may also present scabs and alopecia (10). Microscopically, it is, characterized by lymphocyte aggregates in the dermis and subcutaneous tissue (14), with occasional epidermal infiltrates, however the cutaneous annexes are not affected (5, 6). Typical lymphocytes, plasma cells, histiocytes, neutrophils and eosinophils are frequently seen along with the neoplastic cells (6, 11, 14), which implies a differential for cutaneous histiocytoma, plasmacytoma, mast cell tumor, transmissible venereal tumor, or even inflammatory

Braz J Vet Pathol, 2020, 13(3), 622 – 627
DOI: 10.24070/bjvp.1983-0246.v13i3p622-627

conditions, being immunohistochemistry or flow cytometry necessary for diagnosis confirmation (5, 6, 14).

Because their cell morphology is highly variable, they are sub-classified into large cells (histiocytoid or clear cells), small cells, immunoblastic (5), and inflammatory (10). The large cell phenotype is more common (5). Treatment is based on chemotherapy protocols using mainly lomustine. Authors have studied the prognosis and toxicity of some protocols in the treatment of T-cell lymphomas and have observed favorable results (1, 8). Nevertheless, the prognosis remains poor, due to the short-term response to chemotherapeutic agents and the progressive course of the disease, which may affect lymph nodes and bone marrow, among other organs (5).

Non-epitheliotropic lymphomas tend to be more aggressive and progressive (6). However, Moore et al. (2013), reported an average survival time of 9 months in 19 dogs with the inflammatory form of cutaneous non-epitheliotropic T-cell lymphoma.

The aim of this study is to report a case of non-epitheliotropic large T-cell lymphoma in an English Bulldog, treated with a modified LOPP protocol for six cycles, which showed disease progression with an infiltrative stomach mass in the 11th week of treatment.

Case report

A nine-year-old, intact female English Bulldog was presented to the Veterinary Hospital "Professor Ricardo Alexandre Hippler", in Vila Velha, Espírito Santo, Brazil, showing nodules in the cervical region of the left auricular base, at the edge of the left auricular pinna, and in the left flank region, with a two-day evolution.

These nodules were subcutaneous and firm on palpation, neither ulcerated nor alopecic. Fine needle aspirates (FNA) were performed, stained with Diff-Quick, revealing the same cell pattern in all nodules. The smear consisted of high cellularity, composed of large lymphocytes with moderate to sparse and basophilic cytoplasm, with a clear perinuclear area; increased nucleus: cytoplasm ratio; round nucleus, often indented, rarely binucleated, central, but sometimes eccentric, ranging from 2 to 3 red blood cells or more, and with an irregular nuclear membrane; coarse chromatin, multiple peripheral nucleoli allthough sometimes large and single. There was also mild to moderate anisocytosis and severe anisokariosis, moderate nuclear pleomorphism (Fig. 1). Seven mitotic figures were observed in 10 high-power magnification fields (HPF, 100x). According to Kiel classification (13) it was diagnosed as a high-grade lymphoma, likely centroblastic.

Excisional biopsy was performed, and samples were fixed in 10% formalin and routine histopathological processing for paraffin inclusion. Cut sections were mounted in glass and stained with hematoxylin and eosin (HE). Macroscopically, the nodule in the cervical region, near the base of the left ear, was 1.5 x 2.1 cm; while the left flank nodule was 0.8 x 0.9 cm. Both nodules were found in the subcutaneous, poorly delimitated, firm, and with multifocal brownish areas.

Similar histopathological features were found in the nodule close to the base of the left ear (Fig. 2A), and in the left flank region (Fig. 2B). Non-encapsulated proliferation in the subcutaneous tissue particularly in the deep dermis onto the periphery of annexes glands (Fig. 3A), but without invading them. It also expanded to the muscular area (Fig. 3B). In the neoplasm's periphery, the cells were organized into cords; they were rounded, with a slightly eosinophilic scarce to moderate cytoplasm; with an oval nucleus, sometimes reniform or cleaved, large and vesicular; single to multiple nucleolus. There was accentuated anisokaryosis, cellular and nuclear pleomorphism. There were 40 mitotic figures in 10 HPF (40x) (FN20) (Fig. 3C). The characteristics and distribution of neoplastic cells confirmed the diagnosis of non-epitheliotropic lymphoma.

Immunohistochemistry was performed, and the technique information's is presented in Table 1. The tissue sections were fixed on slides previously silanized. A polymer system was used as secondary antibody (Advance system - DAKO®). Staining was performed using 3,3-diaminobenzidine and counter-stained with hematoxylin. External and internal controls were used to validate the reaction. A normal lymph node was used as a positive control for antibodies CD3, CD79a, MUM-1, Ki-67, PAX-5, and CD18; mast cell tumor was used as a control for Ki-67 and KIT, and skin for E-Cadherin. As negative control, primary antibody was replaced by buffer solution. Histopathological diagnosis was confirmed by immunohistochemistry, where neoplastic cells immunoexpressed CD3 (Fig. 3D), but they did not express CD79a, MUM1, PAX5, CD18, KIT and E-Cadherin (Fig. 3E), and the proliferation marker Ki-67 was positive in approximately 80% of the neoplastic cells (Fig. 3F). It favored the diagnosis of cutaneous non-epitheliotropic lymphoma of large T-cells.

The treatment consisted of a modification of the LOPP protocol (lomustine, vincristine, procarbazine and prednisolone), with replacement of procarbazine by dacarbazine (600 mg/m^2), according to Table 2. Prednisolone was maintained only in the first cycle and, from the second cycle, interferon-alpha 2b was started, at a dose of 1.5x106 IU/m2 on Mon-Wed-Fri, subcutaneously. Isotretinoin was also started, however in the second week of chemotherapy, at a dose of 1.5 mg/kg every 12 hours, orally.

Braz J Vet Pathol, 2020, 13(3), 622 – 627
DOI: 10.24070/bjvp.1983-0246.v13i3p622-627

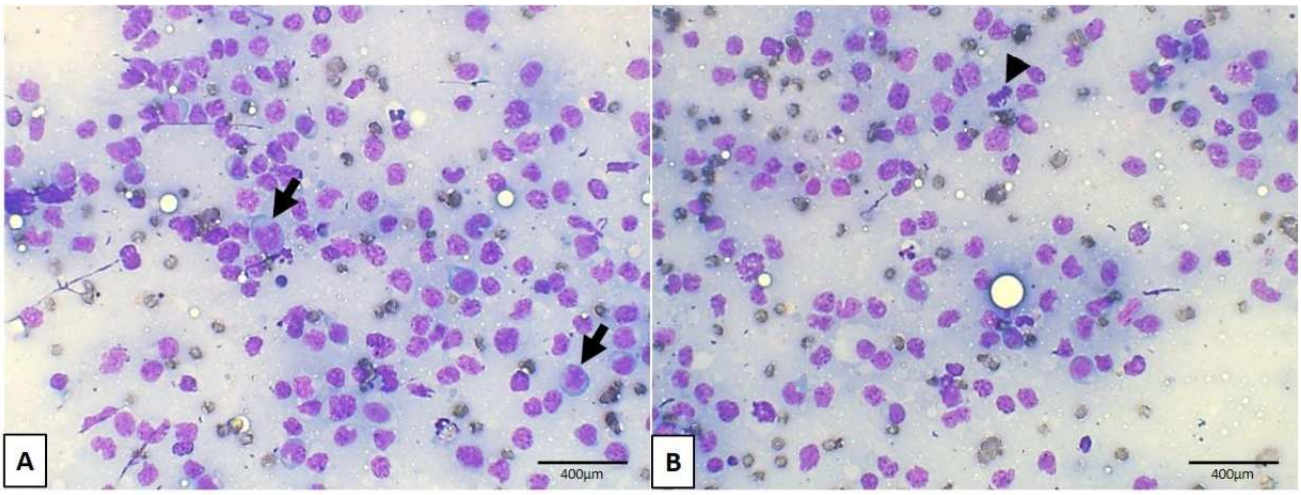

Figure 1. Non-epitheliotropic large T-cell lymphoma, English Bulldog, female, nine years old. Fine needle aspirates. **A.** Large lymphocytes with moderate to sparse and basophilic cytoplasm, with a clear perinuclear area; round nucleus, often indented (arrow), ranging frequently > 2 red blood cells, and with an irregular nuclear membrane; coarse chromatin, multiple peripheral nucleoli. **B.** Mitotic figure (arrow head). Diff-Quick staining, 40X.

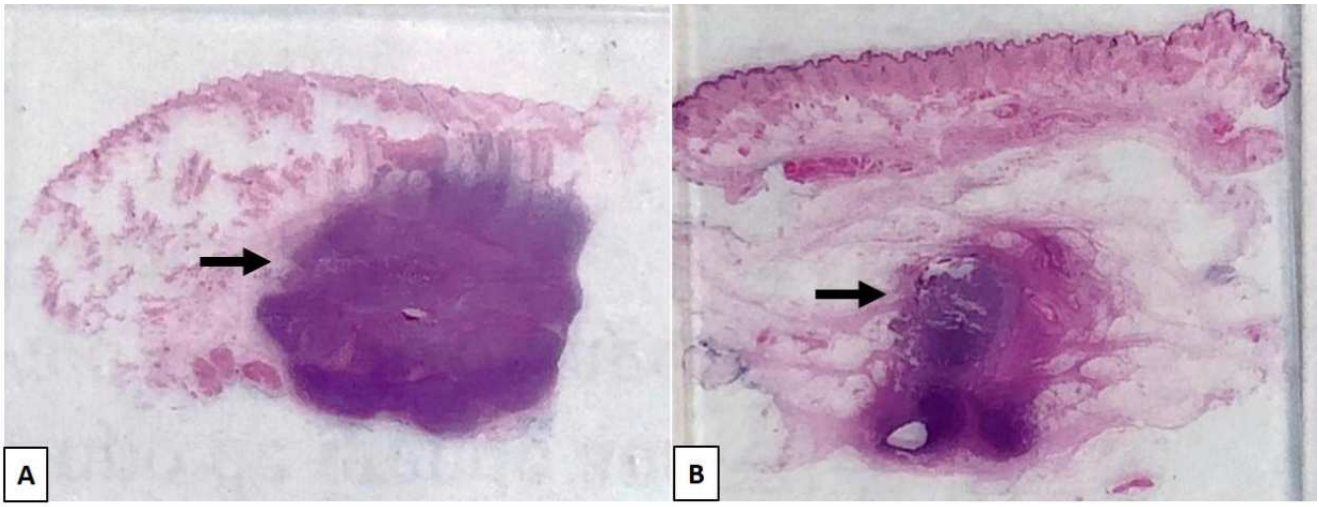

Figure 2. Non-epitheliotropic large T-cell lymphoma, English Bulldog, female, nine years old. Submacroscopic image of non-epitheliotropic lymphoma, HE. **A**. Subcutaneous nodule (arrow) near the base of the left ear. **B.** Subcutaneous nodule (arrow) near the on the left flank.

In spite of that, the patient did not respond to the protocol and had tumor recurrence after 10 days. In the 11th week of treatment, recurrent episodes of vomiting and diarrhea were also observed. Abdominal ultrasound was performed and in the stomach's greater curvature topography an accentuated thickening of the gastric wall was observed, with 1.57 x 2.38 cm, and loss of stratification as well as absence of peristalsis (Fig. 4A and B). One week later, the ultrasound was repeated, and again in the larger curvature of the stomach it was observed a structure in continuity with the gastric wall measuring 4.50 x 5.37 cm in transversal sections of the gastric body, suggestive of an infiltrative mass (Fig. 4C).

After 91 days of cytological diagnosis, euthanasia was elected, due to the infiltrative mass in the stomach which was compromising the animal's welfare and leading to severe lethargy and inappetence. Necropsy was not authorized by the owner.

Discussion

Although the etiology of non-epitheliotropic lymphoma in dogs has not been elucidated, it is believed that chronic inflammation is a possible predisposing factor (3). The animal in the present study had a history of allergic dermatitis and recurrent

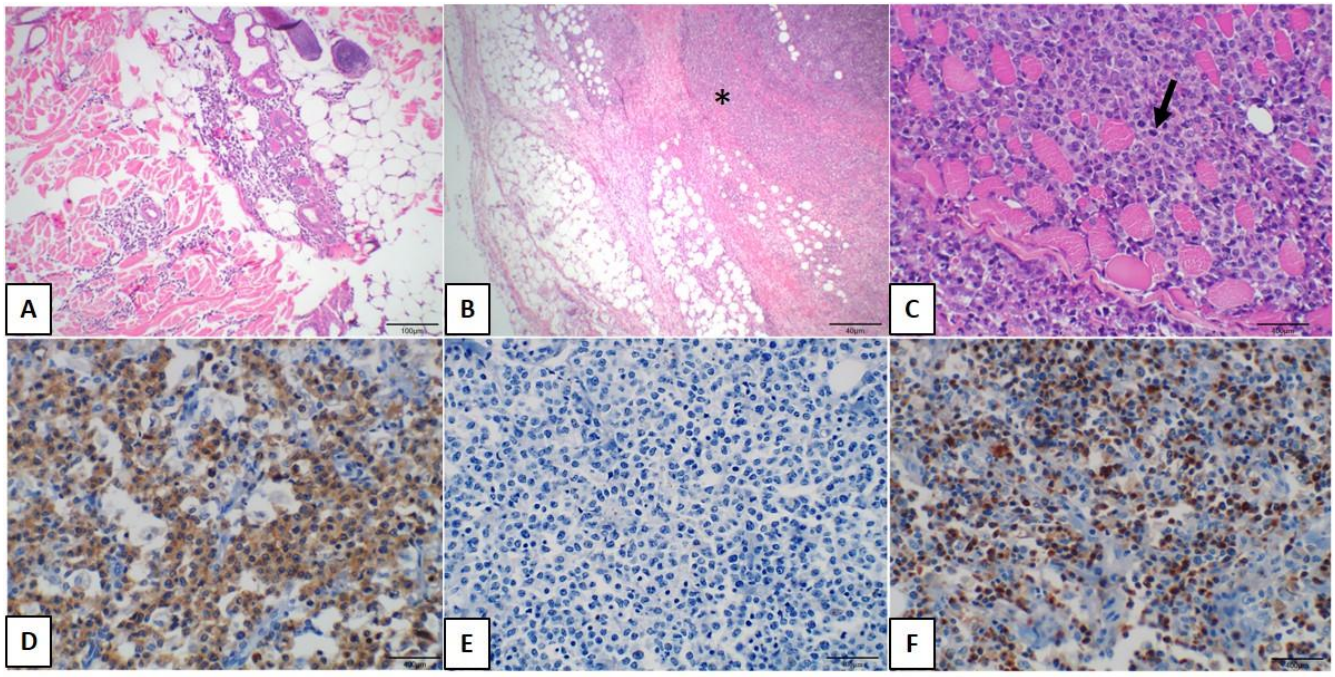

Figure 3. Non-epitheliotropic large T-cell lymphoma, English Bulldog, female, nine years old. **A.** Nodular lesion consisting of neoplastic lymphocyte aggregates immersed in the deep dermis, however, it does not invade cutaneous annexes. HE, 10X. **B.** Nodular lesion consisting of neoplastic lymphocyte extending to subcutaneous and muscular areas (*). HE, 10x. **C.** Nodular lesion consisting of neoplastic lymphocytes presenting eventually moderate cytoplasm, with accentuated cell pleomorphism, single, round nucleus, but sometimes cleaved, with accentuated anisokaryosis and nuclear pleomorphism. High mitotic index (arrow). HE stain, 40X. **D.** Positive immunostaining for CD3. **E.** Negative immunostaining for E-Cadherin. **F.** Immunostaining for Ki67, showing 80% of nuclear immunolabeling among neoplastic cells.

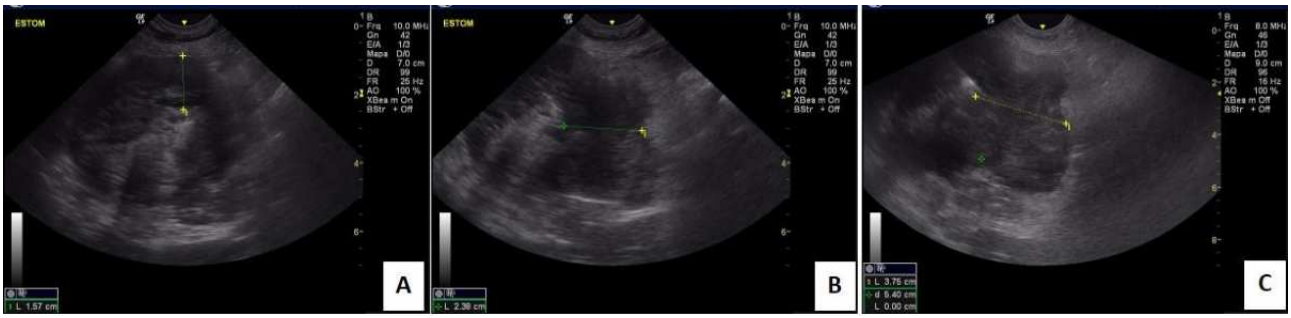

Figure 4. Non-epitheliotropic large T-cell lymphoma, English Bulldog, female, nine years old. **A, B.** Abdominal ultrasound of the stomach's greater curvature topography with an accentuated thickening of the gastric wall, with 1.57 x 2.38 cm. **C.** One week later, the structure in continuity with the gastric wall measured 4.50 x 5.37 cm, in transversal sections of the gastric body, suggestive of an infiltrative mass.

Braz J Vet Pathol, 2020, 13(3), 622 – 627
DOI: 10.24070/bjvp.1983-0246.v13i3p622-627

Table 1. Immunohistochemistry protocol used.

Target antigen	Clone	Brand	Dilution	Antigenic Recovery	pH	Incubation
CD3	F7.2.38	Dako	1:300	Citrate	5,6	Overnight
CD79a	JCB 117	Dako	Ready-to-use	EDTA	8,9	Overnight
MUM-1	MUM1p	Dako	Ready-to-use	EDTA	8,9	Overnight
KI67	Mib-1	Dako	1:300	EDTA	8,9	Overnight
PAX-5	DAK-PAx5	Dako	Ready-to-use	EDTA	8,9	Overnight
CD18	M18/2	Abcam	1:300	EDTA	8,9	Overnight
KITr	YR 145	Cellmarque	1:300	EDTA	8,9	Overnight
E-Cadherin	EP6	Cellmarque	1:300	EDTA	8,9	Overnight

Table 2. Modified LOPP chemotherapy protocol.

Chemotherapeutic	Week		
	1	**2**	**3**
Vincristine (0,5mg/m²)	X		X
Lomustine (60mg/m²)	X		
Dacarbazine (600mg/m²)		X	
Predinisolone (1mg/Kg)	X	X	X

Repeat for up to 6 cycles. Prednisolone was maintained only during the first cycle, being replaced by interferon-alpha2b at a dose of $1.5x10^6$ iu/ m^2 mon-wed-fri.

malasseziosis with severe itching. The English and French Bulldog breeds were identified as predisposed for development of cutaneous lymphoma by Hendricks (2017), and non-epitheliotropic lymphoma has already been reported in French Bulldogs (7), however, reports of such lymphoma in English Bulldogs were not found. The patient in the present report was a nine year old, which is in concordance with Hendricks (2017) about the average age of cutaneous lymphoma occurrence in dogs.

Dermal and subcutaneous nodules are commonly found in diseased animals, and this was seen in clinical examination and submacroscopic evaluation (5). The macroscopic characteristics were similar to those described by Hendricks (2017), but without ulceration or alopecia as observed by other authors (7, 10). Microscopic characteristics of the neoplastic cells observed and described in this study corroborate with what has been demonstrated by other authors (5, 6, 11, 14). Large cell lymphomas have large, oval, cleaved, vesicular nuclei as well as clear abundant cytoplasm and, therefore, can mimic the appearance of histiocytes. The subclassification of large cell non-epitheliotropic lymphoma, the most common phenotype of this lymphoma (5), has been associated to a high mitotic index according to Gross et al. (2005) and Hendricks (2017). In this report, the mitotic index was high in the histopathology count, correlated with the high positive Ki-67 immunolabeling.

Tumor cells of the present case presented immunolabeling for CD3, a pan-T cell marker (10), which defines the T - immunophenotype of this lymphoma, considered as the most common according to Day (1995) and Valli (2017).

Other possible differential diagnoses were ruled out due to the non-expression of CD79a and PAX5 (expressed in B cell lymphomas), MUM1 (expressed in plasmacytomas), CD18 (expressed mainly in histiocytomas), KIT (expressed in mast cell tumors) and, E- Cadherin (expressed in carcinomas and hystiocytic tumors). These differentials were suggested due to the location of the tumors, and due to the fact that they were round-cell neoplasms, as also suggested by some authors (5, 6, 14).

Non-epitheliotropic lymphoma is a neoplasm with a rapid and progressive course and may involve the regional lymph nodes and viscera (5, 6). Protocols with lomustine for the treatment of high-grade lymphomas with T phenotype exist and have shown acceptable levels of toxicity and average survival rate of 176 days (1). However, in this report, even though the patient showed no clinical signs of toxicity, despite the agressiveness of the LOPP protocol, specially with replacement of procarbazine

by dacarbazine, due to the lack of commercialization of procarbazine in the country, there was gastric compromise due to the infiltrative mass, which led to euthanasia.

The use of retinoids, such as isotreitinoin, along with interferon-alfa 2b, are reported to treat epitheliotropic T-cell lymphoma by Lee et al. (2017), and this combination was very effective, resulting in disease control for more than 246 days without manifesting new clinical signs and metastases, and with long term complete and partial clinical remission. In this study, this combination was used since dealing with a lymphoma with the same immunophenotype, however, there was no objective response.

In the study by Moore et al. (2013), the average survival rate was nine months for non-epitheliotropic inflammatory T-cell lymphoma. The present report showed the most common form of non-epitheliotropic lymphoma in dogs according to Gross et al. (2005), which presents a more aggressive and rapidly progressive course, starting at the skin and progressing to the lymph nodes and viscera as mentioned by Hendrick (2017), showing a reduced survival of only 91 days. Dogs with gastric lymphoma may have diffuse mild thickening of the gastric wall with loss of wall layering and a homogenous hypoechoic echotexture (4), of variable sizes, ranging from segmental to extensive infiltration, and decreased motility in the affected region (12), as seen in this case. However, histopathological evaluation would be necessary to confirm neoplastic infiltration.

In conclusion, the dog in this study was diagnosed by means of cytology with high-grade anaplastic lymphoma due to the characteristics of highly pleomorphic large cells. On histopathology it was compatible with non-epitheliotropic large-cell lymphoma, and immunohistochemistry revealed the T-cell immunophenotype. The patient's survival was three months, and the disease was not responsive to treatment with the modified LOPP protocol, isotreitinoin, and interferon-alpha 2b. Euthanasia was elected due to the presence of an infiltrative mass in the stomach's greater curvature, with an accentuated increase in size in one week, leading to severe deterioration of clinical condition.

References

1. Brown PM, Tzannes S, Nguyen S, White J, Langova V. LOPP chemotherapy as a first-line treatment for dogs with T-cell lymphoma. Vet Comp Oncol. 2017;16(1):108-13.
2. Day MJ. Immunophenotypic characterization of cutaneous lymphoid neoplasia in the dog and cat. J Comp Pathol. 1995;112:79-96.
3. Fontaine J, Bovens C, Bettenay S, Mueller RS. Canine cutaneous epitheliotropic T-cell lymphoma: a review. Vet Comp Oncol. 2009;7(1):1-14.
4. Frances M, Lane AE, Lenard ZM. Sonographic features of gastrointestinal lymphoma in 15 dogs. J Small Anim Pract. 2013;54(9):468-74.
5. Gross TL, Ihrke PJ, Walder EJ, Affolter VK. Lymphocytic tumors. Skin diseases of the dog and cat: clinical and histopathologic diagnosis. 2nd ed. Garsington Road: Oxford, Blackwell Science; 2005. p.882-5.
6. Hendrick MJ. Mesenchymal Tumors of the Skin and Soft Tissues. In: Meuten DJ. Tumors in Domestic Animals. 2nd ed. Ames, Iowa: John Wiley & Sons Inc; 2017. p.172-3.
7. Kondo H, Kagawa Y, Shirota K, Moore PF, Nagata M. Canine non-epitheliotropic CD4 positive cutaneous T-cell lymphoma: a case report. J Vet Sci. 2018;5(2):206-9.
8. LeBlanc AK, Mauldin GE, Milner RJ, LaDue TA, Mauldin GN, Bartges JW. Efficacy and toxicity of BOPP and LOPP chemotherapy for the treatment of relapsed canine lymphoma. Vet Comp Oncol. 2006;4:21-32.
9. Lee GW, Song SB, Kang MH, Park HM. Clinical response to isotretinoin and interferon-α of two dogs with cutaneous epitheliotropic T-cell lymphoma: a case report. BMC Vet. Res. 2018;14(1):382.
10. Moore PF, Affolter VK, Keller SM. Canine inflamed nonepitheliotropic cutaneous T-cell lymphoma: a diagnostic conundrum. Vet Dermatol. 2013;24(1):204-e45.
11. Moore PF, Olivry T. Cutaneous lymphomas in companion animals. Clin Dermatol. 1994;12(4):499-505.
12. Penninck D, d'Anjou MA. Gastrointestinal Tract. In: Penninck D, d'Anjou MA. Atlas of Small Animal Ultrasonography. 2nd ed. Ames, Iowa: John Wiley & Sons Inc; 2015. p.287-8.
13. Suzano S, Sequeira J, Rocha N, Pessoa A. Classificação citológica dos linfomas caninos. Braz J. Vet Res Anim Sci. 2010;47(1):47-54.
14. Valli VE, Bienzle D, Meuten DJ. Tumors of the Hemolymphatic System. In: Meuten DJ. Tumors in Domestic Animals. 2nd ed. Ames, Iowa: John Wiley & Sons Inc; 2017. p.287.