



Original Full Article

Veterinary forensic necropsies: a look through an aspect of forensic traumatology

Natália Freitas de Souza^{1*}, Ranna Taynara dos Reis Sousa², Sara Letícia dos Santos Andrade³, Akim Felipe Santos Nobre³, Washington Luiz Assunção Pereira³, Adriana Maciel de Castro Cardoso Jaques⁴

¹School of Veterinary Medicine and Animal Science (FMVZ), São Paulo State University (UNESP), Road Prof. Doutor Walter Mauricio Correa s/n, 18618-681, Botucatu, São Paulo, Brazil.

²Veterinary Medicine Institute (IMEV), Federal University of Pará (UFPA), BR 316 Road, Km 62, Suburb Saudade I. CEP: 68743-080, Castanhal, PA, Brazil.

³Institute of Animal Health and Production (ISPA), Federal Rural University of the Amazon (UFRA). CEP: 66.077-530, Belém, PA, Brazil

⁴Animal Pathology Laboratory, Institute of Animal Health and Production (ISPA), Federal Rural University of the Amazon (UFRA). CEP: 66.077-530, Belém, PA, Brazil.

*Corresponding author: School of Veterinary Medicine and Animal Science (FMVZ), São Paulo State University (UNESP), Road Prof. Doutor Walter Mauricio Correa s/n, 18618-681, Botucatu, São Paulo, Brazil. Phone: +55-91-98507-4664. E-mail: nataliafreitas_vet@yahoo.com.br.

Submitted May, 11th 2020, Accepted February, 9th 2021

Abstract

Forensic veterinary pathology is essential to identify the cause of death of animals with suspicion of abuse, neglect, exogenous intoxication, medical errors, if the lesions were accidental or ante-mortem or in cases where the animal's identity is needed. It involves several areas that can be used to determine the cause of death in animals, such as traumatology, entomology and toxicology. This work aims to determine the main lesions found in judicial necropsies of animals from the metropolitan region of Belém, qualifying the most prevalent lesions according to the classification in forensic traumatology. The necropsy was performed according to the animal species and using the method of Ghon. The animals were grouping by specie, sex, race and age and it was made a segmentation by vulnerable energy. 33 judicial necropsies (9.06%) were performed between January 2018 and December 2019, including 22 canines (66.7%), seven felines (21.2%), two farm animals (6.1%) and two wild animals (6.1%). Regarding the sex of the animals, in general, 51.51% were males and 45.45% were females. Young dogs and cats represented the highest percentage of cases. Mixed breed dogs were the most prevalent, with 31.8%. In all species, the most prevalent energy was chemical energy, totalling 18 cases. Second, with six cases, mechanical trauma with only canines and felines, in which, only in three were evident the blunt injury. In only one case, the suspicion was of biodynamic energy, with suggestive findings. In conclusion, the forensic necropsy associated with the animal's history is capable of providing relevant information which assists the pathologist in the search for injuries, its identification and interpretation.

Key words: forensic pathology, vulnerable energy, animal abuse, forensic science.

Introduction

Veterinary expertise is an exclusive responsibility of the veterinarian, that may act as a judicial, extrajudicial. Therefore, the veterinarian needs to understand aspects not only of his generalist training but also specific aspects of legal veterinary medicine. The forensic veterinary pathology and forensic veterinary traumatology are sub-areas of legal veterinary medicine which deals with documents, explanation of pathological findings both for

investigators and to the court (4, 6, 27).

Forensic veterinary pathology is essential to identify the cause of death of animals with suspicion of abuse, neglect, exogenous intoxication, medical errors, determine if the lesions were accidental or ante-mortem or in cases where the animal's identity is needed. It involves traumatology, which studies injuries and its agents, and thanatology, which studies death and cadaverous phenomena (4, 7 22). However, the forensic field is multidisciplinary, and areas such as toxicology and

entomology can be used to determine the cause of death in animals.

Veterinary forensic traumatology has been highlighted over the years and it is based on human forensic traumatology for determining injury patterns in veterinary medicine. The demand increased due to the concern of society about animal cruelty and consequent knowledge by the population about animal law (4, 21). As a result, the creation of animal law as a separate science is needed, separating it from environmental law.

In traumatology, injury-promoting agents are classified according to the type of energy they produce. Within veterinary forensic traumatology, the most common energies are the energies of a mechanical order, which include injuries caused by a puncture, sharp and blunt agents; chemistry, including poisons; and biodynamic, where there are shocks (21).

A forensic or judicial necropsy is a variation of conventional necropsy in veterinary medicine, which describes, in detail, the injuries found, as well as their consequences, relating them to the history presented in the request when it is available. It is a fundamental part of a legal process involving animal crimes and must be carried out by a competent professional (4, 7, 22).

The major goal of his work is to determine the main lesions found in judicial necropsies of animals from the metropolitan region of Belém, qualifying the most prevalent lesions according to the classification in forensic traumatology.

Material and methods

Origin of animals

The inclusions of these animals in this study was based on the following criteria: presence or absence of a police report or a police official letter, history presented by the tutor, for example: animal cruelty, intentional poisoning or intentional death; the aim of the examination (procedural purpose or not). For the most part, the exam was requested by the tutor himself and, in a few cases, by a veterinarian or institution.

The animals came directly from the Veterinary Hospital “Mário Dias Teixeira” - Federal Rural University of the Amazon (HOVET / UFRA), from the Environment Police - DEMA, Military Police, Brazilian Army or required by the tutor himself. Regardless of the origin, the animals were referred to the Animal Pathology Laboratory - LABOPAT / UFRA and received the protocol number.

At LABOPAT / UFRA, a necropsy request form was filled out with information about the animal, as well as previous examinations, diseases and treatments that could assist during the necroscopic examination and in the final diagnosis of the cause of death.

Necropsy

Necropsies were performed according to the animal species and using Ghon's adapted technique for the removal of the viscera (19).

The photodocumentation was made of all necroscopic findings, in addition to the detailed description into the necropsy form. Stainless steel fixed table, knives of different sizes, anatomical, rat teeth, haemostatic forceps (when necessary), hatchet, costotome, ruler, string, scalpel, syringes, needle, ladle, identification tags, saw for removal of the skullcap and plastic bags for the disposal of biological material. Also, pencils, glass slides, Eppendorf's, collecting bottle containing 10% buffered formalin for fragments for histopathological analysis and transparent plastic bags for collecting fragments for toxicological examination.

Initially, the animals were grouped by species, sex, race and age, when the information was provided besides the separation into the vulnerable energy: mechanical energy; physical energies; chemical energies; biodynamic energies; physico-chemical energies; elucidation of *causa mortis* (requested by the tutor); and those cases where the official institution required the necropsy.

Complementary exams were performed or requested when necessary. The x-ray examination was used in an animal with suspected projectile injury to check its presence and anatomical positions.

Besides, in all judicial cases, stomach contents were collected in a 15 ml falcon type tube, identified, and delivered to the animal's tutor after signing the receipt term, to toxicological examination in a specific laboratory. To perform the referred exam, the tutor was advised by the pathologist, to register a police report in case they did not have one. For other samples, the same procedure was adopted.

Results and discussion

In Brazil, there are no official data regarding violence against animals. There is sub notification of this case and sub estimation of the animal's rights. Even though there are several information in the media, the majority of the population still do not know the legislation for animal protection and the penalties, which may contribute for the low number of notifications (23).

From January 2018 to December 2019, 364 necropsies were performed at LABOPAT/ UFRA, being 33 forensic necropsies (9.06%), including 22 canines (66.7%), seven cats (21.2%), two farm animals (6.1%) and two wild animals (6.1%). Regarding the origin of the animals, 29 (87,87%) were request by the owner and 4 (12,12%) were request through a public institution: military police, Brazilian army and Environmental police.

Dogs represent the majority of cases of animals received for the forensic necropsy. In the work developed by Marlet and

Maiorka (14), from 2003 to 2007, dogs also presented the highest percentage in all years of the study. However, dog and cat dynamics population has changed over the years, especially regarding cats population, which is increasing (8).

Regarding the sex of the animals, in this study, 51.51% were males and 45.45% were females and one animal did not have informed sex, representing 3.03%. These results are similar to other results both for humans and animals, where the prevalent sex in cases of violent death is male. The literature highlight the aggressive and risk behaviour of men and that it could explain the prevalence of the gender in this cases. In the study by Marlet and Maiorka (15), there was a slight prevalence of males compared to females, however, these data are variable, since sex is not a prerequisite for the practice of animal abuse. However, some studies show the prevalence of abuse is higher in male dogs due to the difficulty of controlling the animal and the fact that they are more aggressive when compared to females (15, 17).

Regarding felines, there was a higher prevalence of females compared to males, similar data were found in the study by Marlet and Maiorka (15). The hypothesis for the higher prevalence of female felines in relation to males is about animal behaviour. Females have a more active sexual behaviour when compared to males, which makes difficult to control procreation, such as the habit of going to roofs at night and vocalizing during oestrus. In addition, such behaviour implies expenses, since sterilization is necessary (13, 18)

In this study, young dogs and cats (up to five years old) represented the highest percentage of cases received for a forensic necropsy. Similar to the research of Marlet and Maiorka (15). The authors reinforce the relationship with human's cruelty, since the practice against children up to three years of age is also high. This fact can be justified by the vulnerability of both humans and animals at this stage of life, making it easier for the aggressor to practice abuse.

Of the 22 dogs, 13 were aged up to five years; four aged between six and 10 years; four between 11 and 15 years old and one over 16 years old. Regarding felines, of the seven, six were aged up to five years and one aged between six and 10 years. Of the two wild specimens, only

one had an informed age of one year. Of the farm animals, the specimen *Bubalus bubalis* was 19 years old and the domestic duck specimen was one year old.

Regarding canine breed, the mixed breed animals were the majority, with 31.8%, followed by German Spitz with 18.2%, German Shepherd with 13.6%, Poodle with 9.1%, Rottweiler with 9.1%, Boxer, Golden Retriever, Shih-tzu and Pug with 4.5%. All cats (100%) were mixed breed. Similar data were found by Maria (14), who developed a retrospective study on the main changes found in autopsies of dogs and cats that died.

Of the wild animals received for necropsy, one was of the specie *Iguana iguana* and another of the species *Bradypus variegatus*. Breeds were not informed of production animals.

The distribution according to the suspected cause of death presented by the applicant in the history is shown in table 1, which was also grouped by species, in the canine, feline, farm animals and wild animals.

In all species, the most prevalent vulnerable energy was chemical energy (54.54%), accounting 18 cases, especially in canines and felines. Mostly, the suspicion was of exogenous intoxication and two cases of anaesthetic intoxication during the surgical procedure. This prevalence is due to the ease in the acquisition of toxic agents as well as the easy administration to animals (15).

Despite the higher prevalence of canine intoxication obtained in this study, Marlet and Maiorka (15) report that intoxication in companion animals is more frequent in felines than in canines. In addition, the authors relate this high rate to the behaviour of animals, as felines have easier access to neighbouring streets and houses, and isolating themselves when they become ill.

The history is fundamental for delimiting the suspicion of exogenous intoxication. The main clinical signs reported were: vomiting, shortness of breath, diarrhea, seizures and tachypnoea. In addition, some tutors reported that they saw the moment of offering snacks with the possible toxic agent. According to Klainbart et al. (12) and Tremori (28), the frequent clinical signs are vomiting, diarrhea, sialorrhoea, miosis, generalized tremors, respiratory

Table 1. Distribution of cases received for forensic necropsy according to suspicion.

Suspicion	Canine	Feline	Farm animal	Wild animal	Total
Chemical energy	11 (50%)	5 (71,43%)	1 (50%)	1 (50%)	18 (54,54%)
Mechanical energy	4 (18,18%)	2 (28,57%)	-	-	6 (18,18%)
Biodynamic energy	1 (4,54%)	-	-	-	1 (3,03%)
Elucidation of <i>causa mortis</i>	3 (13,63%)	-	-	1 (50%)	4 (12,12%)
Official organ request	3 (13,63%)	-	1 (50%)	-	4 (12,12%)

distress, hyperactivity and tonic-clonic seizure.

These clinical signs occur, mainly in carbamates intoxication, due to inhibition of acetylcholinesterase, promoting the accumulation of acetylcholine and consequent hyperstimulation of muscarinic, nicotinic and CNS receptors (7, 28)

The main findings at necropsy of these were congestion in subcutaneous vessels and several organs such as liver, lung, mesentery vessels, epicardium and central nervous system. In only two cases, blackened granules were observed in the stomach, suggestive of aldicarb (Fig. 1). Grossly, the findings are nonspecific and may present with haemorrhage, congestion and pulmonary oedema, hepatic and renal congestion. A macroscopic indication is the presence of grayish-colored spherical granules inside the stomach and the initial portion of the duodenum (28).

The production animal corresponded to a domestic duck, a four-month-old female, which lived with other animals that died in suspicion and suddenly. It was reported, in the history, that the animal could not move or feed, and that this would also have happened with other animals that were raised in the same place: 40 ducks, 30 chickens, seven guinea hens, two mallards, 15 bantam, one turkey, four giant chickens.

Poisoning of farm animals can result in mass death, especially if the animals live close and in areas of agricultural production. This intoxication may be due to the ingestion of pesticides, having organophosphates and carbamates as an active agent. These agents are toxic to non-target species, such as domestic animals, wild animal populations, especially birds. Exposure to this agent can be primary or secondary, through ingestion of contaminated vegetables or animals (11).

The wild animal refers to a free-living *Bradypus variegatus*, which presented a poor state of conservation, compromising the gross evaluation of the organs, in addition to numerous specimens of larvae morphologically compatible with fly larvae, especially in the oral cavity suggesting that there was a prolonged time between death and animal withdrawal for necroscopic examination. Based on macroscopic findings, the cause of death was undetermined. However, stomach contents were collected for toxicological analysis.

Branford et al. (2), in their study, detected the exposure of free-living *Bradypus variegatus* sloths to pesticides, especially organophosphates. In the long term, chronic exposure can result in adverse effects such as decreased sperm quality and reduced bone formation. It is worth mentioning that carbamates can also produce effects similar to that of companion animals in wild animals, such as systemic congestive, however, no signs of carbamate poisoning were observed in macroscopy.

In two cases (11.11%), among the energies of a chemical order, the suspicion was death due to the administration of anaesthetics during a surgical procedure. The necropsy findings were nonspecific, represented by

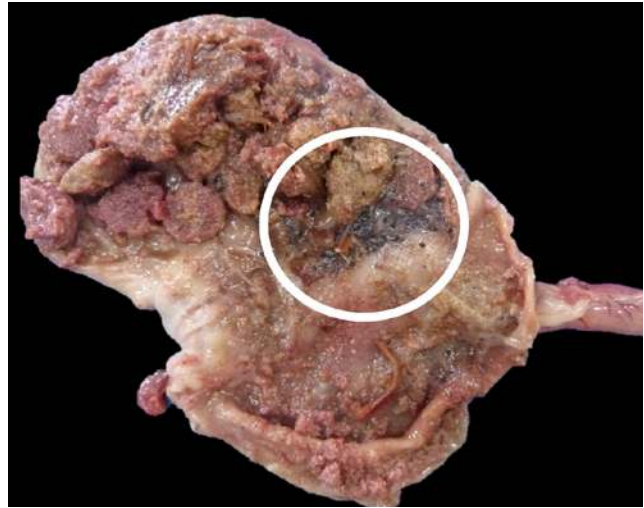


Figure 1. Feline, seven year old, female. Gastric content containing grayish granules (circle), embedded in intact and digested food fragments.

systemic congestive conditions associated with multifocal capillary haemorrhages. In this situation, necropsy aims to clarify pre-existing conditions, surgical, anaesthetic or diagnostic complications related to death. There are no known pathognomonic or even typical gross or histopathologic findings for anaesthesia related deaths, however, special techniques for investigating pneumothorax and venous gas embolism can be used (3, 9).

Also, some situations cannot be detected by post mortem examination, such as upper airway occlusion by soft palate or inappropriate intubation; acidosis by hyperventilation and cardiac conduction abnormalities (9).

Second, accounting six cases (18.18%), there are mechanical traumas, comprising only canines and felines. Regarding canines, in two the suspect was a blunt traumatic injury caused by human action, such as kicks and blows; in one case, the suspicion was trauma resulting from bathing and grooming in pet shops; and another of projectile injury.

Of the three cases related to blunt trauma caused by human action, macroscopic evidence was found in only one, represented by bilateral hyphema and haemorrhagic lesions on body and subcutaneous surfaces, especially in the cranial region, which are compatible with injuries caused by blunt instrument (Fig. 2A, 2B, 2C and 2D).

The animal was in a poor state of conservation, but there were no ruptures in internal organs. It was observed, predominantly, skin and muscle lesions. According to the literature, mechanical traumas caused by human action, especially blunt ones, have their identification impaired due to animal coat and, sometimes, due to skin colour. In addition, the animals have a reduced blood supply to the skin. The severity of the contusions depends on their extent, the force applied and the agent used, which can result in small skin lesions but with extensive injuries to internal organs (16). For this reason, the identification of these lesions is only possible,

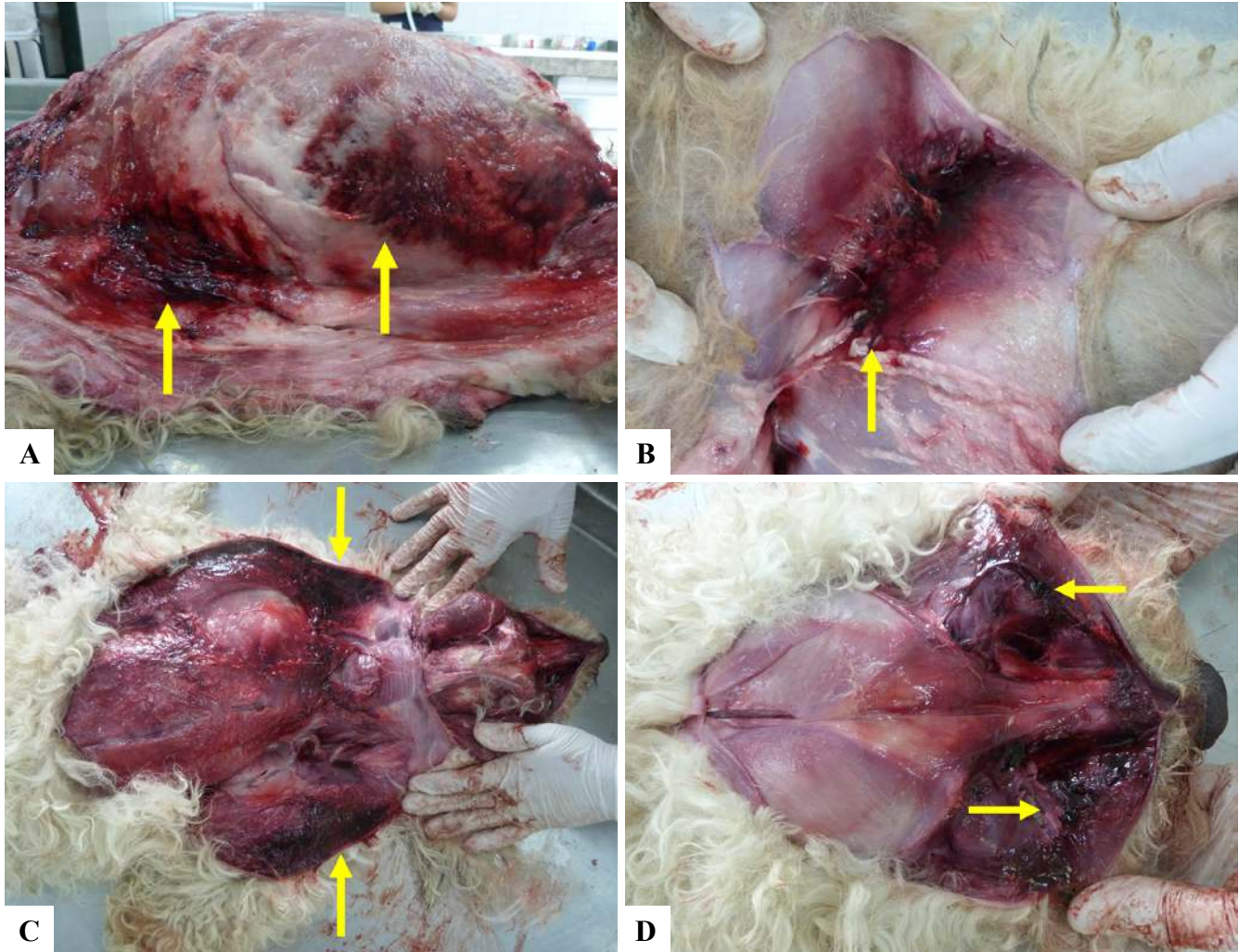


Figure 2. Canine, six year old, male. Extensive areas of dark red color throughout the animal's subcutaneous tissue. **A.** Ventral and lateral region. **B.** Inguinal region. **C.** Dorsal region. **D.** Nasal bone region extending to the maxillary and parietal region.

in most cases, during a necroscopic examination.

The animal with suspected trauma resulting from bathing and grooming in a pet shop was a 12-year-old canine, Poodle. According to Marlet and Maiorka (15), Poodle, Lhasa-apso, Yorkshire, Shih-tzu and Maltese breeds are the breeds that most show signs related to stressors in the bath and grooming environment and are also the breeds that most frequent these ambient. During the necropsy, there was also no evidence related to history.

In this animal, congestion of subcutaneous vessels, oedema and pulmonary congestion, liver congestion, endocardiosis and cardiac hypertrophy were observed. According to Marlet and Maiorka (15), during necropsy of animals with suspected injury or trauma in pet shops, oedema and pulmonary haemorrhage are frequently observed, similar to the animal in this study.

In the only case of firearm injury in this survey, an image examination (x-ray) was performed to check possible projectiles and its anatomical position. Two projectiles were identified, located in soft tissue and shrapnel, located in the

oral cavity (Fig. 3). It is recommended to perform imaging tests such as x-rays or tomography before the necropsy since it can provide undetectable information at the time of the necropsy (1).

There were three entry wounds, some of them with the projectile. One of the entry wounds was located in the frontal bone region close to the right eyeball, with triangular perforation, measuring approximately 1.2 x 0.5 cm, with an epilation area on the periphery of the perforation, with skin in this region of slightly blackish colouring (Fig. 4). The entry lesions have more precise edges and the diameter of the wound resembles that of the projectile, unlike the exit lesion, which has irregular edges and a larger diameter than the projectile (1).

In addition, the entry wounds may have blackish and sooty-coloured surroundings or an abrasion ring depends on the shooting distance. Usually, when the shooting is close to the body, the soot can be deposited on the animal, and the blackish colour is observed (1).

A second entry wound was located in the region of

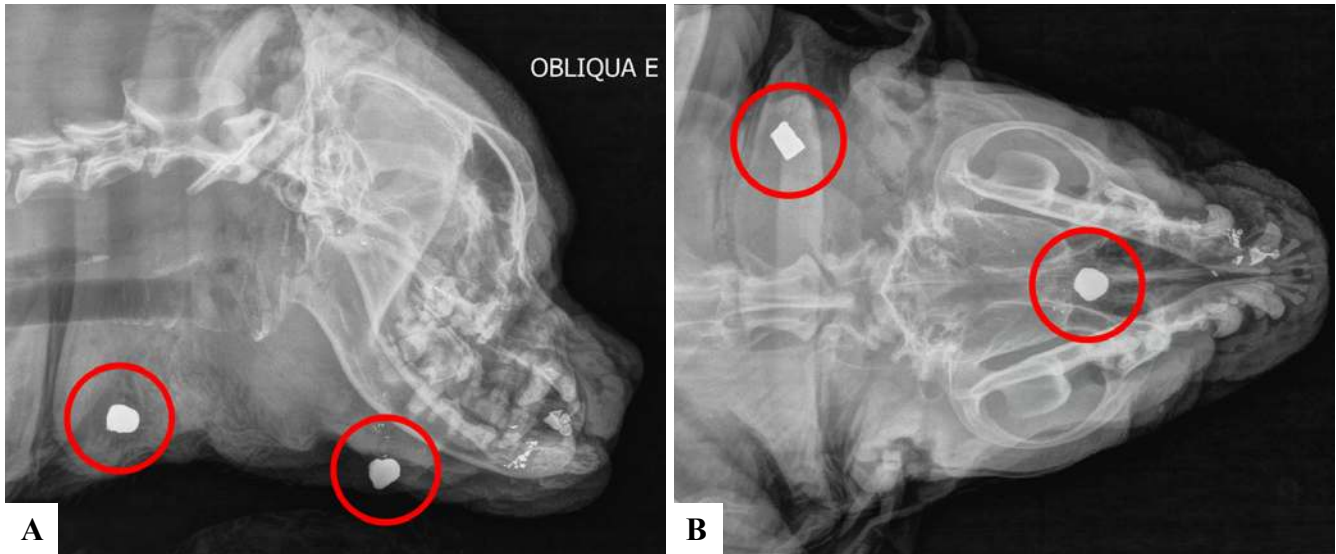


Figure 3. X-ray exam of the heard of a canine, five year old, male. **A.** Left side view of the cranial region showing radiopaque structures in soft ventral and rostral regions of the mandible, compatible with projectile shrapnel (red circle). **B.** Dorsoventral view showing the location of the projectiles (red circle).

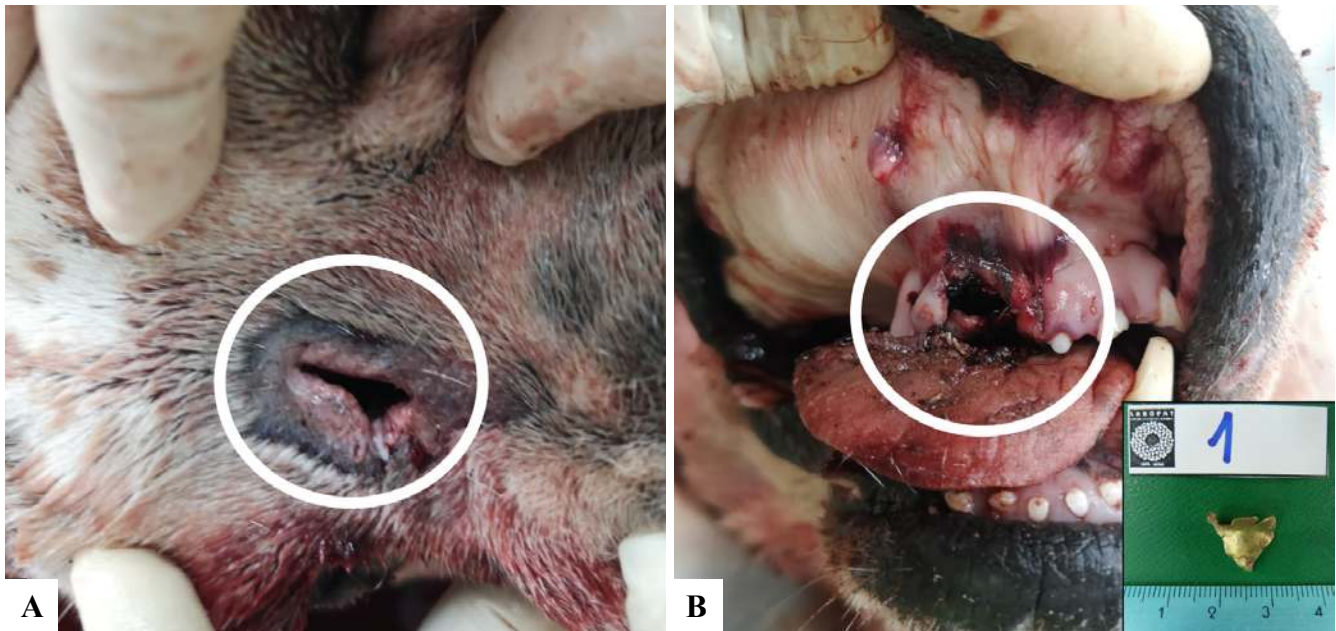


Figure 4. Canine, Five year old, male. **A.** Perforation of triangular shape in the frontal bone close to the right ocular globe, with epilation area on the periphery of the perforation, with skin in this region blackish coloured (entry wound) (white circle). **B.** Region of the oral mucosa of the right frontal maxillary region with a circular area with delimited edges and dark red colour, with the absence of incisor teeth and a projectile fragment (white circle).

the oral mucosa, right frontal jaw, showing a circular shape with delimited edges and dark red colour, with the absence of incisor teeth and the presence of a projectile fragment.

In the cervical ventral region, it was observed a perforation of slightly everted edges (exit wound) measuring 1.0 x 0.8 cm, with the presence of a projectile, also, there was leakage of bloody content (Fig. 5). The exit wound usually has irregular, everted edges and are larger than the size of the projectile, in addition, their shape can vary according to the

distance and speed that the projectile reaches the body (1).

Injuries caused by a firearm projectile are penetrating or perforation wound caused by instruments that have a mixed action, which act by piercing the tissues and at the same time causing blunt injuries around the perforation, haemorrhage and fractures (1, 24).

One of the main concerns of the society and public organs, due to the increase in violence. Ballistic injuries are often related to the uncontrolled use of firearms, especially by

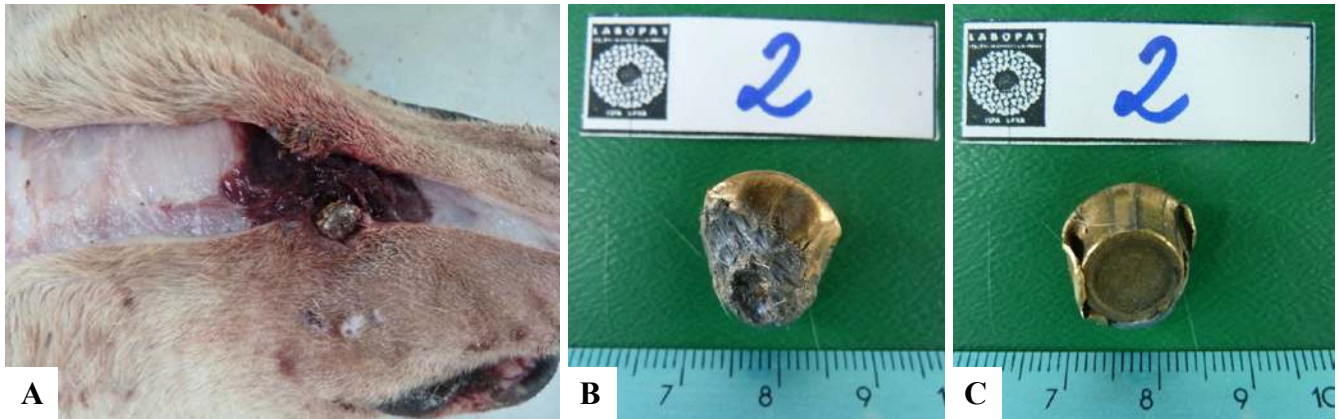


Figure 5. Canine, five year old, male. **A.** Ventral cervical subcutaneous tissue, showing a dark red lesion caused by a projectile. **B** and **C.** Dorsal and ventral view of the projectile.

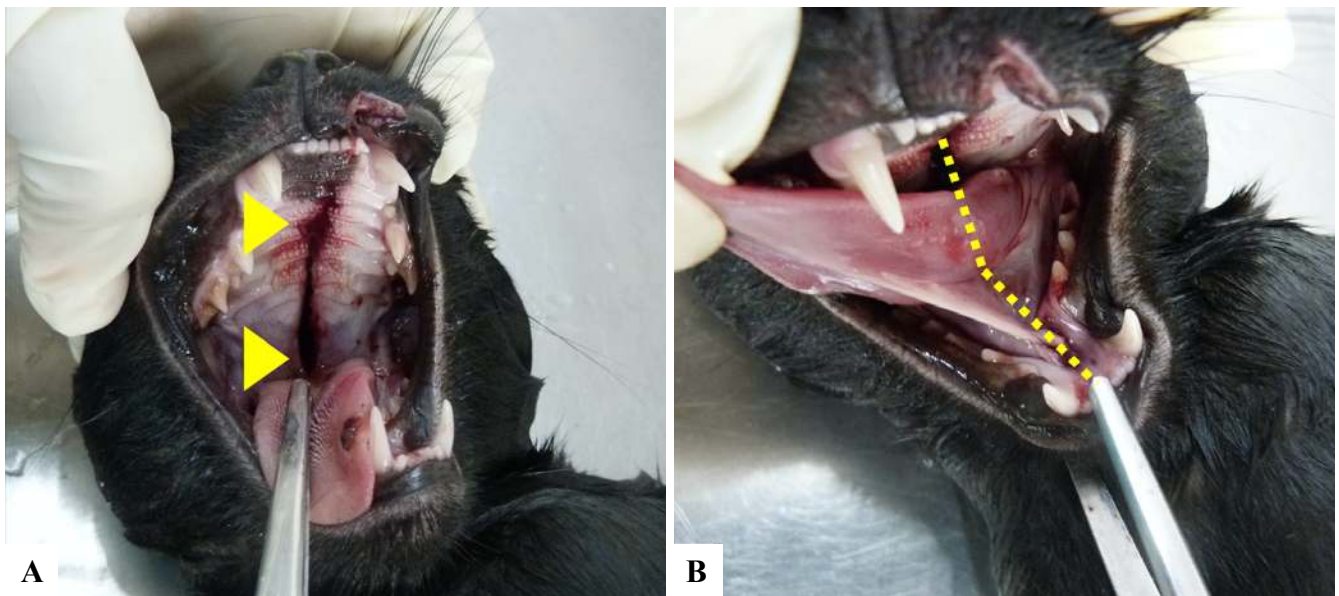

Figure 6. Feline, one year old, male. **A.** Linear wound in hard and soft palate associated with leakage of bloody content (arrowhead). **B.** Mandible shifted to the left side (segmented line).

the authorities who can carry them, or by the spread of violence and it usually results in death or euthanasia of animals. Also, animal behaviour is reported as a cause for this form of the lesion. Usually, the animals involved in projectile injuries are dogs, male, (20, 26), similar to the animal in this case.

Regarding felines, two cases were suspected, and in only one was found evidence of traumatic injuries, but not caused by human action, according to the reported history, which mentioned the suspicion of falling from the balcony of the fifth floor of a building.

Felines can move in the air during a fall and hit the ground in a way that reduces the effects of impact on the body, however, depending on the height of the fall, the lesions can be more or less serious, which is called “High-rise syndrome in cats”. This term is used to describe injuries suffered by cats that fall from windows or balconies of buildings and houses, with the minimum height of the fall being equivalent to two

floors (10, 29). In this case, it was reported that it had fallen from the fifth floor of the building, therefore, its movement in the air was compromised, resulting in a great impact.

The animal was a young feline, eight months old and the tutor reported that she had already witnessed similar situations with that animal. This behaviour is frequently observed in young animals, generally under the age of three years old, due to inexperience in the environment and the curious nature (10, 29).

At necropsy, a lesion was observed in the middle region of the hard and soft palate represented by a linear incision, regular and distant edges, associated with leakage of bloody content (Fig. 6A); in addition to the displacement of the mandible to the left and with crackling in the left branch (Fig. 6B), which are similar to those reported in the literature, where the lesions vary according to the height of the fall, however, in general, there is a fracture of the

palate, separation of the mandibular symphysis, mandibular fracture, dental fracture, pulmonary contusion, rib and vertebrae fracture and pneumothorax (10, 29).

Besides, multifocal, linear, superficial areas of hepatic rupture (Fig. 7) and splenic rupture were observed, the perirenal fat was dark red, especially on the left side, shiny surface, and in the cranial region, separation of cranial sutures with bone detachment (Fig. 8).

Of the 33 animals, only one case the suspicion was biodynamic energy and in the animal's history, death was associated with fireworks the previous day. Grossly, congestion was observed in subcutaneous vessels, epicardial vessels, hepatic, renal, lungs, and in intestinal serous and central nervous system vessels.

The lesions found were nonspecific, but are suggestive of distributive shock of the neurogenic type, since, according to the literature, it is associated with animals that have a history linked to stressful situations, fear or pain, sometimes prolonged, such as bathing in a pet shop, capture and fireworks. However, any situation that causes an emotional or physiological imbalance in animals can result in this type of disorder (5, 15, 25).

Conclusion

In this study, it was possible to conclude that the forensic necropsy associated with the animal's history, when available, is capable of providing relevant information regarding the *causa mortis*. It is important to highlight that the knowledge of other areas is fundamental, such as toxicology and imaging. Although the demand is still modest of judicial cases, it is changing over the years. The population is more concerned about animal rights, a fact confirmed by the media, where there are cases of cruelty that have national repercussions, increasingly highlighting the veterinarian as professional to act in these situations.

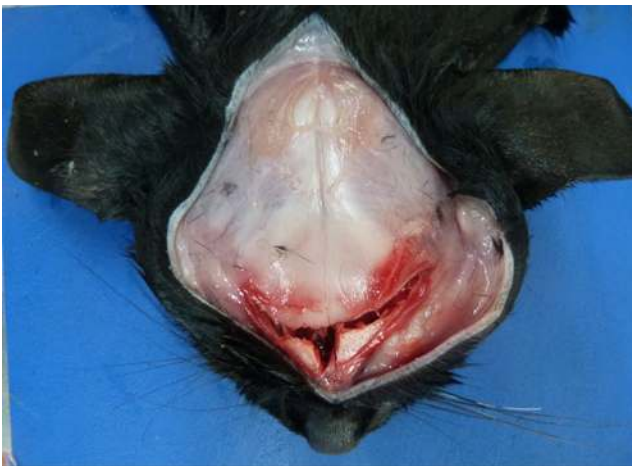

Figure 8. Feline, one year old, male. In the subcutaneous tissue, in the head region, separation of the frontonasal sutures was observed, with bone detachment.

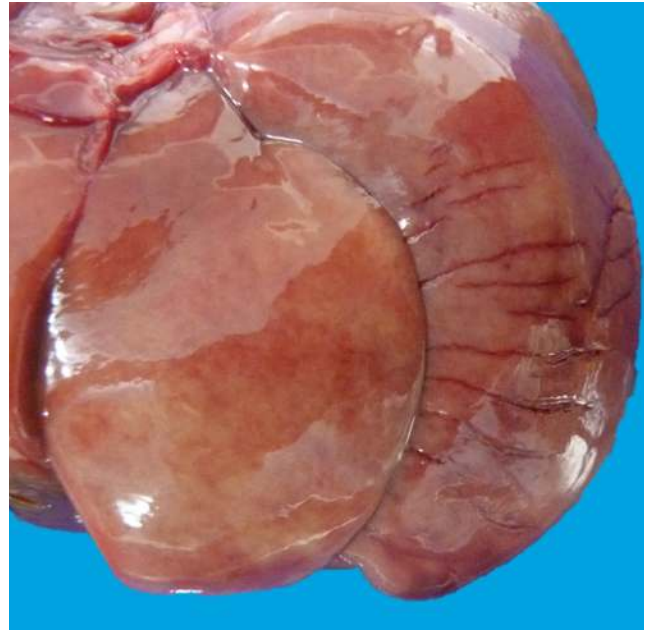


Figure 7. Feline, one year old, male. The liver appeared pale and with areas of linear rupture.

References

1. Bradley-siemens N, Brower AI. Veterinary Forensics: Firearms and Investigation of Projectile Injury. *Veterinary Pathology* 2016; 53(5):988-1000.
2. Branford MVP, Cruz EL, Solano K, Ramírez O. Pesticide exposure on sloths (*Bradypus variegatus* and *Choloepus hoffmanni*) in an agricultural landscape of Northeastern Costa Rica. *Journal of Environmental Biology*. 2013;35(1):29-34.
3. Brooks JW. *Veterinary Forensic Pathology. Volume 2.* Springer; 2018, p.89-95.
4. Brownlie HB, Munro R. The veterinary forensic necropsy: a review of procedures and protocols. *Veterinary pathology*. 2016;53(5):919-28.
5. Capilé KV, Lima MC, Fischer ML. Bioética ambiental: refletindo o uso de fogos de artifício e suas consequências para a fauna. *Revista Bioethikos - Centro Universitário São Camilo*. 2014;8(4):406-412.
6. CFMV – Conselho Federal de Medicina Veterinária. Resolução no 1138, de 16 de dezembro de 2016. Código de Ética do Médico Veterinário. Brasília: Diário Oficial da União, 2017. Disponível em: <http://www2.cfmv.gov.br/manual/arquivos/resolucao/1138.pdf>.
7. Cuevas SEC, Siqueira A, Lacerda AMD, Maiorka PC. Papel da patologia forense veterinária na investigação de óbito sob circunstâncias desconhecidas de um cão. *Revista de Educação Continuada em Medicina Veterinária e Zootecnia do CRMV-SP*. 2016;14(1):49.
8. Garcia R, Amaku M, Biondo AW, Ferreira F. Dog and cat population dynamics in an urban area: evaluation of a birth control strategy. *Pesquisa Veterinária Brasileira*. 2018;38(3):511-8.

9. Gerdin JA, Slater MR, Makolinski KV, Looney AL, Appel LD, Martin NM, McDonough SP. Post-Mortem Findings in 54 Cases of Anesthetic Associated Death in Cats from Two Spay - Neuter Programs in New York State. *Journal of feline medicine and surgery*. 2011;13(12):959-66.
10. Gheren MW, Jesus AC, Alves RS, Souza HJM. Síndrome da queda de grande altura em gatos: 43 casos atendidos no município do Rio de Janeiro. *Brazilian Journal of Veterinary Medicine*. 2017;39(3):182-189.
11. Gill HK, Garg H. Pesticide: environmental impacts and management strategies. In: Soloneski, S. *Pesticides-toxic aspects*. 201;8:187.
12. Klainbart S, Grabernik M, Kelmer E, Chai O, Cuneah O, Segev G, Aroch I. Clinical manifestations, laboratory findings, treatment and outcome of acute organophosphate or carbamate intoxication in 102 dogs: A retrospective study. *The Veterinary Journal*. 2019;251:105349.
13. Machado JC, Paixão RL. A representação do gato doméstico em diferentes contextos socioculturais e as conexões com a ética animal. *Revista Internacional Interdisciplinar INTERthesis*. 2014;11(1):231-53.
14. Maria ACBE, Siqueira A, Salvagni FA, Maiorka PC. Óbitos de cães e gatos durante procedimentos de banho e tosa: uma realidade pouco conhecida no Brasil. *Revista de Educação Continuada em Medicina Veterinária e Zootecnia do CRMV-SP*. 2015;13(3):24-9.
15. Marlet EF, Maiorka PC. Análise retrospectiva de casos de maus tratos contra cães e gatos na cidade de São Paulo. *Brazilian Journal of Veterinary Research Animal Science, São Paulo*. 2010;47, (5):385-394.
16. Merck MD. *Veterinary Forensics: Animal Cruelty Investigations*, 2nd Edition, Wiley- Blackwell; December 2012, 424p.
17. Moura EC, Gomes R, Falcão MT, Schwarz E, Neves AC, Santos W. Desigualdades de gênero na mortalidade por causas externas no Brasil, 2010. *Ciência & Saúde Coletiva*. 2015;20: 779-88.
18. Nolêto FFZ, Nolêto VAZ, Ribeiro MLC, Dias FRC, Silva DA. Perfil dos tutores de gatos e aspectos relacionados a sua criação. *Acta Biomedica Brasiliensia*. 2017;8(1):84-94.
19. Orsini HEO, Grandi F, Cagnini DQ. *Necropsia em animais domésticos, silvestres e de experimentação*. 1 edição. Vetschool São Paulo (SP) [s.n]; 2019. 334p.
20. Pachaly JR, Tramontin RS, Quessada AM, Belettini ST, de Paula DS, De Conti JB, Vasconcelos RD, Giovanelli DF, Voltarelli-Pachaly EM. Tratamento cirúrgico de lesões orais e faciais causadas por projétil balístico em cão da raça Pit Bull: relato de caso. *Brazilian Journal of Veterinary Medicine*. 2017;39(2):138-45.
21. Sabes AF, Giradi AM, Vasconcelos RO. Traumatologia forense: revisão de literatura. *Nucleus Animalium*. 2016; 8(2):2.
22. Salvagni FA, Siqueira A, Maria ACBE, Mesquita LP, Maiorka PC. Patologia veterinária forense: aplicação, aspectos técnicos e relevância em casos com potencial jurídico de óbito de animais. *Clínica Veterinária*. 2014L 58-72.
23. Sant'Ana LV; Reis STJ. A crueldade animal como possível indicador de violência doméstica. De que forma a medicina veterinária pode contribuir? *Medvep - Revista Científica de Medicina Veterinária - Pequenos Animais e Animais de Estimação*. 2020;15(46); 79-86.
24. Silveira PR. *Fundamentos da medicina legal*. 5 edição. Livraria e Editora Lumen Juris Ltda, Rio de Janeiro, 2015. 638p.
25. Standl T, Annecke T, Cascorbi I, Heller AR, Sabashnikov A, Teske W. The nomenclature, definition and distinction of types of shock. *Deutsches Ärzteblatt International*. 2018;115(45):757.
26. Tanrisever M, Karabulut E, Canpolat I. The clinical and radiological evaluation of firearm injuries in dogs. *IOSR-JAVS*. 2017;10:58-62.
27. Tostes RA, Reis STJ, Castilho VV. *Tratado de Medicina Veterinária Legal*. Curitiba, MedVep, 2017. 420p.
28. Tremori TM, Reis STJ, Massad MRR, Ribas LM, Florez LMM, Rocha NS. Achados necroscópicos em cães e gatos vítimas de intoxicação exógena. *Revista Brasileira de Ciências Veterinárias*. 2018;25(1):17-21.
29. Zaghoul AE, Samy A. High Rise Syndrome: A Correlation Between Height And Affections In 45 Cats From Urban Areas. *Alexandria Journal for Veterinary Sciences*. 2018;59(2):43-48.