



Case Report

A dicephalus calf: anatomical, pathological and radiographic aspects

Lorena S. Ribeiro¹, Múcio F. F. Mendonça², Ana Caroline S. N. Souza², Marcela P. R. Pinto², Antonio W. O. Silva², Caterina Muramoto³, Caio Biasi³, Vitor S. Carvalho⁴, Paula V. Leal³, Tiago C. Peixoto^{3*}.

¹Programa de Residência em Patologia Veterinária, Escola de Medicina Veterinária e Zootecnia (EMEVZ), Universidade Federal da Bahia (UFBA), Salvador, BA, Brazil.

²Programa de Pós-graduação em Ciência Animal nos Trópicos (PPGCAT), UFBA.

³Departamento de Anatomia, Patologia e Clínicas Veterinárias, EMEVZ/UFBA.

⁴Centro de Desenvolvimento da Pecuária, EMEVZ/UFBA, Santo Amaro, BA, Brazil.

*Corresponding author: Tiago C. Peixoto, Universidade Federal da Bahia (UFBA), Av. Adhemar de Barros 500, Salvador, BA 40170-110, Brazil. Email: tpeixoto@ufba.br

Submitted September, 09th 2020, Accepted December, 29th 2020

Abstract

Congenital malformations are morphofunctional abnormalities of tissues and organs that can occur during embryonic or fetal development in all animal species. Among these, dicephalus is characterized by the development of an individual with two heads and two necks, due to the total duplication of facial, cranial, and brain structures. Reports of dicephalus in cattle are scarce and do not normally emphasize radiographic and bone anatomy characteristics. The objective was to describe a case of a stillborn dicephalus calf. The duplication of the head, brain, neck, and two thoracic vertebral columns, isolated from each other, with 13 vertebrae each was verified radiographically. There were 13 pairs of ribs, the ones on the right side articulated with the thoracic spine on the right and the left ones with the spine on the left. Caudally at T13, there was only one lumbar spine, sacral and coccygeal. In the ventrodorsal projection, L1, L2, L3, and L6 had the shape of a butterfly (suggestive of hemivertebrae). At necropsy, in addition to craniocervical and spinal morphological changes, collapsed lungs, duplication of the heart with anastomosis between the aortic arches of the hearts, and duplication of the upper digestive tract were observed. Additionally, there was arthrogyriposis of the pelvic limbs. Corpse maceration, followed by the skeletal assembly, showed the bone changes previously observed and confirmed the suspicion of hemivertebrae.

Key words: congenital malformation, Siamese twins, radiography, ruminant.

Introduction

Congenital malformations are morphofunctional abnormalities of tissues and organs that can occur during embryonic and / or fetal development in all animal species. Part of these abnormalities compromises the individual's life, causes reproductive losses (abortion) or neonatal death (6, 19, 21). These disorders can occur due to intrinsic (genetic), extrinsic (infectious, toxic, mechanical and nutrient deficiency) factors, by the combination of both, or even without a known cause and sporadically, as is the case of dicephalus (5, 21).

It is estimated that the worldwide prevalence of congenital malformations in cattle herds is 0.2% to 3.0% (13). However, in Brazil, in a study carried out in Rio Grande do Sul, the frequency of malformations observed in a bovine herd was 4.28% (48/1,121), over 31 years (15). In a similar study, conducted in the northeastern semiarid region, the frequency of these malformations was 3.22% (14/434) in an eight-year period (6).

Dicephalus is a malformation that can be classified as complete or incomplete. In the first case, the animal has a double head, neck, brain, and spinal cord. In the second, there is only craniofacial duplicity, and it is also called diprosopia (17).

Dicephalus develops during the embryological phase, in which the formation of primitive germ layers and rudiments of organs occurs. In this stage, cell growth and differentiation are in high activity, being more susceptible to teratogens. When there is an abnormal duplication of the neural plaques, with subsequent formation of partially or completely duplicated neural ridges, the facial structures are formed twice (4).

Anatomical and radiographic descriptions of congenital malformations in farm animals are uncommon and, in the literature consulted, only two cases of bovine dicephalus address the radiographic aspects of this disease (20, 26). The other few existing studies deal only with the necropsy findings of the affected animal (2, 6, 12, 15).

The objective was to report a case of complete dicephalus in a bovine in the state of Bahia, describing anatomical, radiographic, and pathological aspects.

Case Report

In September 2018, a stillborn crossbred calf, with about 50kg and 46.2cm in length from the neck to the sacrum (Fig. 1), from eutocic birth in the municipality of Santo Amaro, BA, who exhibited evident anatomical malformations, mainly in the head, neck and pelvic limbs, was referred to the Veterinary Pathology Laboratory of Federal University of Bahia (LPV-UFBA), for diagnostic investigation.

According to history, the progenitor cow was crossbred, primiparous and, raised extensively in pastures formed by *Brachiaria decumbens*. Fertilization occurred naturally and there was no history of malformations on the farm.

Before the necropsy, the corpse was referred to the radiology service of the Veterinary Hospital of UFBA for radiographic study. Laterolateral and ventrodorsal radiographs of the head, chest and abdomen were performed (Fig. 2).

The analysis of radiographic images allowed the identification of two skulls with normal conformations, opacification of the frontal sinuses and nasal cavities with just a very small amount of gas content. In each cervical region, seven vertebrae, atlas without fusion of the ventral tubercle, soft tissues corresponding to the neck with normal appearance and no visualization of the tracheal lumen were observed. Two thoracic vertebral columns, isolated from each other, were identified, with 13 thoracic vertebrae each, but with intimate contact between the both T13 vertebral bodies, which were separated only by a thin radiolucent line. There were 13 pairs of ribs, the right and the left articulated with the respective ipsilateral thoracic vertebrae.

A supernumerary rib was identified in-between the two thoracic columns in the ventrodorsal view, apparently articulated with the first left thoracic vertebra and cranially projected, towards the right neck. The spinous processes of the 3rd, 4th, and 5th left thoracic vertebrae were fused.



Figure 1. A stillborn complete dicephalus calf associated with arthrogryposis of the pelvic limbs.

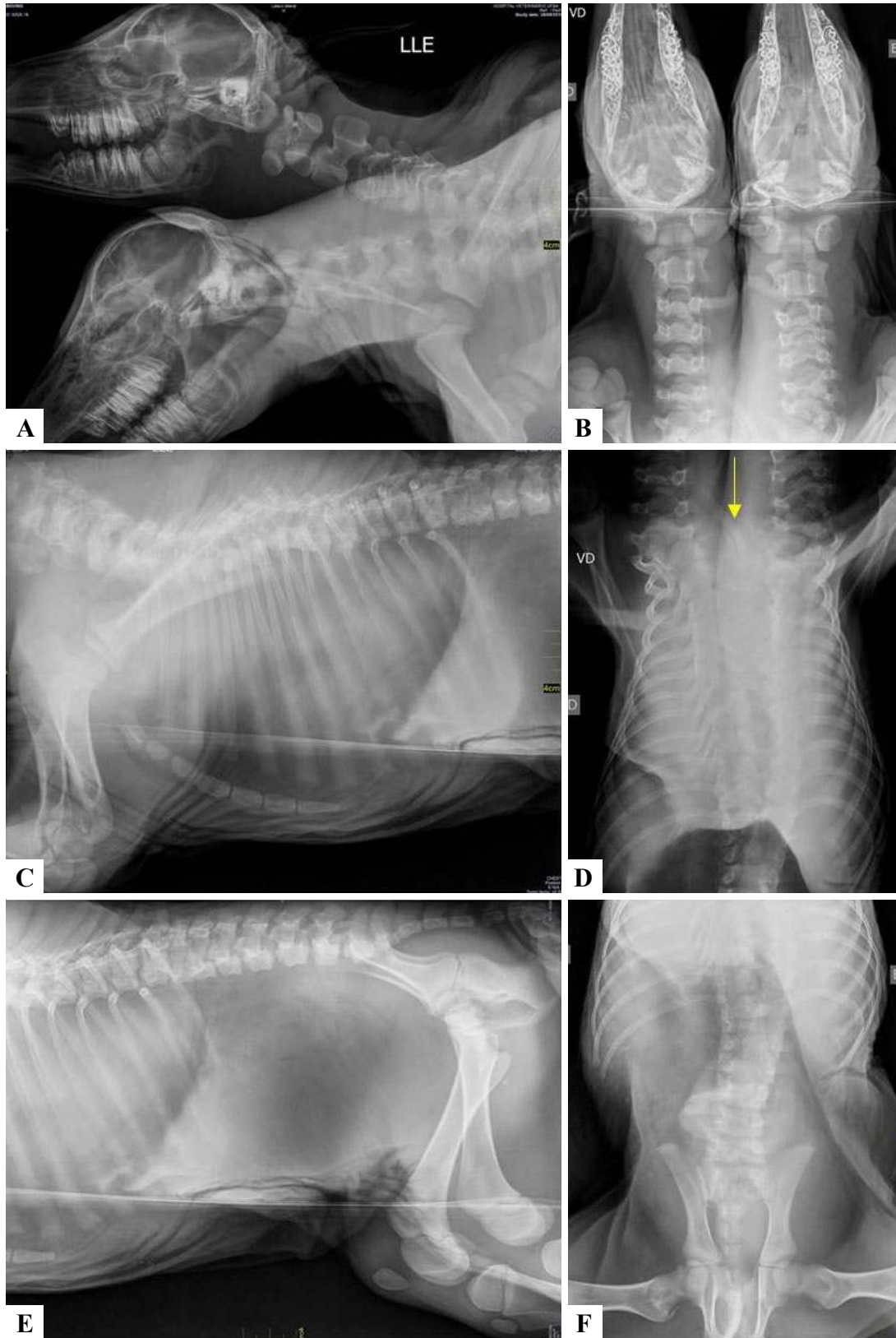


Figure 2. Radiographic images of the corpse of the dicephalus calf in laterolateral (LL) and ventrodorsal (VD) views of the neck and head (A and B, respectively), thoracic region (C and D) and abdominal and pelvic regions (E and F). In A and B the head and neck duplications are evident. In C and D: thirteen thoracic vertebrae and 13 pairs of ribs and a supernumerary rib in-between the two thoracic columns (yellow arrow). In E and F: six lumbar vertebrae, some with butterfly shape and homogeneity of thoracic and abdominal cavities.

Caudally to the T13, apparently, there was only one lumbar, sacral, and coccygeal spine, corresponding to the spine of a single individual. However, it was not possible to affirm with certainty, by radiographic evaluation, where was the real point from which the spine becomes common for both individuals, either because of the overlapping of structures, which is characteristic of the radiographic images, or because of the malformation of the vertebrae itself, especially in the thoracolumbar transition. The lumbar spine consisted of six vertebrae. Between L1 and L2 the intervertebral space was very narrow. In ventrodorsal view, L1, L3 and L6 had butterfly-shaped, an alteration suggestive of the hemivertebra. It was also observed that the sacral vertebrae were not fused and there were at least nine caudal vertebrae, in addition to the narrowing of the pelvic canal due to deformity of the hip bone. The thoracic and abdominal cavities had homogeneous and diffuse soft tissue radiographic opacity, and it was impossible to delimit the diaphragm and any organs in those cavities

After the radiographic examination, the corpse was submitted to necropsy in the LPV - UFBA. There was duplicity of the head, necks, and spine, united by the fusion between the last thoracic vertebrae and the first lumbar vertebra. Each head had two ears, two eyes, a nostril and a mouth, structures similar in size to those contralateral and normal for the species. The animal had a pair of thoracic and pelvic limbs, with the latter showing marked shortening of the tendons with consequently marked arthrogyrosis (Fig. 3A).

In the thoracic cavity, two collapsed lungs with irregular margins were observed. There was a diaphragmatic hernia in the right antimere, with an 8.0cm diameter hernial orifice, through which the duplicated pre-stomachs were displaced into the thoracic cavity (Fig. 3B), leading to the cranial positioning of the pericardial sac that contained two hearts.

The heart that was displaced to the left antimere had an ascending aorta, aortic arch, and thoracic and abdominal aorta, while the contralateral heart had an incomplete aorta, containing only the ascending aorta and aortic arch. Cardiac duplicity led to the development of anastomosis between the aortic arches of the hearts. Incomplete development of the first rib was also noted in the medial region of the right thoracic spine.

The development of the tongue, pharynx, larynx, trachea, and esophagus was normal in both heads and necks (Fig. 3C). In the abdominal cavity, the abomasum (Fig. 3D) was connected to the small intestine, which was unique until the final portion of the smaller colon, rectum, and anus, which were also unique. The liver did not have the normal lobation for the species, still containing areas of capsular fibrosis and gallbladder duplication.

After necropsy, the skeleton was subjected to mechanical maceration, bleaching with 10% hydrogen peroxide, degreasing, assembly, and bone fixation. The macroscopic evaluation of the skeletal structure allowed to verify some details, not previously seen by radiographic and necroscopic examinations (Fig. 4 and 5). There was a small amorphous bone located between the right and left spine,

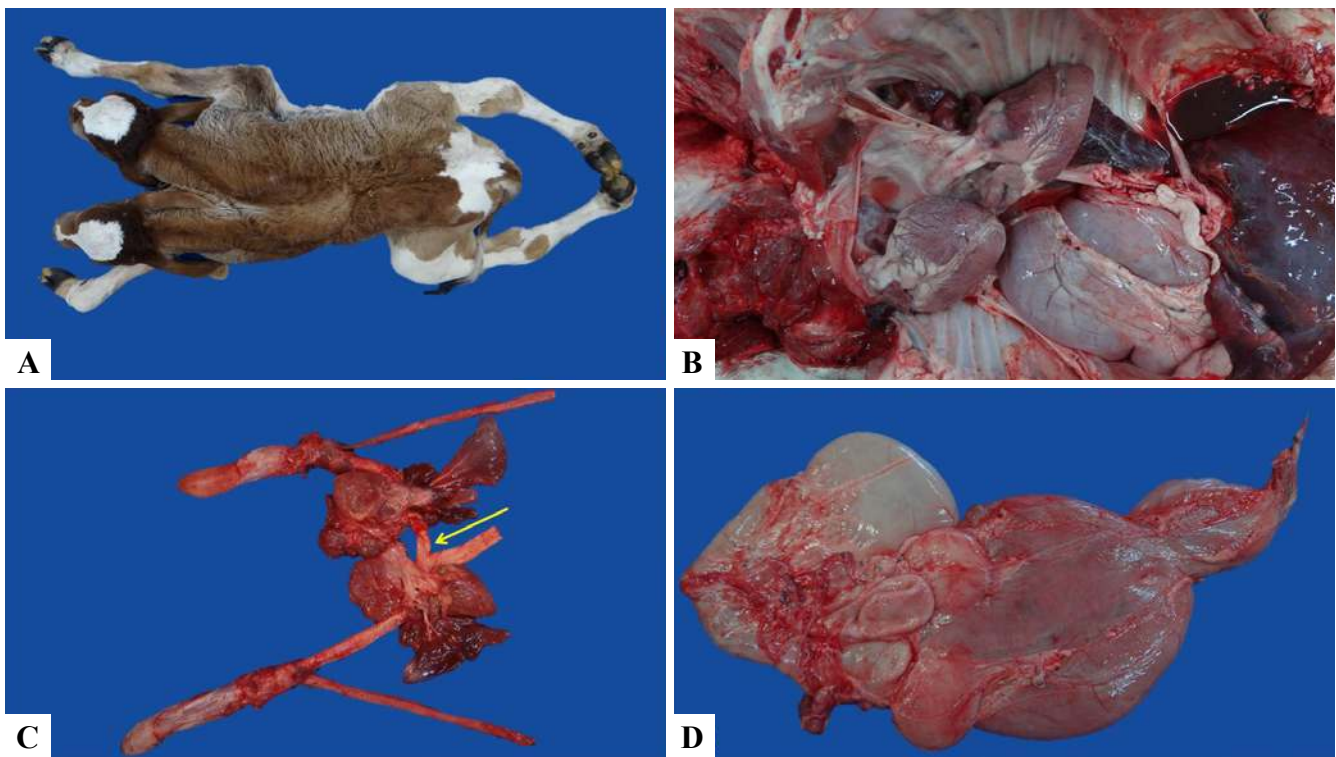


Figure 3. A stillborn dicephalus calf. **A.** Dorsal view, showing two separate heads and two necks. **B.** Wide chest cavity containing two hearts, collapsed lungs, and immature, herniated, and duplicated pre-stomachs. **C.** Block identifying duplication of the tongue, esophagus, and heart. Aorto-aortic anastomosis between the aortic arches of the hearts (arrow). **D.** Duplicated pre-stomachs and single abomasum.

adjacent to T13 and L1. The bodies of each lumbar vertebra were two separate components close together, each with one transverse process on its lateral surface. There was aplasia or hypoplasia on the medial surfaces of malformed lumbar vertebral bodies, characterizing them as hemivertebrae. In addition, each component of the lumbar vertebrae had one spinous process, directed medially, and the sacral vertebrae, not fused together, had a single body but two spinous process, also toward medially. Unfortunately, the spinal cord was not evaluated because in order to allow skeleton reconstruction after maceration, it was decided not to saw the spine.

Discussion

The diagnosis of complete dicephalus was established based on radiographic and anatomopathological findings, which showed the presence of two well-defined heads and two brains in a stillborn calf in the state of Bahia.

In Brazil, studies carried out in Paraíba (6), Bahia (20) and Rio Grande do Sul (10) have shown that bovine dicephalus occurs sporadically and that its etiology cannot yet be associated with known teratogenic agents. In fact, in the present case, the etiology has not been determined.

The cases of dicephalus in cattle described in Paraíba (6), Rio Grande do Sul (15) and in the Bahia (20), had two heads completely separate, with two encephala and two vertebral columns, however, the concomitant occurrence of arthrogryposis was not observed, as described in the present case. It should be noted that arthrogryposis is a congenital malformation commonly seen in cattle and small ruminants in the Bahian semiarid, however, this anomaly is frequently associated with the ingestion of *Mimosa tenuiflora* and dicephalus has not been reported among the malformations induced by the plant (6, 18).

In the present case, the occurrence of congenital malformations associated with the ingestion of toxic (teratogenic) plants was ruled out due to their absence in

the pastures where the animals were kept. Two cases of dicephalus associated with arthrogryposis of the pelvic limbs described in India (12) and in Paraguay (2), which were also not associated with ingestion of *M. tenuiflora* or any other species known to be teratogenic, corroborate this hypothesis.

The radiographic, anatomical and pathological findings described here were, in part, similar to those observed in a bovine dicephalic fetus, in which there were duplicate heads, necks and organs of the cardiac and digestive systems, save for the rumen, abomasum, and intestines (20). However, it is noteworthy that, in this report, the spinal fusion site was not determined, although it appears to become unique between T13 and L1 at the radiographic examination. We believe that during the maceration process there may have been a separation of bone structures, previously attached by soft/cartilage tissues, which prevents us from claiming that the lumbar vertebral bodies were double, in fact, or unique and just not fused. It is more likely that there are two malformed lumbar columns, since there were two spinous processes and, thus, the bovine spine of this study would become unique only at the level of the sacrum, as in the siamese twins described in a previous report (20).

On the other hand, in Japan, was observed radiographically the vertebral fusion of a two-headed bovine in the second cervical vertebra. In this way, the animal had two completely separate heads, but two incomplete necks (26).

It is known that fetuses with congenital malformations, including dicephalus, often lead to dystocic births (22), since Siamese twins tend to be anatomically larger and disproportionate. The incompatibility between fetal size and the birth canal is the most common cause of bovine dystocia, and in most cases, surgical intervention is necessary, given the risk of death of the cow and fetus (3). It was reported in India the occurrence of dystocia of fetal origin, due to the large size of a stillborn Jersey bovine fetus, which had total duplication of the head and neck. Complications of this nature were not observed in the present case (8).

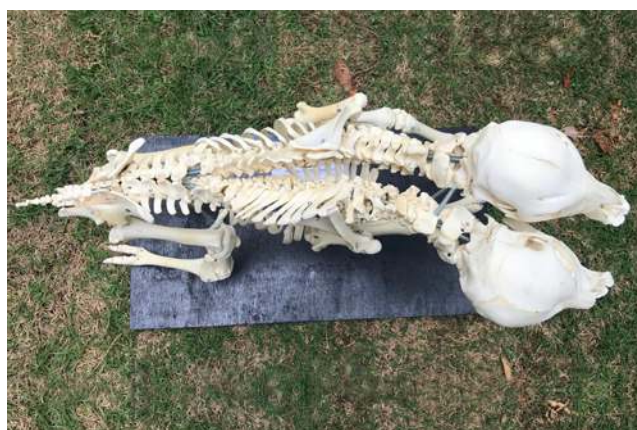

Figure 4. Dorsal view of the skeleton of the assembled double-headed calf. Duplication of the head, neck, cervical and thoracic spine with T13 - L1 fusion. Note that caudally at T13 there is only one lumbar, sacral, and caudal spine.



Figure 5. Two-headed bovine skeleton after maceration and assembly. Note two separate heads and two necks, a single rib cage, and marked arthrogryposis in the pelvic limbs.

Additionally, other concomitant congenital malformations have been documented here, such as arthrogryposis of the pelvic limbs and the non-closure of the diaphragmatic muscles in the right antimere, which resulted in herniation of the pre-stomachs to the thoracic cavity (congenital diaphragmatic hernia). The death of the newborn calf probably occurred due to perinatal asphyxia secondary to this malformation. This hypothesis corroborates the macroscopic changes observed during necropsy, in particular, pulmonary compression caused by herniated abdominal viscera and the absence of pulmonary distension (negative hydrostatic docimasia test).

Thus, it can be concluded that, in the present case, it is a stillborn dicephalic calf. This justifies the lack of visualization of some organs by radiographic examination, due to the lack of contrast between the overlapping structures (absence of air in the respiratory tract and in the digestive tract).

Regarding complete and incomplete dicephalus (diprosopus), some considerations are necessary. In the literature, cases of diprosopus (7, 9, 14, 19, 24) are more often reported than complete dicephalus (2, 6, 12, 15). This finding had already been observed in the 1980s, indicating that diprosopus is about three times more common than complete dicephalus (16). Although, to date, there is no justification for this difference, it is known that fetuses exposed to teratogenic agents during the initial stage of development have more severe malformations, because it is at this stage that the formation of embryonic organs and systems occurs (23).

Two cases of diprosopus in cattle have already been reported, which were stillborn or fetuses and survived for a few days until they were subjected to euthanasia. Therefore, diprosopus are more likely to survive (1,9).

Cardiac alterations can be observed in dicephalus animals, such as multiple chambers, large and/or duplicated vessels, interruption of the aorta, supernumerary aorta, and interventricular septal defect (20). In the present case, there was complete development of the aorta of the left heart and incomplete contralateral aorta, associated with aortic anastomosis due to cardiac duplication. Among the cases described in the literature, two hearts have been mentioned. Additionally, describe dextroposition of the aorta of the right heart (20). Such anatomical differences may contribute to a better understanding of the etiology of these malformations in the future (20).

In this context, double-headed animals with two thoracic limbs associated with duplication of the heart is not a common finding, since the incidence of cardiac duplication is correlated with extra-numerical thoracic limbs (25). This correlation was not evidenced in the present study, since the calf had duplicate hearts, but only one pair of thoracic limbs.

The analysis and correlation of the epidemiological data of the regions with the occurrence of malformation cases are essential to verify possible genetic or environmental influences (6). However, the etiology for dicephalus occurrence and other concomitant malformations were not

assessed in the present case.

The etiology remains unknown due to the small number of cases described so far. On the other hand, the occurrence of congenital anomalies, such as dicephalus in cattle, buffaloes and small ruminants, may be associated with viral infections (transplacental), as well as exposure to toxic substances ingested by the mother, vitamin A deficiency, and folic acid (11).

References

1. Araújo KF. Diprosopia incompleta com inversão ventral do cerebelo em um bovino. Fundação Universidade Federal de Rondônia, Curso de Medicina Veterinária. 38f. 2019.
2. Bertoli G, Mendes JP, Filadelpho AL, Guazzelli Filho J, Silva JRCP, Schimming BC, Peres JA, Barcelos RP. Dicefalia em bovino: relato de caso. *Rev Cient Med Vet.* 2014;23(2):1-11.
3. Borges MCB, Costa JN, Ferreira MM, Menezes RV, Chalhoub M. Caracterização das distocias atendidas no período de 1985 a 2003 na Clínica de Bovinos da Escola de Medicina Veterinária da Universidade Federal da Bahia. *Rev Bras Saude Prod Anim.* 2006;7(2):87-93.
4. Carles D, Weichhold W, Alberti EM, Leger F, Pigeau F, Horovitz J. Diprosopia revisited in light of the recognized role of neural crest cells in facial development. *J Cran Gen Dev Biol.* 1995;15(2):90-97.
5. Constable PD, Hinchcliff KW, Done HS, Grunberg W. *Veterinary Medicine: a textbook of the diseases of cattle, horses, sheep, pigs and goats.* Philadelphia: Saunders Elsevier; 2016.
6. Dantas AFM, Riet-Correa F, Medeiros RMT, Galiza GJN, Pimentel LA, Anjos B, Mota RA. Malformações congênitas em ruminantes no semiárido do Nordeste Brasileiro. *Pesq Vet Bras.* 2010;30(10):807-815.
7. Díaz PC, Ramírez W, Wilson D. Reporte de un caso de bicefalia en bovino. *Rev El Vet.* 2009;10(6):1-3.
8. Dutt R, Arjun V, Hariom, Singh G. Dystocia due to dicephalic fetus in a cross bred Jersey cow. *Inter J Agr Sci.* 2019;11(10):8509-8510.
9. Echeto OV, Morillo MA, Oviedom ORV, Alvarado CMA, Bracho JEC, Orozco EEF. Duplicidad parcial cefalica facial (diprosopia) en bovinos: estudio clínico patológico de un caso. *Rev Cient Uni Zulia.* 2004;14(4):338-343.
10. Gularte F, Gularte FDA, Rosa GTV, Rassier JA, Soares GG, Salla PF. Dicefalia em feto bovino: relato de caso. *Anais Salão Inter Ensino, Pesq Ext.* 2020;11(2).
11. Jones TC, Hunt RD, King NW. *Veterinary Pathology*, 6th ed. São Paulo: Manole; 2000. 1415p.
12. Katyiar R, Khan FA, Khan MM, Sachan SSD, Sachan SP, Gupta HP. Dystocia due to dicephalus monster with kyphosis and arthrogryposis in a cross bred cow - a case report. *Inter J Liv Res.* 2015;5(6):64-66.

13. Leipold HW, Dennis SM. Congenital defects affecting bovine reproduction. In: Morrow DA, editor. Current Therapy in Theriogenology: diagnosis, treatment and prevention on reproductive diseases in small and large animals. Philadelphia: WB Saunders Company; 1986. p. 177-199.
14. Macêdo JTSA, Lucena RB, Giaretta PR, Kommers GD, Figuera RA, Irigoyen LF, Barros CSL. Defeitos congênitos em bovinos da Região Central do Rio Grande do Sul. *Pesq Vet Bras.* 2011;31(4):297-306.
15. Marcolongo-Pereira C, Schild AL, Soares MP, Vargas Jr SF, Riet-Correa F. Defeitos congênitos diagnosticados em ruminantes na Região Sul do Rio Grande do Sul. *Pesq Vet Bras.* 2010;30(10):816-826.
16. McGirr WJ, Partlow GD, Fisher KRS. Two-headed, two-necked conjoined twin calf with partial duplication of thoracoabdominal structures: role of blastocyst hatching. *Anat Rec.* 1987;217(2):196-202.
17. Pacheco AM, Hamzé AL, Resende HRA, Birck AJ, Zappa V, Filadelpho AL. Dicefalia bovina: revisão de literatura. *Rev Cient Elet Med Vet.* 2009;12(1):1-4.
18. Pimentel LA, Riet-Correa F, Gardner D, Panter KE, Dantas AFM, Medeiros RMT, Mota RA, Araújo JAS. *Mimosa tenuiflora* as a cause of malformations in ruminants in the Northeastern Brazilian semiarid rangelands. *Vet Pathol.* 2007;44(6):928-931.
19. Rotta IT, Torres MBAM, Motta RG. Diprosopia em bovino. *Arq Bras Med Vet Zootec.* 2008;60(2):489-491.
20. Santos MC, Azevedo ZFT, Pereira AL, Lacerda MSC, Silva ARS, Pedroso PMO, Macêdo JTSA. Dicefalia em Bovino. *Acta Sci Vet.* 2016;44(Suppl. 1):151.
21. Schild AL. Defeitos congênitos. In: Riet-Correa F, Schild AL, Lemos RAA, Borges JRJ, editor. *Doenças de Ruminantes e Equídeos*. Santa Maria: Vicente Pallotti; 2007. p. 25-55.
22. Silva Filho AP, Souto RJC, Costa NA, Souza JCA, Coutinho LT, Silva NAA, Afonso JAB. Monstros fetais como causa de distocia em vacas. *Rev Bras Cien Vet.* 2015;22(2):81-84.
23. Sobestiansky J, Barcelos D. *Doenças de suínos*. Goiânia: Cãnone Editorial; 2012. 959p.
24. Spadetto RM, Dias AS. Diprosopia em bezerro - relato de caso. *Acta Vet Bras.* 2012;6(4):325-328.
25. Spencer R. *Conjoined Twins: developmental malformations and clinical implications*. Johns Hopkins University Press. 2003, 496p.
26. Wakuri H, Mori T, Mutoh K. Arnold-Chiari malformation and associated anomalies in a dicephalic newborn calf. *Okaj Fol Anat Jap.* 1990;67(5):339-350.