



Short Communication

Apoptosis detection in embryonic chicken lymphoid tissues infected with attenuated very virulent infectious bursal disease virus (vvIBDV)

Ane F. Tapparo¹, Deriane E. Gomes¹, Camila Silva²,
Heitor F. Ferrari², Maria C. R. Luvizotto², Tereza C. Cardoso^{2*}

¹Graduate student in Microbiology, IBILCE, Unesp, São José do Rio Preto - SP, Brazil

²University of São Paulo State, Unesp, Araçatuba - SP, Brazil

*Corresponding author: Tereza C. Cardoso, Laboratory of Animal Virology and Animal Pathology, Veterinary School, Unesp, Rua Clóvis Pestana, 793, Araçatuba, 16050-680, São Paulo, Brazil. E-mail: tcardoso@fmva.unesp.br

Submitted April 15th 2009, Accepted June 1st 2009

Abstract

We exposed chicken embryos at embryonating day (ED18) to a cell-adapted very virulent strain of IBDV (ca-vvIBDV) and original vvIBDV and examined the apoptosis from infected bursa of Fabricius (BF) and thymus organs. Following ca-vvIBDV exposure, embryonic bursa showed mild cellular destruction, lower rate of apoptosis and presence of viral proteins detectable by immunohistochemistry. In contrary, original vvIBDV exposed embryos had an enhanced detectable changes in the bursa associated to an increase apoptotic events, and most of the times, total destruction of BF follicles. In thymus, viral antigen was detectable until after hatch. Positives cell signals to activated *caspase-3* were intensively detect in embryos lymphoid tissues exposed to original vvIBDV observed in BF and less in thymus. No immunoreactive thymocytes were visualized in embryos exposed to ca-vvIBDV. Apoptosis changes, such as chromatin condensation, DNA fragmentation, and the appearance of apoptotic nuclear bodies, were observed in both organs. TUNEL-detected DNA was more intense in original vvIBDV infected lymphoid cells, and less apoptotic cells were detectable in attenuated strain. By sequencing analysis, the attenuation presented amino acid changes at position 222 (A→P), 256 (I→V) and 279 (D→N). One serine in the serine-rich heptapeptide (position 333) was substituted into other amino acid which is similar to the IBDV vaccine strain. Taken together our results indicate that virus attenuation interferes with *caspase-3* apoptotic pathway and may play an important role in switch viral pathogenesis.

Key Words: IBDV, activated *caspase-3*, apoptosis

Introduction

Infectious bursal disease virus (IBDV), member of the *Avibirnavirus* genus of the *Birnaviridae* family, is the causative agent of infectious bursal disease (IBD). Since IBDV was first isolated in the town of Gumboro, Delaware, USA in 1957, it has caused serious sanitary problems worldwide. The disease is characterized by destruction of the lymphoid cells in the bursa of Fabricius (BF), which leads to severe B-cell suppression (8).

Infectious bursal disease virus (IBDV) belongs to *Avibirnavirus* genus and is considered the causative of an acute contagious disease of poultry industry spread worldwide. Two serotypes (I and II) can be differentiated by cross-neutralization assay and ELISA methodologies using monoclonal antibodies (8). Significantly, IBD-induced immunosuppression increases the occurrence of disease caused by opportunistic pathogens and prevents young chickens from responding optimally to vaccination (3). Since the mid 1980's a new very virulent strain of

IBDV (vvIBDV) has emerged, first in the Netherlands, and after disseminated to other European countries, and unfortunately as well as worldwide. It has been reported that very virulent strains were able to overcome high levels of maternal derived immunity and cause a substantial increase in mortality (6).

Cellular targets for IBDV replication are found in lymphoid organs, mainly the Bursa of Fabricius (BF) and thymus (4, 5). Many reports have shown that infection with pathogenic serotype I IBDV strains leads to the induction of apoptosis both *in vivo* and *in vitro* (1, 7, 11). It has been suggested that induction of apoptosis in infected lymphoid cells may contribute to the immune-suppressive effect of virus infection (7). However, the exactly mechanism that IBDV induces apoptosis is not clearly understanding, in spite of many reports described chromatin condensation, DNA fragmentation, and the appearance of apoptotic nuclear bodies as main cellular alteration (11).

Therefore, to determine whether cell adapted very virulent infectious bursal disease virus (ca-vvIBDV) and original vvIBDV induces the expression of activated-*caspase 3* in embryonic lymphoid tissues chicken embryos were exposure to infection at 18 embryonation day (ED18). The apoptotic effect was evaluated by terminal deoxynucleotide transferase-dUTP nick-end-labeling (TUNEL) assay. Viral distribution, histopathological analysis and *caspase-3* detection were performed by histological and immunohistochemistry assays. Finally, sequencing of VP2 variable region was performed to search amino acids changes during cell adaptation.

Stocks of cell adapted vvIBDV (ca-vvIBDV) and original vvIBDV (G11 Brazilian genotype of vvIBDV) were produced by infecting 3-week-old chickens and isolating virus from the bursa of Fabricius (BF) 3 days latter described earlier, respectively (12). All IBDV strains used in this study were kindly supplied by Merial Laboratories, Brazil. Fifty five embryonated chickens eggs were allotted into two groups of twenty eggs each, and one group of fifteen designed as control. In the group 1 and 2, each egg was inoculated with $1 \times 10^{3.5}$ EID₅₀ of original vvIBDV and ca-vvIBDV, respectively at ED18. Each embryo at group 3 was inoculated with sterile water. At ED21 embryos from each of the three groups were examined for BF and thymus microscopic lesions, viral distribution, apoptosis and cleaved *caspase-3* expression. Specific pathogen free embryos (SPF) were gentle supplied by Biovet®, vaccine industry localized at São Paulo State, Brazil. The embryos were held in an incubator under supervisor of Laboratory of Animal Virology, Veterinary School, Araçatuba, São Paulo. After ovoscopy analysis, the embryos at ED18 were inoculated with $1 \times 10^{3.5}$ 50% egg infectious dose (EID₅₀) of the original vvIBDV propagated on chickens and ca-vvIBDV, whereas attenuation was performed before (12). Infected and control group was kept separately. Midsections of BF and thymus were sampled and fixed in 10% neutral buffered

formalin in phosphate buffered saline (PBS) for 24h, after which they were submitted to paraffin-embedded routine procedure. Sections of 4µm thick were floated onto a distilled water bath (45°C), collected on slides and deparaffinised and rehydrated through an ethanol series and processed for routine histological analysis using haematoxylin and eosin staining (HE) and immunohistochemistry assay (11). Sections of BF and thymus were stained with HE for histopathological examination or subjected to the standard streptavidin-biotin-peroxidase procedure for immunohistochemistry previously described (11). For immunolabelling of viral antigen, a polyclonal anti-IgY antibody was used, have been raised in rabbits against the Lukert vaccine strain (2); for negative control purposes the primary antibody was replaced by phosphate-buffered saline. The apoptotic cells were detected by APO-BrdU™ TUNEL Assay kit (Molecular Probes™, Invitrogen detection technologies) method. Deparaffinized and rehydrated sections were subjected to re-fixation with 1% of paraformaldehyde during 30 min at room temperature (RT). After fixation, the slides were submitted to a pre-treatment protocol, which involved microwave oven treatment (800W) in 10mM citrate buffer (pH 3,0) for 14 min. The next step, slides were covered with a solution of proteinase K (10µg/mL) for 5 min at RT and washed with PBS. From this point the provided manufacture's instructions were followed. Cells that have undergone apoptosis have demonstrated fluorescence brightly when viewed under fluorescent microscopy. Immunolabelling was observed as fluorescent deposits and were counted in a total of 100 slides (obtained from 10-high-power [x400] fields). Deparaffinised and rehydrated sections were subjected to an antigen retrieval procedure by proteinase K (5µg/mL) for 3 min and after rinsed in PBS and re-fixed with 4% of paraformaldehyde during 30 min at RT. After, the slides were covered with 100µl of anti-*caspase 3* active antibody (cat # C8487, Sigma-Aldrich, St Louis, MO, USA) at 1:200 diluted in PBS. The incubation was under humidified chamber at 4°C over night. Next step, slides were washed 5 times consecutively, with PBS and covered the sections with 1:100 of goat anti-mouse biotinylated antibody (Sigma-Aldrich) during 30 min at RT. After wash as described before, the slides were covered with streptavidin-alkaline phosphatase conjugated (Sigma-Aldrich) and incubated at RT for 45 min. Sections were then treated with FAST RED® TR/Napthol AS-MIX (cat # F4648, Sigma-Aldrich), a substrate for the detection of alkaline phosphatase activity such that positive cells stained red. Slides were mounted using aqueous mounting media and submitted to Olympus microscopy evaluation and the images documented. In order to verify if the IBDV cell adaptation generate any genomic change in hypervariable VP2 region, at position 181 to 340 of viral genome, viral RNA extraction, RT-PCR (reverse transcriptase polymerase chain reaction assay) and sequencing were performed as described previously (10).

Differences between variables in respect to histopathology lesions were analyzed by the Mann-Whitney *U* test. *P* < 0.05 was considered significant. Immunolabelling for *caspase-3* was observed in the cytoplasm and counted in a total of 1000 cells (obtained from 10-high-power [400x] fields). Infection of embryos at ED18 with original vvIBDV resulted in a typical acute response. Microscopically, some follicular destruction was observed in BF, lower in ca-vvIBDV and more intensive in original vvIBDV (Fig.1, I and II, D). Sections of bursae collected at ED21 were examined for the presence of IBDV antigen. Peroxidase-stained cells, presenting brownish deposits, were considered positive for viral antigens and were observed in all bursal follicles (Fig.1, I and II, A, B). In thymus, histologically, several necrosis focus associated to lymphocytic depletion were observed in the cortex and also in the medulla of both IBDV viruses (Fig. 2B, D). However, the ca-vvIBDV seems to damage less the thymus architecture than original strain (Fig 2A, E). The viral antigens were less intensively detected in ca-vvIBDV exposed embryos (Fig 2E) at ED21 than original vvIBDV (Fig 2C). In BF of control and ca-vvIBDV positive fluorescent cells were observed in all slides (Fig 3B, C). In contrast, the intense fluorescence was obtained from BF collected from infected embryos with vvIBDV. In thymus, weak fluorescent signals were visualized (Fig 3B, E). All samples were taken at ED21, and fragmentation of chromatin could also be identified (Fig 3D). All analyzed slides, prepared from BF and thymus, infected with ca-vvIBDV and original vvIBDV presented positive signal to TUNEL assay. Of the 100 slides searched, 100% showed strong positive immunolabelling after vvIBDV infection (Fig.3A, D); in contrast all slides gave weak immunoreactivity (Fig. 3B, E), observed from BF and thymus, respectively. Only BF and thymus sections prepared from infected embryos at ED21 with original vvIBDV presented positive signal to activated *caspase-3* immunostaining (Fig 4. B, C). Neither ca-vvIBDV exposed embryos, nor the controls presented any positive signal to activate *caspase-3* immunoreaction (Fig 4. A, D). Caspase labeling was well visualized inside the cytoplasm as red deposits inside the lymphocytes in BF and thymus (Fig. 4, inset). To determine the genetic changes, the VP2 variable region sequences of ca-vvIBDV was determined and compared with their parental strains and published IBDV sequences from position 181 to 340 of IBDV genome (Fig. 5). Differences in amino acids between ca-vvIBDV and others vvIBDV strains were found mutations at position 222 (A→P) and 330 (S→R), considered important sites for virus attenuation. The heptapeptide, S-W-S-A-S-G-S (326-332), which is known to be conserved among virulent strains, showed mutation at position 333 in ca-vvIBDV VP2 encoding-gene (GenBank accession number FJ 497058). In the present study, we have demonstrated the effect of embryos infection with vvIBDV and ca-vvIBDV, analyzing the respective effect on BF and thymus concerned to virus distribution, DNA fragmentation and

caspase-3 expression. Experimental infection with vvIBDV but not ca-vvIBDV at ED18 significantly caused follicular destruction and lymphocyte depletion in both lymphoid organs. In addition, the virus antigen was promptly detected from the same samples. The vvIBDV exposure at ED18 induced thymocytes apoptosis, confirmed by TUNEL-assay and intense expression of *caspase-3*. In fact, infection of chickens (embryos or 1 day-old chicks) with classical IBDV strains leads to a kwon inflammatory response in BF and thymus, added by virus antigen distribution (8, 12). However, the immunopathology caused by adapted virulent IBDV strains is not well understood. As demonstrated before, the mechanism of IBDV-induced lymphocyte depletion, both in BF and thymus, is probably due to apoptosis event (7, 10). Moreover, it has been demonstrated functional restoration of infected BF following *in ovo* vaccination with intermediate strains (5). The recovery of BF can be explained by less functional T cells in younger birds, and as shown before, T cells have a negative impact on follicular recovery of BF (5).

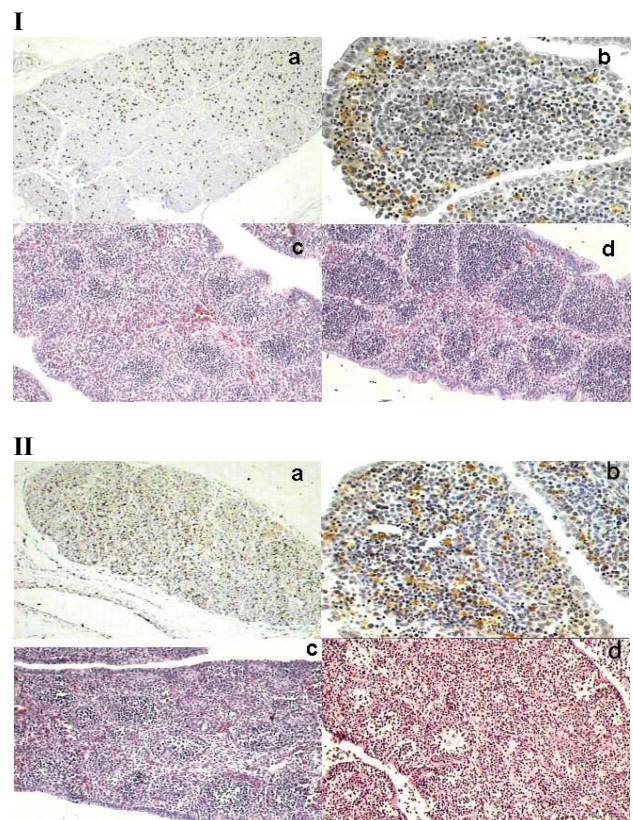


Figure 1 – Effect of IBDV replication on BF (I) ca-vvIBDV and (II) original vvIBDV. At ED21, bursal sections from normal embryos (I and II, C) were examined. HE staining (I and II, D) revealed moderate damage of bursal follicles in ca-vvIBDV (I, D) exposed chicken. HE staining (II, D) revealed extensive damage of bursal follicles in original vvIBDV exposed chickens. Staining with anti-IBDV antibody (I and II, A, B) revealed viral proteins more intensively marked in original vvIBDV exposed chicken, and less in ca-vvIBDV. x 200.

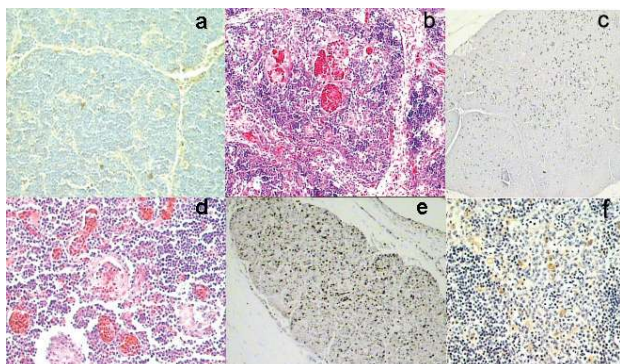


Figure 2 – Effect of IBDV infection on thymus. At ED21, thymus sections from normal chicken (A) ca-vvIBDV (B) and original vvIBDV (D) were examined. HE staining (A, B and D) revealed the depletion of lymphocytes, hemorrhage and mild necrosis (B, D). Thymus in control embryos was intact (A). Staining with anti-IBDV antibody (B, E, F) in an IHC reaction revealed viral proteins intensively marked in original vvIBDV exposed embryos (B), and less in ca-vvIBDV birds (E, F). x 200.

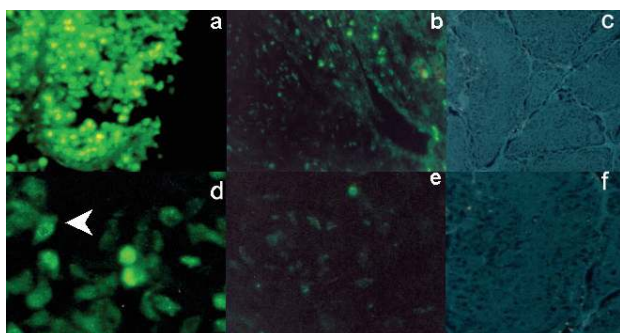


Figure 3 – Photomicrograph of TUNEL-stained BF (A, B, C) and thymus (D, E, F) of chicken embryos. At ED21, bursal sections from normal embryos (C), original vvIBDV (A) and ca-vvIBDV (B) were examined for apoptosis using TUNEL-assay. Extensive fluorescent lymphoid cells were visualized in BF in original vvIBDV exposed embryos. At ED21, thymus sections were examined and less fluorescent lymphoid cells could be visualized in original vvIBDV exposed embryos. BF and thymus lymphoid cells were intensively marked, and both controls were intact (C, F). x 100.

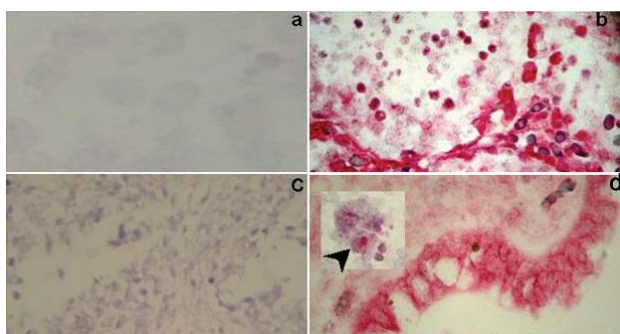


Figure 4 – Cleaved *caspase-3* immunostaining patterns in BF (A, B) and thymus (C, D) of original vvIBDV exposed embryos. At ED21, only the original vvIBDV exposed embryos produced red deposits in BF (B) and thymus (D), considered positive (arrow, inset), BF and thymus in both non-infected and ca-vvIBDV exposed embryos were intact (A, C). x 200.

There are two major pathways of apoptosis: the death receptors-external signal pathway and mitochondria-mediated internal signal pathway. The most important effectors of apoptosis are cysteine aspartic acid-specific proteases (*caspases*), which participate in a tightly regulated proteolytic cascade. Besides, fourteen *caspases* have been identified in mammals. Among them, *caspase-3* activation is considered to play a central role in apoptosis: activated *caspase-3* is responsible for the breakdown of several cellular components related to DNA repair and regulation. Moreover, *caspases* also play a key role in the effector phase of apoptosis induced by a variety of viruses (10). In spite of few reports, describing IBDV infections inducing apoptosis process, herein it was possible to infer that vvIBDV, non-adapted to cell culture, demonstrated *caspase-3* immunoreactivity and TUNEL-assay positive signals in infected chicken embryos (12). In contrast, when cell adaptation was conducted, vvIBDV strain still replicates in infected chicken embryos, but less or no evidence of DNA damage and *caspase-3* positive signals could be observed, respectively.

Passages of virulent IBDV strains in chicken embryos and/or cell culture have been used to produce live virus vaccines, with low virulence and equal effective immunogenicity (3, 13). Usually, pathogenic bursal-derived field strains are not easily adapted to cell culture, a process which requires extensive infection either in cell culture or chicken embryos (13). Alteration of two specific amino acids in VP2 encode-gene of vvIBDV strains resulted in tissue culture adaptation and attenuation in chickens (van Loon et al., 2002). In our study, mutations at positions 222 (A→P), 256 (I→V) and 279 (D→N) were observed and are in accordance to several studies reporting virus attenuation (9, 13).

Finally, taken together our findings, vvIBDV cell adaptation induced mutations that affected the immunopathogenesis and adds one more example to the growing list of avian viruses that induces apoptosis by activate *caspase-3* pathway.

Acknowledgements

This work was supported by a Research Grant from Fundação de Amparo à Pesquisa do Estado de São Paulo (Fapesp).

References

1. ARIAS-FERNADÉZ A., MARTÍNEZ S., RODRÍGUEZ J. The major antigenic protein of infectious bursal disease virus, VP2 is an apoptotic inducer. *J. Virol.*, 1997, 71, 8014-8.
2. CARDOSO TC., RAHAL P., PILZ D., TEIXEIRA MCB., ARNS CW. Replication of classical infectious bursal disease virus in the chicken embryo related cell line. *Avian Pathol.*, 2000, 29, 213-7.

3. ELDAGHAYES I., ROTHWELL L., WILLIAMS A., WITHERS D., BALU S., DAVISON F., KAISER P. Infectious bursal disease virus: strains that differ in virulence differentially modulate the innate immune response to infection in the chicken bursa. *Viral Immunol.*, 2006, 19, 83-91.
4. INOUE M., FUKUDA M., MIYANO K. Thymic lesions in chicken infected with infectious bursal disease virus. *Avian Dis.*, 1994, 38, 839-46.
5. IVÁN J., NAGY N., MAGYAR A., KACSKOVICS I., MÉSZÁROS J. Functional restoration of the bursa of Fabricius following in ovo infectious bursal disease vaccination. *Vet. Immunol. Immunopathol.*, 2001, 79, 235-48.
6. JACKWOOD DJ., SREEDEVI LJ., SOMMER-WAGNER SE. Studies on naturally occurring infectious bursal disease viruses suggest that single amino acid substitution at position 253 in VP2 increases pathogenicity. *Virology.*, 2008, 377, 110-6.
7. JUNGSMANN A., NIEPER H., MÜLLER H. Apoptosis is induced by infectious bursal disease virus replication in productively infected cells as well as antigen-negative cells in their vicinity. *J. Gen. Virol.*, 2001, 82, 1107-15.
8. KIBENGE FSB., DHILLON AS., RUSSEL RG. 1988. Biochemistry and immunology of infectious bursal disease virus. *J. Gen. Virol.*, 1988, 69, 1757-75.
9. KWON HM, KIM SJ. Sequence analysis of the variable VP2 gene of infectious bursal disease viruses passaged in Vero cells. *Virus Gen.*, 2004, 28, 285-91.
10. SCHWARTZMAN RA., CIDLOWSKI JA. Apoptosis: the biochemistry and molecular biology of programmed cell death. *Endocrine Rev.*, 1993, 14, 133-51.
11. TANIMURA N., SHARMA JM. In-situ apoptosis in chickens infected with infectious bursal disease virus. *J. Comp. Pathol.*, 1998, 118, 15-27.
12. TAPPARO AF., TONIETTI PO., LUVIZOTTO MCR., CARDOSO TC. Application of a serum/protein-free medium for the growth of mammalian cell lines and high level production of classical, variant and very virulent strain of infectious bursal disease virus (IBDV). *Am. J. Agric. Biol. Sci.*, 2008, 3, 517-21.
13. YAMAGUCHI T., OGAWA M., INOSHIMA H, MIYOSHI M., FUKUSHI H., HIRAI K., 1996. Identification of sequence changes responsible for the attenuation of highly virulent infectious bursal disease virus. 1996, 223, 219-23.