



Case Report

Bilateral auricular aneurysm with intact pericardial sac in a dog

Mayane Faccin¹, Mônica Regina de Matos¹, João Pedro Cavasin¹,
Ana Cláudia Bochi², Mariana Pavelski³, Aline de Marco Viott^{4*}

¹ Veterinary Pathology Laboratory, Universidade Federal do Paraná (UFPR),

Rua Pioneiro, 2153, Jardim Dallas, 85950-000, Palotina, PR, Brazil. E-mail: patologiapalotina@gmail.com

² Small Animal Medicine, Universidade Federal do Paraná (UFPR),

Rua Pioneiro, 2153, Jardim Dallas, 85950-000, Palotina, PR, Brazil. E-mail: anaclaudiabochi@hotmail.com

³ Substitute Professor of Small Animal Medicine, Universidade Federal do Paraná (UFPR),

Rua Pioneiro, 2153, Jardim Dallas, 85950-000, Palotina, PR, Brazil. E-mail: marianapavelski@gmail.com

⁴ Adjunct Professor of Veterinary Pathology, Universidade Federal do Paraná (UFPR),

Rua Pioneiro, 2153, Jardim Dallas, 85950-000, Palotina, PR, Brazil. *Corresponding author E-mail: alinedemarco@yahoo.com.br

Submitted October, 6th 2020, Accepted November, 17th 2020

Abstract

A nine-year-old, male, Pekingese dog was presented with a history of dyspnea, lethargy, syncope, polyuria, polydipsia, and selective appetite over two years. When the clinical signs first began, a radiographic exam revealed a radiopaque mass in the cranial mediastinum. An adequate treatment was not performed and the dog was presented to the hospital with severe tachycardia, dyspnea, and tachypnea, and died during physical examination. On necropsy, the heart presented bilateral auricular aneurysms. The pericardial sac was intact, and no other defects were found within the heart. Microscopically, the cardiomyocytes were marked degenerated and proliferation of connective tissue. This is the first case report of a bilateral auricular aneurysm with intact pericardial sac in a dog.

Key words: Auricular dilation; Cardiomyopathy; Congenital; Cardiac fibrosis.

Introduction

Auricular aneurysm, also known as appendage aneurysm and aneurysmal dilation, is a rare cardiac condition that has been reported in humans (1, 3, 11, 14) and dogs (5, 8, 13). It is defined as a congenital (8) or inflammatory (13) dilation of the auricles. This can also be secondary to pericardial sac defects with herniation of the auricle and part of the atrium (6, 9). Angiotomography is considered the standard diagnostic test of auricle aneurysm (5), although radiography and computer tomography also may reveal increased auricular volume (4, 5, 8, 13). Treatment for this condition is described mostly in humans (14) and once in dogs (4) and consists of surgical resection of the dilation through partial atriectomy.

In dogs, the disease has been reported affecting either the right (5, 8, 13) or the left (4) atria. After detailed national and international literature review, this is the first report of bilateral auricular aneurysm with intact pericardial sac in a dog.

Case report

A 7-year-old, neutered male, Pekingese dog was referred to the veterinary care with clinical signs of syncope, dyspnea, and lethargy. The electrocardiography revealed normal sinus rhythm and no other significant findings were noted. Three radiographic projections were performed (ventrodorsal, left lateral, and right lateral), and they revealed an increased opacity on the soft tissues cranially and adjacent to the heart, better visualized on the left lateral projection (Fig. 1). No signs of congestion or edema were appreciated in the lungs. The presumed radiographic diagnosis was a mass in cranial mediastinum of undetermined origin. Also in this projection, the heart was generally enlarged with marked right atrial dilation. The owner declined other diagnostic tests, as well as any treatment for the suspected cardiomyopathy.

Approximately two years after the first clinical

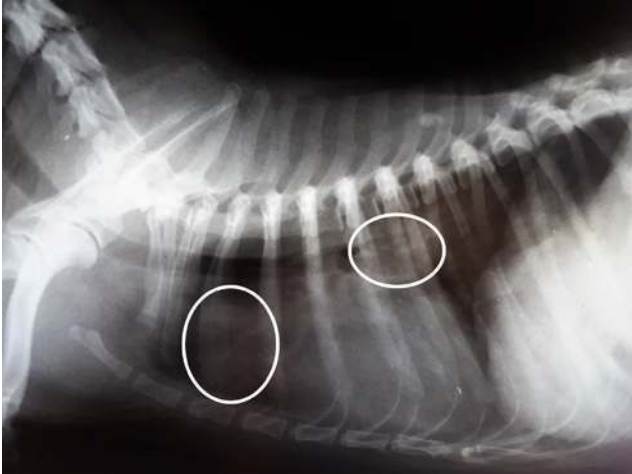

Figure 1. Radiographic image of a 9-year-old, male, Pekingese dog; lateral projection. There are two areas of increased radiopacity cranial and dorsal to the heart (circles), with cranial deviation of the trachea. No significant findings in the pulmonary artery and vein, and normal radiopacity in the caudo-dorsal lung, with no evidence of pulmonary congestion and edema.

signs, the disease worsened and the dog was presented for re-evaluation with a remarkably persistent dyspnea and lethargy. Additional clinical signs included syncope, polyuria, polydipsia, and selective appetite. On physical examination, the animal had a cardiac frequency of 132 beats per minute, marked tachypnea, expiratory dyspnea, rectal temperature of 38.1°C, capillary refill time of 2 seconds, pink mucous membranes, and regular pulse. On cardiac auscultation, a grade IV/VI heart murmur was identified in both atrioventricular valves. The patient also had intense uremic breath and severe dental tartar. The dog was physically restrained for blood withdrawal, but collapsed and died.

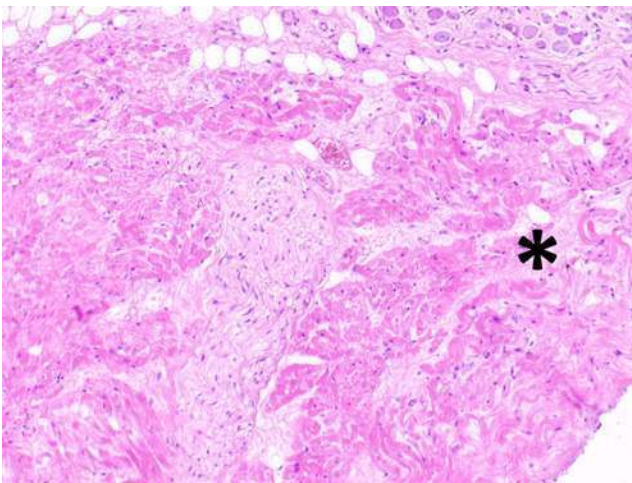


Figure 3. Photomicrograph of the heart, 9-year-old, male, Pekingese dog; hematoxylin and eosin, 10x. The myocardium presented multifocal to coalescing areas of myofiber disarray, with vacuolization, hyaline degeneration, and fragmentation of the sarcoplasm. The cardiomyocytes were often dissected by disorganized fibrous connective tissue (asterisk).

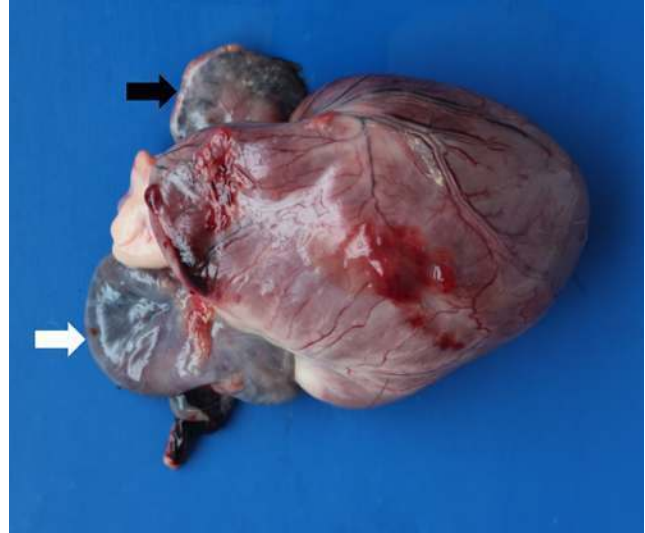


Figure 2. Gross evaluation of the heart, 9-year-old, male, Pekingese dog. Both auricles are dilated, and the right side is more severely affected (white arrow) than the left side (black arrow).

On gross macroscopy, the heart was markedly increased in size, elongated, and presented severe dilation of both auricles, that was prominent on the right side (Fig. 2). The left ventricle had moderate eccentric hypertrophy and marked myxomatous degeneration of the left atrioventricular valve, with a small focal roughening on the endocardium of the left atrium, right above the valve, consistent with a jet lesion. The aorta had a moderate focal area of arteriosclerosis dorsal to the left semilunar valves. The right atrioventricular valve, right ventricle, and both semilunar valves were unremarkable.

Other gross lesions included moderate, locally extensive, bilateral necroulcerative stomatitis, moderate, diffuse hemorrhagic and erosive gastritis, interstitial pneumonia with edema and congestion, and the kidneys were mildly pale with multifocal small depressions on the capsular surface. Tissue fragments were collected and fixed on formalin 10% and routinely processed and stained with hematoxylin and eosin and Masson's trichrome (2).

Histologically, the myocardium had multifocal to coalescing areas of myofiber disarray, with vacuolization, hyaline degeneration, and fragmentation of the sarcoplasm. The cardiomyocytes were often dissected by loose fibrous connective tissue. Few cardiomyocytes were necrotic with minimal lymphocytic infiltration and hemorrhage. Masson's trichrome staining, extensive infiltration of streams and bundles of fibrous connective tissue within the myocardium, bridging and dissecting small groups of cardiomyocytes, both within the auricle and the left ventricle was noted. Prominent fibrosis was mostly observed where there was severe damage to the cardiac musculature (Fig. 3 and 4).

Other histological findings included moderate, diffuse lymphocytic and histiocytic interstitial pneumonia, moderate membranoproliferative glomerulonephritis and glomerulosclerosis with interstitial and periglomerular fibrosis, consistent with chronic kidney disease.

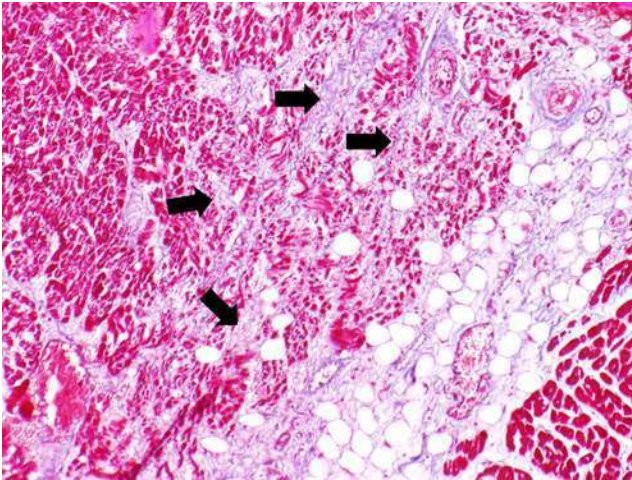


Figure 4. Photomicrograph of the heart, 9-year-old, male, Pekingese dog; Masson's trichrome, 10x. Extensive infiltration of streams and bundles of fibrous connective tissue (arrows) within the cardiac tissue, bridging and dissecting small groups of cardiomyocytes (red) are noted. Note marked decrease in the myofiber diameter within the affected areas when compared with normal areas in the periphery of the picture.

Discussion

Auricular aneurysm is a poorly described condition in the veterinary literature and its pathogenesis is incompletely understood. Partial congenital or traumatic defects on the pericardial sac leading to cardiac herniation have been associated with this condition (6). There have been reported cases where the pericardial sac was intact (8) or thinner over the area of the aneurysm compared to the rest of it (4). In those cases, the authors suggested a congenital auricle weakness. Another possible origin is inflammation associated with immune-mediated polymyositis and myocarditis (13). In humans, the left auricular aneurysms are mostly congenital (1, 3, 10, 11, 14) and has been attributed to congenital dysplasia of the *musculi pectinati* (10). No genetic defect in the collagen synthesis was found in affected humans (14). Acquired auricular aneurysm was associated with severe valvular regurgitation (7) and left atrioventricular valve myxomatous degeneration (4, 8). In this case, the pericardium sac was intact, which rules out the possibility of herniation. The lymphocytic infiltration was very subtle compared to the severity of the cardiac lesions, which makes an underlying inflammatory condition less likely. This patient had severe left atrioventricular valve degeneration which could be a potential cause for the left aneurysm. As this patient had both auricles dilated and the right side was more affected than the left side, it is very reasonable to speculate that the right side might have a congenital origin, especially because no valvular disease was present in the right side. Whether the left side is also congenital or consequence of the valvular degeneration, it is uncertain.

There is no sex, age, or breed predilection established

in the literature. Sporadic case reports described the disease in Golden Retrievers, Lhasa apso, Pekingese, Labrador, and toy Poodle, affecting both genders, from 9 to 12 years old (4, 5, 8, 13). Another study accessed pericardium sac defects in eight dogs (9), of which four were females, three males, and one unknown, one Boxer, one Dachshund, and six mixed-breeds with ages ranging from 3 to 15.5 years. From these eight studied animals, six of them had herniation of some portion of the heart through the pericardial defect. Based on all the studies mentioned above, there is no clear predisposition for large or small breeds or sex predilection, although clinical manifestation is most common in adult and aging animals.

The patient's clinical signs of dyspnea, lethargy, and cardiac murmur are often suggestive of left atrioventricular valve myxomatous degeneration, as observed during necropsy. The clinical signs associated with auricle aneurysm are similar and characterized by exercise intolerance and collapse, non-responsive chronic coughing, and cardiac murmur (4, 5, 8, 13). In general, other parameters tend to be normal. The animal in this case likely had overlapping clinical signs of auricular and valvular diseases which led to the sudden death during restraining.

Local increased radiopacity was visualized adjacent and cranial to the heart, with differential diagnosis of mediastinal mass. These findings were also described in other reports as being suggestive of right auricular aneurysm (4, 5, 13). On electrocardiography, one patient with right auricular dilation presented occasional atrial premature complex (13). In a dog with left auricular dilation associated with myxomatous valvular degeneration, the exam revealed valve regurgitation and dilation of the left atrium and ventricle (4). Nevertheless, some cases may not have any abnormalities (5), as seen in this case.

Echocardiography is a highly efficient method to evaluate cardiac function and is a useful tool to diagnose valvular diseases (12). However, lack of echocardiographic changes does not rule out an auricular aneurysm (5). In these cases, angiotomography is recommended as the standard diagnostic test for auricular dilation (5). Further investigation of the mediastinal mass was declined by the owner in this case, which prevented the ante-mortem diagnosis.

Auricular and atrial dilation associated with myocardial fibrosis are the main gross findings reported in the literature (4, 8, 13). To the authors' knowledge, this is the first case report of bilateral auricular aneurysms with an intact pericardial sac in a dog cited in veterinary literature.

Although cardiac wall thickness is decreased, histologically all chambers are present (8). Main histological findings of auricular aneurysms are marked variation in cardiomyocyte diameter, with tumefaction, hyaline degeneration, and myofibrillar atrophy, associated with myonecrosis and fibrosis, which is highlighted by the Masson's trichrome stain (4, 8, 13). Some reports do not describe any type of inflammatory infiltrate associated

with the cardiac lesions (4, 8), while another case included marked lymphocytic and histiocytic infiltrate in all examined muscles, which raised suspicion of an immune-mediated component leading to polymyositis (13). The patient of this report presented mild mononuclear infiltration within the heart. This is likely a reaction to the degenerative and necrotic cardiomyocytes, rather than the primary cause of cellular damage, as the infiltrate was mild and was not present in other muscular groups.

In conclusion, this case report describes a bilateral auricular aneurysm with intact pericardial sac in a dog associated with fibrosis and myocardial degeneration. Mediastinal tumors should be differentiated from this condition mainly when located close to the heart base and without evidence of pulmonary edema and congestion. Radiographic examination should be associated with other imaging tests to facilitate the diagnosis.

Acknowledgements

We acknowledge the Imaging Diagnostic Service of the Veterinary Hospital of the Universidade Federal do Paraná – Setor Palotina, for contributing with the radiographic images.

References

1. Chowdhury UK, Seth S, Govindappa R, Jagia P, Malhotra P. Congenital left atrial appendage aneurysm: a case report and brief review of literature. *Heart Lung Circ.* 2009;18(6):412-416.
2. Luna LG, Armed Forces Institute of Pathology. Manual of histologic staining methods of the Armed Forces Institute of Pathology. 3rd ed. New York: Blakiston Division, Mcgraw-hill, 1968. 258p.
3. Munárriz A, Escribano E, Urchaga A, Olaz F, Beunza M, de la Fuente A, Cantabrana S, Sola T. Congenital aneurysm of the left atrial appendage. *Eur J Echocardiogr.* 2008;9(1):152-154.
4. Rosselli D, Schmiedt C, Kirejczyk S, Sakamoto K, Sinkin A, Rapoport G. Surgical resection of a left auricular aneurysm in a dog. *J Vet Cardiol.* 2019;23:15-20.
5. Schwarz T, Willis R, Summerfield NJ, Doust R. Aneurysmal dilatation of the right auricle in two dogs. *J Am Vet Med Assoc.* 2005;226(9):1512-1515.
6. Sisson D, Thomas WP. Pericardial disease and cardiac tumors. In: Fox PR, Sisson D, Moise NS. *Textbook of canine and feline cardiology.* 2nd ed. Philadelphia: WB Saunders Co., 1999, 679-700.
7. Terada H, Tanaka Y, Kashima K, Sannou K, Arima T. Left atrial diverticulum associated with severe mitral regurgitation. *Jpn Circ J.* 2000;64:474-476.
8. Toaldo MB, Diana A, Morini M, Cipone M. Imaging diagnosis – intrapericardial right auricle aneurysm in a dog. *Vet Radiol Ultrasound.* 2010;51(5):512-515.
9. Van Der Gaag I, Van Der Luer RJT. Eight cases of pericardial defects in the dog. *Vet Pathol.* 1977;14:14-18.
10. Victor S, Nayak VM. Aneurysm of the left atrial appendage. *Congenit Heart Dis.* 2001;28(2):111-118.
11. Wang B, Li H, Zhang L, He L, Zhang J, Liu C, Wang J, Lv Q, Shang X, Liu J, Xie M. Congenital left atrial appendage aneurysm. *Medicine (Baltimore),* 2018;97(2):e9344.
12. Ware WA. Cardiovascular system disorders. In: Nelson RW, Couto CG. *Small Animal Internal Medicine.* 5th ed. St Louis: Elsevier, 2014, 1-50.
13. Warman S, Pearson G, Barret E, Shelton GD. Dilatation of the right atrium in a dog with polymyositis and myocarditis. *J Small Anim Pract.* 2008;49:302-305.
14. Zeebregts CJAM, Hensens AG, Lacquet LK. Asymptomatic right atrial aneurysm: fortuitous finding and resection. *Eur J Cardiothorac Surg.* 1997;11:591-593.