



Case Report

Diaphragmatic hernia and unilateral renal agenesis in a crab-eating fox (*Cerdocyon thous*)

B.B. Lins¹, M.S. Sousa¹, A.D.A. Frade¹, R.L. Oliveira¹,
P.G.T. Almeida², D.M.N.M. de Oliveira¹, J. Leal de Araújo^{1*}

¹ Departamento de Ciências Veterinárias, Universidade Federal da Paraíba,
12 Rodovia, PB-079, Areia - PB, Brasil, 58397-000.

² Centro de Triagem de Animais Silvestres, CETAS – IBAMA, Floresta Nacional da Restinga de Cabedelo,
Rod. Gov. Antonio Mariz - Lot. Bela Vista Cabedelo-PB, Brasil, 58310-000

*Corresponding author: Departamento de Ciências Veterinárias, Universidade Federal da Paraíba,
12 Rodovia, PB-079, Areia - PB, Brasil, 58397-000. E-mail: lealjeann@gmail.com

Submitted November, 03th 2020, Accepted March, 3th 2021

Abstract

An approximately 3-month-old crab-eating fox (*Cerdocyon thous*) was found by environmental authorities in the State of Paraíba, Northeastern Brazil and referred to a wildlife care center. The fox was presenting respiratory distress and it was referred to the Veterinary Hospital of the Federal University of Paraíba (UFPB) for ancillary testing. Abdominal and thoracic ultrasound and radiographies were performed. These imaging tests indicated the fox had a possible diaphragmatic hernia and ectopic kidney. The imageology results were confirmed on necropsy, which revealed a postero-lateral focal discontinuity of the dorsal aspect of the diaphragmatic muscle with protrusion of the gastrointestinal tract into the thoracic cavity. The stomach and intestinal loops were filled with gas and obliterated the visualization of the heart and lungs. Additionally, only the right kidney was found, and no vestigial left kidney was identified. Congenital diaphragmatic hernias are not commonly observed in wildlife but should be considered as a potential differential diagnosis for acute onset of respiratory distress in young carnivores.

Key words: Wildlife, wild canid, respiratory distress, ultrasonography, radiography.

Introduction

The crab-eating fox (*Cerdocyon thous*) is a medium-sized canid widely distributed in South America that inhabits all Brazilian biomes and represents a resilient species against anthropomorphic threats (19). These canids have nocturnal habits and an omnivorous diet that ranges from fruits to small mammals (13).

Among the diseases affecting wild animals, birth defects are not commonly observed, and there are only a few reports of congenital abnormalities occurring in wild canids (8, 20, 22, 24, 30). Diaphragmatic hernias are disruptions of the diaphragm that result in the misplacement of abdominal viscera within the thoracic cavity, and they may be acquired or congenital (2). Renal agenesis has been reported in dogs and cats, but in wildlife, the reports are scarce and restricted to one report in a flamingo (18) and in a common-squirrel monkey (25). To date, congenital diaphragmatic hernias and renal agenesis have not been described in wild canids.

The aim of this report is to describe antemortem and postmortem features of a diaphragmatic hernia and unilateral renal agenesis in a crab-eating fox in Northeastern Brazil.

Case description

An approximately 3-month-old female crab-eating fox (*Cerdocyon thous*) was found alone by environmental authorities in a rural area of the State of Paraíba, Northeastern Brazil and referred to a wildlife care center (Centro de triagem de animais silvestres, CETAS) where it was kept while the authorities were seeking for a proper destination. The fox was possibly abandoned by its mother, and although had good body condition, it continuously presented with abdominal breathing and, during physical examination, it was observed a mild lateral angular deformity in the carpal region of the thoracic right limb. Additionally, a substantial infestation by ticks was noted. To investigate the cause of the abnormal breathing

and general health status, the fox was referred to the Veterinary Hospital of the Federal University of Paraiba (UFPB) for ancillary testing. The patient was submitted to ultrasound, abdominal and thoracic radiographies, and clinical pathology evaluation.

A complete blood count (CBC) was performed, but all values were within reference intervals. Abdominal ultrasound at the subcostal window revealed loss of delimitation of the right diaphragmatic dome, which suggested the presence of a unilateral diaphragmatic hernia or diaphragmatic rupture. Hepatomegaly was observed in association with decreased echogenicity and increased caliber vessels, suggesting hepatic congestion. The right kidney was in a non-anatomic region, located adjacent to the urinary bladder. After extensive scanning, it was not possible to identify the contralateral kidney. On the thoracic ultrasound, it was observed intestinal loops as herniated content, and an anechoic fluid collection free in the thoracic cavity, which suggested pleural effusion.

The patient was also submitted to a radiographic evaluation of the abdominal cavity, and dorsoventral and laterolateral radiographies were taken. No sedation was

necessary. Radiographies confirmed the unusual location of the kidney in the hypogastric region, in addition to renomegaly and hepatomegaly. Radiographic examination of the thoracic cavity identified the presence of intestinal loops filled with gas, partial loss of definition of the cardiac silhouette, with lateralization of the organ and loss of visualization of the diaphragmatic dome (Fig. 1 and 2). These findings were compatible with diaphragmatic hernia.

The fox died during transportation on the second visit to the Veterinary Hospital, and the carcass was sent for necropsy at the Veterinary Pathology Laboratory at UFPB. At necropsy, the fox had adequate nutritional status and slightly pale ocular, oral and vaginal mucosa. A postero-lateral focal discontinuity of the dorsal aspect of the diaphragmatic muscle with protrusion of the gastrointestinal tract into the thoracic cavity (Fig.3) was observed. The stomach and intestinal loops were filled with gas and obliterated the visualization of the heart and lungs. The discontinuity was approximately 10 cm in diameter with smooth edges and no evidence of bleeding or fibrosis. There were multifocal to coalescing areas of atelectasis on the left lung, which was cranially dislocated and compressed by the stomach. Additionally, only the right kidney was found on an ectopic location near the urinary bladder, and no vestigial left kidney was identified (Fig.4). Although the ultrasound examination suggested hepatic congestion, on necropsy, the liver was pale brown and enlarged. There were no other remarkable abnormalities, and signs of polytrauma were absent.

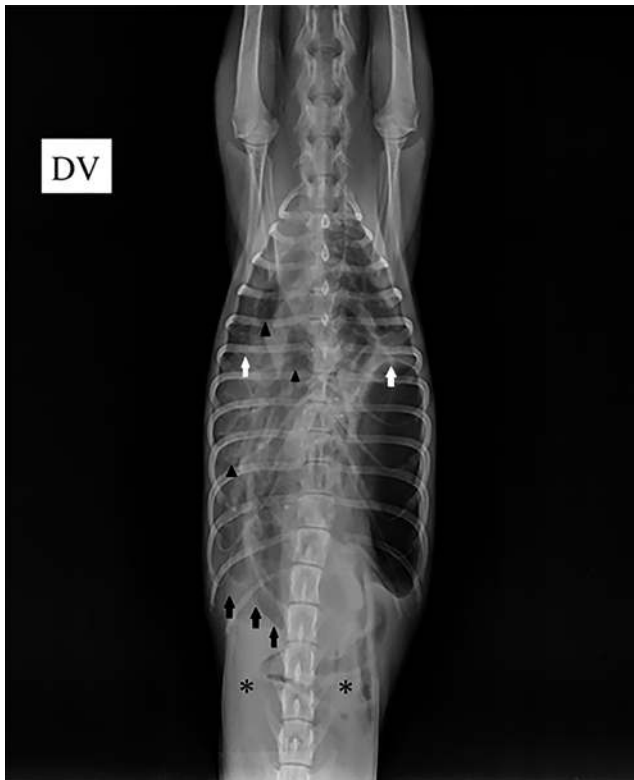

Figure 1. Dorsoventral projection of the thoracic radiography of the crab-eating fox. It is possible to observe an increase of radiopacity in the right hemithorax with visualization of interlobar fissures (white arrows) of the lung, suggestive of pleural effusion. Discontinuity in the musculature of the right diaphragmatic dome (black arrows), with passage of gas-filled opacities, compatible with the presence of intestinal loops (black arrowheads), almost complete absence of intestinal loops in the peritoneal cavity (asterisks).

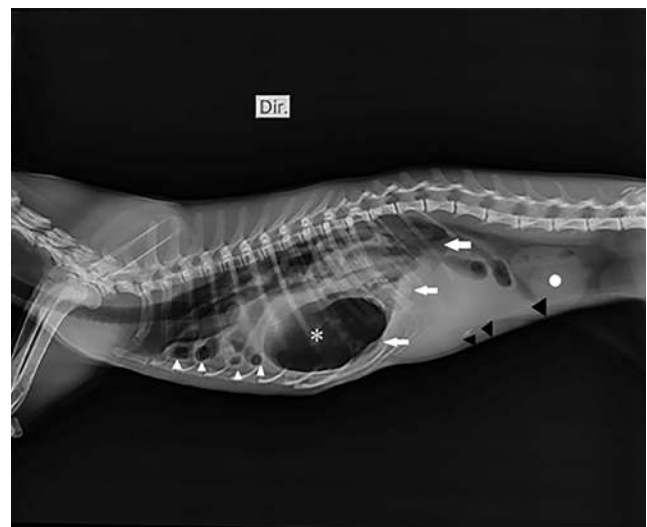


Figure 2. Thoracic and abdominal radiography in latero-lateral projection of the crab-eating fox. Note the loss of delimitation of the diaphragmatic dome (arrows) with gas-filled opacities in the thoracic cavity, suggesting a diaphragmatic hernia containing stomach (asterisk) and intestinal loops (arrowheads). Hepatomegaly is evident (black arrowheads). Almost complete absence of intestinal loops in the peritoneal cavity. Ectopic right kidney (white circle) in adjacent topography cranial to the urinary vesicle.

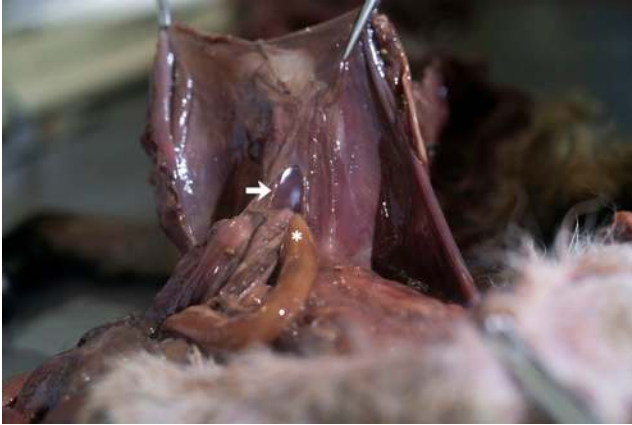

Figure 3. Diaphragmatic hernia in a crab-eating fox (*Cerdocyon thous*). Abdominal perspective. Note the intestinal loops (asterisk) projecting into the thoracic cavity through the diaphragmatic hernia. The hernia has smooth borders (arrow) and no signs of hemorrhage or lacerations are observed.

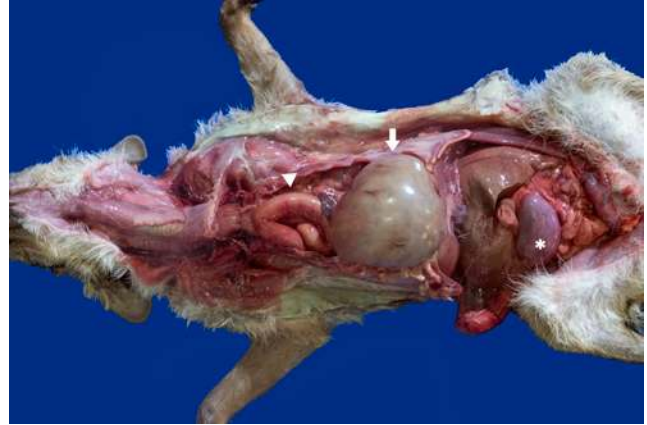

Figure 4. Diaphragmatic hernia and renal agenesis in a crab-eating fox (*Cerdocyon thous*). Note the gas-filled stomach (arrow) and intestinal loops (arrowhead) in the thoracic cavity. Only the right kidney (asterisk) was observed.

Discussion

In Veterinary Medicine, acquired diaphragmatic hernias are more common and may result from blunt trauma, most associated with vehicular collisions. Congenital diaphragmatic hernias are rare and result from aberrant embryogenesis(2).

Birth defects in wild canids are rare and usually associated to ocular (8), cardiac (22, 24) or musculoskeletal abnormalities (20, 22, 30). There are only a few reports of hernias in wild carnivores and they are restricted to wild felids (12, 14) and a maned wolf (10).

Reports of congenital diaphragmatic hernias in zoo and wildlife animals are scarce, and restricted to llamas (4), alpacas (6, 7) and a Golden Lion Tamarin (21). Most cases of congenital diaphragmatic hernias are idiopathic (15), and although several etiologies have been proposed, which includes vitamin A maternal deficiency (29), pesticides such as nitrofen and cadmium chloride (3, 15) and autosomal recessive disorders (23), its etiology remains obscure.

Some studies have indicated that the pathogenesis of the congenital diaphragmatic hernias is associated with impairments of the retinoic acid signaling pathway (RSP) (9). Experimental models have demonstrated that mice deficient of retinoic acid receptors produce offspring with congenital diaphragmatic hernias and a high rate of comorbidities including bone, cardiac, gastrointestinal and pulmonary malformations (17).

Although it was not possible to confirm the congenital nature of the hernia, the concomitant presence of renal agenesis, the smooth non-fibrotic borders of the hernia, and the absence of findings such as hemorrhage, exudate, and fractures that would indicate a possible traumatic cause, reinforced this hypothesis. In humans, a study of 143 fetuses, revealed that 272 malformations presented an association between congenital diaphragmatic hernia and

genitourinary abnormalities, including renal agenesis, which corresponded to 13,8% of all genitourinary malformations (31). In one report of congenital diaphragmatic hernia with concurrent renal agenesis (11), the infant was tachypneic and chest radiography indicated that parts of the bowel were present in the thoracic cavity, similar to the present case. The compression of the lung parenchyma by the herniated content can induce circulatory and respiratory dysfunctions, and in severe cases, the atelectatic lung can represent a life-threatening condition (28).

In Veterinary Medicine, renal agenesis has been reported mainly in dogs (1, 5, 16, 26, 27), and reports of wild and zoo animals presenting this malformation are limited to one case in a flamingo (18) and in a common-squirrel monkey (25).

This case illustrates the importance of radiology and ultrasound for evaluation of malformations in wild animals, and the crucial role of pathology to confirm the diagnosis. This is presumably the first report of diaphragmatic hernia and renal agenesis in a wild canid. Congenital diaphragmatic hernias are not commonly observed in wildlife but should be considered as a potential differential diagnosis for respiratory distress in young carnivores.

References

1. Agut A, Fernandez del Palacio MJ, Laredo FG, Murciano J, Bayon A, Soler M. Unilateral renal agenesis associated with additional congenital abnormalities of the urinary tract in a Pekinese bitch. *J Small Anim Pract.* 2002;43(1):32-5.
2. Avante ML, Pófaró V, Canola JC, Feliciano MAR. Sistema respiratório. In: Feliciano MAR, Canola JC, Vicente WRR, editors. *Diagnóstico por imagem em cães e gatos.* 1 ed. São Paulo: MedVet; 2015.
3. Barr M, Jr. The teratogenicity of cadmium chloride in two stocks of Wistar rats. *Teratology.* 1973;7(3):237-42.

4. Black-Schultz LL, Hanson PD, Wilson DG, Markel MD. Diaphragmatic hernia in a llama. Journal of the American Veterinary Medical Association. 1993;202(3):410-2.
5. Brownie CF, Tess MW, Prasad RD. Bilateral renal agenesis in two litters of Shetland sheepdogs. Vet Hum Toxicol. 1988;30(5):483-5.
6. DeVilbiss B, Ziegler J, Righter D, Allen A, Barrington G, Haldorson G. Diaphragmatic hernia in a two-year-old alpaca (*Vicugna pacos*). J Zoo Wildl Med. 2011;42(3):513-7.
7. Foster DM, Chinnadurai SK, Nutt JN, Pandiri A, Linder KE, Alley ML, et al. Congenital peritoneopericardial diaphragmatic hernia in an alpaca. Australian veterinary journal. 2011;89(1-2):51-4.
8. Granson H, Grahn B, Parker D, Himsworth C. Bilateral cataracts in a coyote (*Canis latrans*) pup from Saskatchewan, Canada. J Zoo Wildl Med. 2010;41(2):368-70.
9. Greer JJ, Babiuk RP, Thebaud B. Etiology of congenital diaphragmatic hernia: the retinoid hypothesis. Pediatr Res. 2003;53(5):726-30.
10. Hage MC, Peixoto JV, de Paula TA, de Oliveira AR, Carneiro FT, Dornelas e Silva VH, et al. Clinical challenge. Esophageal hiatal hernia. J Zoo Wildl Med. 2014;45(4):999-1001.
11. Han KH, Kim KS, Chang JW, Kim YD. Unilateral renal agenesis in a neonate with congenital diaphragmatic hernia. Central European Journal of Medicine. 2013;8(3):358-61.
12. Hettlich BF, Hobson HP, Ducote J, Fossum TW, Johnson JH. Esophageal hiatal hernia in three exotic felines--*Lynx lynx*, *Puma concolor*, *Panthera leo*. J Zoo Wildl Med. 2010;41(1):90-4.
13. Jorge RSP, Jorge MLS. Carnivora - Canidae (Cachorro-do-mato, cachorro-vinagre, lobo-guará e raposa-do-campo). In: Cubas ZS, Silva JCR, Catão-Dias JL, editors. Tratado de Animais Selvagens: Medicina Veterinária. 1. São Paulo: Roca; 2014. p. 848-63.
14. Kearns KS, Jones MP, Bright RM, Toal R, DeNovo R, Orosz S. Hiatal hernia and diaphragmatic eventration in a leopard (*Panthera pardus*). J Zoo Wildl Med. 2000;31(3):379-82.
15. Mey J, Babiuk RP, Clugston R, Zhang W, Greer JJ. Retinal dehydrogenase-2 is inhibited by compounds that induce congenital diaphragmatic hernias in rodents. Am J Pathol. 2003;162(2):673-9.
16. Morita T, Michimae Y, Sawada M, Uemura T, Araki Y, Haruna A, et al. Renal dysplasia with unilateral renal agenesis in a dog. J Comp Pathol. 2005;133(1):64-7.
17. Nakamura H, Doi T, Puri P, Friedmacher F. Transgenic animal models of congenital diaphragmatic hernia: a comprehensive overview of candidate genes and signaling pathways. Pediatr Surg Int. 2020;36(9):991-7.
18. Oliveira ELR, Costa ALM, Borges MF, Nemer VC, Gonçalves RAB, Vasconcellos M, et al. Unilateral Renal Agenesis in Chilean-Flamingo (*Phoenicopterus chilensis*). Acta Scientiae Veterinariae. 2020;48(496).
19. Pinheiro LL, Branco É, Souza DC, Pereira LHC, Lima AR. Descrição do plexo braquial do cachorro-do-mato (*Cerdocyon thous* Linnaeus, 1766) %J Ciência Animal Brasileira. 2014;15:213-9.
20. Räikkönen J, Bignert A, Mortensen P, Fernholm B. Congenital defects in a highly inbred wild wolf population (*Canis lupus*). Mammalian Biology. 2006;71(2):65-73.
21. Randolph J, Bush M, Abramowitz M, Kleiman D, Montali RJ. Surgical correction of familial diaphragmatic hernia of Morgagni in the Golden Lion Tamarin. Journal of pediatric surgery. 1981;16(3):396-401.
22. Seeley KE, Garner MM, Waddell WT, Wolf KN. A Survey of Diseases in Captive Red Wolves (*Canis Rufus*), 1997-2012. J Zoo Wildl Med. 2016;47(1):83-90.
23. Smith SA, Martin KE, Dodd KL, Young ID. Severe microphthalmia, diaphragmatic hernia and Fallot's tetralogy associated with a chromosome 1;15 translocation. Clin Dysmorphol. 1994;3(4):287-91.
24. Sousa MG, de Cordova FM, Ramos AT, Viana EB, de Castro Conti LM. Ventricular Septal Defect in a Crab-Eating Fox (*Cerdocyon Thous*). J Zoo Wildl Med. 2016;47(2):667-70.
25. Souza NF, Mendes CCR, Vasconcelos LDP, Carvalho FM, Farias AA, Cardoso AMC. Agenesia renal unilateral em *Saimiri sciureus*: relato de caso. I Congresso Brasileiro de Patologia Veterinária/XVI Encontro Nacional de Patologia Veterinária; Curitiba, Paraná, Brazil.2013. p. 392.
26. Taney KG, Moore KW, Carro T, Spencer C. Bilateral ectopic ureters in a male dog with unilateral renal agenesis. Journal of the American Veterinary Medical Association. 2003;223(6):817-20, 0.
27. Uemura A, Tanaka R. Unilateral Renal Agenesis in an Aged Dog with Severe Urine Accumulation and a Urinary Tract Infection. Kafkas Üniversitesi Veteriner Fakültesi Dergisi. 2017;24.
28. Wadhwa R, Ahmad Z, Kumar M. Delayed traumatic diaphragmatic hernia mimicking hydropneumothorax. Indian J Anaesth. 2014;58(2):186-9.
29. Wilson JG, Roth CB, Warkany J. An analysis of the syndrome of malformations induced by maternal vitamin A deficiency. Effects of restoration of vitamin A at various times during gestation. Am J Anat. 1953;92(2):189-217.
30. Wobeser G. Traumatic degenerative, and developmental lesions in wolves and coyotes from Saskatchewan. 1992;28(2):268-75.
31. Zaiss I, Kehl S, Link K, Neff W, Schaible T, Sutterlin M, et al. Associated malformations in congenital diaphragmatic hernia. Am J Perinatol. 2011;28(3):211-8.