



Case report

Transitional cell carcinoma of the renal pelvis in a dog with combined treatment with unilateral nephrectomy and carboplatin

Natália M. Ocarino¹, Patrícia C. Souza¹, Jankerle N. Boeloni¹, Gleidice E. Lavalle¹, Eliana M. Souza¹, Luiz C. Pereira¹, Rogéria Serakides^{1*}

¹Escola de Veterinária da Universidade Federal de Minas Gerais, Brazil

*Corresponding author: Departamento de Clínica e Cirurgia Veterinárias, Escola de Veterinária da Universidade Federal de Minas Gerais, Av. Presidente Antônio Carlos, 6627 – CEP 30161-970, Belo Horizonte, Minas Gerais – Brazil. Phone: 55 31 3499 22 29, Fax: 55 31 3499 22 30. E-mail: serakide@dedalus.lcc.ufmg.br

Submitted May 28th 2009, Accepted June 19th 2009

Abstract

A transitional cell carcinoma of the renal pelvis was diagnosed in a 10-year-old, male German shepherd that presented with a 1-month history of hematuria and weight loss. Unilateral nephrectomy and chemotherapy with carboplatin was applied, but the dog was euthanized five months after the surgery due to metastasis.

Key Words: Chemotherapy, kidney, neoplasia

Introduction

Primary renal neoplasms are relatively rare in domestic animals. Carcinomas, nephroblastomas, adenomas, and spindle cell sarcomas have all been described in dogs, horses, pig and cows (16). Malignant epithelial neoplasias of the renal parenchyma are the most common type (5), and renal pelvis neoplasias are rare comprising 7% of the total number of renal neoplasias (10).

Treatment for primary renal neoplasia principally involves surgical tumor removal (8). In the human literature, there are conflicting results regarding the use of radiotherapy and chemotherapy as surgical adjuvants (7). Carboplatin is one of the most common chemotherapeutics used in the treatment of canine neoplasias. There are no reports, however, that address the use of carboplatin as an adjuvant in the treatment of primary renal neoplasias in dogs. Furthermore, studies evaluating the effects of

surgical and chemotherapeutic treatments on the survival rate of animals with renal tumors are scarce (13). The purpose of this study is to report a case of transitional cell carcinoma of the renal pelvis in a dog that underwent combined treatment with unilateral nephrectomy and carboplatin.

Case report

A 10-year-old, male German shepherd dog weighing 30 kg was admitted to the veterinary hospital at the *Universidade Federal de Minas Gerais* (UFMG) with a history of hematuria, anorexia, and weight loss over the previous 30 days. On clinical examination, the dog showed pain on abdominal palpation. The serum analysis showed increased levels of urea and creatinine (Table 1). A urinalysis collected by urethral probe showed hematuria and proteinuria (Table 1). On ultrasonographic examination of the abdomen, the right kidney was shown

Table 1 – Values found from the complete blood counts, renal function tests, and urinalyses before and after the treatment with nephrectomy and chemotherapy.

Analysis	Reference values	Day of nephrectomy (day 0)	Before the first dose of chemotherapy	After the second dose of chemotherapy	After the third dose of chemotherapy
Hemogram					
Erythrocytes (cells/uL)	5.5-8.5×10 ⁶	7.4×10 ⁶	7.3×10 ⁶	7.47×10 ⁶	7.5×10 ⁶
Hemoglobin (g/dL)	12-18	15.0	13.6	13,4	12,2
Hematocrit (%)	37-55	45.0	44.0	42	39
Renal function					
Urea (mg/dL)	20-56	206	40.0	34.0	25.0
Creatinine (mg/dL)	0.5-1.5	7.4	1.4	1.4	0.7
Urinalysis					
Protein	Negative	+++	++++	++	+
Occult blood	Negative	+++	+++	+++	0
Bilirubin	Negative	Negative	Negative	0	0
Erythrocytes (cells/field)	<5	uncountable	Negative	10-15	3
Epithelial cells	Negative	2 p/c	2 p/c	++	0

to be increased in size, and appeared as an irregular and hyperechoic mass. Radiographs of the thorax did not show evidence of metastatic disease. On exploratory laparotomy, the right kidney had an increased size with an irregular surface, and the ureter was dilated. Right nephrectomy and ureterectomy were performed. The left kidney and the other organs were grossly normal in appearance.

Macroscopically, the right kidney measured about 12 cm in diameter with an irregular surface. On sectioning, there was evident compression and reduction of the thickness of the renal medulla and cortex, as well as a dilated renal pelvis (Fig 1) that was filled with 250ml of serosanguineous liquid. In the hilus, a red solid mass was observed (8 cm diameter) (Fig 2). This tumor was friable and had irregular borders. The right ureter was dilated and partially obstructed by a small fragment of tissue projecting from the mass of the renal pelvis. Samples of the right kidney and ureter were collected and submitted in 10% formaldehyde for histology. The fixed tissues were processed and stained with hematoxylin-eosin.

Histologically, the mass of the right renal pelvis consisted of neoplastic epithelial cells organized in a solid and invasive pattern and associated with an abundant connective tissue stroma. The neoplastic cells showed a high degree of pleomorphism, but the majority of cells were polyhedral, with clear cytoplasm, similar to transitional epithelium cells (Fig 3). The nuclei of the neoplastic cells were hyperchromatic, and there were several mitotic figures seen per high power field, including some atypical mitotic figures. Blood vessels with thrombi of neoplastic cells, large areas of necrosis and hemorrhage, and foci of mineralization were observed in the neoplasm. The renal medulla disappeared and the renal cortex was very thin. Intense fibrosis and a multifocal lymphoplasmocytic inflammatory infiltrate were seen in the renal cortex. Based on the macroscopic and

microscopic features, transitional cell carcinoma of the renal pelvis was diagnosed.

Three weeks after surgery, the hematology and serum concentrations of urea and creatinine were normal (Table 1). At that time, chemotherapeutic treatment was started, which involved administration of a total of three doses of carboplatin (300mg/m², by intravenous injection, repeated every 21 days). Ten days after administration of the first dose of chemotherapy, a complete blood count, serum biochemistry and urinalysis were repeated. The serum urea and creatinine concentrations were normal, but the urinalysis showed proteinuria, hemoglobinuria and renal epithelial cell clumps. After the second chemotherapy session, leukopenia and thrombocytopenia were observed. In the same period, renal function was normal and stable; however, the urinalysis showed proteinuria, hematuria and abundant epithelial cells (Table 1). Before each chemotherapy session, abdominal ultrasonography was performed.

Up to four months after the end of chemotherapy, the animal maintained a stable clinical status, with normal appetite, micturition, and defecation. There was weight recovery, and fever and azotemia were not observed. Five months after nephrectomy, however, the animal was taken again to the Veterinary Hospital, presenting with lethargy and anorexia. Ultrasonographic examination of the abdominal cavity suggested disseminated metastases. Due to an unfavorable prognosis, the animal underwent euthanasia and necropsy.

At necropsy, several reddish white nodules, measuring 0.2 cm to 3.5 cm in diameter, either solid or friable, were located in the omentum, liver, serous of urinary bladder lung, parietal pleura, and pericardial sac (Fig 4). Fragments were collected from all organs with nodules, and also from the organs that had no macroscopic changes, such as the left kidney, adrenals, heart, mesenteric lymph nodes, inguinal lymph nodes, and

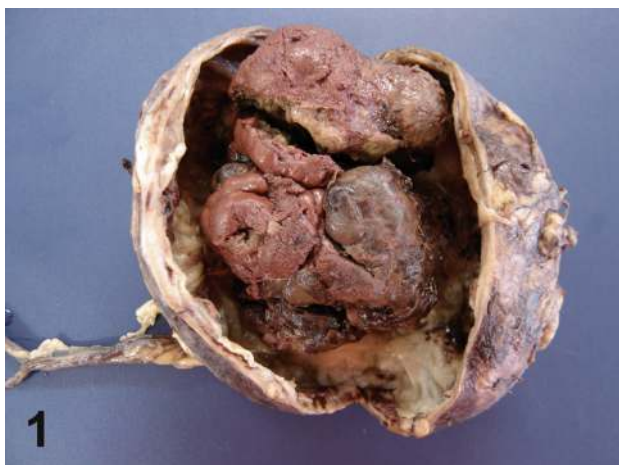

Figure 1 – Transitional cell carcinoma of the renal pelvis in a dog. Intense atrophy of the medullar and cortical regions with a dilated pelvis. In the pelvis, a solid mass is present with an 8 cm diameter and irregular border.

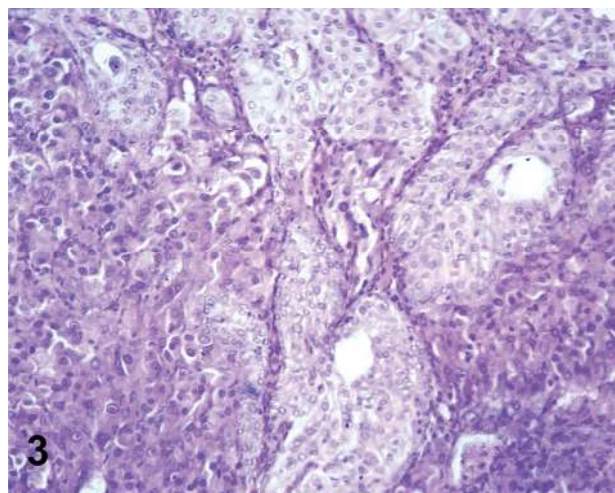


Figure 3 – Transitional cell carcinoma of the renal pelvis in a dog. Neoplastic epithelial cells, similar to transitional epithelium, are organized in a solid pattern, HE, bar = 100µm.

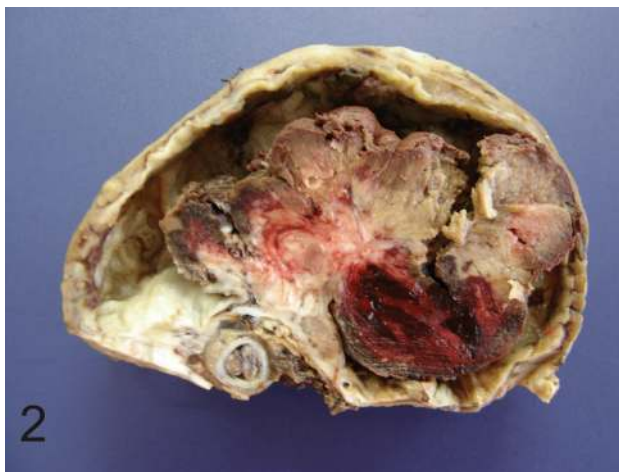

Figure 2 – Transitional cell carcinoma of the renal pelvis in a dog. The ureter is dilated and partially obstructed by a small fragment of neoplastic tissue from the renal pelvis.

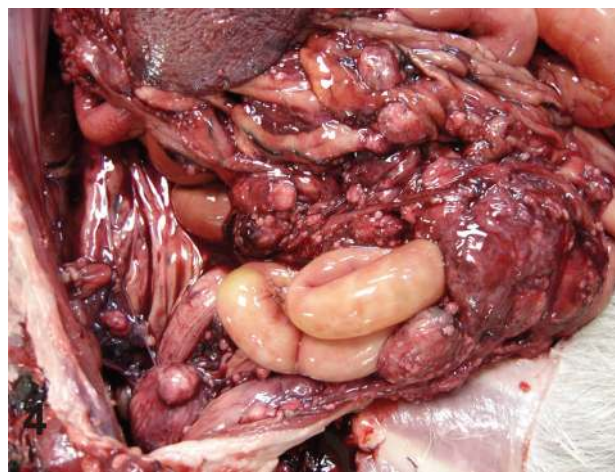


Figure 4 – Transitional cell carcinoma of the renal pelvis in a dog. Nodules, measuring 0.2cm and 3.5cm of diameter, located in the omentum and serous of the bladder and intestine.

internal iliac lymph nodes. Microscopic analysis of these nodules confirmed the suspicion of metastasis of transitional cell carcinoma of the renal pelvis. The left kidney, adrenals, heart, mesenteric lymph nodes, inguinal lymph nodes, and internal iliac lymph nodes did not show metastases.

Discussion

Primary renal tumors are uncommon in dogs, comprising 0.3 to 1.7% of canine neoplasias (11). Regarding neoplasias associated with the renal pelvis, some reports on the canine species may be found in the literature, but cases where patients were diagnosed with a renal pelvic carcinoma and then underwent some treatment are rare (8).

In this case, the clinical signs presented by the animal, such as hematuria, depression, anorexia, and weight loss, have been reported previously (3). Other signs, such as abdominal pain, vomiting, polydipsia, and polyuria have also been reported (8). Laboratory examinations, such as complete blood count and serum biochemical analysis show varying results, but anemia and azotemia are the most common changes observed (8). In the present case, anemia was not observed, but the animal presented high serum concentrations of urea and creatinine, which only normalized three weeks after nephrectomy. These values then remained normal throughout the chemotherapeutic treatment. Some changes, such as hematuria and proteinuria, have also already been reported in dogs with renal pelvis carcinoma (8). These changes were also observed in the dog from our study before surgery. Thrombocytopenia, which is also one of

the side effects of carboplatin, was observed after administration of the third dose (4). There was no evidence of metastasis observed in the radiographic examination of the thoracic region, abdominal ultrasonography, and laparotomy at the time of nephrectomy. Metastases of renal pelvis tumors are rare (6, 11) and sometimes occur as an extension of the renal capsule to the serous and intestinal walls (6). In this study, five months after nephrectomy, renal pelvis tumor metastases were observed in organs within the thorax and abdominal cavities. The macroscopic and microscopic findings confirmed that the TCC in the bladder was superficial and it was located only in the serous of bladder. The mucous membrane did not show any tumor. The TCC thus did not originate in the bladder. Due to these findings, the TCC was likely primary to the renal pelvis.

Renal neoplasias may be treated after unilateral nephrectomy and ureterectomy with chemotherapy. In the case of bilateral renal involvement, neither surgery nor chemotherapy is effective (6). The clinical findings improved significantly after complete tumor removal, which may be a consequence of the fact that only one kidney was affected by the tumor.

Platinum complexes are the most common drugs used as adjuvant treatment of neoplasias, and cisplatin has been used very frequently in veterinary oncology (2). Nevertheless, cisplatin's high toxicity to the urinary, gastrointestinal, and nervous systems has limited its use. Therefore, carboplatin, an analog of cisplatin that has reduced toxicity, has been used instead (1). In veterinary medicine, there are reports on the use of carboplatin in the treatment of osteosarcomas (9), bladder transitional cell carcinomas (4, 15), mesotheliomas (3), mesenchymomas (12), ependymomas (19), thyroid adenocarcinomas, melanomas (18), perianal adenocarcinomas (14), and mammary gland tumors (17). However, studies have demonstrated that carboplatin does not have good results in the treatment of bladder transitional cell carcinomas (4). There are no studies of this agent in the treatment of renal pelvis tumors in dogs. The literature has few studies on the survival time of dogs with transitional cell carcinoma of the renal pelvis. In a follow-up of five dogs with carcinoma of the renal pelvis after unilateral nephrectomy without chemotherapeutic treatment, the survival times observed were three months, five months, and 25 months after nephrectomy; two animals were euthanized during surgery (8). In the animal in the present study, the dose of carboplatin used was in accordance with the dose recommended in the literature (4, 14), but the effectiveness of the treatment is still unclear. Nephrectomy remains the treatment of choice for unilateral primary renal neoplasias without evidence of metastasis. For some tumors, the best therapy is the combination of surgery and chemotherapy. In this case, the association of nephrectomy and chemotherapy does not seem to have improved the animal's survival time compared to the study of Klein *et al.* (1988), who evaluated the survival time after

nephrectomy without adjuvant treatment. The survival time after treatment is important, but the patient's quality of life cannot be taken for granted. In the present case, the patient maintained stable clinical findings and was without symptoms until a little more than four months after nephrectomy. Further studies on the response of these tumors to the combined treatment of nephrectomy and chemotherapy are necessary.

References

1. BARABAS K., MILNER R., LURIE D., ADIN C. Cisplatin: a review of toxicities and therapeutic applications. *Vet. Comp. Oncol.*, 2008, 6, 1-18.
2. BERG J. Canine osteosarcoma. *Vet. Clin. North. Am. Small Anim. Pract.*, 1996, 26, 111-121.
3. BRISSON BA., REGGETI F., BIENZLE D. (2006) Portal site metastasis of invasive mesothelioma after diagnostic thoracoscopy in a dog. *JAVMA*, 2006, 15, 980-983.
4. CHUN R., KNAPP DW., WIDMER WR., DENICOLA DB., GLICKMAN NW., KUCZEK T., DEGORTARI A., HAN CM. Phase II clinical trial of carboplatin in canine transitional cell carcinoma of the urinary bladder. *J. Vet. Int. Med.* 1997, 11, 279-283.
5. CROW SE. Urinary tract neoplasms in dogs and cats. *Comp. Cont. Education*, 1985, 7, 607-618.
6. DAGLI ML., CALDERANO FF., SILVA MT., GUERRA JL. Squamous cell carcinoma of renal pelvis with metastasis in a dog. *J. Comp. Pathol.*, 1997, 116, 397-402.
7. EDSMEYER F., ESPOSTI PL., ANDERSSON L., STEINECK G., LAGERGREN C., STRANDER H. Interferon therapy in disseminated renal cell carcinoma. *Radiol. Oncol.*, 1983, 63, 21-26.
8. KLEIN MK., COCKERELL GL., HARRIS CK. Canine primary renal neoplasms: A retrospective review of 54 cases. *J. Am. Anim. Hosp. Assoc.*, 1998, 24, 443-452.
9. LIPTAK JM., DERNELL WS., EHRHART N., LAFFERTY MH., MONTEITH GJ., WITHROW SJ. Cortical allograft and endoprosthesis for limb-sparing surgery in dogs with distal radial osteosarcoma: a prospective clinical comparison of two different limb-sparing techniques. *Vet. Surg.* 2006, 35, 518-533.
10. MEUTEN DJ. *Tumors of the urinary system*. Meuten, D. J. (ed.), *Tumors in Domestic Animals*, 4th ed, pp. 509-546. Iowa State Press. 2002.
11. MILITERNO G., BAZZO R., BEVILACQUA D., BETTINI G., MARCATO PS. Transitional cell carcinoma of the renal pelvis in two dogs. *J. Vet. Int. Med.* 2003, 50, 457-459.
12. MURPHY S., BLUNDEN AS., DENNIS R., NEATH P., SMITH KC. Intermandibular malignant mesenchymoma in a crossbreed dog. *J. Small Anim. Pract.*, 2006, 47, 550-553.

13. PAGE RL., MCENTEE MC., GEORGE SL., WILLIAMS PL., HEIDNER GL., NOVOTNEY CA., RIVIERE JE., DEWHIRST MW., THRALL DE. Pharmacokinetic and phase 1 evaluation of carboplatin in dogs. *J. Vet. Int. Med.*, 1993, 7, 235-240.
14. RASSNICK KM., RUSLANDER DM., COTTER SM., AL-SARRAF R., BRUYETTE DS., GAMBLIN RM, MELEO KA, MOORE AS. Use of carboplatin for treatment of dogs with malignant melanoma: 27 cases (1989-2000). *J. Am. Vet. Med. Assoc.*, 2001, 218, 1444-1448.
15. ROCHA TA., MAULDIN GN., PATNAIK AK., BERGMAN PJ. Prognostic factors in dogs with urinary bladder carcinoma. *J. Vet. Int. Med.*, 2000, 14, 486-490.
16. RUDD RG, WHITEHAIR JG, LEIPOLD HW Spindle cell sarcoma in the kidney of a dog. *J. Am. Vet. Med. Assoc.* 1991, 19, 1023.
17. SIMON D., KNEBEL JW., BAUMGARTNER W., AUFDERHEIDE M., MEYER-LINDENBERG A. In vitro efficacy of chemotherapeutics as determined by 50% inhibitory concentrations in cell cultures of mammary gland tumors obtained from dogs. *Am. J. Vet. Res.*, 2001, 62, 1825-1830.
18. SLENSKY KA., VOLK SW., SCHWARZ T., DUDA L., MAULDIN EA., SILVERSTEIN D. Acute severe hemorrhage secondary to arterial invasion in a dog with thyroid carcinoma. *J. Am. Vet. Med. Assoc.*, 2003, 223, 649-653.