



Diagnostic Exercise
From The Latin Comparative Pathology Group*

Multifocal ulcerative ventriculitis a pigeon by *Hadjelia truncata*

Contributors:

Jennine N. Ochoa¹*, John M. Adaska¹.

¹ California Animal Health and Food Safety Laboratory-Tulare Branch, School of Veterinary Medicine, University of California, Davis.

**Corresponding author: E-mail: jnochoa@ucdavis.edu

Clinical History:

A single 5-year-old, white homing pigeon (*Columba livia domestica*) was submitted from a flock of 30 birds. The bird was bright alert and responsive upon presentation. One other bird was sick and two had died. The reported duration of illness was six months. Birds were noted to have a full crop but losing weight.

Necropsy and Microscopic Findings:

The bird was in fair nutritional condition with decreased pectoral muscles and minimal remaining fat stores. The crop contained large amounts of mixed seeds, some of which were quite large. The proventriculus was small and had somewhat roughened mucosal surfaces. The gizzard had two areas of marked roughening and apparent thickening of the koilin layer. One of these areas was at the anterior margin and the other one was near the posterior margin of the gizzard. The intestines contained minimal thick yellow material but overall were pink and shiny. The ceca contained scant gray-white feces. All other tissues were within normal limits..

Follow-up questions:

- Morphologic diagnosis
- Etiology



*The Diagnostic Exercises are an initiative of the Latin Comparative Pathology Group (LCPG), the Latin American subdivision of The Davis-Thompson Foundation and published in cooperation with the Brazilian Journal of Veterinary Pathology.



Davis-Thompson
Foundation

Editor-in-chief for this Diagnostic Exercise: Claudio Barros
Associate Editor for this Diagnostic Exercise: Ingeborg Langhor

Macroscopic Images:

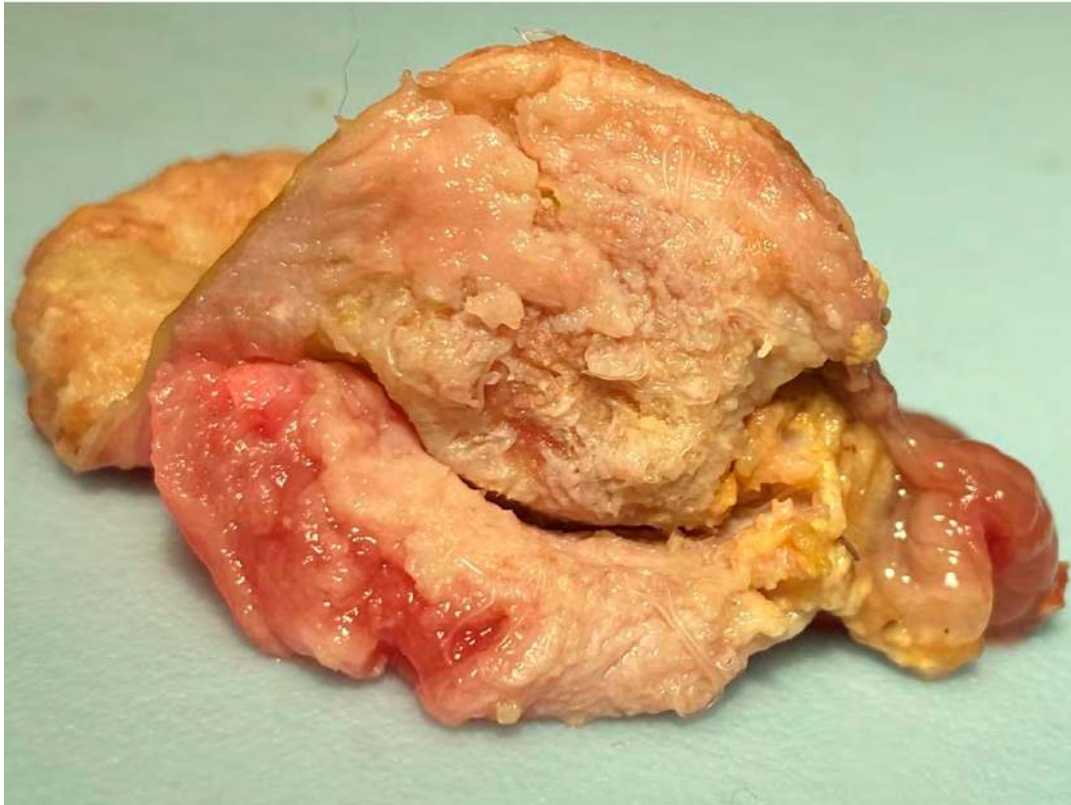


Figure 1

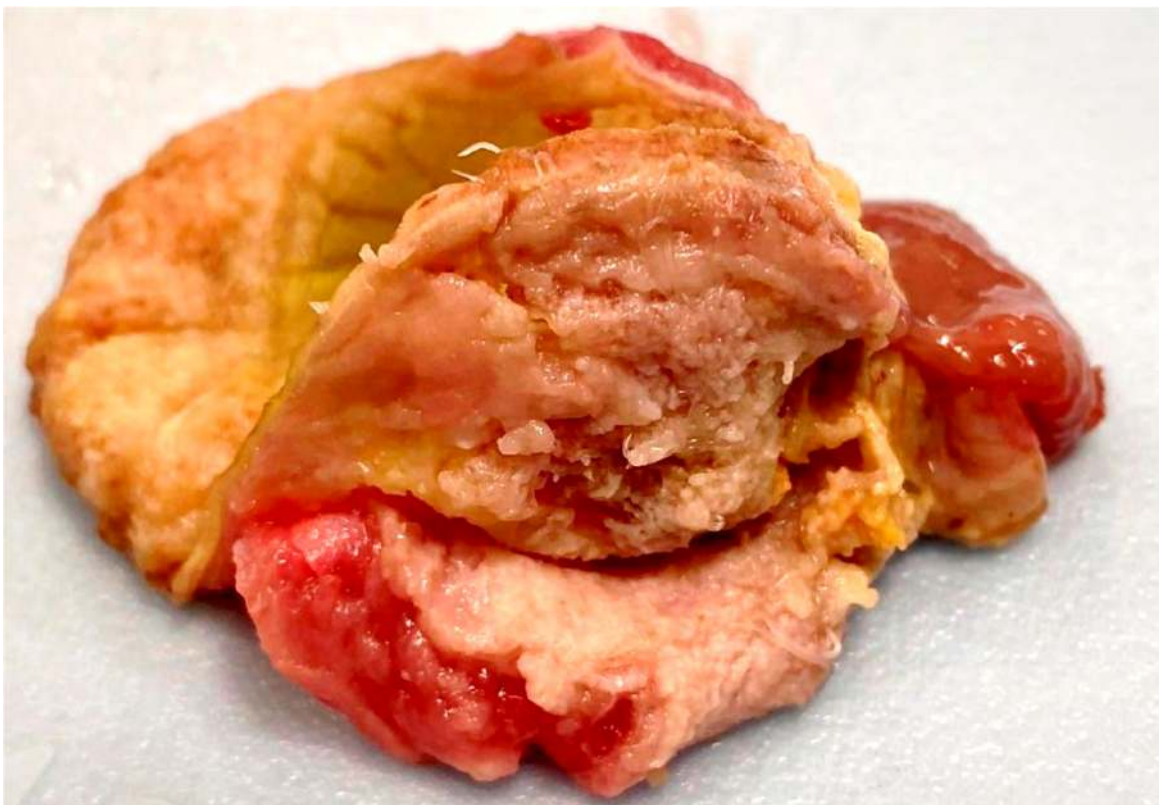

Figure 2

Microscopic Images:

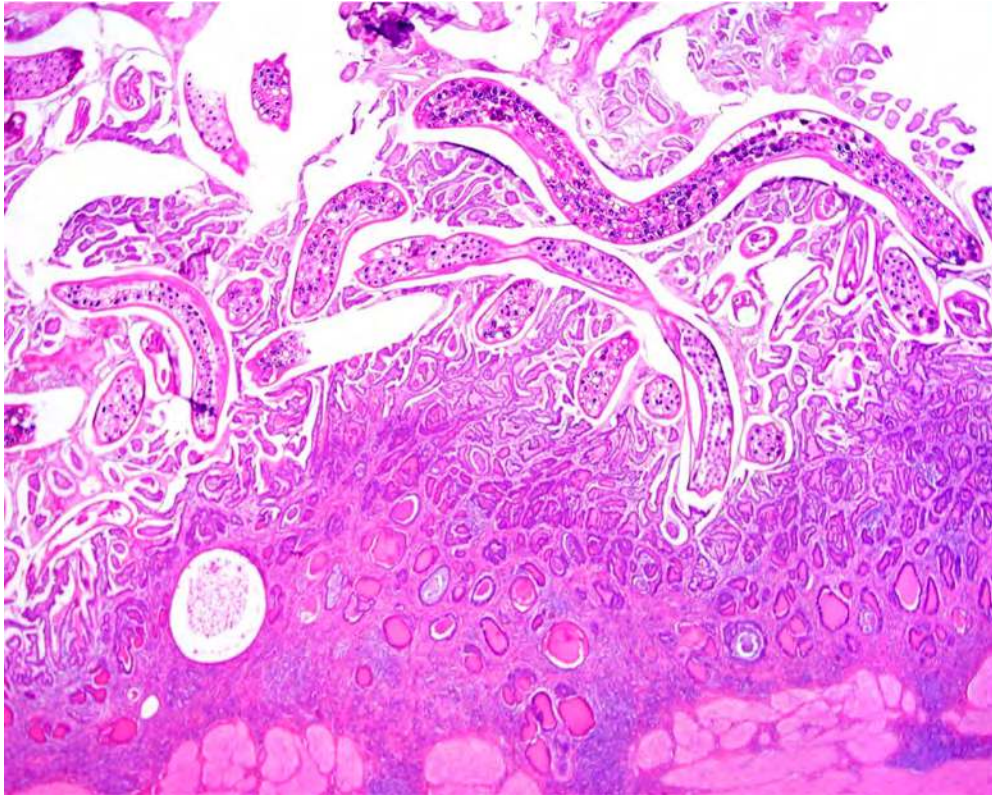


Figure 3

- **Morphologic diagnosis:** Severe, multifocal, ulcerative ventriculitis with intralesional nematode parasites
- **Etiology:** *Hadjelia truncata*

Discussion:

Hadjelia truncata (superfamily Spiruroidea) has been identified in the gastrointestinal tract of several types of birds, but seems to be pathogenic only in pigeons, in which it causes a parasitic ventriculitis. Disease has been diagnosed in pigeons from Iran, Saudi Arabia, Egypt, Cyprus, and North America (3). The complete lifecycle has not been fully elucidated, but transmission is suspected to involve arthropods as the intermediate host.

Clinical signs include weight loss, poor feed consumption and/or conversion, poor feathering, diarrhea, and increased mortality (1).

The diagnosis is made by the presence of thread-like and approximately 1-2 cm long nematodes under the koilin layer of the ventriculus (the koilin layer must be lifted from the ventricular glandular epithelium to reveal the nematodes, especially in mild cases). The koilin layer often will be thickened, ulcerated, and fragile. The overall ventriculus size may be 2-3 times larger than expected due to thickening of the smooth muscle layer (2). Microscopically, the koilin layer is markedly disrupted and, between the koilin and glandular layers, there are nematodes with a thick cuticle that have regularly spaced ridges and lateral wing alae. There is

coelomyarian musculature along the body and ciromyarian musculature along the esophagus. Within the reproductive tracts of the females there are oval, thick-shelled, embryonated eggs. Cystic glandular hyperplasia is often associated with the infection, with both heterophilic and lymphocytic infiltrates as well as smooth muscle hypertrophy (2,3).

Antemortem tests include fecal floatation (centrifugation methods are best) and direct smears; although fecal egg shedding may not be continuous resulting in a false negative result (which has been reported in cases that had lower *Hadjelia truncata* worm burdens on necropsy). 18S PCR primers have been developed, but testing has not yet been validated for routine diagnostic testing (1).

References

1. Kelly JM, Senties-Cué CG, Charlton BR, Gerhold RW, Santoro TJ, Bland MC. Treatment, diagnostic trials, and construction of species-specific PCR primers of *Hadjelia truncata* in pigeons (*Columba livia*). Appl Poul Res. 2013; 22(3):559-64.
2. Oryan A., Rakhshandehroo E, Kamali SA, Taebi Pour MJ. Histopathological changes in the upper digestive tract of pigeons infected with *Hadjelia truncata*. J Parasit Dis. 2016; 40 (3):881-4.
3. Senties-Cué CG, Charlton BR, Anthenill L, Naem S, McDougald L, Bland M. Parasitic ventriculitis caused by *Hadjelia truncata* in California rock pigeons (*Columba livia*). J Vet Diagn Invest. 2011; 23(6):1243-6.